



# HOKKAIDO UNIVERSITY

Title	CLINICAL CASES OF INTESTINAL OBSTRUCTION WITH FOREIGN BODIES AND INTUSSUSCEPTION IN DOGS
Author(s)	KOIKE, Toshio; OTOMO, Kanjuro; KUDO, Tadaaki et al.
Citation	Japanese Journal of Veterinary Research, 29(1-2), 8-15
Issue Date	1981-07-01
DOI	<a href="https://doi.org/10.14943/jjvr.29.1-2.8">https://doi.org/10.14943/jjvr.29.1-2.8</a>
Doc URL	<a href="https://hdl.handle.net/2115/2211">https://hdl.handle.net/2115/2211</a>
Type	departmental bulletin paper
File Information	KJ00003407943.pdf



## CLINICAL CASES OF INTESTINAL OBSTRUCTION WITH FOREIGN BODIES AND INTUSSUSCEPTION IN DOGS

Toshio KOIKE, Kanjuro OTOMO, Tadaaki KUDO  
and Tamotsu SAKAI

*Department of Veterinary Surgery  
Faculty of Veterinary Medicine  
Hokkaido University, Sapporo 060, Japan*

(Received for publication, February 26, 1981)

The medical records of dogs treated in our veterinary hospital during a period of 15 years until 1978 were reviewed. Intestinal obstruction was diagnosed in 47 dogs, among which 51.06 % were under 12 months of age and 80.85 % were under 3 years. The period which elapsed from the appearance of clinical signs to the operation of the obstructed intestines averaged about 5 days (ranging from 1 to 24 days). The presurgical hematological findings of 5 dogs with intestinal obstruction suggested hemoconcentration, low level chloride in the serum, and a rise in the whole blood pH. In the cases of intestinal obstruction in dogs, 87.23 % were caused by foreign bodies and 12.77 % with intussusceptions. The foreign bodies were stones (41.46 %), corn-cobs (24.39 %), and others. The cranial portions of the obstructing intestines were dilated 1.4 to 1.8 times as much as the caudal portions, and the intestines of the obstructing sites were 1.7 to 2.7 times larger than the caudal portions. The severely damaged intestines were excised partially from 2 patients and incised only from 45 patients. Three patients died during and after the intestinal operation, but 44 patients recovered to normal following surgery. Biopsy specimens of the caudal intestines of the obstructing sites revealed normal tissues, but the microscopical examinations showed epithelial desquamation, hyperaemic and hemorrhages in the lamina propria, and edema and hemorrhages in the muscle.

### INTRODUCTION

Several experimental studies of intestinal obstruction in dogs have been conducted<sup>7, 9, 12</sup>; however, statistical clinical and hematological findings of intestinal obstruction in dogs have not been widely reported except for some specific cases encountered by practicing veterinarians.<sup>4, 8, 10, 11</sup> As the clinical features of intestinal obstruction in dogs are not always typical, we have analysed the medical records of our clinical cases in order to obtain information of the various types of intestinal obstruction in dogs.

## MATERIALS AND METHODS

The medical records of dogs treated at the veterinary hospital attached to the Faculty of Veterinary Medicine, Hokkaido University, Japan, for a period of 15 years from January 1964 to November 1978 were reviewed. In 1978, intestinal obstruction was diagnosed in 5 dogs. In these dogs presurgical hematological findings were observed and the biopsy specimens from the caudal intestines of the obstructing sites were recovered during surgery. The histological samples were fixed in 10% formalin, embedded in paraffin, sectioned at  $4\mu$ , and stained with hematoxylin-eosin.

## RESULTS

## Distribution of intestinal obstruction in dogs

We reviewed the medical records of 9,156 dogs treated at our hospital during a period of 15 years, until 1978, with the result that intestinal obstruction was diagnosed in 47 dogs (0.51%).

The age distribution of the dogs with intestinal obstruction and all clinical dogs is summarized in figure 1. Twenty-four of the dogs with intestinal obstruction were under 12 months of age (51.06%) and 38 were under 3 years (80.85%). Of the clinical dogs, however, 36.22% were under 12 months and 62.06% were under 3 years. The diagnosis on intestinal obstruction was confirmed 0.72% of the outpatients under 12 months, 0.67% under 3 years, and 0.26% over 4 years of age.

Of the outpatients 51.01% were females and 48.98% were males; 0.38% and 0.65% of these showed intestinal obstruction respectively.

The breed distribution of dogs with intestinal obstruction and clinical dogs is sum-

FIGURE 1 Age distribution of dogs with intestinal obstruction

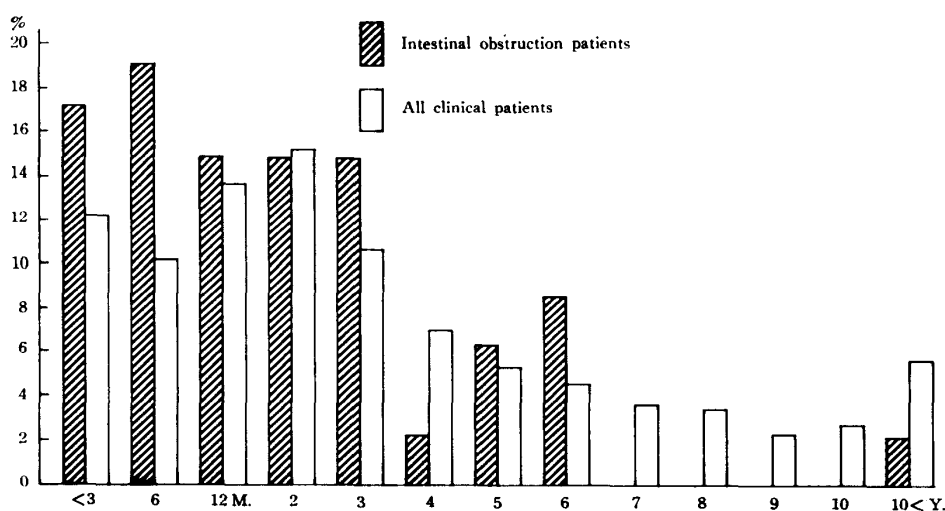


TABLE 1 *Breed distribution of dogs with intestinal obstruction*

BREED	HEAD OF DOGS	BREED % OF CLINICAL DOGS	INTESTINAL OBSTRUCTION % OF BREED POPULATION
Mongrel	3	20.50	0.15
Hokkaido-Ken	18	14.64	1.34
Dachshund	4	4.99	0.84
Collie	4	3.16	1.34
Setter	4	2.63	1.65
Labrador Retriever	3	1.59	2.05
Other breeds	11*	52.49	0.23
Total	47	100.00	0.51

\* One case each

marized in table 1. Mongrel dogs occupied few of the patients with intestinal obstruction, but many of the outpatients.

#### Clinical signs

The obstructed sites of the intestines are given in table 2. The period which elapsed from the appearance of clinical signs such as vomiting, anorexia, depression and discomfort, to the operation of the obstructed intestines ranged from 1 to 24 days, with an average of about 5 days.

The principal clinical signs of disease observed by the owners of the patients were anorexia in 47 animals (100 %) and vomiting in 43 animals (91.49 %).

At first observation, the patients showed serious dehydration associated with dry and lusterless hair, diminished skin turgor, dry visible mucous membranes, enophthalmos, and general prostration.

TABLE 2 *Days elapsed before operation*

SITE	HEAD OF DOGS	DAYS BEFORE OPERATION
Duodenum	13	2.90±1.37
Jejunum	12	5.22±2.81
Ileum	14	5.58±2.77
Colon	8	10.14±5.39*
Total	47	5.19±3.55

\* Significance of differences between colon and small intestine (P<0.001)

Careful abdominal palpation often disclosed the obstructing sites, and the radiographic figures revealed distension of the intestines with gas, fluids and/or foreign bodies. Diarrhoea was common along with bloody stool for some days when the patients had low appetite.

#### Presurgical hematological findings

Hematological findings in 5 patients examined before operation on the obstructed intestines are summarized in table 3. With exception of dog No. 5, four dogs showed hemoconcentration with the increase of hematocrite values. The leucocyte counts and differential cell counts were not stationary. The total protein contents, the sodium values and the potassium values in the serum were within normal limits, but the chloride

TABLE 3 *Presurgical hematological findings*

	DOG NUMBER				
	1	2	3	4	5
Obstructing site	Duodenum	Ileum	Ileum	Ileum	Ileum
Foreign body	Stone	Stone	Stone	Corn-cob	Corn-cob
Days before operation	2	2	4	7	8
Erythrocyte sedimentation rate (mm)					
1 hour	8.2	—	19.5	8.7	30.2
2 hours	16.9	—	26.7	18.8	39.5
Erythrocytes ( $10^6/\mu\text{l}$ )	8.06	12.07	8.40	5.53	6.91
Hemoglobin (%)	111	—	94	84	73
Packed cell volume (%)	54.5	50.0	56.5	52.0	42.0
Leucocytes ( $10^3/\mu\text{l}$ )	16.00	20.40	6.00	14.40	21.20
Differential leucocyte distribution (%)					
Basophils	0.0	0.0	0.0	0.0	0.0
Eosinophils	10.0	2.0	0.0	0.0	1.5
Band neutrophils	3.0	3.0	9.5	3.5	3.0
Mature neutrophils	54.5	81.0	79.5	68.0	78.5
Lymphocytes	22.0	7.0	3.0	22.5	15.5
Monocytes	10.5	7.0	8.0	6.0	1.5
Serum proteins (g/dl)	8.1	6.8	8.3	5.4	6.5
Albumin/globulin ratios	—	0.64	0.68	0.69	0.55
Serum sodium (mEq/l)	—	146	141	138	150
Serum potassium (mEq/l)	—	4.0	3.8	3.6	3.9
Serum chloride (mEq/l)	88	104	88	96	99
Blood pH	7.47	7.53	7.56	7.52	7.57
Blood urea nitrogen (mg/dl)	—	21.8	79.2	36.6	11.4

values were below normal while the whole blood pH values were above normal.

#### Gross appearance of obstructed intestines

The cranial portions of the obstructing intestines were characterized by distension of the intestines with gas and/or fluid; however, the caudal portions showed slight atrophy. The intestines of the obstructing sites and the cranial portions had edematous, congestive and hemorrhagic walls. The figures were modified by the type of the intestinal obstruction, the type and size of the foreign body, and the period after the appearance of the clinical signs. The intestines obstructed with macadams were more severely damaged than those with cobbles. The subserosa of intestines obstructed with corn-cobs showed extensive hemorrhagic injuries. The walls of intestines obstructed with textile goods were folded like an accordion and damaged widely; severe circulatory failure was also apparent.

These causes and sites of intestinal obstruction are given in table 4. Foreign bodies were recovered from 41 dogs with intestinal obstruction (87.23%), and intussusceptions were demonstrated in 6 patients (12.77%). The foreign bodies recovered were 17 stones (41.46%), 10 corn-cobs (24.39%), and others. Stones and corn-cobs were frequently recovered from the ileum and the jejunum respectively.

The size of the foreign bodies and dilatation of the obstructed intestines are summarized in table 5. The cranial portions of the obstructing intestines were dilated 1.4 to 1.8 times as much as the caudal portions, and the intestines of the obstructing sites were 1.7 to 2.7 times larger than the caudal portions.

All of the 47 dogs with intestinal obstruction received surgical treatment; The

TABLE 4 *Causes and sites of intestinal obstruction*

CAUSE	DUODENUM	JEJUNUM	ILEUM	COLON	TOTAL
Stones	5	3	9		17
Corn-cobs	1	6	2	1	10
Hair balls				4	4
Textile goods	2	1			3
Rubber balls	1		1		2
Peach stones				1	1
Marbles	1				1
Plastic	1				1
Bones				1	1
Pieces of metal	1				1
Intussusceptions	1	2	2	1	6
Total	13	12	14	8	47

TABLE 5 *Size of foreign bodies and dilatation of intestines*

NO.	FOREIGN BODY	SIZE	DILATATION OF INTESTINE*	
			Cranial portion	Obstruting portion
1	Cobble	3.8×3.0×2.8 <sup>cm</sup>	1.5	2.2
2	Macadam	3.8×2.7×2.5	1.8	2.6
3	Macadam	3.6×3.0×2.8	1.4	2.7
4	Macadam	4.5×3.8×3.5	1.6	1.7
5	Corn-cob	5.5×2.5×2.5	1.5	1.8
6	Cobble	4.6×3.1×3.0	1.5	1.8
7	Corn-cob	4.7×3.8×3.8	1.4	1.8
8	Cobble	3.7×3.6×3.4	1.4	1.8

\* Times diameter as large as the caudal portion of obstructing intestine

severely damaged intestines were excised partially from 2 animals, and the less damaged ones were only incised from the remaining 45 patients.

Three patients died during and after surgery on the obstructing intestines. The patients were not brought to the hospital until many days after the appearance of clinical signs. The remaining 44 patients, on the other hand, recovered to normal after the operation.

Lactated Ringer's solution as the chief transfusion was administered before and after the operation (50 ml/kg/day). The animals were given 5 ml/kg of 1 % chondroitin sulphuric acid containing penicillin G (4,000 units/ml) intraperitoneally after closure of the facia-peritoneal layer, and antibiotics intramuscularly for several postoperative days.

The postoperative period was usually uneventful, and the sutures were removed on the 7- or 8th postoperative day. The patients' appetite returned around the 3rd day, but regular meals were not eaten until the 7- or 8th postoperative day. A number of patients showed diarrhea or loose stool; in one dog these symptoms persisted for 15 days.

#### Biopsy

Biopsy specimens were obtained from the caudal intestinal walls of the obstructing sites. The specimens were normal intestinal tissues macroscopically, but the microscopical examinations showed epithelial desquamation, hyperaemia, cell infiltration and hemorrhages in the lamina propria, hemorrhages of submucosa, and edema and hemorrhages of muscle.

#### DISCUSSION

CLARK (1968) reported that intestinal obstruction due to foreign bodies was 0.49 % of the dogs he examined. In our study, a diagnosis of intestinal obstruction was 0.51 %

of the dogs examined, and the disease due to foreign bodies was 0.45 % of the animals. It appears that the disease is infrequently found in the outpatients of veterinary hospitals; however, intestinal obstruction in dogs is an important disease noticed by surgical veterinarians. CLARK's results suggested that 74 % of dogs with intestinal obstruction improved after surgery. Whereas, in our study, 93.6 % of 47 patients with intestinal obstruction recovered to normal after surgery, and the remaining 6.4 % patients died during and after the intestinal operation.

We have examined the records of dogs treated at our hospital between the years 1964 and 1978. The clinical observations and the hematological examinations were inconstant for the period; however, the results clarified the clinical features of intestinal obstruction in dogs.

Intestinal obstruction in dogs has been considered to be caused largely by foreign bodies in the intestines.<sup>2,6)</sup> CLARK (1968) reported that the most common foreign bodies were stones, rubber objects, and others. Our records showed that stones, corn-cobs and others were common, which suggested that corn-cobs were a special type of foreign bodies peculiar to Sapporo, Japan.

In addition, we observed that intestinal obstruction in dogs showed the subacute clinical syndrome. One patient brought to our hospital on the 24th day after the appearance of the clinical signs of intestinal obstruction was treated surgically and recovered to normal. MATSUBARA (1974) reported that in 2 dogs experimentally obstructed by sewing the end of the ileum, the survival period was 26 and 28 days. The survival periods of our clinical and his experimental cases suggested that the successful operable stage of intestinal obstruction in dogs could be extended over a long period of time. In our study, the operation were carried out at an average of 5 days after the appearance of the clinical signs. The major clinical and hematological signs of animals with intestinal obstruction were dehydration. HORNBUCKLE & KLEINE (1977) noted an increase in the variation of fluid balance in dogs with intestinal obstruction. Vomiting of the patients with intestinal obstruction caused the depletion of digestive juice, and the hypochloremic or metabolic alkalosis<sup>3,7)</sup>. In this study, the patients with intestinal obstruction were given drugs to alter the fluid balance to prevent these metabolic disturbances.

We incised the caudal portions of the obstructing intestines in 45 of the 47 patients, and excised partially the obstructing intestines with marked gross changes in the remaining 2 dogs. Of the 47 patients treated surgically, 44 recovered to normal. The results suggested that an enterotomy was usually sufficient to remove foreign bodies and to prevent a subsequent intussusception. KAZIWARA (1941) observed the histological changes from the duodenum to the ileum within 4 days after canine ileum was experimentally obstructed. However, in our investigation, a number of dogs with intestinal obstruction recovered to normal following intestinal incision without surgical removal. These results

were similar to these of EASLEY (1974). Our clinical findings that the patients showed diarrhea and soft stool following surgery agreed with the observations of TAKAHASHI (1975) and YASUI (1977). We concluded that postoperatively, patients with intestinal obstruction have to receive drugs to alter the fluid balance along with additional nutrients by transfusion.

## REFERENCES

- 1) CLARK, W. T. (1968): Foreign bodies in the small intestine of the dog *Vet. Rec.*, **83**, 115-119
- 2) EASLEY, J. C. (1974): Intestinal obstruction In: Current veterinary therapy V. Small animal practice Ed. KIRK, R. W. Philadelphia, London and Toronto: W. B. Saunders Company
- 3) HORNBUCKLE, W. E. & KLEINE, L. J. (1977): Obstruction of the small intestine In: Current veterinary therapy VI. small animal practice Ed. KIRK, R. W. Philadelphia, London and Toronto: W. B. Saunders Company
- 4) KANAMOTO, E. (1966): Intestinal trichomoniasis with intussusception in dogs *Jui-chikusan Shimpo (J. Vet. Med.)*, (417) 205-206 (in Japanese)
- 5) KAZIWARA, I. (1941): Morphological studies on experimental low intestinal obstruction *J. Nippon Med. Sch.*, **12**, 6 Suppl. (in Japanese)
- 6) LARSEN, L. H. & BELLENGER, C. R. (1974): Small intestine In: Canine surgery Ed. ARCHIBALD, J. 2ed, Santa Barbara: American Veterinary Publications
- 7) MATSUBARA, K. (1974): Experimental studies on intestinal obstruction in dogs: Its clinical and hematological findings on ileum obstruction *Jpn. J. Vet. Res.*, **22**, 102 (English summary of dissertation in Japanese)
- 8) MIYAMOTO, S. (1972): Clinical cases of intestinal obstruction in dogs *Jui-chikusan Shimpo (J. Vet. Med.)*, (570) 702-704 (in Japanese)
- 9) TAKAHASHI, Y. (1975): Experimental studies on intestinal obstruction in dogs: Clinical and hematological findings on ileum obstruction and after its relief *Jpn. J. Vet. Res.*, **23**, 115 (English summary of dissertation in Japanese)
- 10) TAMURA, T., TAMURA, T. & ITO, K. (1974): Notes of treatment: Intussusception in dogs and cats *Jui-chikusan Shimpo (J. Vet. Med.)*, (629) 1321-1322 (in Japanese)
- 11) YOSHIDA, K. (1969): A therapeutic experience of canine ileus *Jpn. J. Vet. Med. Ass.*, **22**, 510-512 (in Japanese)
- 12) YASUI, T. (1977): Experimental studies on intestinal obstruction in dogs: Clinical and hematological findings on infusion of Ringer's solution with relief of low intestinal obstruction *Jpn. J. Vet. Res.*, **25**, 34 (English summary of dissertation in Japanese)