



# HOKKAIDO UNIVERSITY

Title	SPONTANEOUS GLOMERULONEPHRITIS IN CHICKENS OF THE FIELD FLOCKS
Author(s)	MORIGUCHI, Ryoza; FUJIMOTO, Yutaka; KODAMA, Hiroshi
Citation	Japanese Journal of Veterinary Research, 31(1), 15-29
Issue Date	1983-03-15
DOI	<a href="https://doi.org/10.14943/jjvr.31.1.15">https://doi.org/10.14943/jjvr.31.1.15</a>
Doc URL	<a href="https://hdl.handle.net/2115/2271">https://hdl.handle.net/2115/2271</a>
Type	departmental bulletin paper
File Information	KJ00002374085.pdf



## SPONTANEOUS GLOMERULONEPHRITIS IN CHICKENS OF THE FIELD FLOCKS

Ryozo MORIGUCHI<sup>1</sup>, Yutaka FUJIMOTO<sup>1</sup> and Hiroshi KODAMA<sup>2</sup>

(Received for publication December 14, 1982)

Avian glomerulonephritis (GN) was found in autopsy materials of chickens from a commercial breeding farm in Hokkaido. Almost all of the affected chickens showed systemic lesions in the viscera, which have not been reported in spontaneous nephritis cases in the past, as well as GN. Changes in the viscera consisted of marked hyperplasia of lymphoreticular and plasma cells, prominent germinal center formation and vascular changes, all of which were particularly prominent in the kidneys, less severely in the liver, spleen, heart, proventriculus, thymus and etc.. Etiology of the disease was not clarified.

Key words : glomerulonephritis, chicken, lymphoreticular cell, plasma cell, germinal center

### INTRODUCTION

Concerning to the renal diseases in the fowl comprehensive review have been presented by SILLER (1981),<sup>24)</sup> who pointed out that if all of the kidneys from routine autopsy materials were subjected to histopathological examination, then lesions of proliferative glomerulonephritis (GN) would be encountered with surprising frequencies. Spontaneous GN, however, has been reported by only few investigators.<sup>4,20,22)</sup> The glomerular lesions or GN have been experimentally produced in chickens by overfeeding of toxic fat,<sup>25)</sup> by inoculation of *Mycoplasma synoviae* (MS)<sup>8,9,11)</sup> and by immunization with bovine glomerular basement membrane in Freund's complete adjuvant.<sup>2)</sup>

Present paper described occurrences of GN in chickens of Hokkaido. Interesting observations were that almost all of the chickens with GN showed noticeable systemic lesions in the viscera which have not been reported previously in nephritis cases.

### MATERIALS AND METHODS

Flock history : About two hundred thousand chickens reared in the breeding farm examined. Losses of chickens due to diseases tended to increase from about 16 weeks of age, and about three percent of the birds in every flock usually died or were killed because of diseases during 20 weeks of poultry production. Pathological examination of

<sup>1</sup> Department of Comparative Pathology and

<sup>2</sup> Department of Epizootiology, Faculty of Veterinary Medicine, Hokkaido University, Sapporo 060, Japan

diseased chickens (120 birds) aged 80–230 days which were obtained intermittently during 3 years between 1979 and 1981 revealed that the losses of these birds were caused largely by Marek's disease and GN described herein. Rare and occasional occurrences of lymphoid leucosis and synovitis were also found.

**Chickens examined :** Thirty chickens affected with GN were used. Their ages were 140–160 days in 28 chickens and 230 days in 2 chickens. Although some of the birds never showed histopathologically distinct GN, they were included in the group of GN chickens because of the presence of characteristic GN-associated lesions in the viscera.

**Pathological examination :** All of the chickens used were killed by exanguination and then necropsied. The tissues were routinely collected from the liver, spleen, kidneys, gonads, proventriculus, pancreas, skin, and brachial- and ischiadic nerves. They were fixed for 48 hours in 10% formalin or for 12 hours in Bouin's fixatives, and processed using conventional paraffin embedding. Sections were cut at 4 microns and stained with hematoxylin and eosin (H & E). Selected sections were stained with periodic acid-Schiff (P.A.S.), Mallory-Azan stain and Congo red stains.

## RESULTS

**Clinical- and macroscopic findings of chickens affected with glomerulonephritis.**

Chickens affected with GN showed clinically depressed condition, paleness of the comb and wattle, anorexia, emaciation, retarded growth, diarrhea with green or milky feces, and arrest of sexual maturity.

Frequently observed macroscopic findings were paleness and enlargement of the kidneys (Fig. 1), swelling of the liver, hydropericardium and dilatation of the right ventriculus, swelling of the mucosa of the proventriculus and small intestine, underdevelopment of the gonads, and atrophy of both of the thymus and bursa of Fabricius. Swelling of the leg joints and synovitis were seen in some chickens.

**Histopathological findings of chickens affected with glomerulonephritis.**

Principal pathological changes were GN, perivascular or interstitial hyperplasia of lymphoreticular and plasma cells, perivascular germinal center (GC) formation and vascular changes in the kidneys, less severely in the liver, spleen, heart, proventriculus, thymus and others, and atrophic changes of both of the thymus and bursa of Fabricius.

**Kidneys :** Renal changes suggestive for various developmental stages of proliferative GN were recognized in 26 out of 30 chickens examined. The majority of chickens showed proliferative GN and the remaining birds showed proliferative GN with crescent.

**Proliferative GN.** Not all of the glomeruli were involved simultaneously and the larger juxtamedullary glomeruli were the first to be affected. The initial changes of glom-

erular involvement were characterized by thickening of the wall of the capillary loop, swelling of the endothelial and epithelial cells of the tuft and P.A.S.-positive hyaline droplets deposition in the cytoplasm or the foot processes of the visceral epithelium (Fig. 2). Subsequently, more and more glomeruli became involved until the majority showed changes. The above-mentioned initial changes of the glomeruli were followed by proliferative glomerular changes which were characterized by proliferation of the endothelial, epithelial and mesangial cells in the tuft and capsule, and hyaline droplet degeneration of the visceral epithelium (Fig. 3). The glomeruli always became enlarged due to an increase in the size of the tuft. The parietal epithelium of Bowman's capsule and the visceral epithelium of the tuft consequently lay, without adhesion, in close apposition and fill the capsular space. The capillary loops were distorted by the proliferated cells in the tuft. Hyaline droplet degeneration of the visceral epithelium was noticeable and, however, it became weakened in the advanced glomerular lesions.

In the interlobular spaces of the cortices, marked changes were frequently seen (Figs. 4 and 5). Hyperplasia of lymphoreticular cells consisting of lymphocytes and reticulum cells was markedly seen. Hyperplasia of plasma cells including plasmablasts and mitotic figures and GC reaction were also noticeable within or adjacent to the sites of lymphoreticular cell proliferation. Important evidences were that in spite of the beginning or absence of the glomerular involvement the above-mentioned interstitial lesions were often prominent and, on the contrary, in cases showing advanced glomerular involvement (generalized proliferative GN), proliferated lymphoreticular cells tended to be distributed rather loosely and the GC present decreased in number as well.

Renal tubules appeared less severely degenerate but were often pressed by the accumulated cells in the interstitium. Hyaline droplet degeneration and infiltration of lymphoid cells into the tubular epithelium were also often present in the proximal convoluted tubules.

Generalized proliferative GN with epithelial crescents. All of the renal corpuscles became heavily enlarged. Bowman's capsule became greatly thickened owing to proliferation of the epithelial cells of the capsule which led to epithelial crescent formation and, in part, to the development of pericapsular fibrosis (Fig. 6). In the glomerular tufts overgrowth of the endothelial and epithelial cells tended to fill the glomerular spaces, causing adhesion between the parietal and visceral layers of Bowman's capsule. Capillary loops were distorted. Hyaline droplet degeneration of the visceral epithelium was mild or absent.

In the intertubular spaces of the cortices, relatively mild lymphocytic, plasma cellular and heterophil infiltration was present. GC formation was minimum or could not be found. On the other hand, interstitial fibrosis and thickening of the vascular wall due to fibrosis of the media and adventitia, hypertrophy or regeneration of the tubules were remarkable.

Liver : Hyperplasia of lymphoreticular cells mixed with plasma cells and GC reac-

tion were observed in the interlobular connective tissues of the majority of GN chickens. Hypertrophy of the media or edema of the wall of the arteries were occasionally found. Enlarged endothelial cells of the sinusoidal capillaries, the cytoplasm of which often contained P.A.S.-positive materials, were characteristically seen in the majority of the GN chickens (Fig. 7). Dilatation of the bile capillaries and hyaline thrombi in the sinusoidal capillaries were occasionally observed. Liver fibrosis indicated by atrophy of the parenchymal cells, thickening of the wall of the sinusoidal capillaries due to deposition of P.A.S.-positive and Congo red-negative substances and fibrous proliferation in the same sites were observed in 4 chickens.

**Spleen :** Splenic lesions were differentiated largely into two kinds. One kind, which was seen in about half of the GN chickens, was characterized by hyperplasia of periarterial lymphoid tissues and vascular changes. Periarterial GC formation, often greatly enlarged, was particularly prominent (Fig. 8). The vascular changes consisted of hypertrophy of the media or edema of the wall, adventitial cell-proliferation with some edema and lymphoid cell infiltration, and hyaline droplets deposition in the media or adventitia (Fig. 9). The other kind of lesions, which was found in about one-third the cases of the GN chickens, was characterized by marked depression of periarterial lymphoid tissues and marked proliferation of reticulum cells around the sheathed arteries (Fig. 10). Vascular changes consisting of irregular proliferation of the media with a tendency toward formation of nodular lesions or papillomatous proliferation of the intima were sometimes present. GC reaction was minimum or absent. Histologic features showing both of the above-mentioned splenic reaction were observed in some of the remaining chickens.

**Heart :** Cardiac lesions, which were found in the majority of GN chickens, consisted of hyperplasia of lymphoreticular and plasma cells mixed with a few heterophils, and GC formation in the perivascular tissues or interstices between muscle fibers in the epicardium and myocardium (Fig. 11). Interstitial edema and vascular changes consisting of hypertrophy of the media or edema of the wall were occasionally seen. In one case showing exceptionally severe cardiac lesions prominent hyperplasia of lymphoreticular cells mixed with a number of lymphoblasts and mitotic figures occurred throughout the heart, expanding markedly the interstices between myocardial fibers. Furthermore plasma cells including plasmablasts and GC or localized foci reminiscent of GC were found numerous within or adjacent to the proliferated lymphoreticular cell sites (Fig. 12).

**Lungs :** Alveolar emphysema and mild catarrhal bronchiolitis with hyperplasia of lymphatic tissues in the lamina propria were observed in the majority of GN chickens. In the interlobular septa, mild perivascular lymphocytic infiltration and GC formation were occasionally seen.

**Proventriculus and intestine :** About two-third of GN chickens showed proventricular lesions. The mucosal lesions consisted of hyperplasia of lymphoreticular and plasma cells mixed with heterophils in the lamina propria, and GC formation in the deeper

layers of the mucosa (Fig. 13). In the proventricular glands, most of the chickens showed atrophy of the glands and some of the birds demonstrated hypertrophy of the glands, hyperplasia of lymphoreticular and plasma cells accompanied with GC formation and fibrous proliferation in the interstitium within lobules.

In the small intestine, hyperplasia of the lymphatic tissues and plasma cells in the lamina propria were frequently seen.

Thymus and bursa of Fabricius : There was moderate to severe cortical and medullary atrophy of both of the thymus and bursa of Fabricius. GC formation and plasma cellular hyperplasia were occasionally found (3 out of the 30 GN chickens examined) in the medulla of the atrophied thymus (Fig. 14).

Other organs : Hyperplasia of lymphoreticular cells mixed with plasma cellular infiltration and GC formation were often found in the adrenal glands and pancreas. Mild Marek's disease lesions were occasionally seen in the peripheral nerves and skin.

#### DISCUSSION

The renal lesions of the GN chickens tended to develop proliferative GN with noticeable interstitial lesions. The histopathology of the GN resembled that of spontaneous GN of chickens reported by SILLER (1959).<sup>22)</sup> The pathological features of GN chickens described in the present report, however, were different from those described by Siller in the points of interstitial changes of the kidneys and lesions in other organs. In our GN cases, marked hyperplasia of lymphoreticular and plasma cells and GC formation were consistently seen in the interstitium of the cortices. Important evidences were that such interstitial lesions tended to be particularly prominent at the initial stages (or prior to) of development of GN. GC formation and dense lymphoid cell infiltration in the inter-tubular spaces have been produced in chickens by experimental inoculation of a picornavirus<sup>6,15)</sup> and infectious bronchitis virus<sup>19,23)</sup> which attack primarily the renal tissues. The present renal lesions of GN chickens, however, could be differentiated from these viral nephritis on the basis of the severity of glomerular involvement, the less severe degenerative changes of tubules or the distribution of lesions. Furthermore, similar changes such as hyperplasia of lymphoreticular and plasma cells and GC formation were also consistently seen in the liver, spleen, heart, proventriculus and etc.. Vascular changes were also frequently seen. It was suggested that hyperplasia of the lymphoreticular and plasma cells and GC formation in the interstitium of the kidneys may not be secondary lesions to the glomerular involvement, but may be primary lesions as well as those in other organs. But both of these changes in the viscera and GN appeared to have close correlation pathogenetically. These systemic changes have not been described in reports of spontaneous nephritis cases in the past.<sup>3,4,7,20,22)</sup> It may be important to investigate what stimuli were given to the occurrence of the GN and whether the stimuli inducing the GN as well as the systemic lesions in the viscera were similar or not.

It has been documented in man and in experimental animals that GN is a product of immunological mechanism. And it has recently been suggested that immune complex GN was induced in chickens by inoculation of infectious bursal disease virus<sup>13)</sup> or MS,<sup>8,9,11)</sup> and by immunization with bovine glomerular basement membrane in Freund's complete adjuvant.<sup>2)</sup> Pathological changes of the GN chickens resembled those of experimental infection of MS in many respects, i. e., GN development, vascular changes,<sup>8,9,10)</sup> GC formation in the thymus and spleen,<sup>8,17)</sup> reticuloendothelial proliferation in the viscera, atrophy of the thymus and bursa of Fabricius, and swelling of the leg joints or synovitis.<sup>8,9,11,12,17,21)</sup> Furthermore, a serological test indicated that almost all of the GN chickens showed positive agglutination reaction in a rapid serum plate test for MS (undescribed data in the results). However it is unexplainable that the present disease is induced by MS infection alone, because of severity and characteristics of the lesions in the present disease. Some important findings were reported by KUME et al. (1977)<sup>12)</sup> and KAWAKUBO et al. (1981).<sup>9)</sup> They revealed that the development of the systemic lesions induced by MS infection was altered due to thymectomy prior to inoculation of MS, and that increased incidences of the GN and vasculitis were found in addition to altered pathogenesis in the articular lesions. In addition they suggested that MS infection in chickens could lead to an immune complex disease by impairment of the immune mechanism, presumably initiated by thymic dysfunction.

Pathological features of the GN chickens were different from those of Marek's disease. However, because of the severity of hyperplasia of the lymphoreticular cells in the various organs of GN chickens and the coexistence of chickens affected with GN and Marek's disease in the field flocks examined, a question arises that Marek's disease virus-infection could play some role in the pathogenesis of the GN.

GC formation was one of the most characteristic phenomena in chickens after antigenic injection.<sup>1,18)</sup> Numerous GC reactions were seen in various organs of GN chickens, including the thymus. GC formation in the thymus was also observed in human auto-immune disease<sup>14)</sup> and the rodent thymus after injection of various substances such as diphtheria toxoid<sup>16)</sup> and horse radish peroxidase.<sup>5)</sup> It could be probable from the findings above-mentioned that autoimmune phenomena played a role in the pathogenesis of the GN.

#### REFERENCES

- 1) ANDERSON, J. C. (1973) : The induction of germinal centers in germfree chickens *J. Pathol.*, **109**, 251-257
- 2) BOLTON, W. K., TUCKER, F. L. & STURGILL, B. C. (1980) : Experimental autoimmune glomerulonephritis in chickens *J. Clin. Lab. Immunol.*, **3**, 179-184
- 3) FLETCHER, R. D. & MAAS, H. J. L. (1962) : Acute fowl cholera in a Connecticut chicken flock : Description of the isolation of *Pasteurella multocida* *Tijdsch. Diergeneeskd.*, **87**, 1125-1128

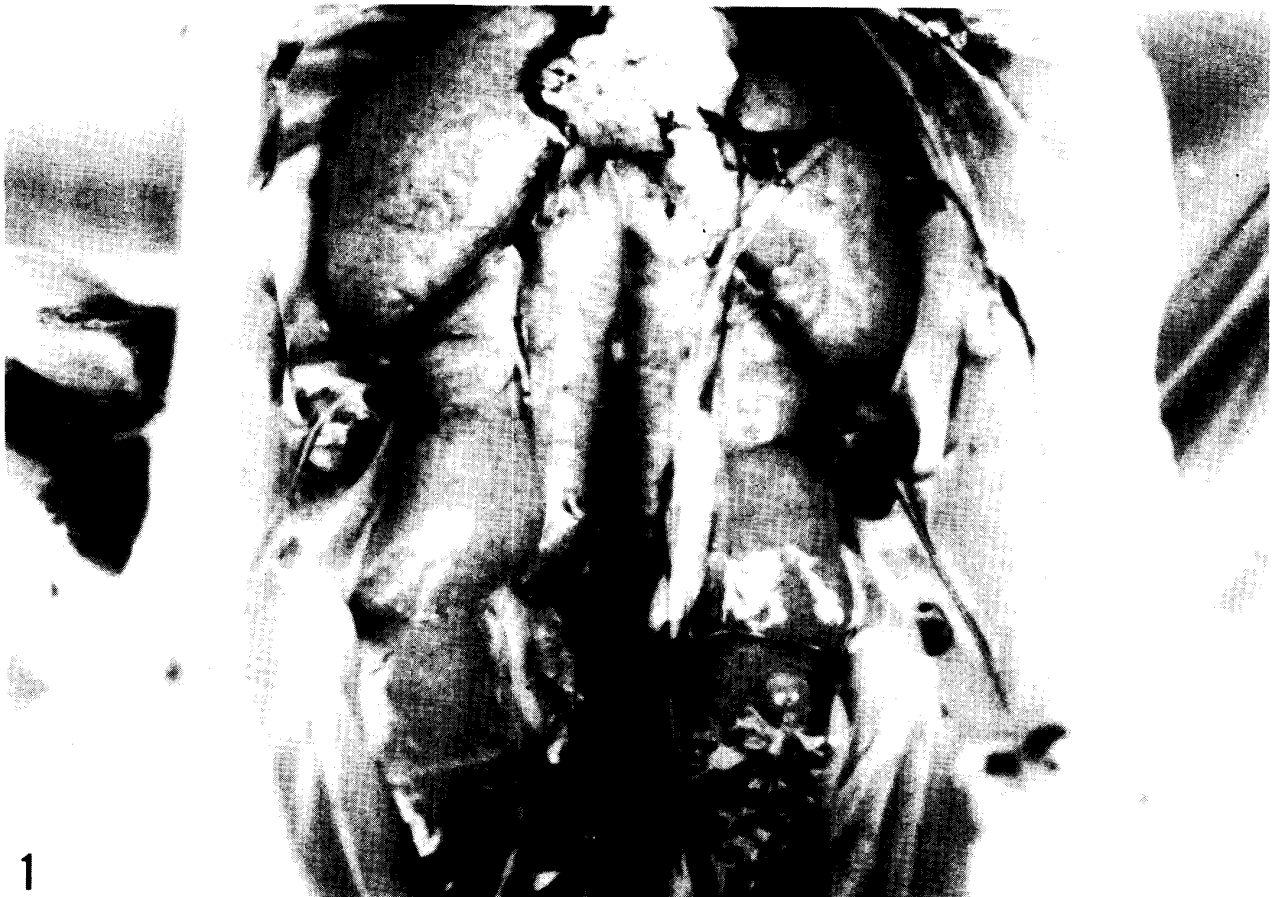
- 4) FRISCHBIER, G. & RINDFLEISCH, SEYFARTH, MARTHA (1948): Über Nierenschäden des Hausgeflügels unter dem Gesichtspunkt der allgemeinen Nephritisforschung *Dtsch. tierärztl. Wochenschr.*, **55**, 161–165
- 5) HABU, S. (1972) : Experimental production of lymphoid follicles in thymus by horse-radish peroxidase *Acta Pathol. Jpn.*, **22**, 681–695
- 6) IMADA, T., YAMAGUCHI, S. & KAWAMURA, H. (1979) : Pathogenicity for baby chicks of the G-4260 strain of the picornavirus "Avian nephritis virus" *Avian Dis.*, **23**, 582–588
- 7) ITAKURA, C. & KAWAI, Y. (1972) : Pathology of spontaneous cases of avian transmissible tubulonephrosis *Jpn. J. Vet. Sci.*, **34**, 61–69
- 8) KAWAKUBO, Y., KUME, K. & YOSHIOKA, M. (1980) : Histo- and immuno-pathological studies on experimental *Mycoplasma synoviae* infection of the chickens *J. Comp. Pathol.*, **90**, 457–467
- 9) KAWAKUBO, Y., KUME, K. & YOSHIOKA, M. (1981) : Effects of thymectomy and bursectomy on the systemic lesions of experimental *Mycoplasma synoviae* infection of the chicken *J. Comp. Pathol.*, **91**, 143–151
- 10) KELL, K. M. & OLSON, N. O. (1967) : Cardiac pathology associated with viral and mycoplasmal arthritis in chickens *Ann. New York Acad. Sci.* **143**, 204–217
- 11) KELL, K. M. & OLSON, N. O. (1970) : Pathology of chickens inoculated experimentally or contact-infected with *Mycoplasma synoviae* *Avian Dis.*, **14**, 291–320
- 12) KUME, K., KAWAKUBO, Y., MORITA, C., HAYATSU, E. & YOSHIOKA, M. (1977) : Experimentally induced synovitis of chickens with *Mycoplasma synoviae* : Effects of bursectomy and thymectomy on course of the infection for the first four weeks *Am. J. Vet. Res.*, **138**, 1595–1600
- 13) LEY, D. H. & YAMAMOTO, R. (1979) : Immune-complex involvement in the pathogenesis of infectious bursal disease virus in chickens *Avian Dis.*, **23**, 219–224
- 14) MACKAY, I. R. (1963) : Thymic "Germinal centers" and plasma cells in systemic lupus erythematosus *Lancet*, **28**, 667
- 15) MAEDA, M., IMADA, T., TANIGUCHI, T. & HORIUCHI, T. (1979) : Pathological changes in chicks inoculated with the picornavirus "Avian nephritis virus" *Avian Dis.*, **23**, 589–596
- 16) MARSHALL, A. H. E. & WHITE, R. G. (1961) : The immunological reactivity of the thymus *Br. J. Exp. Pathol.*, **42**, 379–385
- 17) MOORHEAD, P. D., CROSS, R. F. & HENDERSON, W. (1967) : Pathological manifestations of experimental infectious synovitis and staphylococcosis in chickens *Avian Dis.*, **11**, 354–365
- 18) OGATA, K., KITAGAWA, H. & KUDO, N. (1981) : Formation of two types of germinal centers during immune response in chicken spleen *Jpn. J. Vet. Sci.*, **43**, 645–657
- 19) PURCELL, D. A., THAM, V. L. & SURMAN, P. G. (1972) : The histopathology of infectious bronchitis in fowls infected with a nephrotoxic "T" strain of virus *Aust. Vet. J.*, **52**, 85–91
- 20) SAHU, R. N. & RAO, A. T. (1973) : Glomerulonephritis in fowls *Indian Poult. Gazette*, **57**, 44–46

- 21) SEVOIAN, M., SNOEYENBOS, G. H., BASCH, H. I. & REYNOLDS, I. M. (1958) : Infectious synovitis I. Clinical and pathological manifestations *Avian Dis.*, **2**, 499-513
- 22) SILLER, W. G. (1959) : The pathology of avian glomerulonephritis *J. Pathol. Bacteriol.*, **78**, 57-65
- 23) SILLER, W. G. & CUMMING, R. B. (1974) : The histopathology of an interstitial nephritis in the fowl produced experimentally with infectious bronchitis virus *J. Pathol.*, **114**, 163-173
- 24) SILLER, W. G. (1981) : Renal pathology of the fowl-A review *Avian Pathol.*, **10**, 187-262
- 25) SIMPSON, C. F., PRITCHARD, W. R. & HARMS, R. H. (1959) : Endotheliosis in chickens and turkeys caused by unidentified dietary factor *J. Am. Vet. Med. Assoc.*, **134**, 410-416

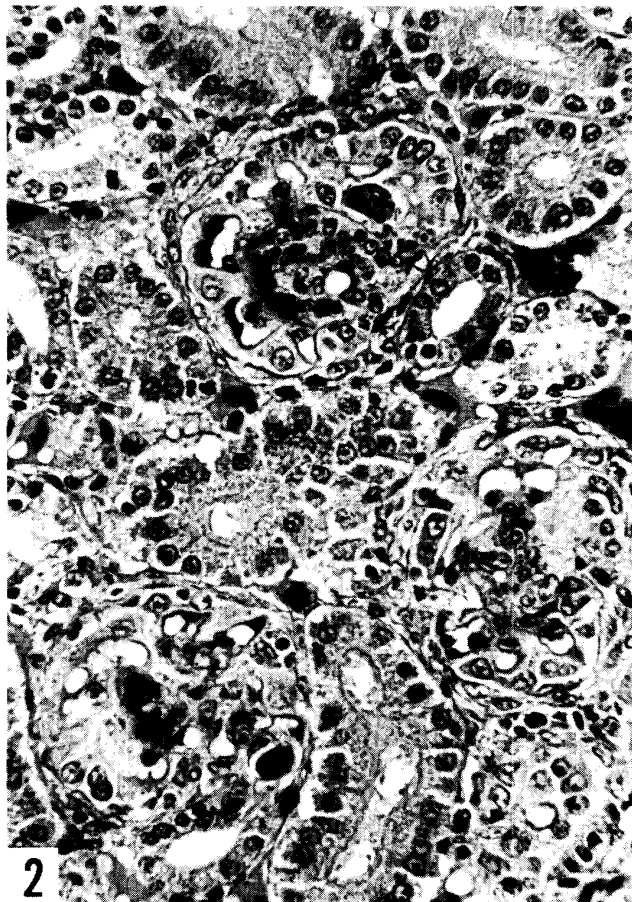
## EXPLANATION OF PLATES

## PLATE I

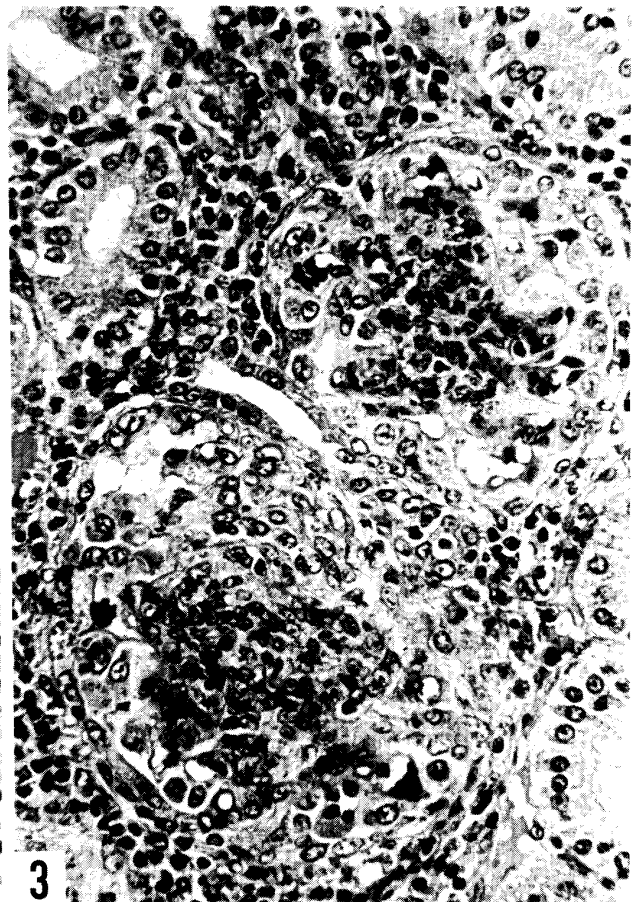
- Fig. 1 Macroscopic feature of kidney lesion of chicken affected with glomerulonephritis showing paleness, enlargement and granular appearance of the surface of the parenchyma. Underdevelopment of the gonads is also seen.
- Fig. 2 Glomerular changes in the initial stage of the proliferative glomerulonephritis showing swelling of endothelial- and epithelial cells of the tufts and marked hyaline droplets deposition in the cytoplasm or the foot processes of the visceral epithelium. H-E  $\times 450$
- Fig. 3 Glomerular changes in the proliferative glomerulonephritis showing marked proliferation of endothelial, epithelial and mesangial cells in the tufts. Hyaline droplet degeneration of the visceral epithelium is relatively mild. H-E  $\times 450$



1



2



3

PLATE II

- Fig. 4 Low power view of the renal lesions in the initial stage of the proliferative glomerulonephritis showing numerous formations of germinal centers of various sizes and hyperplasia of the lymphoreticular and plasma cells in the interstitium of the cortices. H-E  $\times 58$
- Fig. 5 High power view of the renal lesions in the initial stage of proliferative glomerulonephritis showing severe hyperplasia of lymphoreticular and plasma cells and formation of germinal centers in the interstitium of the cortices. H-E  $\times 450$
- Fig. 6 Glomerular changes in the proliferative glomerulonephritis with crescent showing enlargement of the glomeruli and marked proliferation of the epithelial cells in the Bowman's capsule. Hyaline droplet degeneration of the visceral epithelium is mild. H-E  $\times 450$
- Fig. 7 Hepatic lesions showing enlarged endothelial cells of the sinusoidal capillaries (arrows). H-E  $\times 58$

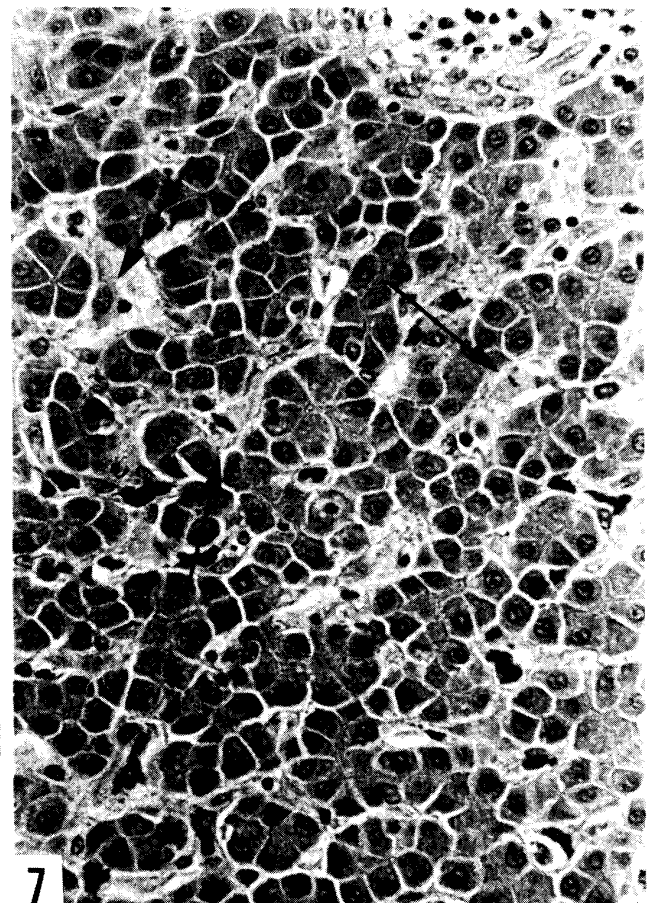
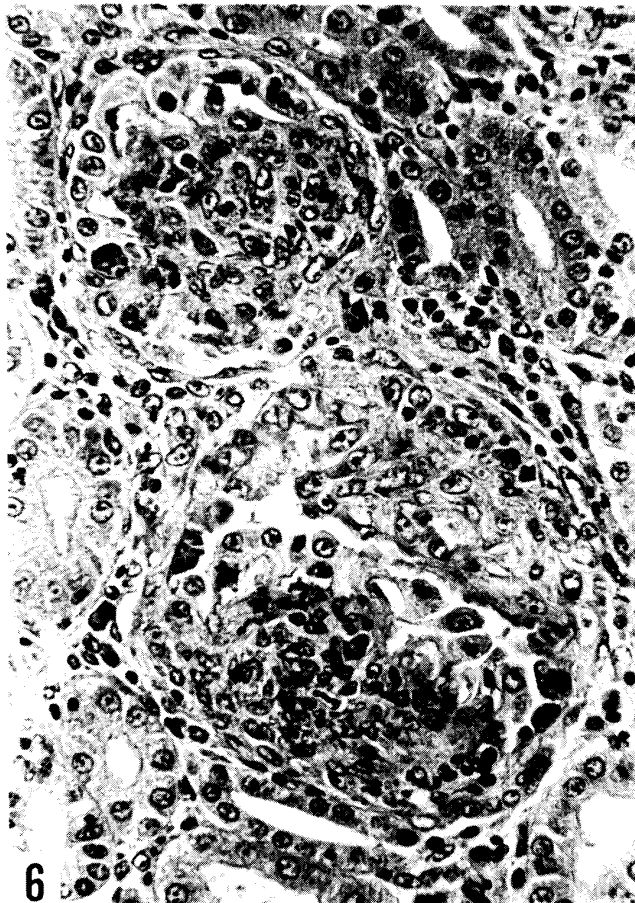
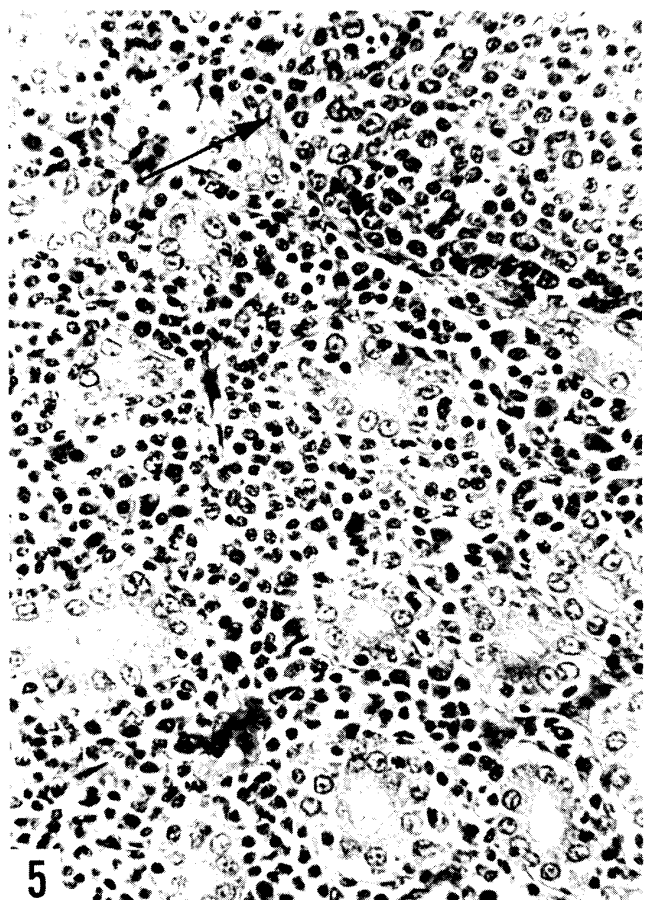
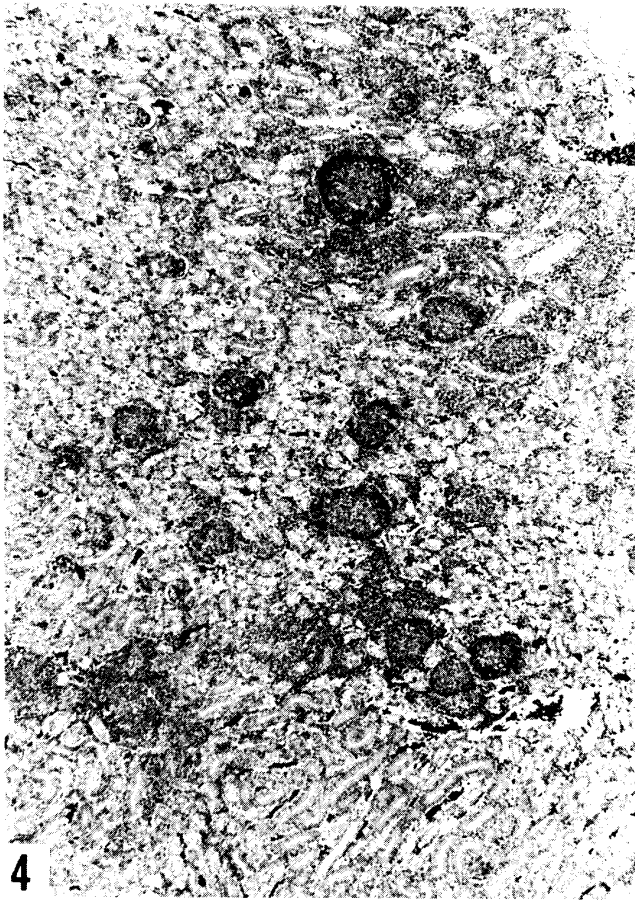
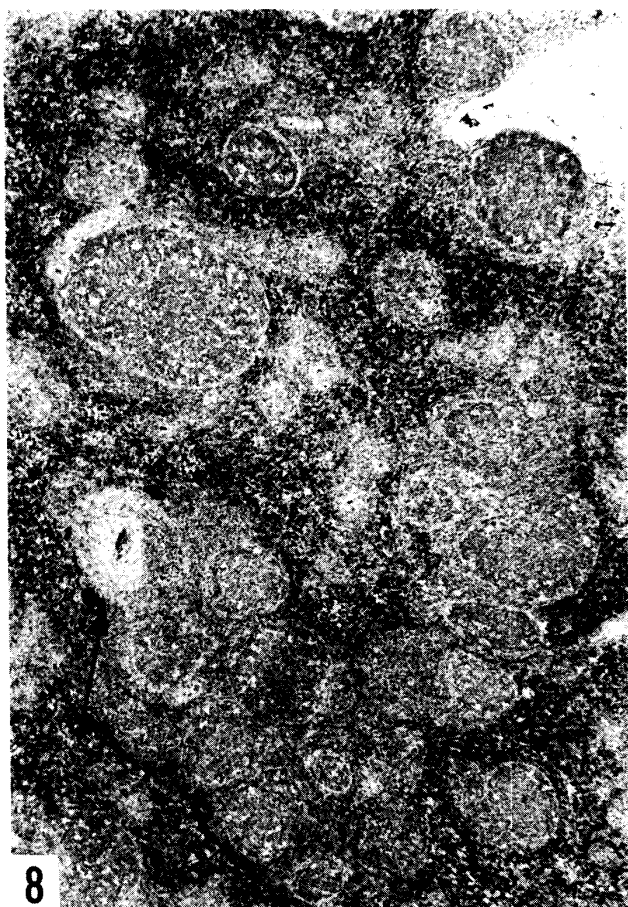
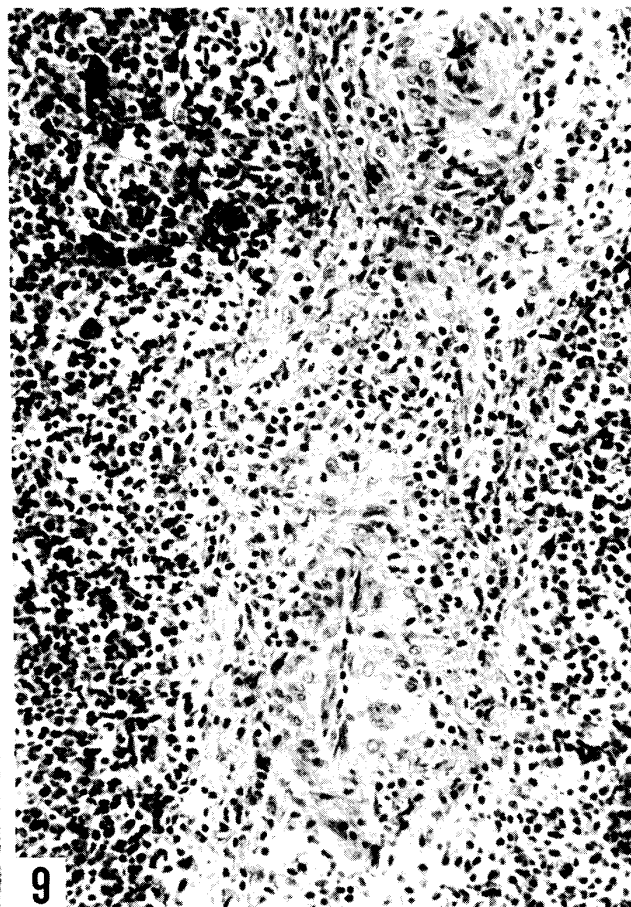


PLATE III

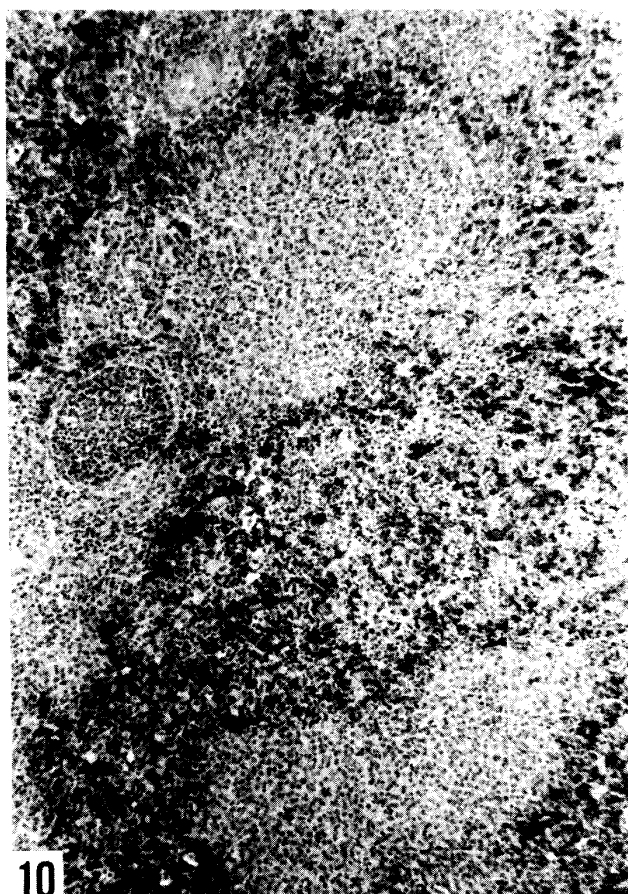
- Fig. 8 Splenic lesions showing hyperplasia of the periarterial lymphoid sheath and vascular change (arrow). Germinal center formations of various sizes are extremely severe. H-E  $\times 58$
- Fig. 9 Vascular lesions in the spleen showing edema of the wall, adventitial cell proliferation with some edema and lymphoid cell infiltration and hyaline droplets deposition in the media and adventitia. H-E  $\times 230$
- Fig. 10 Splenic lesions showing marked proliferation of reticulum cells around sheathed arteries. Periarterial lymphoid sheath is depressed. H-E  $\times 70$
- Fig. 11 Cardiac lesions showing hyperplasia of lymphoreticular cells and plasma cells and germinal center formation in the endocardium and myocardium. H-E  $\times 142$



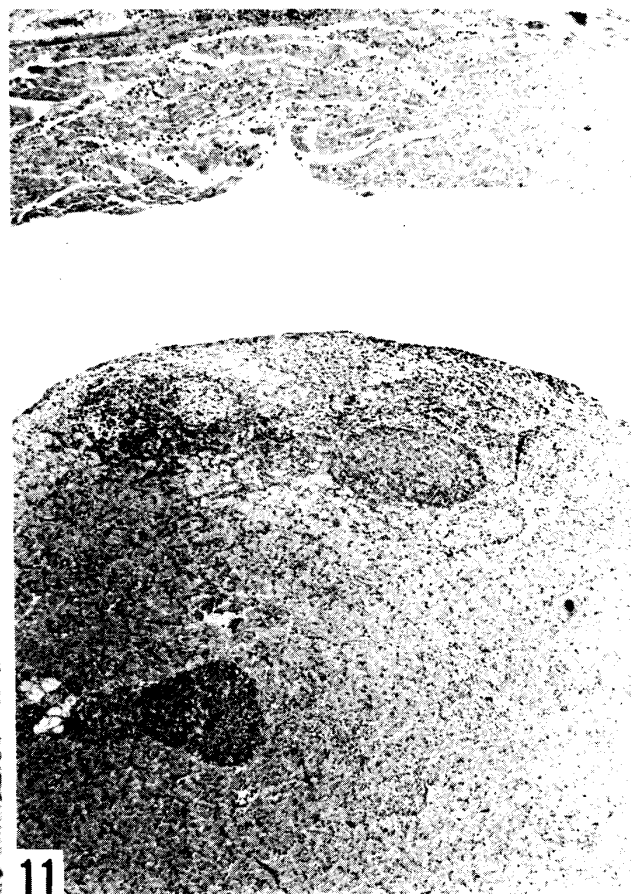
8



9



10



11

PLATE IV

- Fig. 12 Low power view(a) and high power view(b) of the cardiac (a and b) lesions showing prominent hyperplasia of lymphoreticular cells mixed with a number of lymphoblasts and mitotic figures in the myocardium. Plasma cells including plasmablasts, germinal centers (large arrow) or localized foci (small arrows) reminiscent of germinal center are observed within or adjacent to the sites of lymphoreticular cell proliferation. H-E (a)  $\times 58$  (b)  $\times 450$
- Fig. 13 Proventricular lesions showing hyperplasia of lymphoreticular and plasma cells in the lamina propria and numerous formation of germinal centers in the deeper layers of the mucosa. H-E  $\times 70$
- Fig. 14 Thymic lesions showing germinal center formation and plasma cellular hyperplasia in the medulla. H-E  $\times 142$

