



# HOKKAIDO UNIVERSITY

Title	THE EFFECTS OF HYPOPHYSECTOMY ON THE OVARY OF THE GOLDFISH, CARASSIUS AURATUS
Author(s)	YAMAZAKI, Fumio
Citation	北海道大學水産學部研究彙報, 12(3), 167-180
Issue Date	1961-11
Doc URL	<a href="https://hdl.handle.net/2115/23135">https://hdl.handle.net/2115/23135</a>
Type	departmental bulletin paper
File Information	12(3)_P167-180.pdf



# THE EFFECTS OF HYPOPHYSECTOMY ON THE OVARY OF THE GOLDFISH, *CARASSIUS AURATUS*

Fumio YAMAZAKI

*Faculty of Fisheries, Hokkaido University*

## Introduction

It is known with certainty that the pituitary of teleosts secretes gonadotrophic materials and that it plays very important roles in the reproduction of fishes. This fact was demonstrated by injection, implantation and ablation experiments, further by morphological changes of pituitaries correlated with annual breeding.

In the investigations of the functions of secretory glands, it is very important to examine the changes of target organs after the removal of the glands. Hypophysectomy itself has been carried out in many kinds of fishes for the purpose of studies on the pituitary function. Matthews (1933), Osborn (1941), Fries (1943) and others approached the problems of the chromatophore-control of fish pituitary by means of hypophysectomy.

Making use of the same method, Matthews (1939), Burger (1941) and Pickford (1953) studied the functions of the pituitary responsible for spermatogenesis in *Fundulus*. Vivien (1938, 1941) has also made the same studies using gobiid fish as material. All the findings agree to show that the removal of the pituitary in the male fish results in the regression of testes and that spermatogenesis is inhibited.

On the other hand, the effects of hypophysectomy on ovaries have been studied by only a few researchers such as Vivien (1939, 1941) resulting in finding that all large oocytes undergo atresia while small ones remain unchanged.

The aim of the present study is to find the most suitable method for the removal of the pituitary and further to examine the pituitary factors affecting the ovary in the goldfish, *Carassius auratus*.

Before going further, the writer wishes to express his sincere thanks to Professor Kiichiro Yamamoto of the Faculty of Fisheries, Hokkaido University, for his kind guidance and encouragement in the course of the present study and for his help in improvement of the manuscript. Thanks are likewise offered to Assistant Professor Tatsuro Kubo and Mr. K. Takano for much help in the course of the present study. The writer is indebted to Mr. K. Iino for his assistance in preparing various instruments.

### Material and Methods

Materials used in the present study were the goldfish, *Carassius auratus*. They were cultured in a large outdoor pond until needed. The fish which were utilized were 6.2 to 15.5 cm in body length as measured from the tip of the snout to the base of the tail. In 1959 one hundred and three fish were operated on for the determination of the most suitable method and in 1960 twenty-six females completely hypophysectomized were obtained by the method of opercular approach. Operated fish were kept in wooden aquaria of 70×107×30 cm and small outdoor ponds of 160×130×45 cm in size. They were fed with earth worms. The water of these wooden aquaria and ponds was changed with dechlorinated tap water. At fixation, records were made of body length, body weight and gonad weight in all controls and operated fish. The gonads were preserved for histological study with Bouin's solution and the heads were fixed in Bouin's solution to examine by means of dissecting and sectioning whether they were completely or incompletely hypophysectomized.

Sectioning was performed by the usual paraffin method. The ovaries were cut at 10 microns and stained with Delafield's hematoxylin-eosin, Heidenhain's iron hematoxylin-light green and Heidenhain's azan modification of Mallory's triple stain (Dawson & Friedgood, 1938). The pituitary regions were also cut at 10 microns; they were stained by the method of Dawson and Friedgood (1938). This method gave satisfactory results for identification of gross component of the pituitary.

### Technique of Hypophysectomy

In the present study the gular and the opercular approaches were used as the methods of hypophysectomy. The two methods were compared to determine which was better.

#### 1. *The gular approach to the pituitary*

This method has been employed by Matthews (1933, 1939) in the killifish, *Fundulus heteroclitus*, Parker (1934) in the catfish, *Ameiurus nebulosus* and Chavin (1956) in the goldfish, *Carassius auratus*. However, detailed points in the procedures are different as practised by different operators.

The procedures in this experiment were as follows:

The goldfish was anaesthetized by cooling with cold water for more than 15 minutes, the water temperature was about 2°C in February, 6.5°C in August and

3°C in November. After anaesthesia the animal was placed upside down in the groove of the operation board which had a drainage hole, wrapped with wet cloth coated with absorbent cotton, and fixed to the board with an elastic band. During the operation the low temperature was maintained by placing cracked ice around the animal.

For lighting, a 100-watt electric lamp was used. The light was concentrated and cooled by filtering through a round flask which contained cupric ammonium solution. To light the operating place, an oculist's reflector was used. Then the gular membrane of the left side was cut with a scalpel from the lower lip along the tongue. This incision was kept open about 5-8 mm by means of pins attached to a rubber band from both sides. After exposure of the oral cavity, a 3 mm square portion of mucous membrane of the roof of the mouth was cut with a pair of small manicure scissors and carefully removed from the roof by means of modified dental forceps. Then the parasphenoid bone was rendered visible in the opening. At the median portion of the parasphenoid bone, there are two small processes at which the bone bends towards the vomer. The bone was punctured at this portion about 1.5 mm in depth with a trepan of 1.5 or 2 mm diameter. The flowing blood was washed out with cooled Ringer's solution. Through this opening the presence of the pituitary was recognizable, because of its milky colour. The pituitary gland was sucked out with a fine pipette connected to an inspirator. The removed mucous membrane was replaced over the aperture, and the wound was closed with one suture. The operated animal was placed in 0.2 per cent cooled saline water (4°C~6°C) composed of equal parts of sodium chloride and calcium chloride for 24 hours following the procedure of Chavin (1956). The temperature of the water was gradually raised to room temperature. Then the fish was placed in dechlorinated tap water for 2-5 days. The water was changed every day. During this period the suture was taken off and the operated animal was transferred to a wooden aquarium.

## 2. *The opercular approach to the pituitary*

For this operation, an operating board was designed, which had a shallow groove and a pole to hold rubber bands connected with hooked pins. The fish were anaesthetized by cooling as in the previous method. After anaesthesia they were placed sideways on the operating board and fixed to the board in the same way as in the gular approach. The low temperature was maintained by placing chipped ice near the fish.

The operculum and first gill arch were pulled forward by the hooked pins connected with rubber bands to expose the roof of the mouth. Through this

opening an incision was made with Lapersonn's dissection knife. In this way the prootic bone became visible and under bright light the pituitary gland also could be seen through the bone. The place of incision was washed and cleaned with Ringer's solution. The prootic bone was drilled with a dental burr No. 3, 4, or 5 according to the size of the animals. The pituitary, thus exposed, was sucked out with a pipette. The operated fish were placed for 24 hours in cooled saline water, whose temperature was about 5~8°C at the time when the fish were immersed. The temperature of this cooled saline water was gradually raised to room temperature. The animals were removed to dechlorinated running tap water and kept in it for 2-7 days until they had recovered. Then they were transferred to a wooden aquarium.

### Results

#### (1) Comparison between the gular and the opercular approach methods of hypophysectomy

One hundred and three fish were operated on, 51 of them by the gular approach and the others by the opercular approach. In the case of the gular approach, the parasphenoid bone is comparatively thick so that it is not easy to find the pituitary through the small drilled aperture. Accordingly more than 15 minutes were required for the operation. With the opercular approach, on the contrary, the prootic bone is thin and the pituitary is easily visible through it. Therefore the operation can be finished in 5-6 minutes. The results obtained from these two methods are summarized in Table 1.

Table 1. Results obtained from the gular and the opercular approach methods in present hypophysectomies

Method	No. of operated fish	Fish died within one week		Incomplete H. sectomy		Complete H. sectomy	
		No. of fish	%	No. of fish	%	No. of fish	%
Gular approach	51	26	51.0	18	35.3	7	13.7
Opercular approach	52	9	17.3	17	32.7	26	50.0

In the gular approach 51 per cent of the fish operated on died within one week after operation, while only 17.3 per cent of the fish died as the result of the opercular approach during the same period. The number of fish incompletely hypophysectomized was almost equal under the two methods. From the results it is reasonably concluded that the opercular approach is more suitable than the

gular approach for the removal of the pituitary in the goldfish.

(2) *The effects of "mock operations" of the pituitary on the reproductive system*

The pituitary is located below the floor of the brain tissue and is surrounded by many nerves. In order to ascertain the influence of hypophysectomy, therefore, an examination of the effects of a "mock operation" on the reproductive organs is indispensable. With this idea in mind, "mock operations" which exposed the pituitary but left it intact were done.

Four fish were operated on by the gular approach on January 12th and 14th 1959 (Table 2). One of them was a female; it spawned in June with a normal male. The other operated males showed normal sexual behaviour in April and May. The gonosomatic index (gonad weight  $\times 100$ /body weight) of the female was 7.5 at the date killed on June 20. Microscopical observations showed no discernible difference between the ovary of this female and those of intact females.

The second experiment was made from April to August by the opercular approach using 18 female fish (Table 2). After the operation, they were cultured until they were killed according to the days recorded in Table 2. All of their gonads were normal (Figs. 1, 2 and 3) except those of 2 fish which showed some regressive features of ovaries (Table 2). Most of the fish had ovaries as large as normal fish in the breeding season (Figs. 2, 3), while a few yielded somewhat smaller ovaries without any sign of regression. From these experiments it was made clear that the "mock operation" had no discernible effect on the gonad.

(3) *General behaviour and colour change in hypophysectomized goldfish*

After being kept in cold saline water the fish operated on usually recovered quickly, whereas those which did not become completely well within about six hours usually died within one week after the operation.

The hypophysectomized goldfish showed normal behaviour in swimming and they fed well. They grouped themselves and responded to outer stimuli the same as non-operated fish. The body colour was the external criterion between the hypophysectomized and non-operated fish. The hypophysectomized goldfish lost their characteristic red colour and become pale or cream white. This change appeared at first on the abdominal side and gradually became visible over the entire animal. The velocity of the change of body colour varied with the season. In the animals operated on in July and August, the change spread over their bodies in about two weeks, while in those operated on in October the change

covered the animals in about two months or more. This time lapse seems closely connected with the water temperature of the aquarium. The mean water temperature of the aquarium was 24.2°C in August and 6.8°C in November.

(4) *Effects of hypophysectomy on the ovary*

Incompletely hypophysectomized fish with some remnants of pituitaries were all disregarded in gathering material for the present paper. Thirty-nine females which were completely hypophysectomized and healthy were obtained from the operation in 1959 and 1960.

I. *Effects on mature and maturing ovaries*

The fish with maturing yolk-laden oocytes are usually found from October to the following July (Yamamoto & Yamazaki 1961). In the present study, therefore, hypophysectomy was performed in two separate periods from April to July and from October to November (Table 2). In the former period, the fish yielded the ovaries of the secondary maturing and of the ripe stages,\* whilst in the latter period they yielded the ovaries of the primary maturing stage\*.

In general, hypophysectomy proved to exert conspicuous effects on mature or maturing ovaries. In the fish operated on in the former period, oocytes in the ovaries suffered atresia with the passing of time. Along with this internal change, the ovaries gradually became soft and decreased in size and weight. The atretic processes did not occur simultaneously in all oocytes. The oocytes in the late yolk vesicle stage, the primary and secondary yolk stages became atretic at first while those in the tertiary yolk stage remained unchanged for some time (Figs. 7, 8, 9 and 10) but finally showed atresia (Fig. 11). Yolk-less oocytes found numerously in the ovaries seemed not to be affected by any atretic change and remained intact during that time (Fig. 11). In the fish kept for a long time after hypophysectomy, therefore, the ovaries became very small, and they contained many oocytes without yolk and a few with yolk vesicles. As will be stated below, however, the velocity of the atretic events was not the same throughout the period, but it differed by months.

The fish operated on in the latter period reacted to the operation in the same way. Oocytes in the ovaries became atretic following the order found in the former, that is, oocytes in the primary yolk stage and the late yolk vesicle stage began to degenerate at first (Figs. 13, 15) and then those of the early yolk vesicle stage (Fig. 14). In the same way as in the former periods, oocytes without

\* Cf. Yamamoto & Yamazaki (1961).

yolks remained intact during that time.

The above data shows that hypophysectomy yields effects on all oocytes laden with yolk, resulting in the induction of atresia, first in lightly yolk-laden oocytes and then in heavily yolk-laden ones, but it induces no atretic changes in yolkless oocytes.

## II. *Histogenesis of maturing oocytes undergoing atresia after hypophysectomy*

Atretic changes in the oocytes of the yolk stages began in their peripheral region where yolk vesicles were melted and sometimes made a colloidal mass (Fig. 7). This colloidal mass was not stained with hematoxylin but stained with Mallory azan stain in blue. Granulosa cells were hypertrophied. The zona radiata was broken into fragments. At the next step, yolk globules were also melted from the peripheral region and they seemed to be gradually absorbed by the granulosa cells. The nucleus of the oocytes disappeared from sight. The granulosa cells of which the nuclei were located near the oolema appeared to invade gradually into the oocytes. The oocytes became weak in stainability and irregular in shape (Figs. 9, 10, 11 and 13).

In the oocytes of the yolk vesicle stage, a characteristic change was frequently observed, that is, one pole of the oocytes was filled with cytoplasm and the other pole with many yolk vesicles. The nucleus of the oocytes was invisible (Fig. 15). Then the yolk vesicles seemed gradually to melt (Fig. 15). There were found some atretic oocytes presenting an appearance like empty follicles, and those which were invaded by many cells (Fig. 16).

From these findings it is clear that the morphological changes of atretic oocytes after hypophysectomy resemble those found in spent ovaries after spawning (Fig. 12, Yamamoto & Yamazaki 1961).

## III. *Seasonal difference in the effects of hypophysectomy*

Seasonal differences are summarized in Table 2. In the table the alphabet is used as the atretic index: A represents ovaries containing zero to five atretic oocytes out of 100 oocytes counted under the microscope; B, 5-15 per 100; C, 15-25 per 100; D, 25-35 per 100; E, more than 35 per 100. All fish operated on in July were kept in an indoor pond at the water temperature of about 14°C, because water temperature in outdoor ponds was so high that the fish were debilitated. In April and May, the atretic change was recognized in the ovaries of the fish cultured more than 3 weeks after the operation and in June it could be

Table 2. Atretic index of hypophysectomized fish and "mock control."  
For explanation see text

"Mock control"				Hypophysectomized fish			
Date of operation	Days lived after operation	Atretic index	B. L. (cm)	Date of operation	Days lived after operation	Atretic index	B. L. (cm)
Jan. 12	101	♂	8.2	Apr. 15	14	A	10.1
Jan. 12	159	A	8.9	Apr. 15	28	B	10.7
Jan. 14	102	♂	9.0	Apr. 15	42	A	10.0
Jan. 14	119	♂	7.3	Apr. 22	21	B	9.4
Apr. 15	14	A	11.5	May 6	7	A	9.1
Apr. 15	28	A	9.0	May 6	14	A	9.3
Apr. 15	42	B	13.5	May 8	14	A	10.3
				May 6	21	B	9.5
May 6	28	A	11.7	May 6	42	D	9.2
May 6	56	A	10.4	May 6	56	E	11.1
				Jun. 6	14	B	10.1
Jun. 6	28	A	9.8	Jun. 6	28	D	11.1
Jun. 6	59	B	10.6	Jun. 6	35	B	10.8
				Jun. 27	7	B	15.5
				Jul. 7	28	C	10.4
				Jul. 7	43	E	10.3
				Jul. 7	44	C	10.5
Jul. 7	70	A	10.7	Jul. 7	70	D	11.0
				Oct. 2	7	A	8.7
Jul. 23	36	A	7.1	Oct. 2	28	A	9.3
Jul. 23	36	A	7.1	Oct. 2	28	B	8.9
Jul. 23	36	A	7.2	Oct. 3	77	A	7.0
Jul. 23	36	A	7.9	Oct. 3	77	A	6.8
Jul. 23	36	A	6.2	Oct. 3	77	B	7.8
Jul. 23	36	A	7.6	Oct. 8	78	C	11.5
Aug. 5	9	A	8.8	Oct. 8	78	A	10.9
Aug. 5	16	A	6.8	Oct. 8	78	B	8.0
				Oct. 8	78	A	7.9
Aug. 5	36	A	9.8	Oct. 8	78	B	9.2
Aug. 2	64	A	7.2	Oct. 15	71	A	7.2
				Oct. 30	49	B	8.3
				Nov. 9	118	C	11.4

detected in the fish kept for 2 weeks after the operation. In the fish operated on in October, however, atretic indexes were A or B even after 11 weeks.

From the results of observation it is clear that hypophysectomy more quickly effected the ovaries of fish operated on in June and July than in October and November. This difference in month seems intimately connected with both the state of oocytes and the water temperature.

#### IV. Effects on immature and recovering ovaries

An immature fish was hypophysectomized in July of 1959 and kept for 26 days thereafter. She showed a marked difference from the control. In the former most oocytes in the ovary were yolk-less, while in the latter many oocytes

were laden with yolk vesicles. This suggests that hypophysectomy inhibits the formation of yolk in oocytes.

In order to test this supposition, a second series of experiments was carried out September 3 and 9 1960. By September the goldfish in our laboratory had almost completely absorbed the atretic oocytes corresponding to those above the yolk vesicle stage, so that the ovaries of all fish were ranked in the "recovering stage".

Table 3. Gonad weight of hypophysectomized immature fish and the controls

	Fish No.	Date of operation	Date killed	Days lived after operation	B. L. (cm)	Gonad weight
Hypophysectomy	1	Sep. 3	Sep. 30	27	7.8	0.3
	2	Sep. 3	Sep. 30	27	7.8	0.3
	3	Sep. 3	Sep. 30	27	7.8	0.4
	4	Sep. 9	Oct. 14	35	6.8	0.3
	5	Sep. 9	Oct. 28	49	8.5	0.2
	6	Sep. 9	Dec. 16	98	10.2	1.1
	7	Sep. 9	Dec. 16	98	6.7	0.1
"Mock" control	1	Sep. 9	Oct. 14	35	9.0	0.8
	2	Sep. 9	Oct. 28	49	9.3	0.7
Intact control	1		Sep. 13		7.8	0.3
	2		Oct. 2		8.8	0.6
	3		Oct. 27		8.9	0.8
	4		Oct. 27		9.0	1.7
	5		Dec. 26		9.4	3.4

Table 4. Percentage of atretic and normal oocytes found in the ovaries of the fish shown in Table 3

	Fish No.	No. of examined oocytes	Percentage of atretic and normal oocytes at each stage							
			Atretic oocytes	Peri-nucleolus stage		Yolk vesicle stage		Yolk stage		
				Early	Late	Early	Late	Primary	Secondary	Tertiary
Hypophysectomy	1	836	2.2	68.7	22.6	6.5				
	2	754	5.9	80.5	13.6					
	3	578	25.4	64.8	9.8					
	4	643	6.2	76.1	17.7					
	5	762	0.3	82.3	16.4	1.0				
	6	848	18.9	73.6	7.5					
	7	804	0	88.9	10.9	0.2				
"Mock" control	1	811	6.4	49.4	26.8	7.9	9.5			
	2	951	0.2	48.8	24.5	16.8	9.7			
Intact control	1	811	0.2	70.0	25.1	4.7				
	2	1011	0.2	72.0	19.0	6.9	1.9			
	3	805	0	62.1	17.1	10.1	10.7			
	4	660	0.2	38.4	22.1	18.6	13.5	5.8	1.0	0.4
	5	422	0	50.8	17.5	9.7	9.7	6.6	3.3	2.4

On September 13, one intact fish was sacrificed as the initial control. The control contained 4.7 per cent oocytes of the early yolk vesicle stage and 95.1 per cent oocytes of yolk-less stage (Table 4, Fig. 17). Members of this intact control group gained in ovary weight with the passage of time (Table 3), along with the appearance of many oocytes in the yolk vesicle and the yolk stages (Table 4, Figs. 18, 19 and 20).

Two fish were subjected to "mock operation" on September 9 and sacrificed 35 and 49 days later (Table 3). In the ovaries of these two fish many oocytes in the yolk vesicle stage were found (Table 4, Fig. 19).

Compared with the controls, all hypophysectomized fish showed no increase in gonad weight (Table 3) and embraced only a few oocytes laden with yolk vesicles (Table 4, Figs. 16, 21, 22, 23 and 24). Moreover, they contained less oocytes in the late peri-nucleolus stage than mock and intact control fish (Table 4).

From these results it seems reasonable to say that hypophysectomy in goldfish depresses the growth of ovaries due to the failure of yolk formation in oocytes.

#### Discussion

Hypophysectomy has been carried out in many kinds of fishes. The methods may be grouped as follows:

1. Orbital approach (Smith, Burr & Ferguson, 1935)
2. Oral approach (Waring, 1940; Vivien, 1941; Osborn, 1941; Tavolga, 1955)
3. Gular approach (Matthews, 1933, 1939; Parker, 1934; Chavin, 1956)
4. Opercular approach (Abramowitz, 1937; Burger, 1941; Fries, 1943; Pickford, 1953; Burden, 1956)

The orbital approach designed by Smith, Burr & Ferguson (1935) has many technical difficulties, and so far it has given unfruitful results. The oral approach used by Waring (1940) on eel, by Osborn (1941) on catfish and by Vivien (1941) on gobiid fish seems unsuitable for goldfish, because the mouth of the goldfish is far too small as compared with that of the above fishes. The gular approach was used by Matthews (1939) in *Fundulus*, but he stated that the mortality was usually high. But Chavin (1956) removed the pituitary of small immature goldfish of 1-2 inch body length by means of the gular approach. He reported that the time necessary for the operation was 4-5 minutes and that the mortality after operation was less than 10 per cent. In the present experiment the gular approach was tried but resulted in only 13.7 per cent success.

On the other hand, the opercular approach recommended by Abramowitz (1937) and by Pickford & Atz (1957) was successful in 50.0 per cent of the present writer's 1959 trials. In 1960 better results were gained by this method. From these facts

the opercular approach seems most suitable for the removal of the pituitary in goldfish.

Anaesthesia by cooling with cold water as used by Parker (1934) and Abramowitz (1937) gave good results and was improved in the application by the addition of a small per cent of ethyl urethane (about 0.05%).

The present studies made clear that the water temperature necessary for the anaesthesia of the goldfish was about 6.5°C in summer and 2°C in autumn and winter. This seasonal change of resistance to the lower temperature in goldfish was elucidated by Hoar (1955).

"Mock operation" in the pituitary did not induce changes in body colour nor any effect on oogenesis. Therefore it is reasonable to judge that changes of body colour and regression of gonads induced by hypophysectomy are attributable to the lack of the pituitary.

The relationship between the pituitary and body colour in the goldfish has already been ascertained by Chavin (1956). He observed that after hypophysectomy the body colour of the goldfish was changed to pale or cream white and asserted that pituitary must be necessary for the maintenance of lipophores in goldfish. The results obtained in the present studies agree well with Chavin's observation viz., the hypophysectomized goldfish lose their characteristic red colour and become pale. Further, this colour change proved to be closely connected with the water temperature.

In mature or maturing ovaries, yolk-laden oocytes showed decisive effects of hypophysectomy. In the fish operated on in May, all oocytes with yolk were degenerated within six weeks after the operation except some oocytes in the tertiary yolk stage; eight weeks later those in the tertiary yolk stage had also become atretic, while no atretic change was detected in oocytes without yolks and they remained almost intact during the whole time. On the other hand, in the fish with immature or recovering ovaries, which were hypophysectomized in September, no oocytes grew beyond the late peri-nucleolus stage; they remained below 0.16 mm in diameter. These findings fit in with those of Vivien (1939, 1941) that larger oocytes degenerated and small ones failed to grow beyond about 60 microns in diameter. In mammals it is recognized that the follicle-stimulating hormone of the anterior pituitary affects the growing ovarian follicles after a critical stage, corresponding to the start of antrum formation (Bullough 1951, Simpson 1959). From the present study it is reasonable to say that the pituitary of goldfish stimulates yolk-less oocytes to grow into ripe eggs. Therefore, it may be reasonable to divide the growth of the oocyte into two phases, viz., the first in which there is no concern with the influence of pituitary hormones and

the second phase which is promoted by the presence of the pituitary gland. This is in accord with the views of Bullough (1951) and Ball (1960).

The sensitivity in oocytes to the lack of pituitary secretion was different in different stages. The oocytes in the late yolk vesicle stage and in the primary and the secondary yolk stages, were the highest in sensitivity whilst those in the tertiary yolk stage and the early yolk vesicle stage were the next. The formation of atresia found in the present study seems to be identical with the spontaneous atresia of yolk-laden oocytes which occurred in spent ovaries of this species (Beach 1959, Yamamoto & Yamazaki 1961). But the difference between the two cases lies in the velocity of this process. The degeneration and absorption of atretic oocytes in spent ovaries seems to proceed faster than in the ovaries of hypophysectomized fish. The effects of hypophysectomy differed with the season. The change proceeded more slowly in October and November than in June and July. This may be attributed to the differences of yolk deposition in oocytes and of temperature in the culture water.

#### Summary

1. The effects of hypophysectomy on the ovary of the goldfish have been studied.
2. The pituitary was removed by the opercular approach and the gular approach. The former was better than the latter.
3. "Mock operation" of the pituitary resulted in no effect upon the reproductive organs.
4. Change of body colour occurred in hypophysectomized fish.
5. Hypophysectomy affected yolk formation in oocytes. Those already laden with yolks tended to be deformed and became atretic, while yolk-less oocytes remained as they were intact without the formation of yolks.
6. The growth of oocytes may be divided into two phases, the first which is not concerned with pituitary hormones and the second promoted by the presence of pituitary secretion. The critical stage of the two phases is the early yolk vesicle stage.
7. Atretic changes after hypophysectomy were histologically like those of spontaneous atresia in spent ovaries.
8. The effects of hypophysectomy on the ovary varied according to season.

#### References

- Abramowitz, A.A. (1937). The opercular approach to the pituitary. *Science* 85, 609.  
Ball, J.N. (1960). Reproduction in female bony fishes. *Symp. zool. Soc. Lond.* (1), 105-135.

- Beach, A.W. (1959). Seasonal changes in the cytology of the ovary and of the pituitary gland of the goldfish. *Can. J. Zool.* 37, 615-625.
- Bullough, W.S. (1951). *Vertebrate sexual cycles*. 117 p. London; Methuen.
- Burden, C.E. (1956). The failure of hypophysectomized *Fundulus heteroclitus* to survive in fresh water. *Biol. Bull.* 110, 8-28.
- Burger, J.W. (1941). Some experiments on the effects of hypophysectomy and pituitary implantations on the male *Fundulus heteroclitus*. *Biol. Bull.* 80, 31-36.
- Chavin, W. (1956). Pituitary-adrenal control of melanization in xanthic goldfish, *Carassius auratus* L. *J. Exp. Zool.* 133, 1-45.
- Dawson, A.B. & H.B. Friedgood. (1938). The differentiation of two classes of acidophiles in the anterior pituitary of the female rabbit and cat. *Stain Technology* 13, 17-21.
- Fries, E.F.B. (1943). Pituitary and nervous control of pigmentary effectors, especially xanthophores, in killifish (*Fundulus*). *Physiol. Zool.* 16, 199-212.
- Hoar, W.S. (1955). Seasonal variations in the resistance of goldfish to temperature. *Trans. Roy. Soc. Can. Ser. 3*, 49: 25-34.
- Matthews, S.A. (1933). Color changes in *Fundulus* after hypophysectomy. *Biol. Bull.* 64, 315-320.
- (1939). The relationship between the pituitary gland and the gonads in *Fundulus*. *Biol. Bull.* 76, 241-250.
- Osborn, C.M. (1941). Studies on the growth of integumentary pigment in the lower vertebrates. II. The role of the hypophysis in melanogenesis in the common catfish (*Ameiurus melas*). *Biol. Bull.* 81, 352-363.
- Parker, G.H. (1934). Color changes in the catfish *Ameiurus* in relation to neurohumors. *J. Exp. Zool.* 69, 199-233.
- Pickford, G.E. (1953). A study of the hypophysectomized male killifish, *Fundulus heteroclitus* (Linn.). *Bull. Bingham Oceanogr. Coll.* 14 (2), 5-41.
- Pickford, G.E. & J.W. Atz. (1957). *The physiology of the pituitary of fishes*. 613 p. New York; New York Zool. Soc.
- Simpson, M.E. (1959). Rôle of anterior pituitary gonadotrophins in reproductive processes. In *Reproduction in domestic animals*, ed. H.H. Cole & P.T. Cupps, 1, 59. New York; Academic Press. (Cited from Ball 1960).
- Smith, G.M., H.S. Burr & R.S. Ferguson. (1935). A study of the effects of intermedin and injury of the hypophysis on traumatic corial melanophores in goldfishes. *Endocrinology* 19, 409-412.
- Tavolga, W.N. (1955). Effects of gonadectomy and hypophysectomy on prespawning behavior in males of the gobiid fish, *Bathygobius soporator*. *Physiol. Zool.* 28, 218-233.
- Vivien, J.H. (1938). Sur les effets de l'hypophysectomie chez un téléostéen marin, *Gobius paganellus* L. *C.R. Acad. Sci., Paris* 207, 1452-1455.
- (1939). Rôle de l'hypophyse dans le déterminisme du cycle génital femelle d'un téléostéen, *Gobius paganellus* L. *C.R. Acad. Sci., Paris* 208, 948-949.

- Vivien, J.H. (1941). Contribution à l'étude de la physiologie hypophysaire dans ses relations avec l'appareil génital, la thyroïde et les corps suprarénaux chez les poissons sélaciens et téléostéens. *Bull. biol. Fr. Belg.* 75, 257-309. (Cited from Pickford & Atz 1957).
- Waring, H. (1940). The chromatic behaviour of the eel (*Anguilla vulgaris* L.). *Proc. Roy. Soc., B*, 128, 343-353.
- Yamamoto, K. & F. Yamazaki. (1961). Rhythm of development in the oocyte of the goldfish, *Carassius auratus*. *Bull. Fac. Hokkaido Univ.* 12 (2), 93-110.

## Explanation of Plates

All figures are photomicrographs obtained from sections of ovaries of intact, "mock operated" and hypophysectomized goldfish. Fixed in Bouin's fluid and stained with Delafield's hematoxylin-eosin except Figs. 3, 6 and 19.

#### PLATE I

Fig. 1. Portion of the ovary from a fish twenty-eight days after "mock operation." Operated on April 15.  $\times 31$

Fig. 2. Ovarian portion from a "mock operation" fish operated on June 6 and sacrificed twenty-eight days later.  $\times 31$

Fig. 3. The same as above, from a fish sixty-four days after "mock operation." Operated on August 2. Heidenhain's azan modification of Mallory's triple stain.  $\times 31$

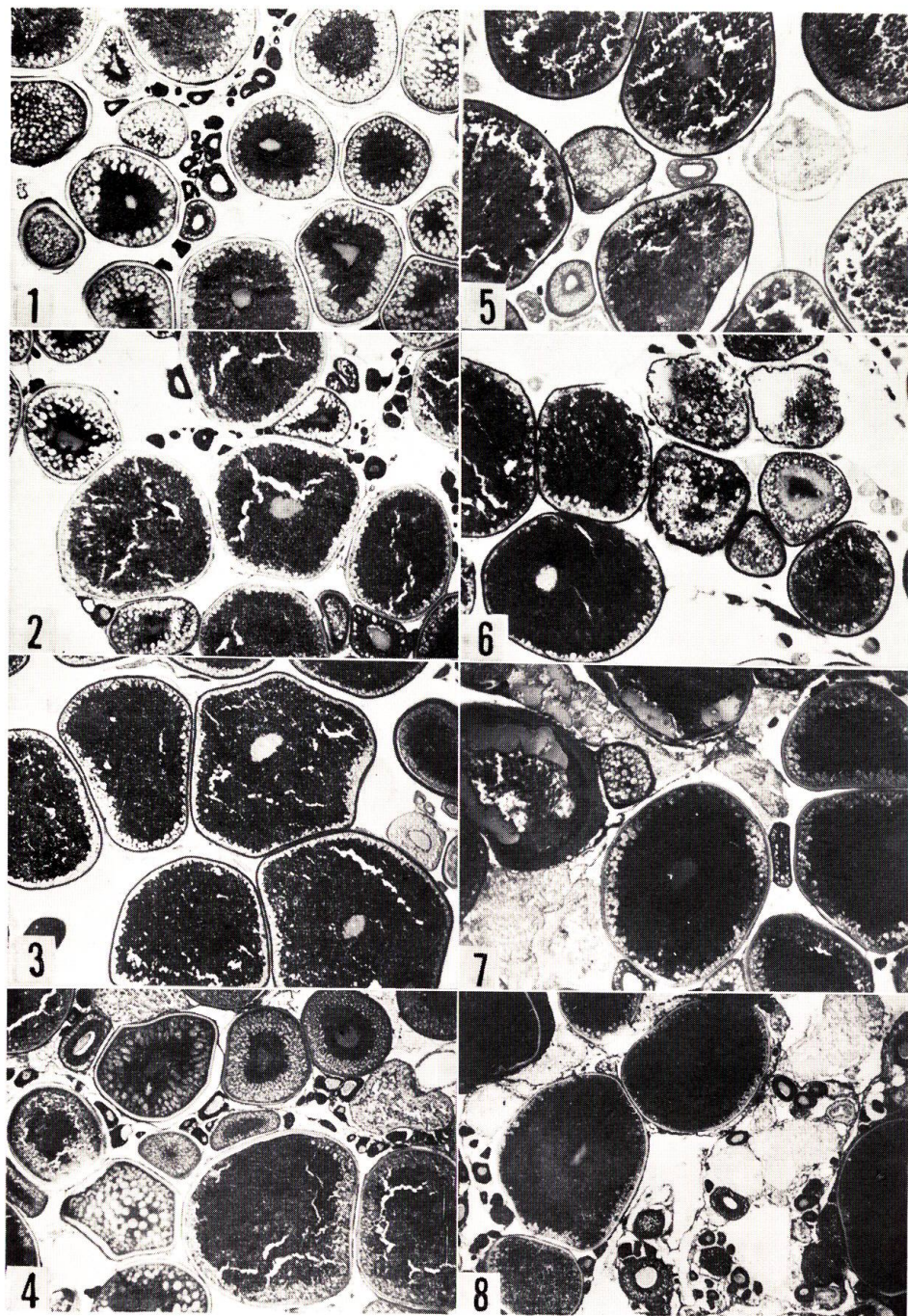
Fig. 4. Portion of the ovary from a fish forty-two days after hypophysectomy. Operated on April 15.  $\times 31$

Fig. 5. Ovarian portion from a fish hypophysectomized on June 6 and killed fourteen days later.  $\times 31$

Fig. 6. The same as above, from a fish seven days after hypophysectomy. Operated on June 27. Heidenhain's azan modification of Mallory's triple stain.  $\times 29$

Fig. 7. The same from a fish forty-two days after hypophysectomy. Operated on May 6.  $\times 31$

Fig. 8. The same from a fish forty-four days after hypophysectomy. Operated on July 7.  $\times 29$



F. YAMAZAKI: The effects of hypophysectomy on the ovary

## PLATE II

Figs. 9, 10. Portions of the ovary from a fish hypophysectomized on June 6 and killed twenty-eight days later. Many atretic oocytes are visible together with healthy oocytes in the tertiary yolk stage and yolk-less stage.  $\times 31$

Fig. 11. Ovarian portion from a fish fifty-six days after hypophysectomy. Operated on May 6. Almost all oocytes laden with yolk are atretic but yolk-less oocytes remained unaffected.  $\times 34$

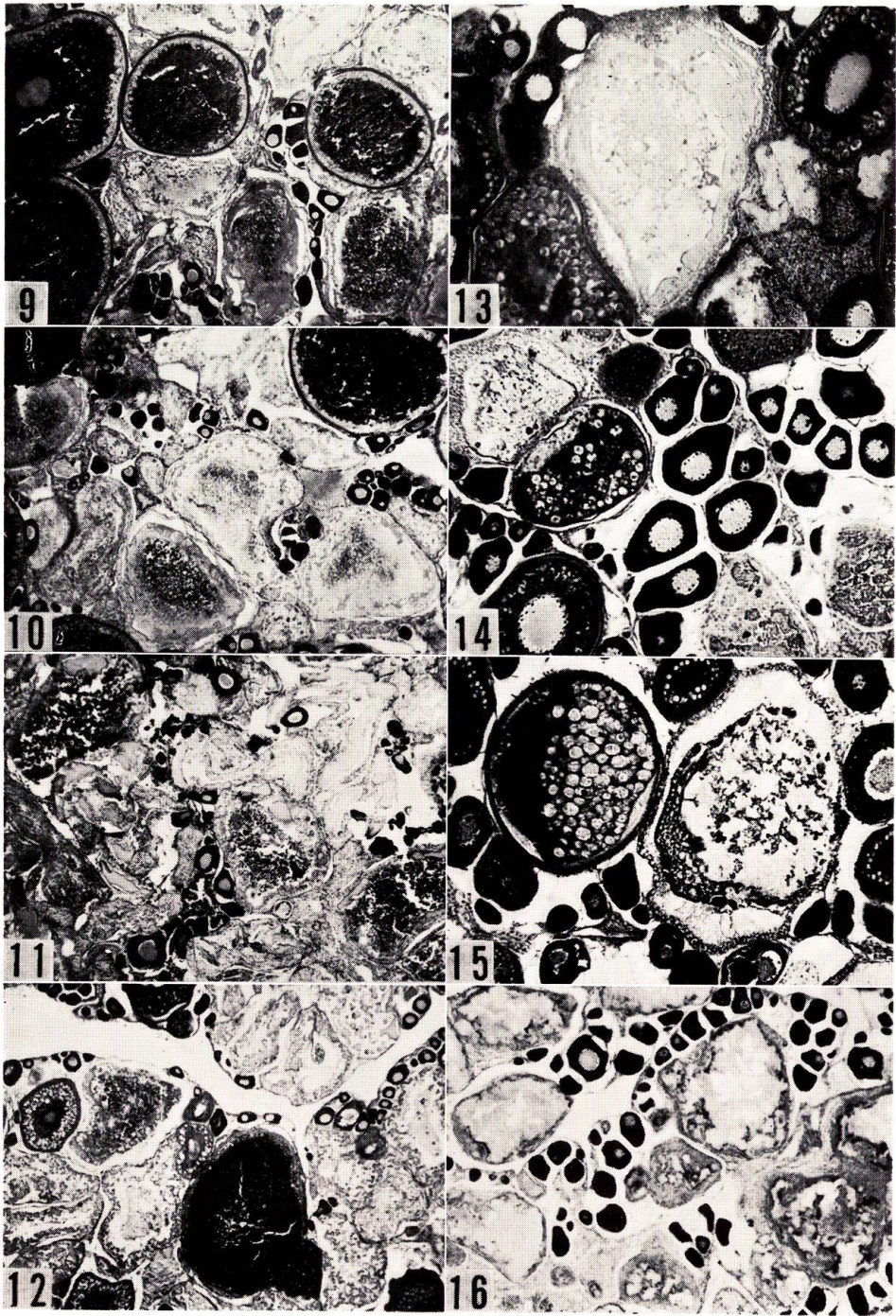
Fig. 12. Portion of the spent ovary of a fish sacrificed on July 18 showing spontaneous atresia.  $\times 31$

Fig. 13. Portion of the ovary from a fish twenty-eight days after hypophysectomy. Operated on October 2.  $\times 85$

Fig. 14. The same as above, from a fish hypophysectomized on October 8 and kept for seventy-eight days.  $\times 77$

Fig. 15. Ovarian portion of a fish one hundred and eighteen days after hypophysectomy. Operated on November 3.  $\times 77$

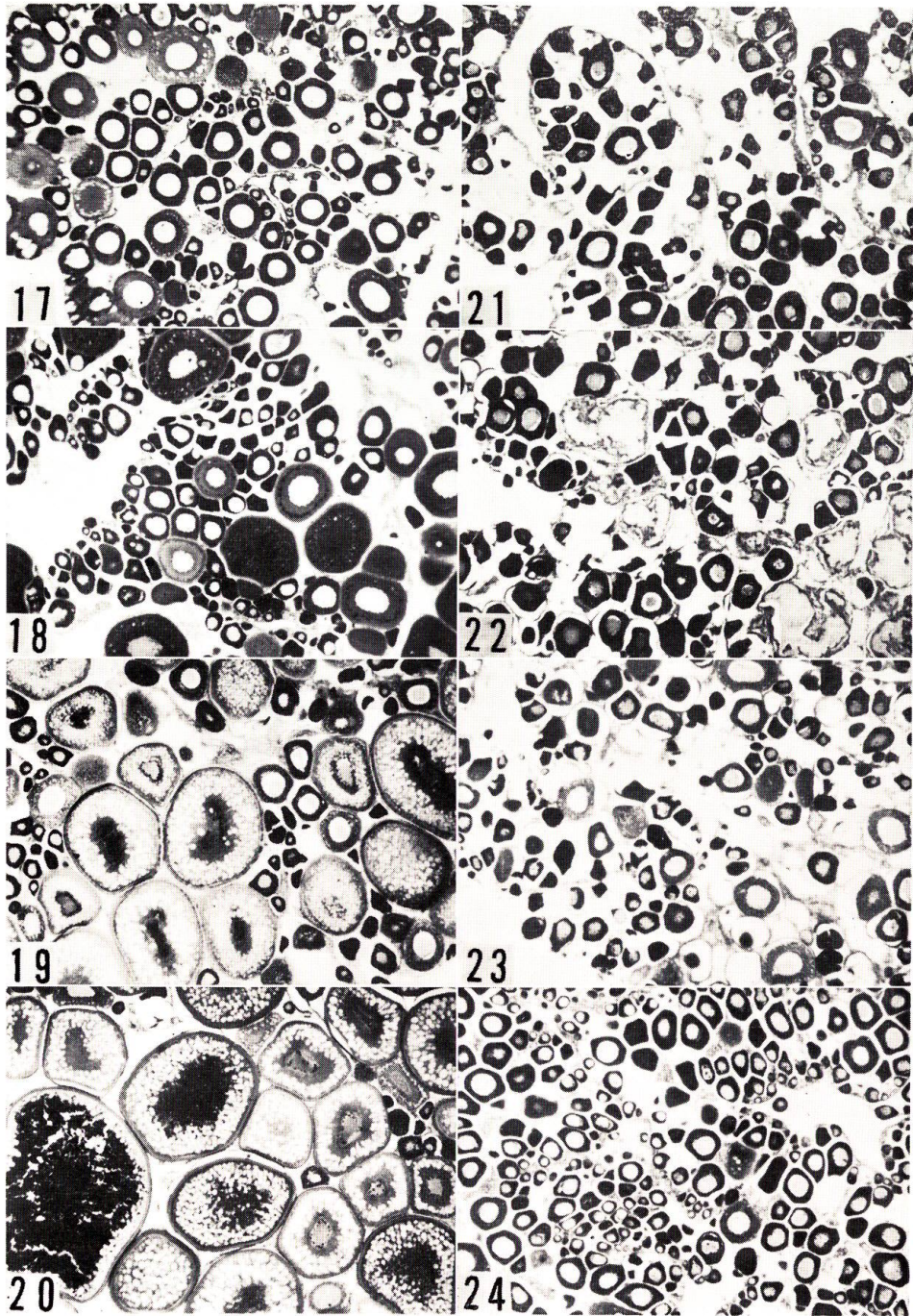
Fig. 16. Ovarian portion of a fish ninety-eight days after hypophysectomy. Operated on September 9. Only yolk-less oocytes remained intact.  $\times 42$



F. YAMAZAKI: The effects of hypophysectomy on the ovary

### PLATE III

- Fig. 17. Ovarian portion of an intact control killed on September 13.  $\times 42$
- Fig. 18. The same as above, from an intact control killed on October 2.  $\times 42$
- Fig. 19. Ovarian portion of a "mock control" operated on September 9 and killed on October 28 (kept for 49 days). Many oocytes in the late yolk vesicle stage are visible. Heidenhain's iron hematoxylin-light green.  $\times 37$ .
- Fig. 20. Ovarian portion of an intact control killed on October 27. Yolk stage oocytes are visible.  $\times 37$
- Fig. 21. Ovarian portion of a fish twenty-seven days after hypophysectomy. Operated on September 3.  $\times 42$
- Fig. 22. The same as above, from a fish hypophysectomized on September 9 and sacrificed thirty-five days later.  $\times 42$
- Fig. 23. The same as above, from a fish forty-nine days after hypophysectomy. Operated on September 9.  $\times 42$
- Fig. 24. Ovarian portion of a fish hypophysectomized on September 9 and cultured for ninety-eight days. All oocytes remains unchanged without the formation of yolk.  $\times 42$



F. YAMAZAKI: The effects of hypophysectomy on the ovary