



HOKKAIDO UNIVERSITY

Title	A SIMPLE CATHETERIZATION FROM THE EAR VEIN INTO THE JUGULAR VEIN FOR SEQUENTIAL BLOOD SAMPLING FROM UNRESTRAINED PIGS
Author(s)	NIIYAMA, Masayoshi; YONEMICHI, Hiromi; HARADA, Etsumori et al.
Citation	Japanese Journal of Veterinary Research, 33(1-2), 1-9
Issue Date	1985-04-30
DOI	https://doi.org/10.14943/jjvr.33.1-2.1
Doc URL	https://hdl.handle.net/2115/2314
Type	departmental bulletin paper
File Information	KJ00002374275.pdf



A SIMPLE CATHETERIZATION FROM THE EAR VEIN INTO THE JUGULAR VEIN FOR SEQUENTIAL BLOOD SAMPLING FROM UNRESTRAINED PIGS⁶

Masayoshi NIIYAMA¹, Hiromi YONEMICHI⁵, Etsumori HARADA²,
Bunei SYUTO³ and Hiroshi KITAGAWA⁴

(Received for publication November 15, 1984)

A simple catheterization from the ear vein into the jugular vein or anterior vena cava was tried for sequential blood sampling from unrestrained pigs for clinical research on stress. Insertion of the catheter was made from the middle or lateral auricular vein by using a trocar-cannula type needle in standing position with restraint of the snout. Vinyl tubes of various sizes were used as the catheter. The free end of the catheter was plugged and fastened at several site of the auricle, neck and back. Sequential blood samplings were made with an injector adapted to an extension tube. Smooth blood sampling was possible without any restraint in standing position for 3 days in pigs weighing 90 kg.

Key Words : pig, catheterization, ear vein.

INTRODUCTION

Pigs are important animals as meat source, and their performance of meat production has been increasing step by step. At the same time, increase of stress-susceptible pigs has been also pointed out. And many researches are required on several diseases relating stress, such as sudden death during transport, abnormal carcass quality and astasia after parturition. In clinical researches on these subjects, sequential collection of blood samples from unrestrained animals is indispensable.

Main purpose of this study is to establish a technique of catheterization for sequential collection of blood in resting condition from finishing pigs on transport and

¹ Department of Veterinary Internal Medicine,

² Department of Physiology,

³ Department of Biochemistry and

⁴ Department of Veterinary Anatomy, Faculty of Veterinary Medicine, Hokkaido University, Sapporo 060 Japan

⁵ Takikawa Animal Husbandry Experimental Station of Hokkaido, Takikawa 073 Japan

⁶ A part of this study was released at the 41st Meeting of the Japanese Society of Swine Science on April 3, 1984 in Tokyo.

from pregnant sows.

In pigs, most of the superficial blood vessels are covered with well-developed subcutaneous fat, and are not suitable for venipuncture. The auricular vein is one of a few visible superficial veins, and easily found in white pigs. But blood samples obtained by venipuncture from the ear vein are often too small in amount for testing. Therefore, venipuncture of the anterior vena cava¹⁾ and the orbital sinus⁸⁾ is adopted widely rather than ear bleeding and tail bleeding with the blade^{5,7)}. Bleeding from the abdominal subcutaneous vein and cephalic vein¹²⁾ is rarely used in young pigs. These methods of venipuncture are useful for temporary blood sampling, but are inadequate for frequent collection of blood because of injury of the vessels. Moreover, collection of blood under resting condition is difficult because animals always struggle during forcible restraint. So, several procedures of chronic catheterization have been described for research on metabolism in order to avoid these effects from restraint. The vessels in which the catheter was implanted were the jugular vein^{2,3,6,10,11)} and artery^{6,10,11)}, femoral vein and artery^{4,9,13)}, saphenous vein^{10,14)}, median coccygeal artery and subcutaneous mammary vein¹⁵⁾. Unfortunately, these methods of catheterization are also inadequate for finishing pigs or sows awaiting parturition within a few days. Because these animals are too obese and heavy to perform such operation in lateral or dorsal position. And these methods require 7 to 10 days for healing up of the wound before desirable blood sampling. Moreover, these methods might induce sudden death or abortion of the animals.

In this paper, authors propose a more simple technique of catheterization from the ear vein into the jugular vein or anterior vena cava in standing position without any previous anesthesia and incision.

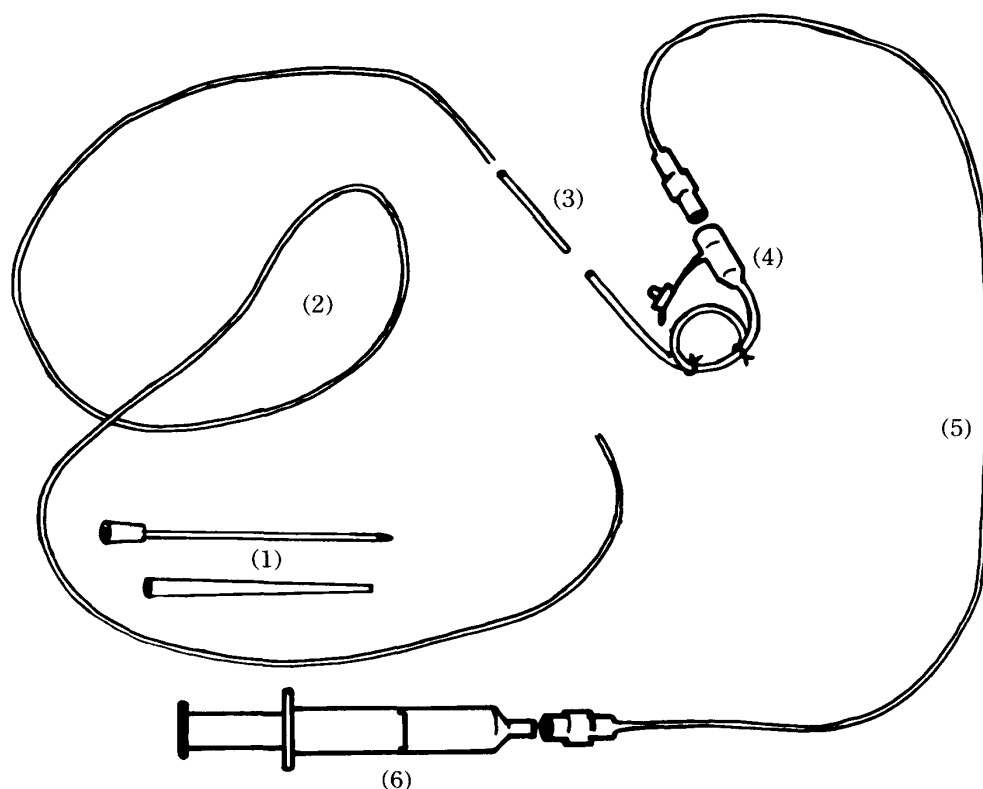
MATERIALS AND METHODS

Following the course of veins

Prior to catheterization, four 20 kg piglets were employed to investigate the course and length of veins from the ear to the heart in order to make reference data for estimation of the most appropriate catheter length for intact animals. The investigation was made by dissection and radiograph of the piglets after death with an anesthetic drug, pentobarbital. Of the three visible veins on the dorsal area of the auricle, the middle or lateral vein was used for cannulation, since the innermost vein runs under thick skin and is situated in an unfavorable area for insertion of the trocar.

Instruments for catheterization

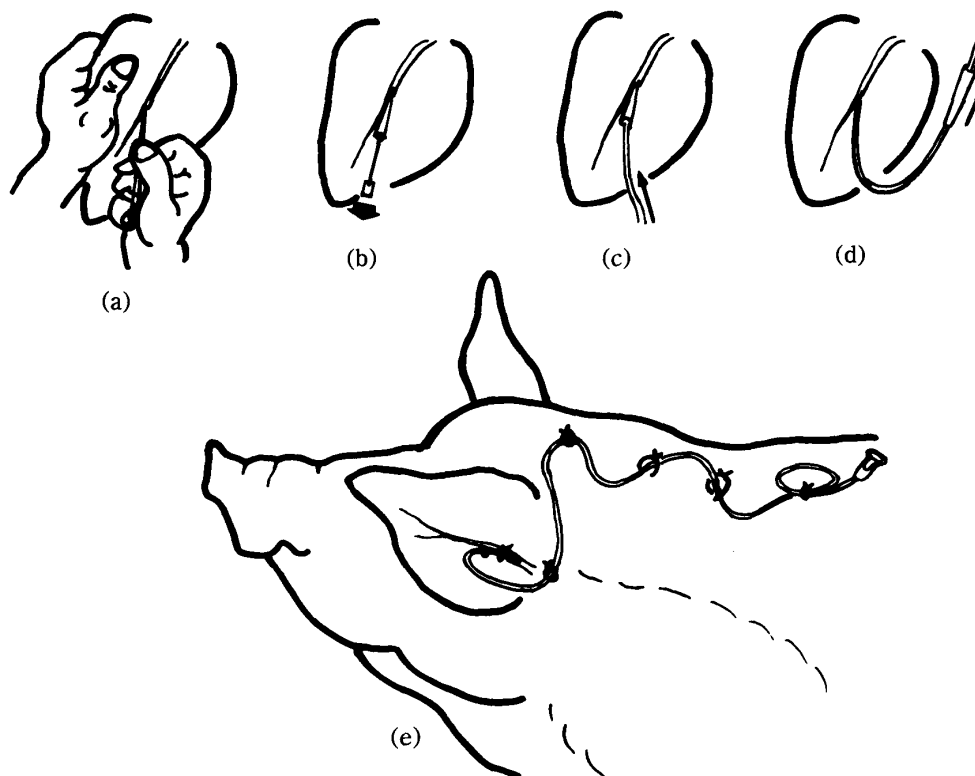
The instruments used for catheterization consisted of the following: a trocar-cannula type needle, catheter, connector, adaptor and extension tube and injector (Fig. 1). Trocar-cannula type needles, Medicut-Cannula (product of Nippon Sherwood Medical Industries Ltd., Tokyo, Japan), were used. The cannula size was 14 gauge

FIGURE 1 *Instruments for catheterization*

- (1) trocar-cannula type needle, (2) catheter,
 (3) connecting tube, (4) adaptor,
 (5) extension tube, (6) injector.

for 20 kg piglets, and 12–14 gauge for 90 kg pigs. In 20 kg piglets, a cardiac catheter (Argyl's Sentinel Line Catheter: Product of Nippon Sherwood Medical Industries) and a vinyl indwelling tube for infant feeding (Disposable indwelling tube for infant feeding: product of ATOM Inc., Tokyo, Japan: 1.35 mm, 40 cm) were tested as the catheter. A vinyl tube for medical use (16 gauge, 1 m in length) and Argyle's Medicut-Catheter (16 gauge, 95 cm) were tried in the 90 kg pigs. The connector was made from an 18 gauge subcutaneous needle and used for connection of the catheter to the adaptor after removal of the cannula from the free end of the catheter. The adaptor was equipped with a small plug. The tube of the adaptor was looped previously to allow better adhesion to the skin. The instruments were light in weight to avoid unpleasant irritation to the animals. The extension tube was connected to the adaptor at every blood sampling.

FIGURE 2 Procedure of venous catheterization from the ear vein in pigs



- (a) insertion of trocar-cannula type needle into the ear vein,
- (b) removal of needle,
- (c) insertion of catheter through cannula,
- (d) removal of cannula from catheter,
- (e) fixation of catheter.

Catheterization

Four 20 kg piglets and five 90 kg pigs were employed to test the catheterization. The animals were restrained in the standing position by grasping the end of the snout with a looped wire, and the caudal auricle was sterilized with 70% ethanol. As shown in Figure 2, the middle or lateral auricular vein was penetrated with the trocar-cannula type needle. After insertion of the cannula into the vessel, the needle was removed, and the catheter was inserted into the vein through the cannula to the jugular vein. Then the cannula was removed from the catheter. The free end of the catheter was connected to the adaptor using the connector. Blood in the canal of the catheter was ejected by filling the canal with Ringer's solution containing sterile heparin (NOVO Heparin: NOVO Industry A/S, Denmark). The adaptor was then sealed with the plug until the next sampling. The catheter was fastened by interrupted sutures at several points, i. e., the nearest point to

the insertion, the hollowed area beneath the root of the ear, and the nearest point to the ear on the middle line of the back. The adaptor was fixed on the withers, where movement of the body was considered to be minimum. A few loops were made by rough suture on the middle line of the back through which the catheter could be moved. Thus, the catheter was fixed on the back so as not to hang down and prevented from slipping down due to rubbing or pulling. The point of insertion of the catheter was treated with α -cyanoacrylate cement (Aron Alpha A, product of Sanyo, Tokyo, Japan) to avoid bleeding and infection.

Blood sampling

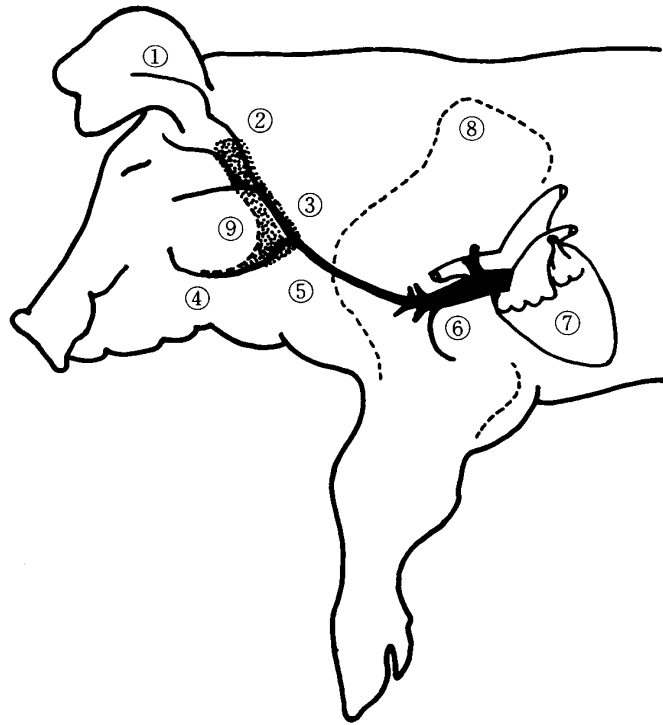
Blood sampling was achieved by connection of the extension tube to the adaptor. After sampling, the canal of the catheter was refilled with anticoagulant solution until the next sampling.

RESULTS AND DISCUSSION

The veins from the ear to the heart are the lateral or middle auricular vein, caudal auricular vein, maxillary vein, external jugular vein, brachiocephalic vein and anterior vena cava. The veins from the ear to the neck run down between the sternomastoid muscle and parotid gland along the caudal margin of the gland (Fig. 3). The caudal auricular vein flows into the maxillary vein. The maxillary vein joins with the linguofacial vein and runs into the external jugular vein at the cross point of the caudal margin of the gland with the extended base-line of the lower jaw. There is no problem of misleading the catheter into the linguofacial vein, because these two veins join at an acute angle. The external jugular vein runs into the thoracic cavity via a point behind the most cranially projected part of the shoulder joint, namely, the tuberosities of the humerus. In 20 kg piglets, the length of each vein was measured as 5–6 cm for the caudal auricular vein (ear base to junction with maxillary vein), 3–4 cm for the maxillary vein (distance between the caudal auricular vein and the external jugular vein), 8–10 cm for the external jugular vein, and 5–6 cm for the brachiocephalic vein and the anterior vena cava.

The catheter length required for indwelling is estimated from the distance of several linked points, i. e., the root of the ear, the cross point of the caudal margin of the parotid gland with the extended base-line of the lower jaw, and the cranial tip of the shoulder joint in proportion to the animal size. The direction of the apex of the ear affects the catheterization. When the ear was pulled in the cranial or caudal direction, the auricular veins were bent at the base of the ear. But the course of the veins showed a smooth curve from the ear to the anterior vena cava when the ear was held up straight.

In 20 kg piglets, insertion of the cardiac catheter and the feeding tube was smooth. The tip of the cardiac catheter reached the junction of the left and right

FIGURE 3 *Course of blood vessels from ear to heart*

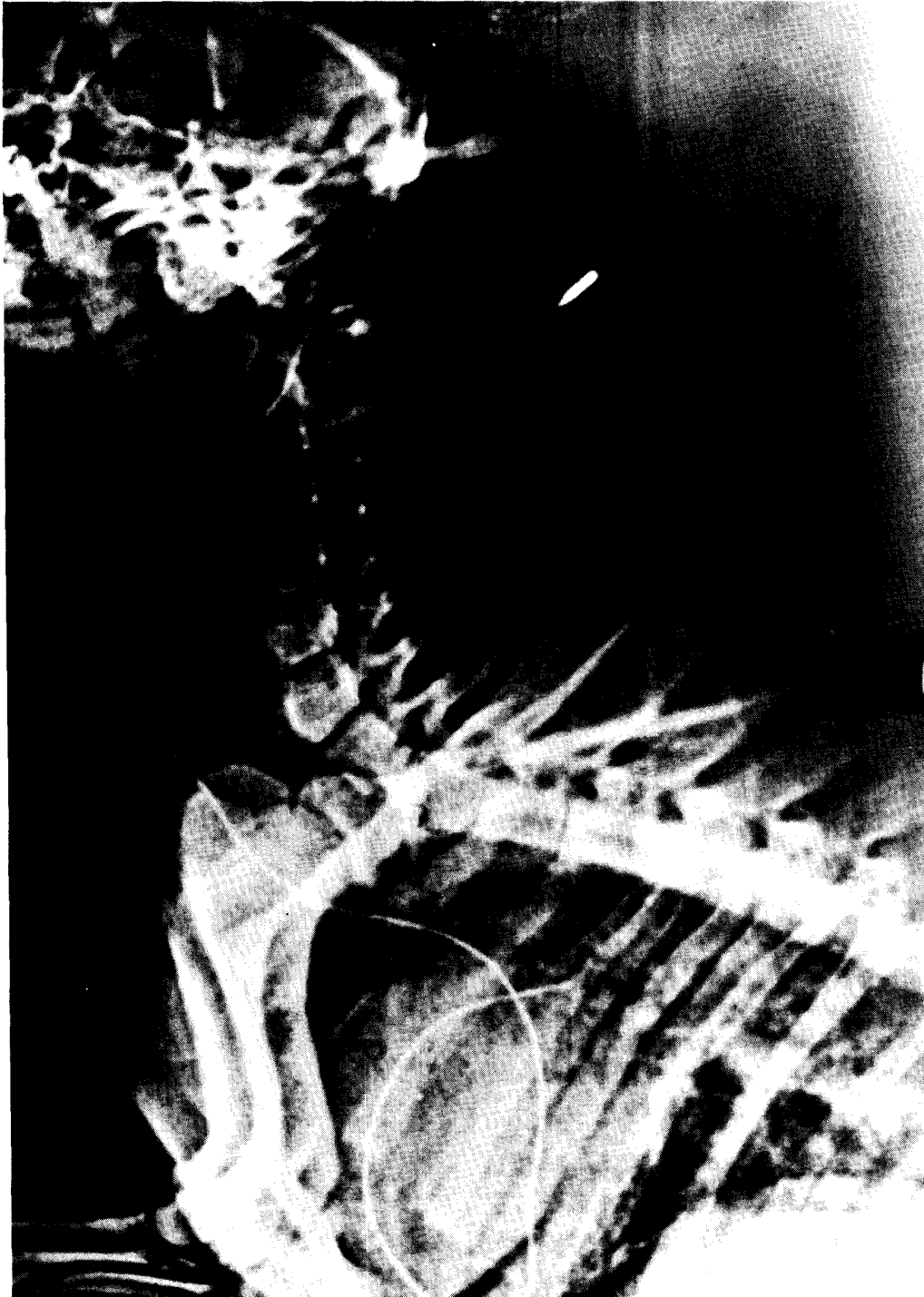The course draws a smooth curve along the caudal margin of the parotid gland and via the most cranial tip of the shoulder.

(1) auricular vein, (2) caudal auricular vein, (3) maxillary vein, (4) linguofacial vein, (5) external jugular vein, (6) brachiocephalic vein and anterior vana cava, (7) heart, (8) outline of the shoulder, (9) parotid gland.(dotted area).

pulmonary artery when the depth of its indwelling portion was 42 cm (Fig.4). But the canal of the catheter was too narrow to draw blood.

The feeding tube was found to be suitable as a catheter in the 20 kg piglets. Catheterization in the 90 kg pigs was also smooth in 4 cases using the vinyl tube, but it was difficult in one case using Argyl's Medicut-Catheter because of its stiff character. This problem might have been due to atmospheric temperature. Smooth insertion of the catheters was accomplished by sure intravenous insertion of the cannula and by perpendicular erection of the ear. Since the auricular vein was used not as a site of blood sampling but for introduction of the catheter into the deeper and bigger vein, time for motionless restraint was short compared with usual auricular venipuncture.

FIGURE 4 *Radiograph of a catheterized piglet*



Cardiac catheter reached the pulmonary artery. Arrow indicates a point of insertion of the auricle.

Retention of the catheter was experienced for 3 days in the 90 kg pigs. Smooth collection of blood samples was possible without restraint. There was no unpleasant symptom during the catheterization. Moreover, the animals appeared to be indifferent to the catheter attached to the auricle.

As mentioned above, the present experience proved that the catheterization from the ear vein was an easy and useful method for frequent collection of blood from unrestrained pigs, except for the restraint period of several minutes prior to insertion of the catheter. This technique is helpful for research on stress syndrome in pigs in which previous restraint in the dorsal position, general anesthesia and incision for catheterization are difficult, for example, in the case of sows awaiting parturition, or in finishing pigs being transported. One disadvantage of this procedure is the inevitable exposure of the catheter from the auricle. Thus, individual feeding in a flatly walled pen is necessary. The use of a heparinized catheter may prolong the functional period.

ACKNOWLEDGMENT

The authors thank Dr. Nobuhiko HOSHI, DVM., for his helpful encouragement in this work.

REFERENCES

- 1) CARLE, B. E. & DEWHIRST, W. H. JR. (1942): A method for bleeding swine *J. Am. Vet. Med. Ass.*, **101**, 495-496.
- 2) CHRISTISON, G. I. & CURTIN, T. M. (1969): A simple venous catheter for a sequential blood sampling from unrestrained pigs *Lab. Anim. Care*, **19**, 259-262.
- 3) DONALD, R. A., SALISBURY, M. S. & NABARPO, J. D. N. (1968): The plasma corticotrophin response to insulin hypoglycemia, lysine-vasopressin and metyrapon in pigs *J. Endocr.*, **41**, 509-518.
- 4) DOUGHERTY, R. W., SHUMAN, R. D., MULLENAX, C. H., WITZEL, D. A., BUCK, W. B., WOOD, R. L. & COOK, H. M. (1965) Physiopathological studies of erysipelas in pigs *Cornell Vet.*, **55**, 87-109.
- 5) GETTY, R. & CHOSHAL, N. G. (1967): Applied anatomy of the sacrococcygeal region of pig as related to tail-bleeding *Vet. Med. / Small Anim. Clin.*, **63**, 361-367.
- 6) HAND, M. S., PHILLIPS, R. W. MILLER, C. W., MASON, R. A. & LUMB, W. V. (1981): A method for quantitation of hepatic, pancreatic, and intestinal function in conscious Yucatan Miniature Swine *Lab. Anim. Sci.*, **31**, 728-731.
- 7) HOERLEIN, A. B., HUBBARD, E. D. & GETTY, R. (1951): The procurement and handling of swine blood samples on the farm *J. Am. Vet. Med. Ass.*, **119**, 357-362.
- 8) HUHN, R. G., OSWEILER, G. D. & SWITZER, W. P. (1969): Application of the orbital sinus bleeding technique to swine *Lab. Anim. Care*, **19**, 403-405.
- 9) JACKSON, I. M. D., COOK, D. B. & CILL, G. (1972): Simultaneous intravenous infusion and arterial blood sampling in piglets *Lab. Anim. Sci.*, **22**, 552-555.

- 10) KNIPFEL, J. E., PEACE, R. W. & EVANS, J. A. (1975): Multiple vascular and gastric cannulation of swine for studies of gastrointestinal, liver, and peripheral tissue metabolism *Lab. Anim. Sci.*, **25**, 74–78.
- 11) LUCKE, J. N. & HALL, G. M. (1978): A technique for measuring hepatic blood flow and oxygen consumption in the anesthetised pig *Res. Vet. Sci.*, **25**, 393–394.
- 12) STAUB, H. (1954): Ein Beitrag zur Blutentnahme bei Ferkeln *Berl. Münch. Tierärztl. Wsch.*, **67**, 188–189.
- 13) WEIRICH, W. E., WILL, J. A. & CRUMPTON, C. W. (1970): A technique for placing chronic indwelling catheters in swine *J. Appl. Physiol.*, **28**, 117–119.
- 14) WITHEY, R. J., WILLES, R. F., EVANS, J. & BRYCE, F. R. (1973): The surgical preparation and maintenance of pigs in bioavailability studies *Lab. Anim. Sci.*, **23**, 122–125.
- 15) WITZEL, D. A., LITLEDIKE, E. T. & COOK, H. M. (1973): Implanted catheters for blood sampling in swine *Cornell Vet.*, **63**, 433–435.