



Title	ON THE EGG FORMATION AND THE FOLLICULAR CHANGES IN LEBISTES RETICULATUS
Author(s)	TAKANO, Kazunori; 高野, 和則
Citation	北海道大學水産學部研究彙報, 15(3), 147-155
Issue Date	1964-11
Doc URL	https://hdl.handle.net/2115/23227
Type	departmental bulletin paper
File Information	15(3)_P147-155.pdf



ON THE EGG FORMATION AND THE FOLLICULAR CHANGES
IN *LEBISTES RETICULATUS*

Kazunori TAKANO

Faculty of Fisheries, Hokkaido University

The viviparous teleost, *Lebistes reticulatus* has been widely used for the analyses of reproductive phenomena in viviparous forms. As for the egg formation of this fish, however, only a few studies have been performed. Dildine (1933, 1936) and Goodrich *et al* (1934) studied histologically the gonads of embryos and clarified the history of the young oocytes. Purser (1938) gave general information on the ovary of gravid fish, and Stolk (1951) offered a brief note concerning the cycle of egg formation during the gestation period. On the other hand, Vakaet (1955) who has made a cytological and cytochemical study on the oocyte, brought to light the chemical nature of the some contents of eggs and the change of oocyte polarity without regard to the reproductive cycle.

Much attention has been devoted to the morphological characteristics of the ovaries and the embryos related to the viviparity. Turner (1940) studied this subject extensively in poeciliid fish. However, little attempt has been made to examine the characteristics of the egg itself in each species to show various extent of the differentiation in viviparity. As a preliminary approach to this problem, the present study has been carried out in order to examine the process of egg formation, with special attention to the follicular changes, using *Lebistes reticulatus* as material.

Before going further, the writer wishes to express his cordial thanks to Professor Kiichiro Yamamoto of the Faculty of Fisheries, Hokkaido University, for his constant guidance and encouragement in the course of the present study and also for his kind correction of this manuscript. Thanks are likewise offered to Assistant Professor Tatsuro Kubo for much help in the course of the present study.

Material and Methods

Lebistes reticulatus used in the present study, was raised in the laboratory of the Fisheries School, Hokkaido University, under artificially controlled conditions. All fish were maintained at 22-26°C, and illuminated by artificial light for about the length of the natural day. The ovaries were fixed with several kinds of fixatives such as Bouin's, Allen-Bouin's, Zenker's, Carnoy's, Champy's, and Weber's fluids. Serial sections of the whole ovary, 7-10 micra in thickness, were prepared following the usual paraffin method and stained with Heidenhain's iron haematoxylin-

light green or Delafield's haematoxylin-eosin. In addition to these procedures, PAS reaction for the demonstration of polysaccharides, and Sudan III and Sudan Black B stains after Ciaccio's method for lipid test were used.

Results

I. *Morphological changes in the growing oocytes*

In order to facilitate description, the process of egg formation was divided into the following seven stages.

(1) Chromatin-nucleolus stage

The oocytes of this stage are very minute and are below 0.02 mm in diameter. In these oocytes the nucleus is spherical and occupies the greater part of the oocyte. The cytoplasm presents a very thin sheath which often has an indistinct boundary. This stage can be subdivided into the synaptic and the post-synaptic stage according to the aspect of the nuclei (Fig. 1). Oogonia and very young oocytes are observed at the surface of the ovarian walls bordering on the ovarian cavity. Usually they group in small nests which are enveloped with subepithelial connective tissue and are situated closely beneath the epithelium lining of the ovarian walls. These young cells are sometimes found embedded independently within the epithelium itself.

(2) Peri-nucleolus stage

This stage can also be divided into two substages; the early peri-nucleolus and late peri-nucleolus stages.

In the early peri-nucleolus stage, oocytes have cytoplasm which gradually increases in volume and becomes stained with haematoxylin. Within the nucleus there are found many chromatin threads. In the early phase a few nucleoli are distributed throughout it (Fig. 2), and then they increase in number, arranging themselves on the periphery of the nucleus. The yolk nucleus may be seen close to the nuclear membrane. The cytoplasm frequently shows a zoning phenomenon. In the materials fixed with osmium fixatives, a few minute oil granules may appear in the peri-nuclear cytoplasm.

In the late peri-nucleolus stage, the nucleus with spherical nucleoli of peripheral arrangement is often situated eccentrically as shown by Vakaet (1955). The cytoplasm gradually loses its affinity to haematoxylin, and the layer of oil drop, which is found in the routine histological preparations as the vacuolar layer, begins to be formed in the peri-nuclear region (Fig. 3). The yolk nucleus moves to the periphery of the cytoplasm and finally it disappears from sight. The oocyte membrane is found as a very thin boundary membrane between the cytoplasm and the follicular epithelium.

The oocytes at this stage range from about 0.02 to 0.15 mm in diameter.

(3) Oil drop stage

In this stage, oil drops which have been found in the peri-nuclear cytoplasm increase rapidly in number and volume (Figs. 4 and 6). The diameter of the oocyte measures about 0.14 to 0.37 mm. In the early phase of this stage, PAS-positive granules which have already been observed by Vakaet (1955) appear in the periphery of the oocyte (Figs. 5 and 13). These granules are almost invisible in the preparations made in the routine manner. Differing from the "yolk vesicle" found in oviparous fish (Yamamoto, 1956; etc.), they seemingly are neither accumulated centripetally nor enlarged in size. On the other hand, the accumulation of oil drops proceeds centrifugally with the growth of the oocyte until they occupy the greater part of the oocyte. Simultaneously, the cytoplasm exhibits the coarse reticulum. The nucleus becomes somewhat oval in form and irregular in outline. The oocyte membrane shows no conspicuous changes, and remains as a very thin layer.

In the Sudan staining preparations after Ciaccio's method, oil drops present a vacuolar form with sudanophilic walls.

(4) Primary yolk stage

When oil drops have been distributed to almost all parts of the cytoplasm, yolk globules begin to appear (Figs. 7 and 14). They are found at first in the peripheral cytoplasm as minute bodies stained with haematoxylin. The accumulation of yolk globules proceeds centripetally and the globules are found embedded between oil drops. At the same time, these globules come together and gradually form the masses of yolk (Fig. 8). As the yolk globules give a strong positive reaction, PAS-positive granules which have been observed in the previous stage become indistinguishable (Fig. 14). The nucleus becomes polyhedral in form, in which the nucleoli are distributed irregularly. The size of the oocytes in this stage ranges from 0.35 to 0.47 mm in diameter.

(5) Secondary yolk stage

As the formation of yolk globules increases further, a large massed globule begins forming in the center of the oocyte. Simultaneously with this change, oil drops are shifted outward and fuse together to some extent. The nucleus showing the polyhedral form and more irregular contour moves toward one pole of the oocyte. In the late phase of this stage, the nucleoli distributed at random in the nucleus are seen as strings of beads which are stained with haematoxylin. The diameter of the oocytes at this stage ranges from 0.45 to 0.8 mm (Fig. 9).

(6) Tertiary yolk stage

The accumulation of yolk globules progresses rapidly and results in the marked

increase of the oocyte size. These globules are almost fused to a single mass with the exception of some of the globules on the periphery of the oocyte, and show a strong PAS-positive reaction. The nucleus has arrived at the periphery and is situated close to the oocyte membrane, and the nucleoli are found distributed at random within the nucleus. These oocytes measure from 0.7 to 1.6 mm in diameter (Fig. 10). Throughout these three yolk stages the oocyte membrane does not show any visible change.

(7) Maturation stage

The oocytes are somewhat larger than those of the previous stage, measuring from 1.5 to 1.77 mm in diameter (Fig. 11). The yolk globule becomes a complete single mass, and vitellogenesis is accomplished at this stage. At the same time, the nucleoli lose their affinity to dyes and finally the nucleus becomes indistinguishable.

The mature eggs are fertilized and begin to develop within the follicle (Fig. 12).

II. *Follicular changes with the growth of the oocyte*

Around the oogonia and very young oocytes found in nests, it is difficult to

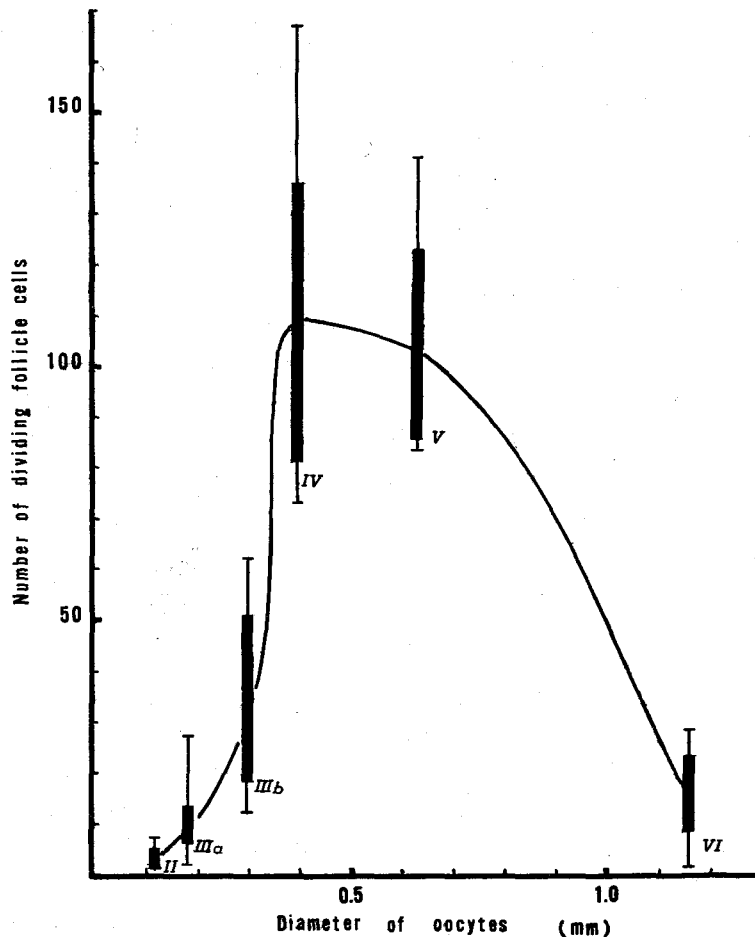
Table 1. Number of dividing follicle cells in oocytes of various sizes

Diameter of oocyte (μ)	Number of dividing follicle cells	Stage	Diameter of oocyte (μ)	Number of dividing follicle cells	Stage	Diameter of oocyte (μ)	Number of dividing follicle cells	Stage
87	2	II	194	25	IIIa	430	117	IV
94	1		197	27		445	86	
108	1		201	10		454	126	
109	4		204	8		479	83	
119	2		206	18		585	135	
119	3		239	10	592	110	V	
146	7		252	21	594	96		
148	7		266	25	680	84		
151	5		278	12	687	91		
153	2		294	20	700	141		
156	3	297	37	716	88			
156	8	305	49	1071	3			
158	6	347	62	1120	22			
162	7	371	30	1124	19			
170	2	350	90	1159	16	VI		
183	6	354	73	1180	1			
184	16	354	76	1182	28			
185	4	368	134	1207	14			
186	5	395	167	1271	21			

II: peri-nucleolus stage, IIIa: early oil drop stage, IIIb: late oil drop stage,

IV; primary yolk stage, V; secondary yolk stage, VI: tertiary yolk stage.

detect the presence of follicle cells. These cells become recognizable when the oocytes of the early peri-nucleolus stage are freed from their nest (Fig. 15). At that time the follicular epithelium is considerably flattened, measuring less than 2.5 micra in height and consists of a few cells which have squamous nuclei and indistinct cell boundaries. In the oocytes of the late peri-nucleolus stage or in the early phase of the oil drop stage, the epithelium begins to protrude into the oocyte. As the oocytes grow further, the protuberances become more conspicuous. This protuberance is not formed by the increase in each cell height, but rather by the



Text-fig. 1. Number of dividing follicle cells at each stage of oocyte growth

irregular arrangement of follicle cells (Fig. 17). In the oocyte of the primary yolk stage, the protuberances gradually become obscure, but some of them are still discernible. The epithelium itself increases in thickness and measures 5-9 micra in height. At the secondary yolk stage, it almost loses its undulatory feature and consists of densely packed cells of 4.5-7 micra in height. The cells are cuboidal in form and have achromatic nuclei with a few stained nucleoli (Fig. 18). Thereafter, the epithelium gradually decreases in height with the growth of the oocyte. During the final rapid growth period, it stretches until it becomes thin and flat, measuring 2.5-4.5 micra in height. Many bacilliform nuclei showing a good affinity for haematoxylin are seen in the epithelium (Fig. 19). After the oocyte has been fertilized, the epithelium loses its packed cellular arrangement and changes into a thin vascular fibrous membrane. With the development of the embryo, this vascularity becomes marked (Fig. 20).

Mitotic proliferation of the follicle cell, on the other hand, begins to appear in the peri-nucleolus stage oocyte measuring more than 87 micra in diameter (Fig. 16). These dividing follicle cells change in number with the development of the oocytes. The total number of these cells in oocytes of various size is recorded in Table 1. Furthermore, Text-fig. 1 shows the mean number of these cells at each stage of oocyte growth. From this data, it is clear that the mitotic activity of the follicle cells rises quickly in the late phase of the oil drop stage and reaches the maximum in the primary yolk stage. This high activity is maintained throughout the secondary yolk stage, while it decreases markedly at the tertiary yolk stage and the dividing cell can scarcely be observed at the late phase of the tertiary yolk and the maturation stages.

Discussion

Lebistes eggs have two kinds of principal vitelline elements, viz., yolk globule and oil drop. Yolk vesicle which is found in most of the fish eggs so far examined could not be distinctly recognized in the present study, although the PAS-positive granules which are likely identical with yolk vesicle were seen in young oocytes.

As stated above, ripe eggs have a continuous mass of yolk and belong to massed yolk type as that of the flounder does (Yamamoto, 1956, 1957). However, the commencement of massed yolk formation in *Lebistes*, takes place in the early phase of the vitellogenesis and results in the early occurrence of nucleus migration, while in the flounder these phenomena occur late in the pre-maturation stage.

Vakaet (1955) classified the process of egg formation of the present species into five stages. Comparing the present stages with his, the result is as follows ;

Chromatin-nucleolus stage	}	<i>Prévitellogénèse précoce</i> (10-50 μ in diameter)
Peri-nucleolus stage		
Early peri-nucleolus stage	}	<i>Prévitellogénèse moyenne</i> (50-150 μ)
Late peri-nucleolus stage		
Oil drop stage	}	<i>Prévitellogénèse tardive</i> (150-300 μ)
Primary yolk stage	}	<i>Vitellogénèse primaire</i> (250-500 μ)
Secondary yolk stage	}	<i>Vitellogénèse secondaire</i>
Tertiary yolk stage		
Maturation stage		

From these results it is reasonably judged that Vakaet's classification places much stress on the pre-vitellogenetic phase and is not adequate in representing the proper stage of egg development.

One of the characteristics of the *Lebistes* eggs lies in the fact that the oocyte membrane retains its thin state throughout the course of the egg formation. This characteristic is considered to be due to its adaptation for viviparity (Chambolle *et al.*, 1962). Another characteristic is that of the follicular protuberances observed in the oil drop stage. In poeciliid fish, *Xiphophorus helleri*, Bailey (1933) has already observed similar phenomena. He described the follicular epithelium as showing undulations as if to increase the surface during the period of oil secretion. Whether or not the undulation or protuberances have a direct connection to the oil secretion, must be the subject of future research.

Mendoza (1943) has already found the mitotic proliferation of the follicle cells during the growth of oocytes in viviparous fish, *Neotoca bilineata*. On the other hand, Yamazaki (1963), using the goldfish, clarified a correlation between the multiplication of follicle cells and oocyte growth. According to his findings, the dividing cells are observed in oocytes over 80 micra, and they are most numerous in the middle-sized oocytes. Then, the dividing cells decrease rapidly in number and disappear in the oocyte just before maturation. In *Lebistes*, the aspect of the correlation between the mitotic proliferation and the oocyte growth is generally similar to that in goldfish. The highest frequency in the division of follicle cells is found in the oocytes of the primary yolk stage as in goldfish. However, the average number of these cells in the primary yolk stage is far more numerous in *Lebistes* (109) than in goldfish (37), in spite of the fact that these oocytes are nearly the same size in both species. Although it is quite possible that the mitotic activity of the follicle cells is influenced by physiological and environmental conditions of fish, this emphasizes the fact that vitellogenesis in *Lebistes* is completed in a very short period as compared with the goldfish.

In considering the above results, the follicular changes in *Lebistes* may be

divided into the following three phases. The first, the inactive phase up to the early peri-nucleolus stage when the follicle cells are flat and few in number and show no dividing figure; the second, the proliferation phase extending from the late peri-nucleolus stage to the secondary yolk stage, during that time the follicle cells commence to divide mitotically and reach their maximum number; the third is the functional phase corresponding to the tertiary yolk stage. During this phase the follicle cells rapidly decrease in the number of dividing figures, and may devote themselves to the accumulation of yolk until the completion of vitellogenesis.

The follicular changes in the second and third phases are probably concerned with pituitary gonadotrophin (Yamazaki, 1961, 1963).

Summary

1. Yolk globule and oil drops are the principal vitelline elements of *Lebistes* eggs. Oil drops appear at first in the peri-nuclear cytoplasm, then are accumulated centrifugally, and finally they are shifted outward with the formation of massed yolk. Yolk globules are accumulated centripetally from the peripheral cytoplasm and form a massed yolk.

2. The oocyte membrane remains in a very thin state throughout the course of egg formation.

3. The follicular epithelium folds into the oocyte as small protuberances at the time of the accumulation of oil drops. Then it becomes again a flat layer composed of cuboidal cells, along with the formation of yolk globules. During the final rapid growth period, the epithelium is stretched thinly, and after fertilization it is transformed to a vascular fibrous membrane.

4. Mitotic proliferation of the follicle cell was observed first in the oocyte of 87 micra, and presented their maximum number in the early phase of yolk accumulation. Then, the dividing cells decreased rapidly in number, and disappeared just before maturation.

Literature

- Bailey, R. J. (1933). The ovarian cycle in the viviparous teleost *Xiphophorus helleri*. *Biol. Bull.* 64, 206-225.
- Chambolle, P., Cambar, R. & Gendre, P. (1962). Etude au microscope électronique de la formation et de la structure de la membrane pellucide de *Lebistes reticulatus* (Téléostéen Poeciliidé). *C. R. Soc. Biol.* 156, 2018-2020.
- Dildine, G. C. (1933). Germ cell origin and gonad differentiation in the viviparous top minnow, *Lebistes reticulatus*. *Anat. Rec.* 57, Suppl. 88.
- (1936). Studies in teleostean reproduction. I. Embryonic hermaphroditism in *Lebistes reticulatus*. *J. Morph.* 60, 261-277.

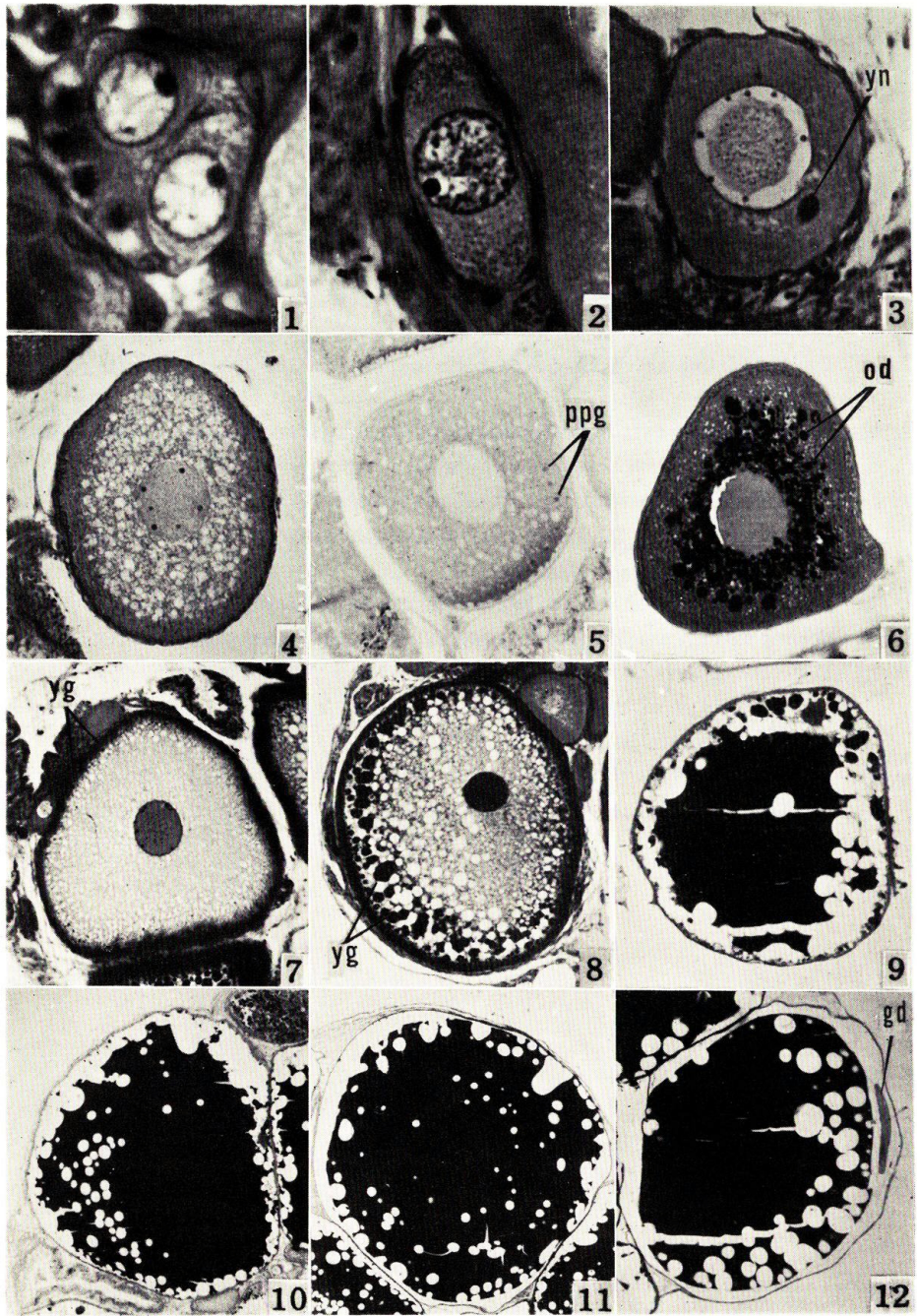
- Goodrich, H. B., Dee, J. E., Flynn, C. M. & Mercer, R. N. (1934). Germ cells and sex differentiation in *Lebistes reticulatus*. *Biol. Bull.* 67, 83-96.
- Mendoza, G. (1943). The reproductive cycle of the viviparous teleost, *Neotoca bilineata*, a member of the family *Goodeidae*. IV. The germinal tissue. *Biol. Bull.* 84, 87-97.
- Purser, G. L. (1938). Reproduction in *Lebistes reticulatus*. *Quart. J. micr. Sci.* 81, 150-158.
- Stolk, A. (1951). Histo-endocrinological analysis of gestation phenomena in the cyprinodont *Lebistes reticulatus* Peters. IV. The oocyte-cycle during pregnancy. *Proc. Kon. Ned. Akad. v. Wetensch. C* 54, 574-578.
- Turner, C. L. (1940). Pseudoamnion, pseudochorion, and follicular pseudoplacenta in poeciliid fishes. *J. Morph.* 67, 59-89.
- Vakaet, L. (1955). Recherches cytologiques et cytochimiques sur l'organisation de l'oocyte I de *Lebistes reticulatus*. *Arch. Biol.* 66, 1-73.
- Yamamoto, K. (1956). Studies on the formation of fish eggs. I. Annual cycle in the development of ovarian eggs in the flounder, *Liopsetta obscura*. *J. Fac. Sci. Hokkaido Univ., S. VI.* 12, 362-373.
- (1957). Studies on the formation of fish eggs. XI. The formation of a continuous mass of yolk and the chemical nature of lipids contained in it in the oocyte of the flounder, *Liopsetta obscura*. *Ibid.* 13, 344-351.
- Yamazaki, F. (1961). The effects of hypophysectomy on the ovary of the goldfish, *Carassius auratus*. *Bull. Fac. Fish., Hokkaido Univ.* 12, 167-180.
- (1963). On the multiplication of follicle cells in the oocyte of the goldfish, *Carassius auratus*. *Ibid.* 14, 41-45.

EXPLANATION OF PLATES

All figures are photomicrographs obtained from sections of the ovaries of *Lebistes reticulatus*.

PLATE I

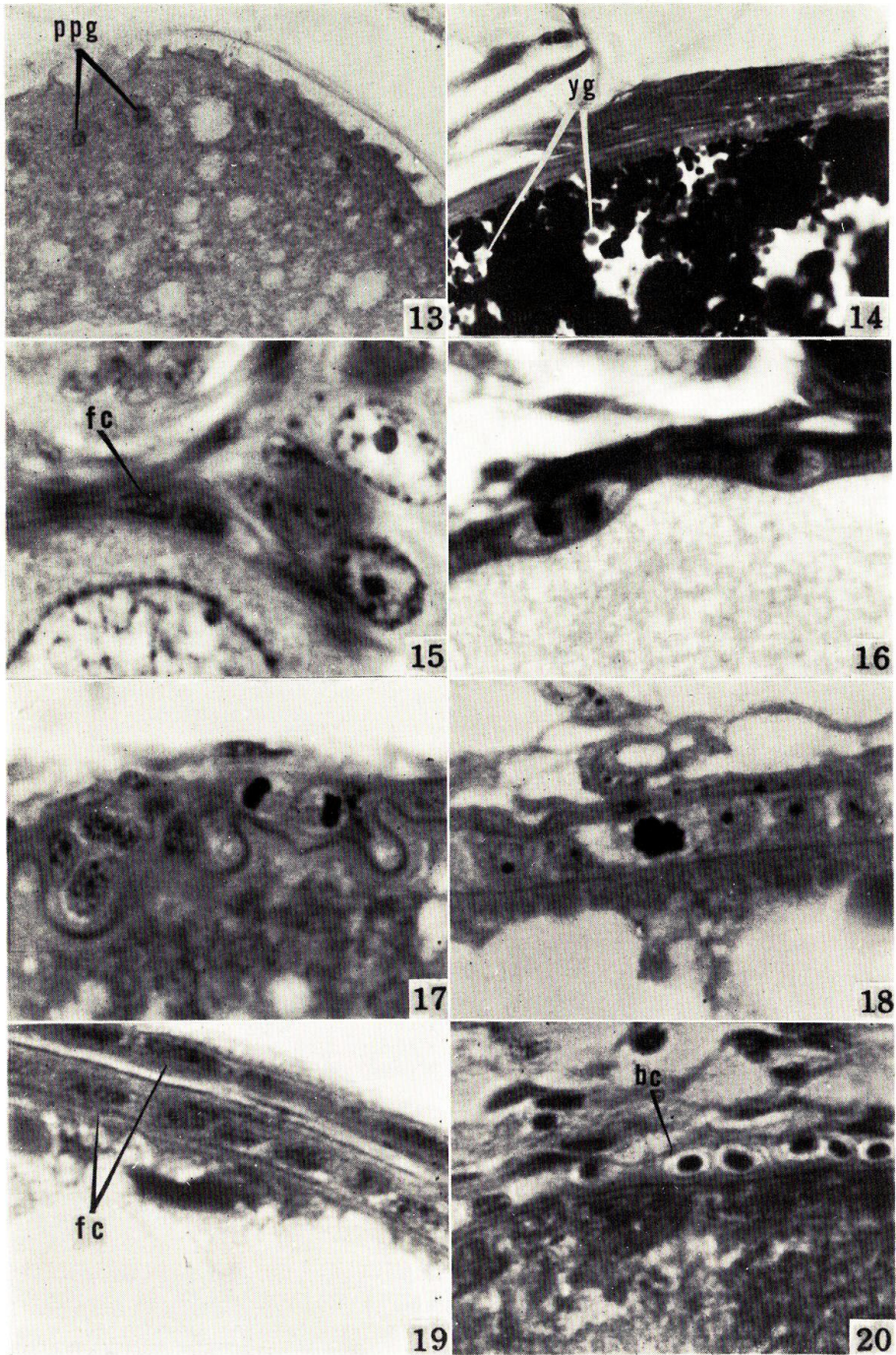
- Fig. 1. Oocytes of the chromatin-nucleolus stage situated in a nest. Allen-Bouin's solution and Delafield's haematoxylin-eosin preparation. $\times 1060$
- Fig. 2. Oocyte at the early phase of peri-nucleolus stage. Allen-Bouin's solution and Heidenhain's haematoxylin-light green preparation. $\times 680$
- Fig. 3. Oocyte at the late phase of peri-nucleolus stage. Allen-Bouin's solution and Delafield's haematoxylin-eosin preparation. *yn*, yolk nucleus. $\times 330$
- Fig. 4. Oocyte at the oil drop stage. Allen-Bouin's solution and Delafield's haematoxylin-eosin preparation. $\times 150$
- Fig. 5. Oocyte at the oil drop stage. Bouin's solution and PAS preparation. *ppg*, PAS-positive granules. $\times 150$
- Fig. 6. Oocyte at the early phase of oil drop stage. Weber's solution and PAS preparation. *od*, oil drops. $\times 230$
- Fig. 7. Oocyte in the primary yolk stage. Allen-Bouin's solution and Heidenhain's haematoxylin-light green preparation. *yg*, yolk globules. $\times 90$
- Fig. 8. Oocyte in the primary yolk stage. Allen-Bouin's solution and Heidenhain's haematoxylin-light green preparation. $\times 85$
- Fig. 9. Oocyte at the secondary yolk stage. Bouin's solution and Heidenhain's haematoxylin-light green preparation. $\times 50$
- Fig. 10. Oocyte at the tertiary yolk stage. Bouin's solution and Heidenhain's haematoxylin-light green preparation. $\times 30$
- Fig. 11. Oocyte at the maturation stage. Bouin's solution and Heidenhain's haematoxylin-light green preparation. $\times 21$
- Fig. 12. Fertilized egg. Allen-Bouin's solution and Delafield's haematoxylin-eosin preparation. *gd*, germ disc in the two-cell stage. $\times 24$



K. Takano: Egg formation and follicular changes in *Lebistes*

PLATE II

- Fig. 13. Highly magnified figure of the peripheral region from the same specimen as Fig. 5. $\times 600$
- Fig. 14. Highly magnified figure of the peripheral region of the oocyte at the primary yolk stage. Weber's solution and PAS preparation. $\times 580$
- Fig. 15. Follicle cells attached to the oocyte in the early phase of peri-nucleolus stage. Allen-Bouin's solution and Heidenhain's haematoxylin-light green preparation. *fc*, follicle cell. $\times 1510$
- Fig. 16. Dividing follicle cells found in the oocyte of the peri-nucleolus stage. Allen-Bouin's solution and Delafield's haematoxylin-eosin preparation. $\times 1490$
- Fig. 17. Follicular epithelium showing intra-oocyte protuberances and dividing follicle cell seen in the oocyte of the oil drop stage. Allen-Bouin's solution and Heidenhain's haematoxylin-light green preparation. $\times 1490$
- Fig. 18. Follicular epithelium and dividing follicle cell in the oocyte of the primary yolk stage. Bouin's solution and Heidenhain's haematoxylin-light green preparation. $\times 1490$
- Fig. 19. Follicular epithelium in the oocyte of the tertiary yolk stage (under) adjacent to that of the oocyte at maturation stage (upper). Bouin's solution and Heidenhain's haematoxylin-light green preparation. $\times 1260$
- Fig. 20. Vascular fibrous membrane enclosed an early developing embryo. Carnoy's solution and Delafield's haematoxylin-eosin preparation. *bc*, blood cell. $\times 1260$



K. Takano: Egg formation and follicular changes in *Lebistes*