



HOKKAIDO UNIVERSITY

Title	STUDIES ON THE MATURATION OF SALMONID FISHES-II. : CHANGES IN THE TESTIS OF THE MASU SALMON, ONCORHYNCHUS MASOU, DURING ANADROMOUS MIGRATION
Author(s)	HIROI, Osamu; 広井, 修; YAMAMOTO, Kiichiro et al.
Citation	北海道大學水産學部研究彙報, 20(4), 252-263
Issue Date	1970-02
Doc URL	https://hdl.handle.net/2115/23400
Type	departmental bulletin paper
File Information	20(4)_P252-263.pdf



STUDIES ON THE MATURATION OF SALMONID FISHES-II. CHANGES
IN THE TESTIS OF THE MASU SALMON, *ONCORHYNCHUS MASOU*,
DURING ANADROMOUS MIGRATION

Osamu HIROI* and Kiichiro YAMAMOTO*

In the preceding report of this series (Hiroi & Yamamoto, 1968), the authors described that the male chum salmon which are destined to die after their first breeding accomplish their maturation during a very short period of 1 to 2 months of their anadromous migration. The course of maturation in the male chum salmon proceeds synchronously in all lobules in a testis. Within a cyst all of the germ cells develop exactly together, but the development of germ cells is different from cyst to cyst in a testicular lobule. In matured testes only a few spermatogonia of somewhat deformed nature are detectable. The intralobular somatic cells show cytoplasmic vacuolization during the period of active spermiogenesis, and the interstitial cells appear to reveal some changes during the anadromous migration.

The Masu salmon, *Oncorhynchus masou*, are also destined to die after their mating, but they show several ecological characteristics different from those of the chum salmon. Many of the male fish live in rivers throughout their lifetime while others, together with most of the females, migrate into the sea. The males in rivers take two full years to mature, but some of them show precocious maturation and discharge milt when one year old. On the other hand, the migrated males live in the sea more than one year and then they return to rivers for breeding. The maturing fish ascend the rivers very early to breed and live in there for a long time of 4 to 5 months until they mature to breed (Oono, 1933; Ooshima, 1957; Osanai & Ōtsuka, 1967). Therefore, it is very interesting to study the maturational processes in the Masu salmon in comparison with those in the chum salmon. The present paper reports some histological observations on the testis of the Masu salmon during anadromous migration.

Before proceeding further, we wish to express our hearty thanks to Messrs. Minoru Osanai and Teruhiko Awakura of the Hokkaido Salmon Hatchery, for their friendly facilities in collecting the fish used in the present study. Thanks are also due to the Japanese Conservational Society of Fisheries Resources for the grant of research fund.

* *Laboratory of Freshwater Fish Culture, Faculty of Fisheries, Hokkaido University*
(北海道大学水産学部淡水増殖学講座)

Material and Methods

Thirty males of the Masu salmon, *Oncorhynchus masou*, during their anadromous migration were used as materials for the present study. Twenty-seven of them were captured in the coastal sea off Shimamaki or in the Chiwase River, south-western Hokkaido, during the period from July 1964 until September 1965. Additional samplings were caught in the succeeding two years, one fish each being collected in the Chiwase River, in the coastal sea off Fukushima, and in the Moheji River near Kamiiso, southern Hokkaido. The specimens used in the present study are represented in Table 1. Besides these 30 fish, 2 immature young males at the final step of their down-stream migration were caught in the mouth of the Moheji River in May 1967 and employed for histological examination of fairly immature testes.

For histological observations, testes were dissected out from the fish immediately after their capture, cut into small pieces, and fixed in Bouin's fluid.

Table 1. Characters of the Masu salmon sampled for the histological study of the testis during anadromous migration

Locality of capture	Date of capture	Number of specimens collected	Stage in testicular maturity
Shimamaki	Dec. 24 '64 Jan. 23 '65 Mar. 9 '65	6 6 1	Late multiplication stage
Fukushima	Mar. 18 '67	1	
Shimamaki	Apr. 1 '65 Apr. 23 '65	2 2	
	Apr. 23 '65	4	Spermatocyte stage
Moheji	Mouth of river (brackish water) May 24 '66	1	Sperm-formation stage
Chiwase	Mid-stream (fresh water) July 17 '64 July 21 '65 July 25 '67 Aug. 10 '65	1 1 1 1	
	Sep. 27 '65	1	Ripe stage
	Sep. 27 '65	2	Spent stage
	Total	30	

Paraffin sections of 5–6 μ in thickness were stained with Delafield's hematoxylin-eosin or with Heidenhain's iron hematoxylin-light green.

In order to make quantitatively clear the degree of maturity of the testes, the maturity factor (testis weight \times 100 / body weight) was estimated for each fish. In addition, a percent ratio of the amount of mature spermatozoa to the total germinal elements of the testis was calculated by the method described in the preceding report (Hiroi & Yamamoto, 1968) so as to give more precise expression to the degree of testicular maturity.

Observations

The testes of the present species, like those of the chum salmon (Hiroi & Yamamoto, 1968), are situated dorsal to the gut and ventro-lateral to the air bladder as paired bodies. Associated with the progress of maturation, the testes change their color from translucent greyish white to opaque milky white, and transform from filamentous bodies into broad, thick and elongated ones. Short gonoducts extend behind from the posterior ends of the testes and unite into a common duct which has an outer opening on the urogenital papilla independently from the anus. The genital system of the present species coincides in anatomical features with those of the other salmonid fishes described by Parker (1943) and Henderson (1967).

Histological changes of the testis during anadromous migration

As shown in Table 2, a histological survey on the testes of the collected salmon fairly indicates that the maturity of testes in terms of spermatogenetic phases proceeds in its degree simultaneously with the progress of anadromous migration of the fish.

In the testes of immature fish collected in the coastal sea during the period from December till April, all the germ cells were the spermatogonia in the resting or in the mitotic phases (Figs. 2 and 10–13). They are found to occur singly or in clusters of two to eight cells bound by a connective tissue element (Fig. 13). The clustered spermatogonia measure 7–10 μ in diameter while the singly located ones are 10–14 μ in dimension and usually surrounded by the cytoplasmic sheets of its associated follicle cells. The nucleus of the clustered cells is generally round in form, 6 to 8 μ in size, and embedded with two to four nucleoli (1–2 μ) and also with many chromatin granules (Fig. 13), while that of the singly located spermatogonia varies from round to elliptical in form and 7–13 μ in size (Figs. 10 and 11). The testes are composed of lobules surrounded by a connective tissue wall. The lobules, except a small empty space in the center, are filled with spermatogonia and intralobular somatic cells (Fig. 2). This stage may be designated as late multiplication stage.

Table 2. Stages in the germ cells found in the testis of each specimen

Locality	Calendar month	Number of fish examined	Spermatogonia	Spermatocytes	Spermatids	Spermatozoa
Coastal sea	December	6	+			
			+			
			+			
			+			
	January	6	+			
			+			
			+			
			+			
	March	2	+			
			+			
	April	8	+			
			+			
			+			
			+			
			+	+		
			+	+		
			+	+		
Mouth of river	May	1	+	+	+	+
Mid-stream	July	3	+	+	+	+
			+	+	+	+
			+			
	August	1	+	+	+	+
	September	3	+			+
			+			+
			+			+

The mark, +, shows the presence of the germ cell indicated on the top of each column.

In two fish out of six collected in December in the coastal sea, several testis-ova were found mixed with the spermatogonia in their testes. These cells measure from 100 to 125 μ in diameter, showing the early peri-nucleolus stage of oocyte development (Fig. 3).

Four fish were caught in the coastal sea in late April, one to two months before entering the river. A certain number of cysts composed of primary spermatocytes were first found in their testes intermingling with spermatogonial cysts (Tables 1 and 2; Fig. 4). Thus, the testes are named "spermatocyte stage". In this maturational stage, every testicular lobule is composed of several cysts containing a large number of the spermatogonia of the same size and same maturational phase. In general the cystic spermatogonia have a small amount of cyto-

plasm and are indistinct in cellular boundary. Their nucleus is round in form and 5 to 5.5μ in size, with two to four nucleoli and several chromatin threads strongly stained with hematoxylin (Fig. 14). The spermatogonia, large in size and singly located, are still present in the lobules, but they become fewer in number than before. The primary spermatocytes in the present species show a synaptic process similar in morphology as that in the chum salmon (Hiroi & Yamamoto, 1968). They are characterized by the presence of the nucleus whose chromatins are aggregated in one pole as a large mass (Figs. 14-16). The development of primary spermatocytes from spermatogonia shows a tendency to occur synchronously in each cyst but variously in different cysts. Testicular lobules become more distinct in the circular arrangement of the cysts and larger in size than those in the preceding phase.

In the testes of a fish captured in May in the mouth of river, germ cells of every maturational stage from spermatogonia to spermatozoa were seen in the lobules. The stage of the testis is designated as sperm-formation stage. Most of the germ cells are observed in the form of cysts (Fig. 5) while singly located spermatogonia are rarely encountered in testicular lobules. The spermatogonial cysts are various in size, consisting of 4-32 cells (Figs. 14 and 23-25). After synapsis the primary spermatocytes are divided into two cells of the same size (Figs. 15-17). The secondary spermatocytes are about the same in morphological feature as the primary spermatocytes except the difference in size (Figs. 18 and 19). The former measure $3-4\mu$ in the diameter of their nucleus while the latter have their nucleus of $5.2-6\mu$ in dimension. Spermatids are round in shape and 2.2 to 2.5μ in nuclear size (Figs. 20 and 21). They develop into spermatozoa and finally the cysts come to rupture and release mature spermatozoa which are seen in the lumen of testicular lobules without any regular arrangement. The head of mature spermatozoon is round or elliptical in form and $2\times 2.2\mu$ in size (Fig. 22). In the present species, just as in the chum salmon (Hiroi & Yamamoto, 1968), all the spermatocytes in each of the cysts proceeded during their maturation into mature spermatozoa at a quite synchronous pace.

The testes of all fish collected in July and August in the mid-stream were also at the sperm-formation stage, and mature spermatozoa were found more or less in every testicular lobule (Table 2). With an increase in amount of mature spermatozoa, testicular lobules become larger in size. When the value of testicular maturity exceeds 30 %, some of the lobules become to fuse into far larger lobules, one of the events in a consecutive metamorphosis of testis prepared for shedding sperms (Fig. 6). Dividing spermatogonia become small in number as the testicular maturation advances. When the value of testicular maturity exceeds 50%, cysts of spermatogonia become undetectable in all the testicular lobules,

whereas in most cases large singly located spermatogonia at resting phase are found along the lobule wall (Fig. 6). They are 8 to 12 μ in size with the nucleus of 7 to 11 μ in diameter, and are seen singly or in the form of small clusters less than 3 cells (Figs. 27 and 28).

A breeding male caught in the mid-stream in September was provided with testes full of mature spermatozoa and could discharge the milt easily when stripped (Ripe stage) (Fig. 7). The testicular lobules of the organ became large in size due to the fusion of the lobules, and the lobule wall became thicker (Fig. 33) in comparison with those of maturing fish (Fig. 32). Spent males still retain a small amount of spermatozoa in their testes (Spent stage) (Fig. 8). The testes are shrunk markedly owing to the release of the greater part of the spermatozoa, and their lobule walls are decreased in thickness (Fig. 34). In the mature and spent testes, spermatocytes and spermatids are no more present, but a small number of spermatogonia are still obviously detectable along the inside of the lobule wall (Figs. 29-31). The spermatogonia do not show any significant changes in their size and morphological characteristics in comparison with those found in the testes of late phase of the sperm-formation stage.

On the other hand, in May 1966, 2 young males were caught just at the final step of their down-stream migration. In the testes of these fish, there were found a large number of spermatogonia in resting or mitotic phases scattered among compact stromal cells. The spermatogonia are present independently each other without forming any clusters and enclosed by respective follicle cells (Early multiplication stage) (Figs. 1 and 9). They are round or elliptical in form and 11 \times 12 to 13 \times 15 μ in size, being the largest of the spermatogonia found in the testis through all the stages of maturation. The nucleus is elliptical in form and 7 \times 9 to 10 \times 13 μ in size, with a large round nucleolus of 2-3 μ in diameter and with chromatin granules stained deeply with hematoxylin (Fig. 9).

Morphological changes of somatic cells with the maturation of salmon testis

In the testes of the multiplication stages, spermatogonia are enveloped with a cytoplasmic sheet of follicle cells having respective flat rod-shaped nuclei ranging from 1.5 \times 8 to 2 \times 11 μ in size (Figs. 9-11, 13, 15 and 35). Besides these somatic cells, another kind of somatic cells was found in the testes. They were various in size and were dispersed among the germ cell components. The nucleus of the cells was triangular or elliptical in shape and 4 \times 4 to 4 \times 10 μ in size, with one or two nucleoli of irregular elliptical form strongly stained with hematoxylin (Figs. 36 and 37). The future of the cells concerned with germ cell maturation, however, could not be followed in a maturing testis.

In matured testes two types of somatic cells can be noticed besides blood cells

and connective tissue cells: one type is intralobular somatic cells which are present inside of the testicular lobules; the other is interstitial cells which exist in interlobular spaces of the testes.

Intralobular somatic cells

During the period of testicular maturation from the spermatocyte stage to the ripe stage, most of the intralobular somatic cells situated along the lobule wall have each a nucleus of triangular or elliptical shape (Figs. 24, 32 and 33). They show a weak affinity to hematoxylin and become larger in size than those in the late multiplication stage (5×5 – $6 \times 12 \mu$) (Fig. 33). Thus, the cells appear to be much functional during the period of testicular maturation. In the testes of the spent stage, however, the nucleus of the cells is elliptical in form and is smaller in size (4×6 – $6 \times 9 \mu$) than that found in the maturing testes, showing comparatively strong affinity to hematoxylin (Fig. 34). No intralobular somatic cells show any morphological evidence of phagocytosis for the residual spermatozoa as far as the authors observed.

Interstitial cells

Interstitial cells are present in interlobular spaces as clusters of several cells. In the testes of the late multiplication stage, the cells have an elliptical nucleus, which is 1.2×2 to $3 \times 6 \mu$ in size and embedded with a nucleolus of

Table 3. Body length, body weight, testis weight
100/body weight) of the

Stage in testicular maturity	Calendar month	Number of specimens collected	Body length (cm) Mean (Range)
Early multiplication stage	May	2*	14.6 (13.3–15.9)
Late multiplication stage	December	5	34.0 (31.8–35.2)
	January	6	35.0 (31.0–41.6)
	March	2	37.9 (33.6–42.2)
	April	4	39.3 (28.5–46.5)
Spermatocyte stage	April	4	39.8 (30.5–48.2)
Sperm-formation stage	May	1	38.7
	July	3	50.0 (44.8–54.2)
	August	1	41.6
Ripe stage	September	1	46.5
Spent stage	September	2	48.0 (44.5–51.5)

* This includes two immature young fish collected

irregular contour, and they are enclosed with a very thin cytoplasm, showing an indistinct boundary (Fig. 39).

During the period of testicular maturation from the spermatocyte to the ripe stage, the interstitial cells increase in size for the nucleus (4×6 – $5 \times 9 \mu$) and in amount for the cytoplasm (Fig. 40). This implies that the cells in these stages of testicular maturation are more active in function than those in the multiplication stage. The feature of the interstitial cells seems to remain unchanged after it enters the spent stage (Fig. 41).

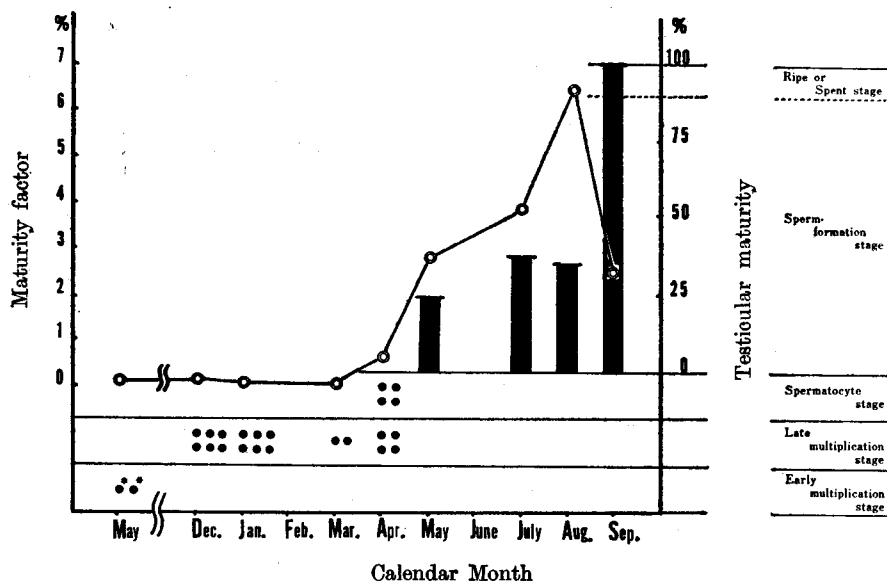
Changes in the testicular maturity and in the maturity factor of the salmon during anadromous migration

Changes in the testicular maturity and in the mean value of the maturity factor (testis weight $\times 100$ / body weight) during anadromous migration are revealed in Text-figure 1. The maturity factors in the salmon which have testes of the late multiplication stage are in all cases below 0.5 % (Table 3). Since the young fish captured at the end of their down-stream migration have testes of the early multiplication stage, multiplication of spermatogonia in this species seems to have proceeded gradually through the long period of feeding migration in the sea. Fish holding testes in the spermatocyte stage show maturity factors (0.6 %) slightly increased in comparison with those of the fish collected in the preceding months (Table 3). The testes collected during the months from May till August are in the sperm-formation stage, and the maturity factor of the

and the maturity factor (testis weight \times
male fish examined

Body weight (g) Mean (Range)	Testis weight (g) Mean (Range)	Maturity factor (%) Mean (Range)
37.5 (29.4–45.6)	0.01	0.03
574 (480–700)	0.9 (0.5–1.6)	0.2 (0.1–0.3)
621 (460–1085)	0.5 (0.5–1.0)	0.06 (0.04–0.1)
1075 (650–1500)	0.8 (0.6–1.0)	0.09 (0.07–0.1)
908 (310–1360)	2.6 (2.2–3.3)	0.4 (0.2–0.7)
1165 (390–1880)	6.1 (2.6–8.9)	0.6 (0.5–0.8)
950	26.5	2.8
2290 (1340–3530)	84.0 (65.0–112)	4.2 (2.2–5.6)
1100	69.9	6.4
1500	44.4	2.9
1425 (1130–1720)	33.2 (29.4–37.0)	2.4 (2.2–2.5)

in the final step of the down-stream migration.



Text-figure 1. Relation between the change of the maturity factor and that of the testicular maturity during the anadromous migration of *O. masou*. The black spot, ●, and black bar represent the degree of the testicular maturity. Mean value of maturity factor is shown by the mark, ⊙.

* These two fish collected in May were at the final step of their down-stream migration.

fish shows a rapid increase during that period. The mean values of the maturity factor are 2.8, 4.2 and 6.4 % in May, July and August, respectively. It is worthy to note that, even in the fish sampled at the mouth of rivers, the testes are evidently in the sperm-formation stage and their testicular maturity is 25 %, which in turn indicates that the male Masu salmon, as in the case of chum salmon (Hiroi & Yamamoto, 1968), commences ascending into the rivers with a considerable number of spermatozoa in their testicular lobules. In the above-mentioned cases the change in the maturity factor tends to be in parallel with that of the testicular maturity. On the contrary, in testes of the ripe stage and of the spent stage, the mean value of the maturity factor is clearly lower than that of the fish in sperm-formation stage, being 2.9 and 2.4 %, respectively. The decrease in the maturity factor of these fish must be attributable mainly to the release of the milt, because the fish examined were caught during or following their breeding activities.

Discussion

Throughout the year, testicular lobules in *Salmo gairdnerii* (Weisel, 1943; Oota *et al.*, 1965) contain resting spermatogonia, which exist singly or in the form of

cysts. During the recovery period of the testes, the spermatogonia undergo mitotic divisions and proliferate. Most of the daughter spermatogonia consecutively develop into the sperms, whereas some spermatogonia remain in the resting state as a reservoir for the next generation of germ cells. The existence of such spermatogonia in the testis was described by Nishikawa (1955) in *Oryzias latipes*, by Nishikawa and Kubota (1959) in *Misgurnus anguillicaudatus*, by Barr (1963) in *Pleuronectes platessa* and by Stanley *et al.* (1965) in *Gobius paganellus* which perform annual mating. These spermatogonia are called "residual spermatogonia". Similar cells were revealed by Henderson (1962) in *Salvelinus fontinalis*, but he called them "primordial germ cells".

Sockeye salmon (Weisel, 1943) and chum salmon (Hiroi & Yamamoto, 1968), destined to die soon after their first breeding, have testes which are essentially similar in structure to those of many fishes which show cyclic reproduction and the testes hold residual-like spermatogonia. The spermatogonia, however, show degeneration and deformation at the time of full maturation.

As demonstrated in the present study, residual-like spermatogonia were also found in the maturing and mature testes of the Masu salmon. However, any sign of degeneration or deformation was not found in the spermatogonia during their breeding period. In this connection, it is interesting to note that some male parrs of Masu salmon which had survived after their first breeding in fresh water, actually repeated the next cycle of spermatogenesis (Kosaka, 1969).

In some salmonid fishes such as *Salmo gairdnerii* (Robertson, 1958), *O. nerka* (Weisel, 1943) and *O. keta* (Hiroi & Yamamoto, 1968), intralobular somatic cells in the testes showed cytoplasmic vacuolization during the final step of gonadal maturation. In the Masu salmon such cytoplasmic vacuolization was not recognized in the intralobular somatic cells during the testicular maturation. However, they assume to show a hypertrophic appearance and decreasing affinity in the nucleus to hematoxylin. In spent testes, however, the cells become atrophic with an evident decrease in nuclear size. These facts may suggest that the intralobular somatic cells in the present species play an important role in testicular maturation extending a certain influence on germ cells as the Sertoli cells in higher vertebrates do (Witschi, 1956; Gorbman & Bern, 1962; Roosen-Runge, 1962; Bloom & Fawcett, 1964).

The multiplication of spermatogonia in the Masu salmon begins soon after the smolts run down into the sea, and it goes on during their feeding migration in the sea. The maturational processes of the germ cells start in late April, a little before or just at the time when the fish begin to ascend the rivers, and continue during the anadromous migration to end by September or October. Thus, the testicular maturation in the Masu salmon proceeds very gradually and is evidently prolonged

in comparison with that of the chum salmon whose testicular maturation is accomplished for only one or two months during anadromous migration (Hiroi & Yamamoto, 1968), and is shorter than that of the rainbow trout which spends 8 to 10 months for testicular maturation (Oota *et al.*, 1965).

Summary

Changes in the testes of the Masu salmon, *Oncorhynchus masou*, during the anadromous migration were investigated histologically in the present study.

1. The period of active multiplication of spermatogonia in this fish seems to begin soon after the sea-run migration of the fish, and continues before one or two months of their anadromous migration. The maturing fish arrived at the mouth of rivers have testes with mature spermatozoa. After entering the rivers, the maturation of germ cells proceeds rapidly toward the actual breeding in September.

2. The processes of testicular maturation are divided into six successive stages based on germ cell stages. These 6 stages are early multiplication stage, late multiplication stage, spermatocyte stage, sperm-formation stage, ripe stage and spent stage. The testicular maturity expressed by the relative amount (%) of spermatozoa calculated out of the total amount of germinal elements in the testis seems to fit for the quantitative representation of late maturation stages, and the maturity factor (testis weight \times 100/body weight) appears suitable to show the outline of sexual cycle.

3. The course of maturation in the present species proceeds synchronously in all cells within a cyst, but it is different more or less from louble to louble. Mature spermatozoa are accumulated in the lobular lumen without any regularity in arrangement. A considerable number of spermatogonia remain as residual spermatogonium in the mature and spent testes.

4. The intralobular somatic cells change clearly along with their sexual maturation. Their nucleus increases in size during the maturation phase, while it decreases markedly in size and shows strong affinity to hematoxylin after breeding. The interstitial cells show hypertrophy during the actual maturation phase, and they remain unchanged in that state even after breeding.

5. Several testis-ova of the early peri-nucleus stage were found among the germinal elements in the testicular louble of a male fish.

Literature

- Barr, W. A. (1963). The endocrine control of the sexual cycle in the plaice, *Pleuronectes platessa* (L). III. The endocrine control of spermatogenesis. *Gen. Comp. Endocrinol.* 3, 216-225.
- Bloom, W. & Fawcett, D. W. (1964). *A Textbook of Histology.* (p. 550-583). Philadelphia

- and London; W. B. Saunders, Co.
- Gorbman, A. & Bern, H.A. (1962). *A Textbook of Comparative Endocrinology*. (p. 247-296). New York and London; John Wiley & Sons, Inc.
- Hann, H. W. (1927). The history of the germ cells of *Cottus bairdii* Girard. *J. Morph.* **43**, 427-497.
- Henderson, N. E. (1962). The annual cycle in the testis of the eastern brook trout, *Salvelinus fontinalis* (Mitchill). *Can. J. Zool.* **40**, 632-641.
- (1967). The urinary and genital systems of trout. *J. Fish. Res. Bd. Canada* **24**, 447-449.
- Hiroi, O. and Yamamoto, K. (1968). Studies on the maturation of salmonid fishes-I. Changes in the testis of the chum salmon, *Oncorhynchus keta*, during anadromous migration. *Bull. Fac. Fish., Hokkaido Univ.* **19**, 173-184.
- Ishida, R., Takagi, K. & Arita, S. (1961). Criteria for the differentiation of mature and immature forms of chum and sockeye salmon in northern seas. *Int. North. Pac. Fish. Comm. Bull.* **5**, 27-47.
- Kosaka, S. (1969). Changes in the testis of the precocious male parr of *Oncorhynchus masou*. Oral report at the General Meeting of Japanese Society of Scientific Fisheries, Tokyo, Japan, April 1969.
- Nishikawa, S. (1955). Histological observations on the seasonal spermatogenetic cycle of a medaka, *Oryzias latipes* (T. & S.). *Zool. Mag.* **65**, 203-206. (In Japanese with English summary)
- & Kubota, Z. (1959). Notes on the seasonal cycle in the spermary of a loach, *Misgurnus anguillicaudatus* (Cantor). *La Kromosomo* **41**, 1379-1384. (In Japanese with English summary)
- Oono, I. (1933). "A life cycle of Masu salmon, *Oncorhynchus masou* (Brevoort), lived in Hokkaido." *SAKE MASU IHOU* **5**, 13-26. (In Japanese)
- Ooshima, M. (1957). Studies on the dimorphic salmon, *Oncorhynchus masou* (Brevoort) and *Oncorhynchus rhodurus* Jordan & Megregor, found in Japan and adjacent territories. 79p. Sapporo; Nire Shobo. (In Japanese)
- Oota, I., Yamamoto, K., Takano, K. & Sakaguchi, T. (1965). Studies on the maturing process of the rainbow trout, *Salmo gairdnerii irideus* - II. Maturation of the testis of a one-year old fish. *Bull. Jap. Soc. Sci. Fish.* **31**, 597-605. (In Japanese with English summary)
- Osanai, M. & Ôtsuka, M. (1967). Ecological studies on the Masu salmon, *Oncorhynchus masou* (Brevoort), of Hokkaido. I. Morphology and spawning habit of the Masu salmon which ascends the river. *Sci. Rep. Hokkaido Fish Hatchery* **22**, 17-32. (In Japanese)
- Parker, J. B. (1943). The reproductive system of the brown trout (*Salmo fario*). *Copeia* **1943**, 90-91.
- Robertson, O. H. (1958). Accelerated development of testis after unilateral gonadectomy, with observations of the normal testes of rainbow trout. *Fish. Bull.* **127**, 9-30.
- Roosen-Runge, E. C. (1962). The process of spermatogenesis in mammals. *Biol. Rev.* **37**, 343-377.
- Stanley, H., Chieffi, G. & Botte, V. (1965). Histological and histochemical observations on the testis of *Gobius paganellus*. *Z. Zellforsch.* **65**, 350-362.
- Weisel, G. F. (1943). A histological study of the testes of the sockeye salmon (*Oncorhynchus nerka*). *J. Morph.* **73**, 207-229.
- Witschi, E. (1956). *Development of Vertebrates*. (p. 14-23). Philadelphia and London; W. B. Saunders, Co.

Explanation of Plates

PLATE I

Fig. 1. Testis of an immature young fish captured on May 27 at the mouth of the Moheji River. The large spermatogonia and many somatic cells are present in the testis and they show no definite lobular arrangement. Note mitotic figures in a few spermatogonia. $\times 360$

Fig. 2. Testis of a maturing fish caught on December 25 in the coastal sea off Shimamaki. Within testicular lobules there is found a central lumen. $\times 480$

Fig. 3. Testis of a maturing fish, which contains several testis-ova. $\times 240$

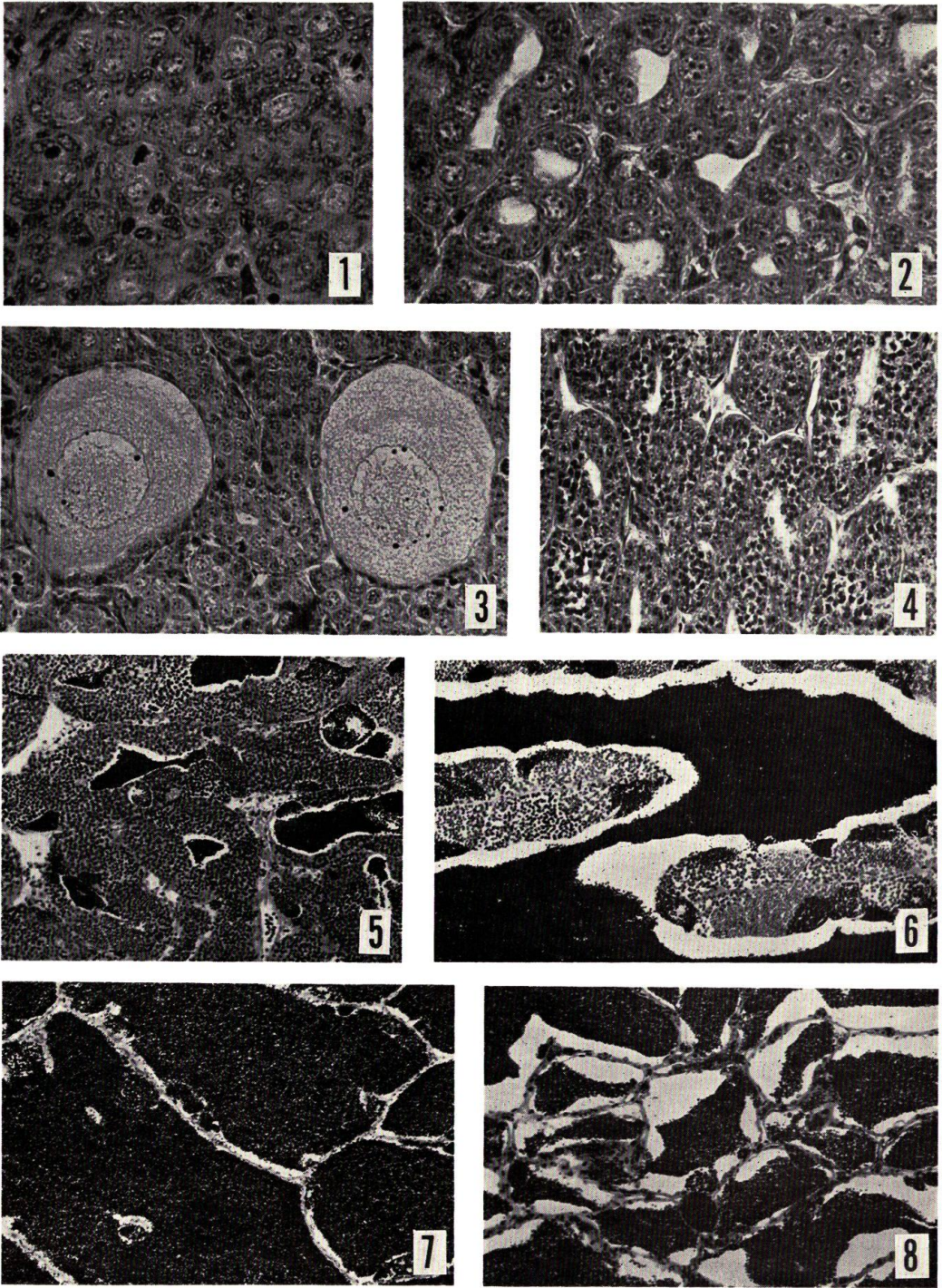
Fig. 4. Testis of a maturing fish collected on April 23, in which the cysts of spermatocytes are discernible. $\times 240$

Fig. 5. Testis of a maturing fish obtained on May 24 at the mouth of the Moheji River. A large number of germ cells in spermatogenesis and a small amount of mature spermatozoa are seen in each testicular lobule. $\times 120$

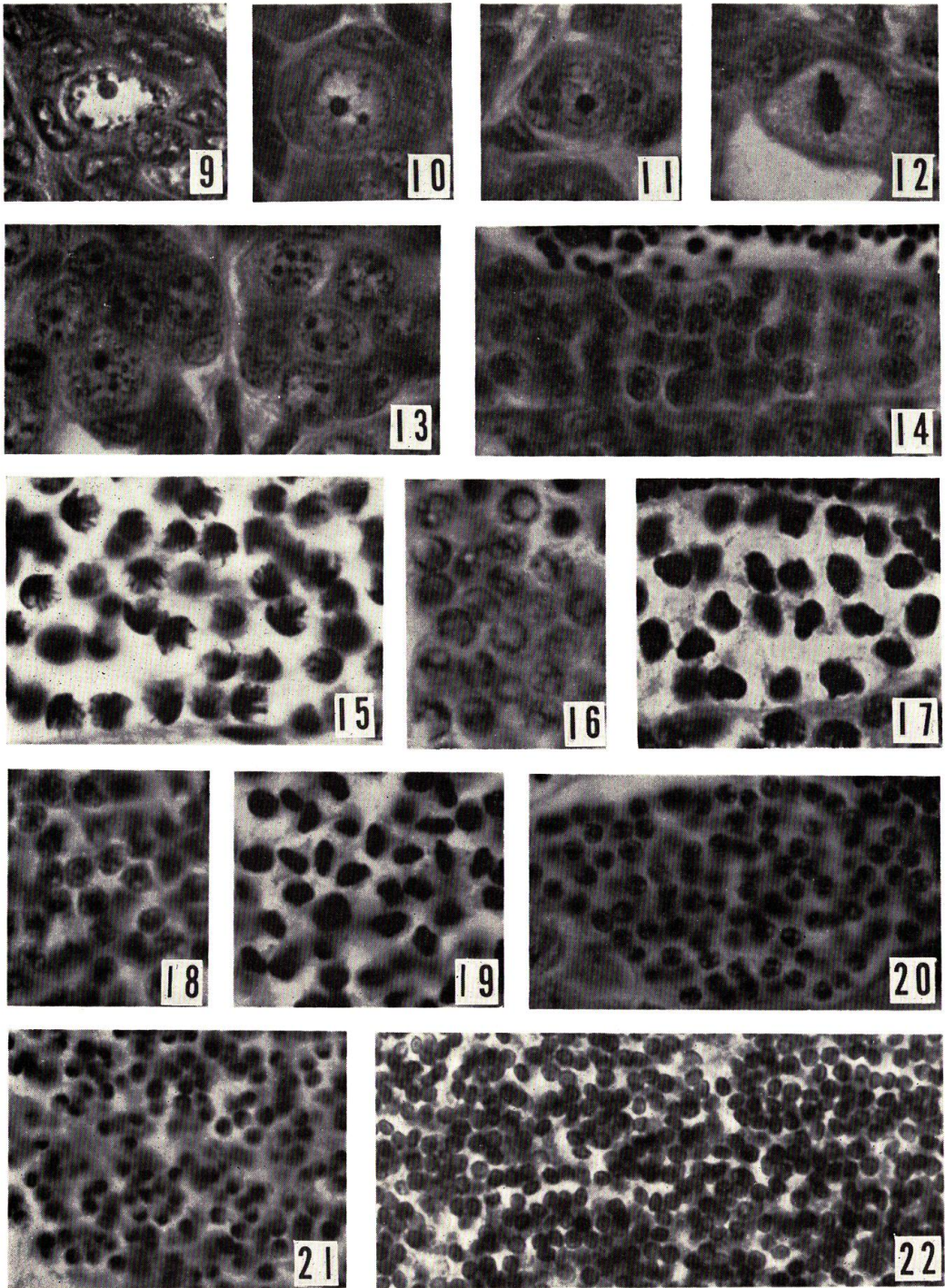
Fig. 6. Testis of a maturing fish held on August 10 in the mid-stream of the Chiwase River. The lobules increase in size and are occupied by a large amount of spermatozoa. $\times 120$

Fig. 7. Testis of a mature fish captured on September 27 in the mid-stream of the Chiwase River. The lobules are entirely filled with spermatozoa. $\times 120$

Fig. 8. Testis of a spent fish caught on September 27 in the mid-stream of the Chiwase River. The lobules shrink as a result of shedding spermatozoa. $\times 120$



O. HIROI & K. YAMAMOTO : Changes in the testis of the Masu salmon



O. HIROI & K. YAMAMOTO : Changes in the testis of the Masu salmon

PLATE II

All figures are of the same magnification at 1200 times.

Fig. 9. Resting spermatogonium present in the testis of an immature young fish captured on May 27 at the mouth of the Moheji River.

Figs. 10-13. Germ cells found in the testicular lobules of maturing fish caught on December 25 and April 1. 10 and 11, resting spermatogonia; 12, spermatogonium in mitosis; 13, spermatogonia in clusters.

Figs. 14-22. Germ cells in the process of spermatogenesis. 14, a cyst of spermatogonia; 15 and 16, primary spermatocytes in the post-synaptic stage; 17, primary spermatocytes in the first maturation division; 18, secondary spermatocytes; 19, secondary spermatocytes in division; 20 and 21, spermatids in spermiogenesis; 22, mature spermatozoa.

PLATE III

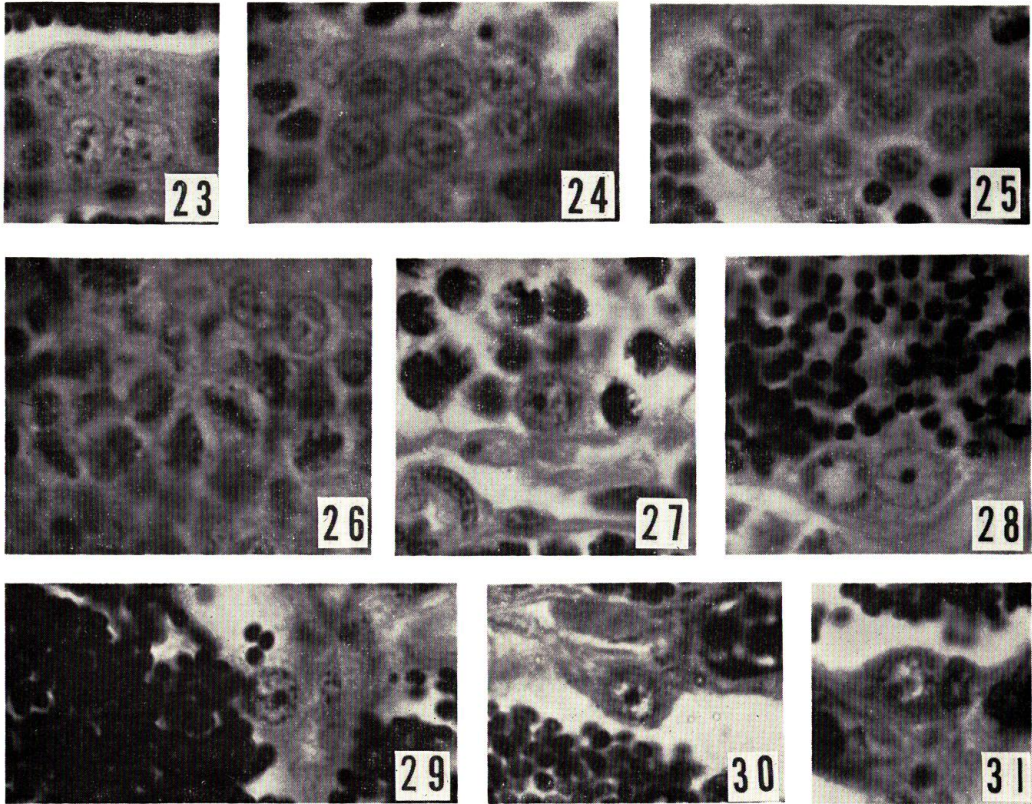
All figures are of the same magnification at 1200 times.

Figs. 23-27. Testes of maturing fish captured on May 24 at the mouth of the Moheji River and on July 25 in the mid-stream of the Chiwase River. Spermatogonial clusters of different sizes (23-25), spermatogonia in mitotic division (26), and a single spermatogonium present in the cyst of spermatocytes (27) are found.

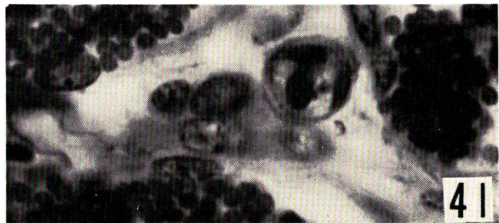
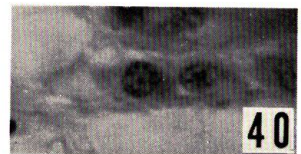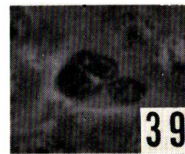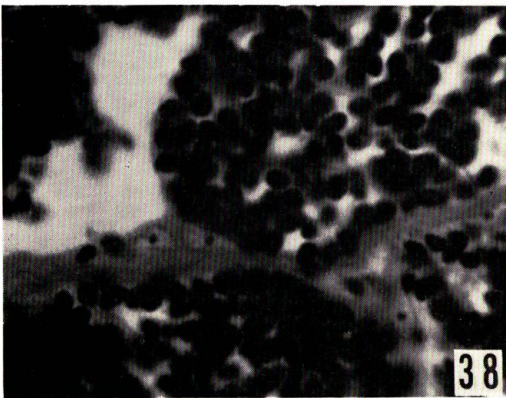
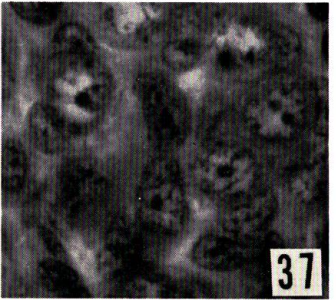
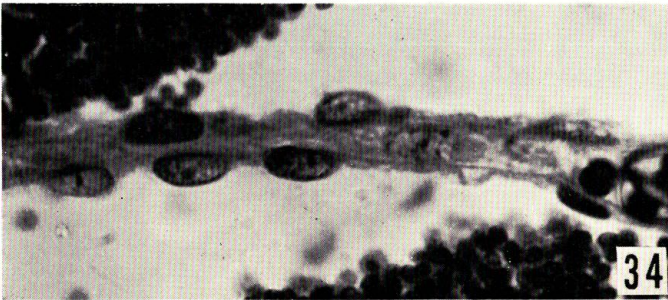
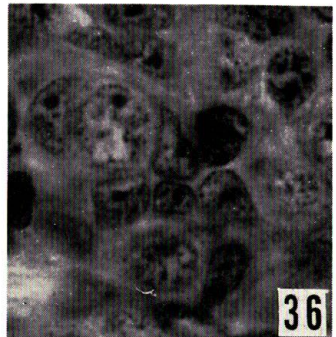
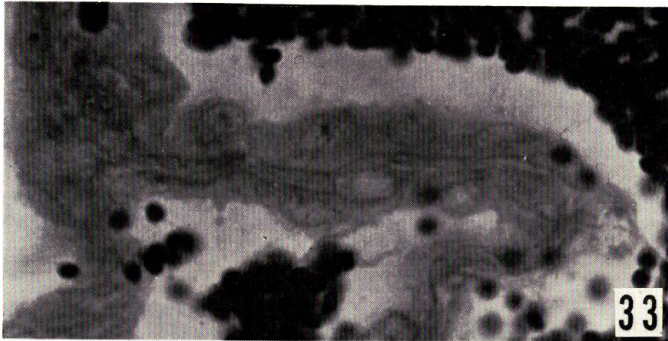
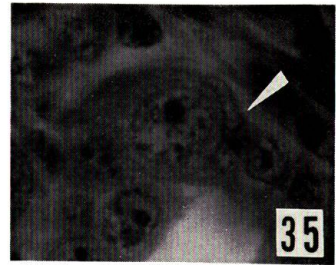
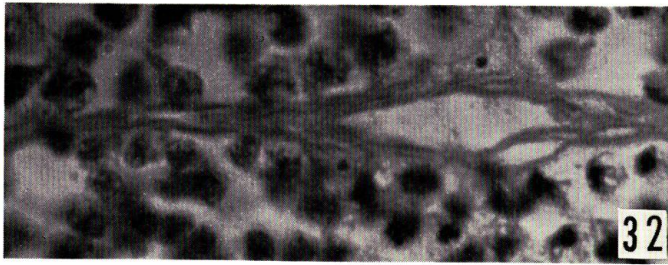
Fig. 28. Testis of a maturing fish obtained on August 10 in the mid-stream of the Chiwase River. Residual spermatogonia are present in the cyst of spermatids.

Fig. 29. Testis of a mature fish caught on September 27. A spermatogonium is located singly along the lobule wall.

Figs. 30 and 31. Residual spermatogonia present in the testes of spent fish collected on September 27 in the mid-stream of the Chiwase River.



O. HIROI & K. YAMAMOTO : Changes in the testis of the Masu salmon



O. HIROI & K. YAMAMOTO : Changes in the testis of the Masu salmon

PLATE IV

All figures are of the same magnification at 1200 times.

Fig. 32. Lobule wall in the testis of a maturing fish captured on May 24 at the mouth of the Moheji River.

Fig. 33. Testis of a mature fish obtained on September 27 in the mid-stream of the Chiwase River. Note the thick lobule walls and the large intralobular somatic cells.

Fig. 34. Lobule wall and intralobular somatic cells found in the testis of a spent fish collected on September 27 in the mid-stream of the Chiwase River.

Figs. 35-37. Intralobular somatic cells in the testes of maturing fish caught on December 25 in the coastal sea off Shimamaki. 35, follicle cells (arrow); 36 and 37, intralobular somatic cells other than follicle cells, situated among the spermatogonia in testicular lobules.

Fig. 38. Intralobular somatic cells found in the testis of a maturing fish captured on August 10 in the mid-stream of the Chiwase River.

Fig. 39. Interstitial cells present in the testis of a maturing fish caught on December 25 in the coastal sea off Shimamaki.

Fig. 40. Interstitial cells in the testis of a maturing fish held on July 25 in the mid-stream of the Chiwase River.

Fig. 41. Interstitial cells found in the testis of a spent fish.