



# HOKKAIDO UNIVERSITY

Title	Masculinization of the Gonad of Juvenile Guppy, <i>Poecilia reticulata</i> , Induced by 11-Ketotestosterone
Author(s)	TAKAHASHI, Hiroya; 高橋, 裕哉
Citation	北海道大學水産學部研究彙報, 26(1), 11-22
Issue Date	1975-06
Doc URL	<a href="https://hdl.handle.net/2115/23543">https://hdl.handle.net/2115/23543</a>
Type	departmental bulletin paper
File Information	26(1)_P11-22.pdf



## Masculinization of the Gonad of Juvenile Guppy, *Poecilia reticulata*, Induced by 11-Ketotestosterone

Hiroya TAKAHASHI\*

### Abstract

The masculinizing effects of 11-ketotestosterone, a potent natural androgen produced in teleosts, were determined in the guppy, *Poecilia reticulata*, using all-female broods obtained by crossing sex-reversed males with normal females. The androgen added to rearing water at concentrations of 25 and 50  $\mu\text{g}/\text{l}$  caused a complete transformation of ovaries into testes in 100% of the genetic females treated for 35 days following birth. The sex-reversed testes scarcely retained intersexual traits at the end of the treatment and continued their development thereafter to assume regular and typical aspects of mature testes, though a few of them were accompanied with a marked scantiness of germ cells showing a tendency to sterilization. The treatments evoked, in addition, a deficiency in the sperm duct formation in the region caudal to the gonad in treated fish. The androgen at a concentration of 10  $\mu\text{g}/\text{l}$  was effective only partially in eliciting the sex reversal of ovaries, but the resultant testes were seen to be functional with a well-formed sperm duct system, being much more potent in the masculinizing action than testosterone at the concentration of 50  $\mu\text{g}/\text{l}$  which could merely modify the ovarian development in some treated females.

In recent years accumulated evidence has come to denote that 11-ketotestosterone, which was isolated first from the plasma of male salmon by Idler et al.<sup>1)</sup>, may be one of the natural androgens occurring in teleostean fishes.<sup>2)</sup> In the sockeye salmon, *Oncorhynchus nerka*, the androgen has been shown to be clearly androgenic not only in inducing a precocious development of male secondary sex characters but also in stimulating spermatogenesis in treated males.<sup>3)</sup> In the medaka, *Oryzias latipes*, the hormone acts as androgenic on secondary sex characters, being three times more active than testosterone in producing those of the male type in female fish.<sup>4)</sup>

According to Hishida and Kawamoto<sup>5)</sup>, 11-ketotestosterone can cause, besides the masculinization of external characters, a sex reversal of the gonad of genetic females of the medaka if given with the food during the period of gonadal sex differentiation, thus leading to the conclusion that the androgen may be most potent in the masculinizing actions among the natural steroids of teleost fishes. The present writer also confirmed the androgenic effects of 11-ketotestosterone on the gonad and other sex characters in the female guppy, *Poecilia reticulata*, fed after birth on a diet containing androgen.<sup>6)</sup> Quite recently, however,

\* Laboratory of Fresh-Water Fish-Culture, Faculty of Fisheries, Hokkaido University  
(北海道大学水産学部淡水増殖学講座)

Hackmann<sup>7)</sup> revealed that, in a cichlid *Hemihaplochromis multicolor*, 11-ketotestosterone added to aquarium water did not have influence on gonadal sex differentiation though it was efficient in provoking a precocious development of male secondary sex characters.

The present paper deals with the occurrence of a complete masculinization of ovaries of the guppy, *Poecilia reticulata*, kept after their birth in rearing water containing 11-ketotestosterone, demonstrating a much prominent androgenic potency of the hormone.

### Material and Methods

All-female broods of *Poecilia reticulata* of the yellow variety bred in our laboratory were employed in the present study. The all-female broods were obtained by mating adult virgin females with sex-reversed males produced by prenatal androgen treatment.<sup>8)</sup> Newly delivered fish of the same brood were divided into control and experimental groups, which were kept each in their respective aquaria with 8 liters of constantly aerated water at 23–25°C under the natural light condition. They were daily fed on crumbled commercial fish food.

Androgen treatments were performed by rearing juvenile guppies in water solutions of hormones. Crystalline 11-ketotestosterone and testosterone were previously dissolved in 95% ethanol at the concentration of 400 µg/ml, and stored in the refrigerator as stock solutions. For treating the fish, given amounts of the stock solution were added gently into the aquaria every third day after the aquarium water was changed entirely. The control fish were raised in water with only the solvent ethanol added at the concentration of 1 ml of ethanol per 8 liters of rearing water.

Two series of experiments were carried out each using juvenile guppies of a single, all-female brood. In the first series, two experimental groups of 16 fish each were treated with 11-ketotestosterone and testosterone, respectively, at a concentration of 50 µg/l for 35 days from the day following birth. Another group of 16 fish served as controls. In the second series consisting of a control and three experimental groups of 20 females each, two experimental groups were treated with 11-ketotestosterone at concentrations of 10 and 25 µg/l during the period from the day following birth to 35 days of age, and another group at a concentration of 50 µg/l for 35 days beginning 10 days after birth. After the cessation of treatment in both series of experiments, the fish were successively maintained under ordinary conditions until the time of fixation.

For histological examinations of the gonad, control and experimental fish were killed 20 and 69 days after birth in the first series of experiments and by 35, 45, 70 and 90 days of age in the second one. Besides, some fish of each brood were sacrificed at the start of every experiment and served as initial

controls. The fish were fixed without dissection in Bouin's fluid, and were trimmed properly after fixation so as to leave the gonad and gonoduct intact in the peritoneal cavity. Serial paraffin sections were cut frontally at 8-10  $\mu$  in thickness and stained with Delafield's hematoxylin and eosin.

### Results

Several preliminary series of experiments showed that 11-ketotestosterone, when added in rearing water at a concentration of 50  $\mu\text{g}/\text{l}$ , had a remarkable androgenic effect on the gonad of juvenile guppies: the testes of treated males were evidently more advanced in spermatogenetic development as compared with those of control males, whereas gonads of genetic females were mostly inverted into those of testicular structures through intersexual phases. In contrast, methyltestosterone and testosterone propionate, both added into aquarium water at the same concentration as above, were without effect on the sex differentiation of the gonad of female guppies, only evoking slight modifications of ovarian functions which were quite similar to those described in a previous paper<sup>6</sup>).

The results obtained in the present study are summarized in Table 1. In the two series of experiments, control groups exclusively consisting of females showed a normal ovarian development (Fig. 2). An examination of the initial controls designated that the ovarian nature of the gonads was definite at the time of birth (Fig. 1).

The treatment with testosterone at the concentration of 50  $\mu\text{g}/\text{l}$  failed to cause any sexual modification of the gonads of treated females. The gonads examined 20 days after the start of treatment were distinctly of ovarian structures with no signs of intersexual development, though an atypical expansion of the ovarian cavity was the common feature for all these ovaries (Fig. 3). After the discontinuance of the treatment lasting for 35 days after birth, the ovaries of treated fish seemed to advance their development rather normally. The fish autopsied 34 days after the end of treatment had ovaries and oviducts which were quite similar in developmental degrees to those of the controls, although the ovary of only 1 out of 5 fish was observed to be slightly modified by the occurrence of regressive changes of a few mature oocytes.

On the contrary, 11-ketotestosterone at the same concentration as testosterone exerted an exceeding androgenic influence on the gonads of treated females. The treatment could not completely prevent the development of oocytes in the affected ovaries. However, the ovaries examined 20 days after the start of treatment revealed notable changes characterized by unusual compactness of their stromal elements, frequent appearances of spermatogenetic cell cysts among the surviving auxocytes, and a complete arrest of the ovarian cavity formation (Figs. 4 and 5). In some sections of these gonads, sperm duct anlagen were seen

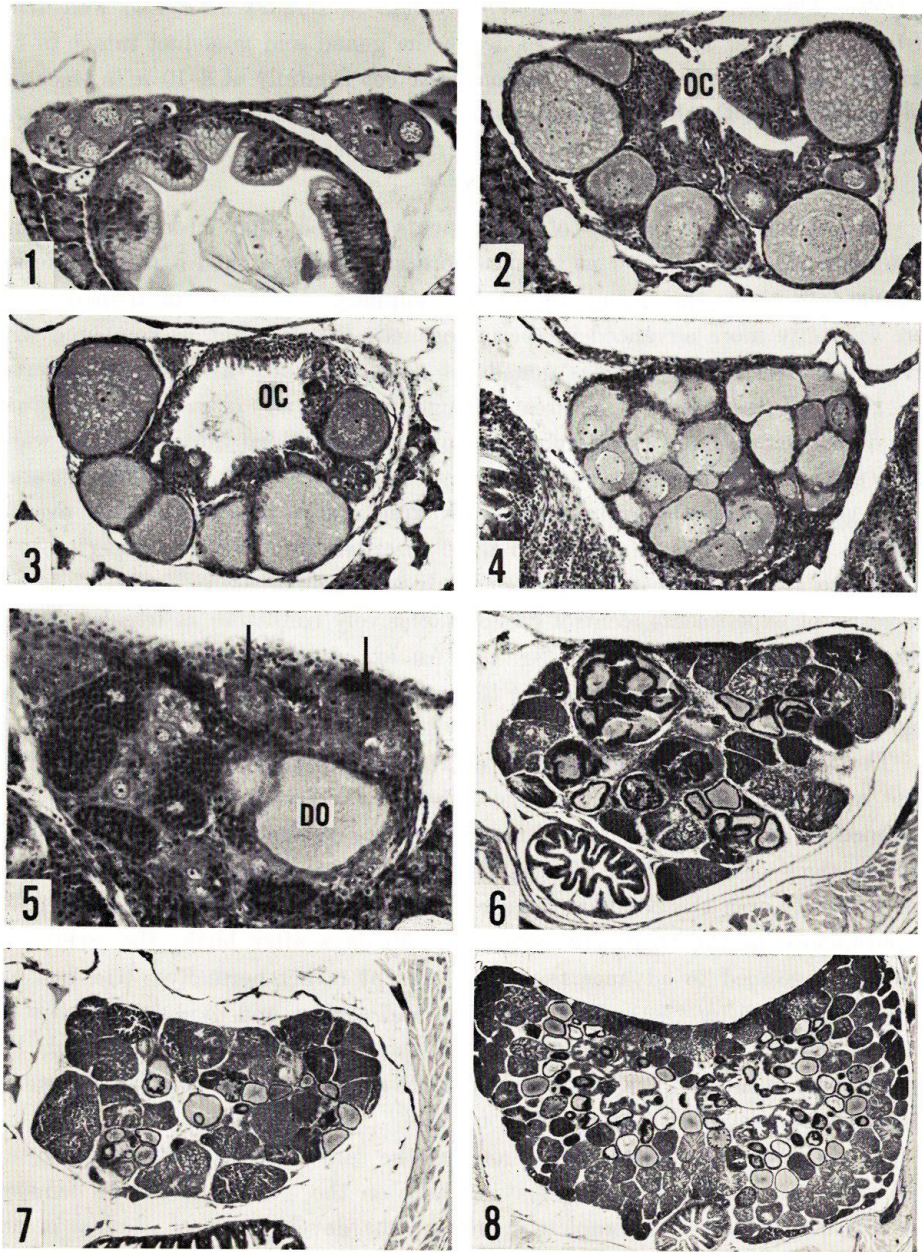


Fig. 1. Cross section of paired ovaries of a control guppy fixed the day following birth.  $\times 175$ .

Figs. 2-5. Cross sections of ovaries of a control female guppy (Fig. 2) and gonads of genetic female fish treated with testosterone ( $50 \mu\text{g}/\text{l}$ , Fig. 3) and 11-ketotestosterone ( $50 \mu\text{g}/\text{l}$ , Figs. 4 and 5) for 20 days from the day after birth. Note the complete absence of

TAKAHASHI: Sex reversal of guppy by 11-ketotestosterone

Table 1. *Effects of testosterone (T) and 11-ketotestosterone (KT) added to rearing water on sexual development of the guppy of female unisexual broods.*

Treatment	No. of fish treated	Age of fish (Days after birth)			Sex distribution <sup>1)</sup>					Total
		at start	at end	at fixation	♀ <sub>1</sub>	♀ <sub>2</sub>	♀	♂ <sub>2</sub>	♂ <sub>1</sub>	
T (50 µg/l)	16	1	35	20 69	10 4	1				10 5 (15)
KT (50 µg/l)	16	1	35	20 69			9	6		9 6 (15)
—	16	—	—	20 69	8 6					8 6 (14)
KT (10 µg/l)	20	1	35	36 71 89		1 2 2	2 2 4		3(1) 2(1)	6 6 6 (18)
KT (25 µg/l)	20	1	35	36 71 89				7(2) 5(1) 6	1	7 6 6 (19)
KT (50 µg/l)	20	10	45	46 70 90		5 7 6	2			7 7 6 (20)
—	20	—	—	36 71 89	6 4 7					6 4 7 (17)

1) ♀<sub>2</sub>, female with normal ovary; ♀<sub>1</sub>, female with ovary showing modified oocyte development and slight intersexual features; ♀, fish with distinct intersexual gonad; ♂<sub>2</sub>, male with testis showing deficiencies in sperm duct formation; ♂<sub>1</sub>, male with defined testis and sperm ducts. Numerals in parentheses designate the number of males with testes displaying sterilized features.

to be differentiated in the stroma tissue (Fig. 5). However, gonoducts were in no case detectable to exist in the region caudal to the gonad proper and also in the ventromedian ridge<sup>6)</sup> which had been induced to be formed by the influence of

ovarian cavity in 11-ketotestosterone-affected ovaries. Arrows in Fig. 5 demonstrate differentiating sperm ducts in the stroma tissue. DO, degenerating oocyte; OC, ovarian cavity. Figs. 2-4, × 115; Fig. 5, × 200.

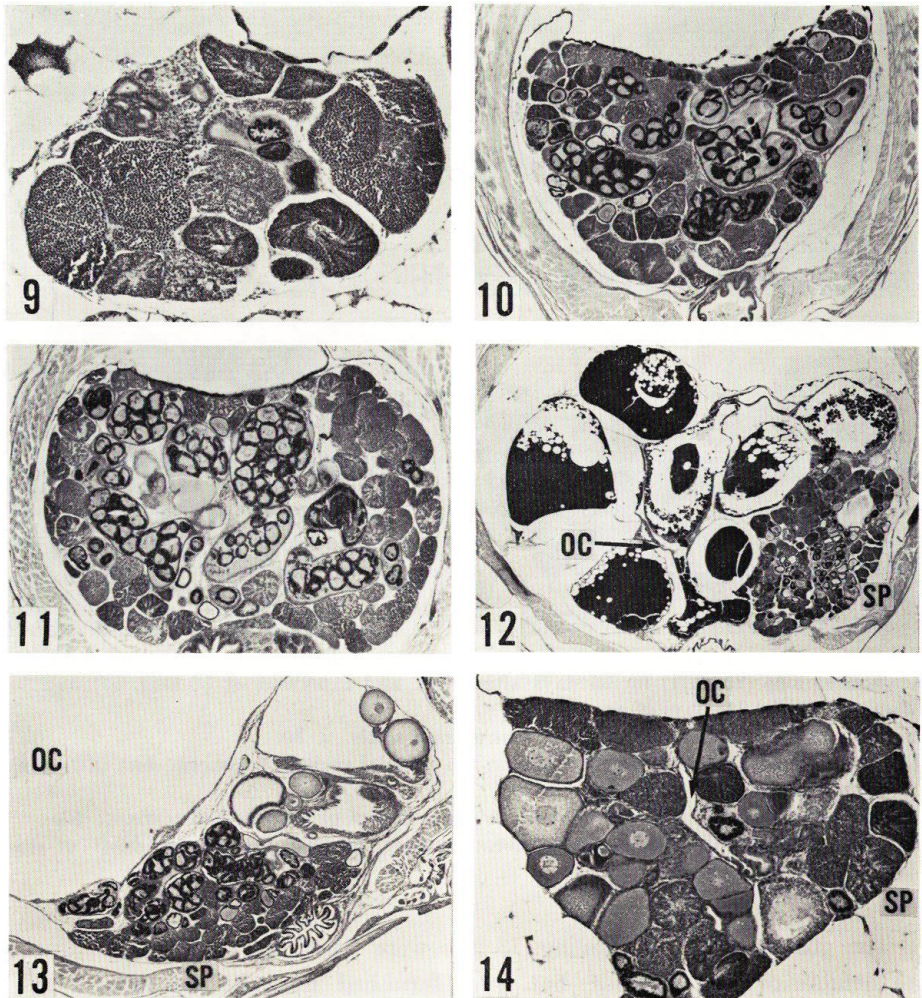
Figs. 6-8. Cross sections of gonads of genetic female guppies 34 days after the end of 11-ketotestosterone (50 µg/l) treatment lasting for 35 days after birth (Figs. 6 and 7) and of a normal male of the same age (Fig. 8). Fig. 6, × 55; Fig. 7, × 35; Fig. 8, × 30.

androgen. All 6 genetic females observed at 69 days of age were provided with testicular gonads retaining no notable remnants of ovarian nature (Fig. 6). The testes had advanced the spermatogenesis to yield spermatophores released into well-differentiated efferent ducts and main sperm ducts. Generally speaking, however, the testes were smaller in size, being furnished with a smaller number of germ cell cysts including the spermatogonial ones, and were sometimes irregular in arrangements of germ cell cysts and sperm ducts (Fig. 7), as compared with those of normal males of the same age (Fig. 8). In addition, the sex-reversed males were in all cases deficient in the extratesticular sperm ducts, as was seen in the fish examined at 20 days of treatment.

In the second series of experiments, a complete sex reversal of the gonad of treated females was elicited following the treatment with 11-ketotestosterone at the concentration of 25  $\mu\text{g}/\text{l}$  for the first 35 days of their postnatal life. All of 19 genetic females surviving the treatment had well defined testes. The testes examined at the end of treatment were small in size and frequently displayed some atypical features in the arrangement of germ cell cysts and sperm ducts (Fig. 9), with scars of degenerated oocytes only on rare occasions. The testes of affected fish subsequently continued to develop to attain nearly normal histoarchitecture of the guppy testis (Figs. 10 and 11, compare with Fig. 8).

In 3 out of 19 fish treated, however, the morphogenesis and development of the testis were seen to have occurred either on the right side or on the left side of the bilateral genital ridges, no gonadal structures being present on the contralateral side (Fig. 15). In 3 others, germinal elements were almost missing in the gonadal region where only some sperm ducts existed beneath the dorsal coelomic wall (Fig. 16). Moreover, in 18 out of 19 fish examined, the region caudal to the testes was entirely devoid of sperm ducts including the so-called seminal vesicle and vas deferens. In a few cases, sperm ducts were undetectable even in the caudal-most part of the testis proper (Fig. 17). The remaining fish had a fully formed sperm duct system which had opened into the urogenital sinus. The testis of this fish showed certain disorders in the production of mature spermatophores, which was accompanied with the appearance of disorganized spermatophores released in the sperm ducts (Fig. 18).

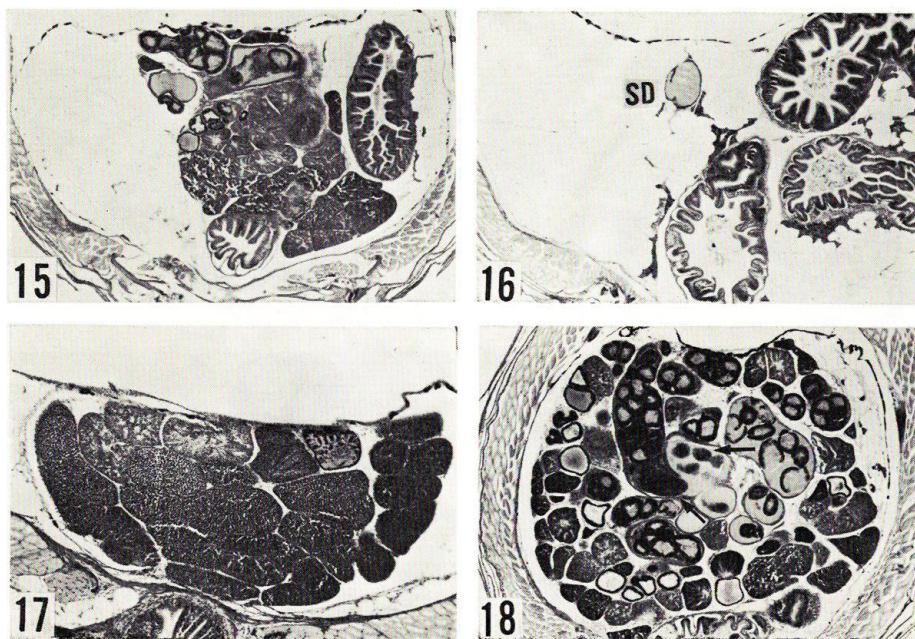
11-Ketotestosterone at the concentration of 10  $\mu\text{g}/\text{l}$  provoked a wide variety of changes in the sexual development of the guppy treated for 35 days after birth. In 5 out of 18 genetic females examined at, and after, the end of treatment, the gonads were decisively of testicular structure with no notable ovarian characters, though the gonads of 2 of them were extensively deficient in germinal elements. In the sex-reversed males, the sperm ducts were well differentiated to connect the testis to the urogenital sinus, which indicated a complete sex reversal of genetic females into functional, fertile males.



Figs. 9–11. Cross sections of sex-reversed testes of genetic female guppies treated with 11-ketotestosterone ( $25 \mu\text{g}/\text{l}$ ) for 35 days after birth and examined at 36 (Fig. 9), 71 (Fig. 10) and 89 (Fig. 11) days of age, revealing complete sex reversal and nearly normal testicular development. Fig. 9,  $\times 70$ ; Figs. 10 and 11,  $\times 30$ .

Figs. 12 and 13. Cross sections of intersexual gonads of genetic female guppies treated with 11-ketotestosterone ( $10 \mu\text{g}/\text{l}$ ) for 35 days after birth and examined at 89 days of age. Fig. 13 shows a part of the gonad modified by an extraordinary expansion of the ovarian cavity with germinal elements localized along its wall. OC, ovarian cavity; SP, spermatogenic tissue. Fig. 12,  $\times 13$ ; Fig. 13,  $\times 20$ .

Fig. 14. Cross section of an intersexual gonad of a genetic female guppy treated with 11-ketotestosterone ( $50 \mu\text{g}/\text{l}$ ) for 35 days from 10 days after birth and killed at the end of treatment. OC, ovarian cavity; SP, spermatogenic tissue.  $\times 60$ .



All figures are cross sections through gonads of genetic female guppies treated with 11-ketotestosterone ( $25 \mu\text{g}/\text{l}$ ) for 35 days after birth and examined at 36 (Fig. 17) and 71 (Figs. 15, 16 and 18) days of age.

Fig. 15. A unilateral development of sex-reversed testis.  $\times 30$ .

Fig. 16. A complete lack of germ cells in the gonadal region. A sperm duct (SD) with secretion exists in the region.  $\times 30$ .

Fig. 17. A deficiency in sperm ducts in the caudal part of sex-reversed testis.  $\times 55$ .

Fig. 18. A dissociation of spermatophores (arrows) released into sperm ducts of sex-reversed testis.  $\times 35$ .

The gonads of the remaining 13 fish were essentially ovarian in structure with definite ovarian cavities, but were furnished more or less with cysts of spermatogenetic cells localized in some parts of the gonads and with fragments of sperm ducts existing near the wall of ovarian cavities. Extragonadal gonoducts were seen to be ill-developed sperm ducts in histology and the ventromedian ridges of the male type were always induced to occur. In most of the modified ovaries, oocytes could develop into maturation and, in 2 fish killed at 89 days of age, were undergoing embryogenesis. However, it was a general characteristic of these gonads that the oocytes had mostly suffered by regressive changes after maturation (Fig. 12) or remained undeveloped and lay together with spermatogenetic tissues along the wall of extraordinarily expanded ovarian cavities (Fig. 13).

In the experiment with 11-ketotestosterone at the concentration of  $50 \mu\text{g}/\text{l}$  beginning 10 days following birth, the gonads of affected females were still predominantly ovarian in aspect at the end of treatment lasting for 35 days, ex-

cept for 2 fish in which their gonads were strongly intersexual (Fig. 14). The ovarian cavity became narrowed to be slit-like lumina extending dorsoventrally in the median part of the gonads, and fragmentary sperm ducts appeared sparsely in the stroma. The extragonadal duct system was observed to be suppressed and masculinized in development. Following the cessation of treatment, the gonads of treated guppies developed to augment their ovarian characters and rendered their heterosexual germinal elements inconspicuous. Oocytes proceeded to mature, but in most cases eventually came to undergo severe degenerative changes such as a dissolution of their components and an extrusion of them into the ovarian cavity, their changes being quite identical with those described previously for the guppies subjected to methyltestosterone treatments<sup>9</sup>).

An androgenicity of 11-ketotestosterone was evidently expressed in the development of anal fins and in the body growth of treated genetic females. An elongation of anal fin rays became noticeable in the fish of the 25  $\mu\text{g}/\text{l}$  group prior to 5 days after birth. A formation of gonopodia was observed in these fish to be completed within 15 days of treatment. Even with androgen at 10  $\mu\text{g}/\text{l}$ , the treated fish became provided with typical gonopodia until 30 days after birth. Testosterone at 50  $\mu\text{g}/\text{l}$  was also capable of inducing a differentiation of gonopodia, but was insufficient to achieve their complete formation within 35 days of treatment. An increment of the body length was markedly checked by 11-ketotestosterone at 50 and 25  $\mu\text{g}/\text{l}$  which was effective in causing gonadal masculinization. The mean body lengths at the end of treatment lasting for 35 days after birth were 11.5, 15.1 and 18.2 mm, and those 34 days later were 14.4, 24.7 and 27.5 mm, in genetic females of 11-ketotestosterone 50  $\mu\text{g}/\text{l}$ , testosterone 50  $\mu\text{g}/\text{l}$  and control groups, respectively. Those with 11-ketotestosterone at 25 and 10  $\mu\text{g}/\text{l}$  and the control group were 13.2, 16.4 and 19.0 mm at the end of treatment and 14.8, 20.8 and 26.8 mm 34 days later, respectively. It was clear that the androgen-treated females could regain their body growth after the withdrawal of androgen to approach to the size of normal females if the androgen would influence the gonad insufficiently for causing complete masculinization.

### Discussion

In the guppy in which gonadal sex differentiation occurs at some period before birth, treatments with various androgenic steroids in varying ways have invariably failed to give rise to a complete sex reversal of the gonads of genetic females when the treatments are commenced after birth. Methyltestosterone<sup>6,9)</sup> and pregnenolone (=ethinyltestosterone)<sup>10)</sup>, both given orally, are admittedly androgenic in their effects on guppy gonads as well as on secondary sex characters, but their action is at most confined to the induction of intersexual gonads of high ratios in treated females. By administering methyltestosterone orally

to juvenile guppies for a long period of days, Clemens et al.<sup>11)</sup> found a sex ratio of 9 males to 1 female in a group of treated fish, but could not confirm the occurrence of a successful masculinization of genetic females. In the case of rearing juvenile guppies in water containing methyltestosterone at concentrations ranging from 100 to 500  $\mu\text{g}/\text{l}$ , Querner<sup>12)</sup> could not obtain any reversal of a sex differentiation of germ cells in affected ovaries.

It was reported in a previous paper<sup>6)</sup> that 11-ketotestosterone exerted only a weak androgenic action on the female gonads of the guppy when administered orally at the dosage of 200  $\mu\text{g}/\text{g}$  diet, being much less in the masculinizing action than methyltestosterone at the same dosage level. The results of the present study revealed, by contrast, that 11-ketotestosterone added to rearing water at concentrations of 25 and 50  $\mu\text{g}/\text{l}$  was strongly efficient in occasioning the masculinization of genetic females. At those concentrations of androgen, all of the treated fish with undoubted genetic sex of the female became to have gonads of definite testicular structure retaining no intersexual traits within 35 days of treatment beginning the day following birth. The resultant testes did not reveal any sign of restoration from the reversed sex to the original one after the treatment had been discontinued, but advanced their development to attain much regular and functional aspects. Such a case of complete masculinization of genetic female guppies has never been achieved heretofore by any way of hormone administration performed during the periods after birth of the fish, so far as the present writer knows.

A remarkable masculinizing effect of 11-ketotestosterone on teleostean gonads has been assured only in the medaka, *Oryzias latipes*, by Hishida and Kawamoto<sup>6)</sup>. They observed the sex reversal in 98.5% of genetic females fed on the diet containing androgen at a dose of 200  $\mu\text{g}/\text{g}$  throughout the period of gonadal sex differentiation, thus regarding 11-ketotestosterone as the most potent androgen among naturally occurring steroids in teleosts. In this regard it is interesting to note that the same hormone was reported to be without effect on the gonadal sex differentiation of a cichlid, *Hemihaplochromis multicolor*, even at a higher concentration of 500  $\mu\text{g}/\text{l}$  of rearing water than that employed in the present study.<sup>7)</sup>

The present case of complete masculinization of the guppy by 11-ketotestosterone is prominent among the hitherto reported cases in the sense that the treatment was started after the gonad had noticeably progressed in their development as ovaries and yet was capable to transforming the ovaries totally into testes. It is of special interest that the masculinization of stromal elements as well as germinal ones of the affected ovaries was directed competently by the influence of androgen, as manifested by the perfect arrest of the ovarian cavity formation and the induced differentiation followed by a rather regular development of intratesticular sperm ducts in the gonads of treated, genetic females. It seems worth

stressing here that the complete transformation of ovaries into testes in the guppy is invariably accompanied with the successful obstruction of the ovarian cavity formation. In this regard, 11-ketotestosterone seems to surpass the other androgens tested so far in androgenic action on the gonad of the guppy.

However, the complete masculinization of the gonad by androgen involved a deficiency in the extratesticular sperm duct system in most of the sex-reversed males. In the guppy, the formation of the gonoduct anlagen caudal to the gonad proper seems liable to be impeded by exogenous androgens; a defect in the gonoduct formation was observable also frequently in the fish fed on methyltestosterone especially at high dosages.<sup>6)</sup> Similar noxious influences on gonoduct formation of methyltestosterone and dehydroepiandrosterone acetate were noticed also in juvenile female guppies kept in water with the androgens.<sup>12)</sup> An excessive action of 11-ketotestosterone was disclosed also on the development of germinal elements of affected ovaries; some of them displayed a tendency to be sterilized by the treatment. The androgen at concentrations of 25 and 50  $\mu\text{g}/\text{l}$  seems to be too much potent to bring about a typical testicular development in treated fish. In fact, at a smaller concentration of 10  $\mu\text{g}/\text{l}$ , the androgen exerted a milder effect on the gonad and gonoduct, being capable of producing sex-reversed males with functional testes and sperm ducts, though a few of them still showed a marked scantiness of germ cells in their testes. However, since the androgen at 10  $\mu\text{g}/\text{l}$  level was not so effective as to incite the sex reversal in all treated females, 11-ketotestosterone may be most potent at some level of its concentration between 10 and 25  $\mu\text{g}/\text{l}$  in terms of potency for inducing a functional masculinization of the guppy by the treatment of the fish after birth.

The results of the present study together with those of preliminary ones demonstrated that testosterone, testosterone propionate, and methyltestosterone, tested at the same level of concentration and at the same time and duration of treatment as 11-ketotestosterone, were little efficient in causing even a partial sex reversal of genetic female guppies, though methyltestosterone was observed to act on ovaries more intensely than the other two androgens. A relative androgenic potency of methyltestosterone, a potent oral androgen, and 11-ketotestosterone, a natural steroid in teleosts, is reversed with the two different ways of hormone administration of feeding and immersion.<sup>6)</sup> The same was true for the induction of gonopodium differentiation in the anal fin and for the inhibition of body growth of genetic female guppies. Among the natural androgens which are known to occur in teleost fishes, 11-ketotestosterone seems to be much more active than testosterone in their androgenic actions on the gonad and secondary sex characters in the guppy as well as the medaka, *Oryzias latipes*<sup>4)</sup>.

### References

- 1) Idler, D.R., Schmidt, P.J. and Ronald, A.P. (1960). Isolation and identification of 11-ketotestosterone in salmon plasma. *Can. J. Biochem. Physiol.* **38**, 1053-1057.
- 2) Ozon, R. (1972). Androgens in Fishes, Amphibians, Reptiles, and Birds. p. 328-389. In Idler, D.R. (ed.), *Steroids in Nonmammalian Vertebrates*. 504p. Academic Press, New York and London.
- 3) Idler, D.R., Bitners, I.I. and Schmidt, P.J. (1961). 11-Ketotestosterone: an androgen for sockeye salmon. *Can. J. Biochem. Physiol.* **39**, 1737-1742.
- 4) Arai, R. (1967). Androgenic effects of 11-ketotestosterone on some sexual characteristics in the teleost, *Oryzias latipes*. *Annot. Zool. Japon.* **40**, 1-5.
- 5) Hishida, T. and Kawamoto, N. (1970). Androgenic and male-inducing effects of 11-ketotestosterone on a teleost, the medaka (*Oryzias latipes*). *J. Exp. Zool.* **173**, 279-284.
- 6) Takahashi, H. (1974). Modification of the development of female reproductive organs in the guppy, *Poecilia reticulata*, following androgen treatment in their juvenile period. *Bull. Fac. Fish. Hokkaido Univ.* **25**, 174-199.
- 7) Hackmann, E. (1974). Einfluss von Androgenen auf die Geschlechtsdifferenzierung verschiedener Cichliden (Teleostei). *Gen. Comp. Endocrinol.* **24**, 44-52.
- 8) Takahashi, H. (1975). Functional masculinization of female guppies, *Poecilia reticulata*, influenced by methyltestosterone before birth. *Bull. Japan. Soc. Sci. Fish.* **41**. (In press)
- 9) Miyamori, H. (1961). Sex modification of *Lebistes reticulatus* induced by androgen administration. *Zool. Mag.* **70**, 310-315. (In Japanese)
- 10) Mohsen, T. (1958). Masculinizing action of pregnenolone on female gonads in the cyprinodont, *Lebistes reticulatus* R. *Nature* **181**, 1074.
- 11) Clemens, H.P., McDermitt, C. and Inslee, T. (1966). The effect of methyl testosterone to guppies for sixty days after birth. *Copeia* **1966**, 280-284.
- 12) Querner, H. (1956). Der Einfluss von Steroidhormonen auf die Gonaden juveniler Poeciliiden. *Biol. Zentralbl.* **75**, 28-51.