



HOKKAIDO UNIVERSITY

Title	Dosage-Dependent Changes in the Effect of Oral Administration of Methyltestosterone on Gonadal Sex Differentiation in <i>Tilapia mossambica</i>
Author(s)	NAKAMURA, Masaru; 中村, 將
Citation	北海道大學水産學部研究彙報, 26(2), 99-108
Issue Date	1975-09
Doc URL	https://hdl.handle.net/2115/23550
Type	departmental bulletin paper
File Information	26(2)_P99-108.pdf



**Dosage-Dependent Changes in the Effect of Oral Administration
of Methyltestosterone on Gonadal Sex Differentiation
in *Tilapia mossambica***

MASARU NAKAMURA*

Abstract

The effects of androgen on gonadal sex differentiation in *Tilapia mossambica* were examined by daily oral administration of methyltestosterone at dosages of 50 and 1,000 $\mu\text{g/g}$ diet lasting for 19 and 44 days from 7 days after hatching.

When methyltestosterone at 50 $\mu\text{g/g}$ was given for 19 days, a complete sex reversal from female to male was obtained. Some germ cells in the gonads of possible genetic females underwent oogenesis despite the androgen treatment but were found to degenerate eventually. The formation of ovarian cavity did not occur. These gonads could differentiate eventually into defined testes with active spermatogenetic tissues and well-formed efferent ducts.

Methyltestosterone at 1,000 $\mu\text{g/g}$ administered for 19 days could not bring about a decisive sex reversal of the treated fish. In the affected ovaries, germinal and somatic elements developed quite similarly to those in controls. In the affected testes, the androgen treatment scarcely influenced the development of germ cells, but invariably induced the formation of ovarian cavity along the lateral wall of the testes. On the other hand, the same treatment, when prolonged for 44 days, induced the formation of efferent duct homologues without notable effects on the germ cell development in the gonads of possible genetic females, whereas it provoked not only the formation of ovarian cavity but also the occurrence of oocytes in the gonads of possible genetic males. Following the treatment, these gonads developed into intersexual ones of a peculiar tubular aspect which were composed of testicular tissues and ovarian ones with ovarian cavities both localized along atypically expanded efferent duct.

From the results, it was concluded that methyltestosterone is capable of inducing a complete masculinization of genetic females at a low dosage level (50 $\mu\text{g/g}$) and of exerting a paradoxical feminizing effect on the gonads of genetic males at a high dosage level (1,000 $\mu\text{g/g}$).

A functional masculinization of genetic females of a cichlid, *Tilapia mossambica*, has been achieved by Clemens and Inslee¹⁾ by feeding the fry on methyltestosterone mixed with food. In recent years, however, much confused results of androgen treatments have been demonstrated in various cichlid fishes concerning the modifications of gonadal sex differentiation.

In *Hemihaplochromis multicolor*, a "paradoxical" feminization was brought about by raising the fry in water containing methyltestosterone or testosterone propionate²⁾. The androgen-induced feminization was proved to be permanent and functional³⁾.

* *Laboratory of Fresh-Water Fish-Culture, Faculty of Fisheries, Hokkaido University*
(北海道大学水産学部淡水増殖学講座)

According to Reinboth⁴⁾, an oral administration of high doses of testosterone to the same cichlid for a long period of days evoked gonadal masculinization while the same treatment for a short period caused feminization. In *Tilapia mossambica*, *T. heudeloti* and *Cichlasoma biocellatum*, methyltestosterone and testosterone propionate revealed to have paradoxically a feminizing potency when added to rearing water⁵⁾. However, in *Haplochromis destotainesi*, testosterone and methyltestosterone favoured, though incompletely, male differentiation whether the androgens were added to water or were given with diet⁶⁾.

In a previous paper, the present writer demonstrated that an estrogen treatment can incite a complete feminization of genetic males of *T. mossambica* when it covers effectively the period of gonadal sex differentiation⁷⁾. The present study was undertaken first to determine whether the estrogen-sensitive period for the induction of feminization of the gonad in *T. mossambica* is also critical for an androgen treatment to induce masculinization, and second to investigate the amphisexual effect of androgen administered orally on a high dosage level for different lengths of days.

Before going further the writer wishes to express his sincere thanks to Emeritus Professor Kiichiro Yamamoto and Associate Professor Hiroya Takahashi, Faculty of Fisheries, Hokkaido University, for their kind guidance and encouragements given throughout the present study.

Material and Methods

The fry of *Tilapia mossambica* were collected, 5 days after hatching, from the mouth of an adult female bred in the laboratory. They were fed on a commercial dry food for carp culture until the start of each experiment. They were separated into one control and three experimental groups of 50-60 fry each at the start of experiments, and were kept each in a glass aquarium with 10 liters of well-aerated water at $22 \pm 2^\circ\text{C}$ under an artificial photoperiod of 14 hours light and 10 hours darkness. The fish of the 3 experimental groups were administered orally with methyltestosterone at dosages of 50 and 1,000 μg per g diet for periods of 19 and 44 days beginning 7 days after hatching. In all of the experiments, some of the treated and control fish were killed at the end of the treatment, and others were raised in ordinary conditions subsequently after the discontinuance of the treatment until the time of sacrifice, as indicated in Table 1.

For preparing the androgen-containing diet, crystalline methyltestosterone was dissolved previously in absolute alcohol at a constant dose. The stock solution was added to the food at doses of 50 and 1,000 μg per g diet. The diet was given to the fish once or twice a day throughout the experimental periods. The aquaria were cleaned and refilled with spring water generally once a week.

For histological observations, the gonads of experimental and control fish were fixed in Bouin's fluid at the end of the treatment and at intervals of 10 to 20 days thereafter. The gonads embedded in paraffin were cut serially at 8 μ in thickness and stained with Delafield's hematoxylin and eosin.

NAKAMURA: Methyltestosterone and sex differentiation in *Tilapia*

Table 1. Effects of oral administration of methyltestosterone (50-1,000 µg/g diet) on sex differentiation of *Tilapia mossambica*.

Treatment	Age after hatching (days)	No. of fish at start	Sex distribution**						(Total)
			♀ ₁	♀ ₂	♀ ₃	♀	♂ ₂	♂ ₁	
Exp. 1	25*	60			3			7	10
	35				5		5	10	
	50						10(6)***	10	
	65						10(6)***	10	
	100						5	5	
	229						3	3	
	(Total)			(8)			(40)	(48)	
Exp. 2	25*	60	5					5	10
	35		3				7		10
	50		3				7		10
	65		4				6		10
	105		4				4		8
	218		3				5	1	9
	(Total)		(22)				(29)	(6)	(57)
Exp. 3	35	50	1	9					10
	50*			8					8
	65			6					6
	218		2			3			5
	(Total)		(3)	(23)		(3)			(29)
Cont.	25	60	3					6	9
	35		5				5		10
	50		3				5		8
	65		6				9		15
	(Total)		(17)				(25)		(42)

* Hormone administration was discontinued at that age.

** ♀₁, females with normal ovaries; ♀₂, females with ovaries modified by the occurrence of efferent ducts; ♀₃, females with ovaries lacking the ovarian cavity; ♀, intersexes with ovarian and testicular tissues; ♂₂, males with testes modified by the formation of ovarian cavity; ♂₁, males with normal testes.

*** Numerals in parentheses show the number of fish having clusters of degenerated oocytes in the testes.

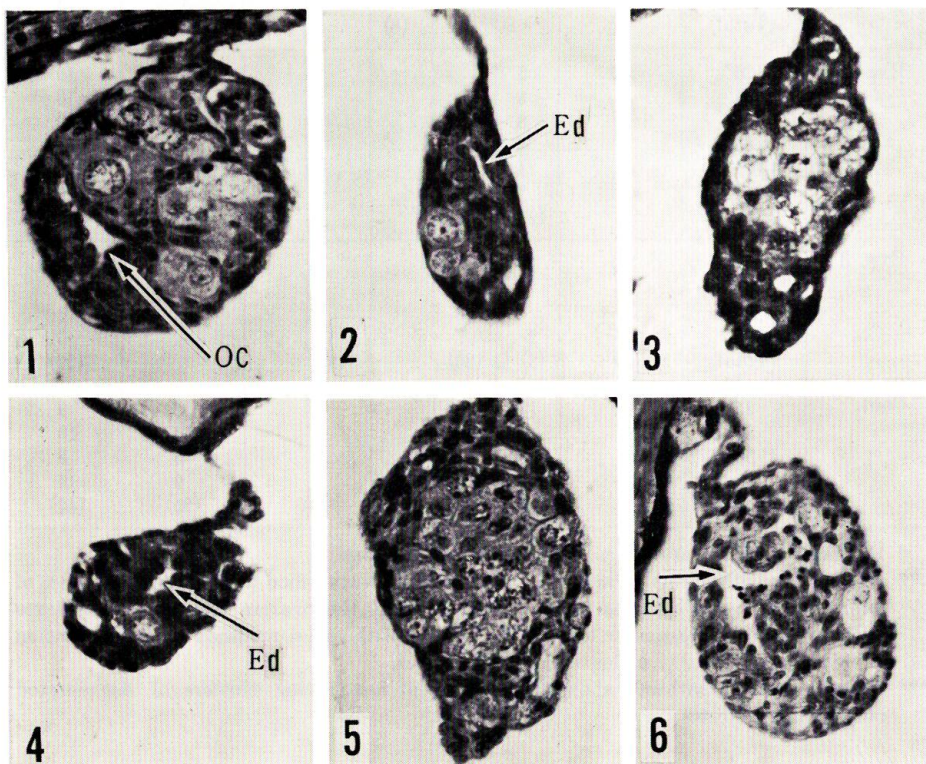
Results

As described in a previous paper⁷⁾, the gonadal sex differentiation in *Tilapia mossambica* becomes histologically recognizable by 20 days after hatching. The ovarian differentiation is characterized by the development of some germ cells into the meiotic prophase and by the concomitant formation of ovarian cavity (Fig. 1), while the testicular differentiation is marked by the appearance of efferent duct anlagen in the gonadal stroma (Fig. 2). In order to achieve a complete feminization of genetic males by exogenous estrogen, the treatment should be carried out to cover this particular stage of sex differentiation extending from 10 to 25 days after hatching.

Experiment 1

The diet containing methyltestosterone at the dose of 50 μg per g diet was given to 60 juvenile fish during the period from 7 to 25 days after hatching. The sex distribution of these fish examined at each time of sacrifice is shown in Table 1.

At the end of the androgen administration, the gonads of the treated fish could be divided into two types in respect to their histological aspects: those of one type had many cysts of pre-meiotic germ cells which were surrounded by stromal cells (Fig. 3), and those of another possessed only a few gonial germ cells dispersed in



Figs. 1 and 2. Cross sections through ovary (Fig. 1) and testis (Fig. 2) of control fish 35 days after hatching. *Oc*, ovarian cavity; *Ed*, efferent duct. Figs. 1 and 2, $\times 560$.

Figs. 3 and 4. Cross sections through ovary (Fig. 3) and testis (Fig. 4) in Experiment 1, at the end of treatment, revealing a deficiency of the formation of ovarian cavity in the affected ovary. *Ed*, efferent duct. Figs. 3 and 4, $\times 560$.

Fig. 5. Cross section through the gonad of a treated female in Experiment 1, 10 days after the end of treatment, demonstrating an increase in number of pre-meiotic germ cells and the deficiency of the ovarian cavity. $\times 400$.

Fig. 6. Cross section through the gonad of a male in Experiment 1, 40 days after the end of treatment, revealing the development of efferent duct, the start of spermatogenesis and the occurrence of clusters of degenerated oocytes. *Ed*, efferent duct. $\times 280$.

the stromal tissue with slit-like efferent duct anlagen (Fig. 4). The former was seen to be in an initial phase of ovarian differentiation, but did not reveal any sign of formation of the ovarian cavity. The latter denoted a differentiation of testes which was similar in histology to that seen in the gonad of control males of the same age. In the ovarian gonads examined 10 days after the end of the treatment, pre-meiotic germ cells had increased in number, but the formation of ovarian cavity did not occur yet (Fig. 5, compare with Fig. 1).

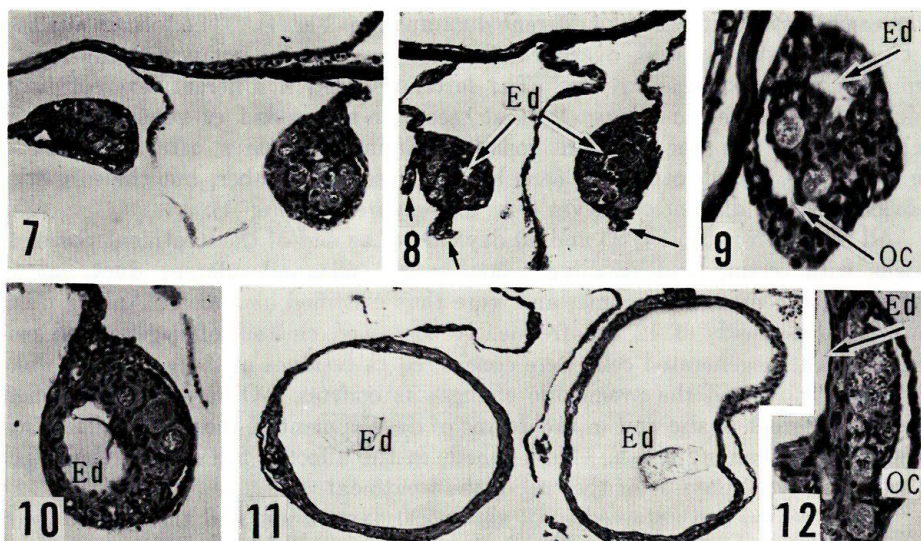
All of 20 fish autopsied 25 and 40 days after the end of the treatment possessed gonads with resting and dividing gonial germ cells and efferent duct anlagen perforating the proximal stroma, and were thus classified as males. Among them, however, the gonads of 12 fish frequently contained clusters of degenerated cells (Fig. 6). The degenerated cells were considered as residues of the germ cells which had formerly started the premeiotic changes as oocytes. Otherwise these gonads were not different in size and in the degree of development of the efferent duct from those of the remaining 8 fish. Most gonads in the affected fish started their spermatogenesis by 75 days after the end of the treatment.

Three treated fish survived until about 230 days of age and their gonads were examined histologically. These fish displayed a body coloration peculiar to mature males on the caudal and dorsal fins, and had fully elongated urogenital papillae. The gonads of these fish were distinctly the testes showing an active spermatogenesis and a normal development of efferent ducts.

Experiments 2 and 3

A group of 120 fish was administered orally with methyltestosterone at a dose of 1,000 μg per g diet starting 7 days after hatching. Nineteen days after the start of the treatment, 60 out of 110 surviving fish were exempted from the treatment (Experiment 2), while 50 others were continuously treated with androgen for 25 subsequent days (Experiment 3). After the hormone administration was discontinued, the fish of both experimental groups were kept on the normal diet for more than 60 days after hatching. They were killed for histological examinations of their gonads at intervals of about 10-15 days during that period. The results of the experiments are indicated in Table 1.

In Experiment 2, the ovaries of the treated fish at the end of the treatment had many pre-meiotic germ cells and ovarian cavities in the initial phase of their formation, being quite similar in aspects to those of the control fish of the same age. On the other hand, the testes of the treated fish possessed a few spermatogonial cells, which were dispersed singly in the stroma, as in the testes of the control fish. Their efferent duct anlagen were seen to be enlarged to some extent as compared with those of the control testes. Ten days after the end of the treatment, 3 out of 10 fish examined had ovaries of normal histological aspects with well-defined ovarian cavities (Fig. 7). The gonads of the remaining 7 fish were essentially testicular in feature with normally organized efferent ducts. Along the lateral sides of the testes facing the lateral coelomic wall, however, outgrowths of a pair of stromal sheets had occurred from both the proximal and distal regions of the testes without exception (Fig. 8). The elongation of stromal sheets was exactly



Figs. 7 and 8. Cross sections through gonads of treated fish in Experiment 2, 10 days after the end of treatment. Stromal elongations (arrows) from the proximal and distal regions of affected testes are noticeable in Fig. 8. *Ed*, efferent duct. Figs. 7 and 8, $\times 80$.

Fig. 9. Cross section through the gonad of a treated male in Experiment 2, 25 days after the end of treatment, demonstrating the formation of ovarian cavity (*Oc*) in the affected testis. *Ed*, efferent duct. $\times 340$.

Figs. 10-12. Cross sections through gonads of treated fish in Experiment 3, 15 days after the end of treatment. The appearance of expanded efferent ducts (Fig. 11), and the existence of the ovarian cavity and the synaptic oocytes in the periphery of the expanded efferent duct (Fig. 12) are shown. *Oc*, ovarian cavity; *Ed*, efferent duct. Fig. 10, $\times 160$; Fig. 11, $\times 100$; Fig. 12, $\times 220$.

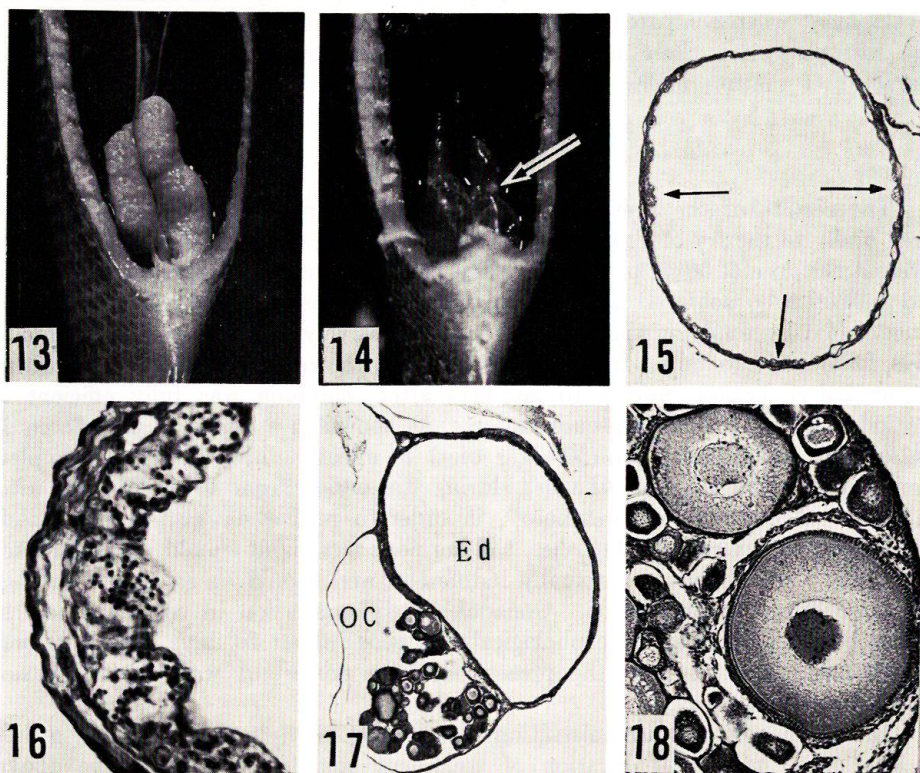
similar to that seen in an initial phase of formation of the ovarian cavity appearing in control females by 25 days of age.

Later on, the ovaries of the treated females grew normally, and began to have well-developed oocytes of the peri-nucleolus stage 25 days after the end of the treatment. The testes of the treated males were retained to be quiescent in germ cell development until 65 days of age, but came to be provided with peculiar cavities along their lateral sides as a result of a fusion of the elongated stromal sheets (Fig. 9), which was quite the same in process as the formation of ovarian cavity. The ovarian cavities became obscure by 193 days after the end of the treatment, due to a much progressed development of the testicular tissue.

In Experiment 3, in which an oral administration of methyltestosterone lasted for 44 days from 7 days after hatching, the results were extraordinary since the expected masculinizing action of androgen was exceeded by a paradoxical one of the same hormone, though there occurred a high mortality in the treated fish during the period from 20 to 30 days of treatment. Twenty-nine days after the start of treatment, only 1 out of 10 fish examined had defined ovaries with many auxocytes and ovarian cavities, which was considered to be a genetic female. The remaining

9 also possessed the gonads of ovarian structures with cysts of premeiotic germ cells and ovarian cavities, but their gonads were peculiar in being furnished with enlarged lumina perforating craniocaudally the gonadal stroma. The lumina appeared to be homologous in their histoarchitecture and position to the efferent duct of the testis.

The gonads of 3 out of 14 fish examined at the end of the treatment and 15 days later were ovaries with many auxocytes of similar developmental stages to those seen in control ovaries, but were still modified by the occurrence of expanded efferent ducts of a testicular nature (Fig. 10). These ovaries were considered to be those of genetic females. The gonads of the other 11 had ovarian cavities, synaptic oocytes and auxocytes which were clearly less in number and size (Fig.



Figs. 13 and 14. Ventral views of gonads of treated fish in Experiment 3, about 170 days after the hormone withdrawal. Fig. 13 shows a well-developed ovary. Fig. 14 reveals the gonads of a peculiar tubular aspect with localized ovarian tissue (arrow) on the expanded efferent ducts.

Figs. 15-18. Cross sections through gonads of treated fish in Experiment 3, about 170 days after the hormone withdrawal. Figs. 15 and 16 show the spermatogenesis (arrows) in the inner periphery of the expanded efferent ducts. Figs. 17 and 18 reveal the oogenesis in the outer periphery of the expanded efferent duct. *Oc*, ovarian cavity; *Ed*, efferent duct. Fig. 15, $\times 90$; Fig. 16, $\times 360$; Fig. 17, $\times 90$; Fig. 18, $\times 140$.

12) as compared with those of the controls. These gonads were all characterized by an extraordinary expansion of their efferent ducts, assuming a characteristic tubular aspect along the whole length of the gonad (Fig. 11).

Five fish of the treated group were autopsied 168 days after the end of the treatment. Two out of them had well-developed ovaries which seemed to be of genetic females (Fig. 13), while the remaining 3 possessed gonads of a peculiar tubular aspect which were expanded enormously and were transparent in an external appearance (Fig. 14). Histologically, the gonads possessed sporadically a small amount of ovarian tissue on the wall of expanded efferent ducts (Fig. 17), and a few cysts of spermatogenetic cells along the inner periphery of these efferent ducts (Figs. 15 and 16). The oocytes in these gonads had started their vitellogenesis with the development of follicle cells (Fig. 18), though they were retarded in their development when compared with those of the affected ovaries of genetic females. The fish possessing these intersexual gonads did not show the secondary sex character of mature males.

Discussion

The results of the present study indicate that methyltestosterone administered orally to the fry of *T. mossambica* has an evident masculinizing potency when given at the dose of 50 μg per g diet. This confirms the result obtained by Clemens and Inslee¹⁾ who achieved a functional masculinization of genetic females of the same cichlid by applying the androgen most effectively at 30 μg per g diet for 69 days following hatching. In the present study, however, the treatment lasting for a shorter period from 7 to 25 days after hatching was fully efficient in the induction of gonadal masculinization. As shown in a previous paper⁷⁾, in *T. mossambica*, ethinylestradiol (50 $\mu\text{g}/\text{g}$ diet) is effective in inducing a complete feminization when given to the fish during the period from 10 to 25 days after hatching. According to Yamamoto⁸⁾, in order to realize successfully a complete and functional sex reversal in fishes, the hormone treatment should be undertaken at a stage when gonads are sexually indifferent, and should be continued through the stage of sex differentiation. Gonadal sex differentiation in both sexes of the cichlid becomes detectable morphologically to occur about 20 days after hatching. Consequently, the result of the present study is consistent with the conclusion stated by Yamamoto⁸⁾.

In the case of oral administration of 1,000 μg methyltestosterone per g diet, on the other hand, the duration of treatment completely covered the above-mentioned particular period of gonadal sex differentiation and yet the masculinization of the gonad was not observed in the affected females. In the treated males, on the contrary, the formation of ovarian cavity was induced in the testes without exception. Moreover, even if the administration of androgen at the same dose was protracted over 50 days after hatching, the sex reversal from females to males did not occur, either. The ovaries of the affected fish were well-developed just like those of the controls, though efferent ducts peculiar to the testis were induced to be formed in the gonadal stroma. On the other hand, under the influence

of androgen with such intense dose, oogenesis progressed, though much less in degree than that in the control ovaries, and the ovarian cavity was formed paradoxically in the gonads of possible genetic males. Subsequent to the discontinuance of the androgen treatment, those peculiar gonads developed into those with an intersexual structure which displayed an advancing spermatogenesis along the inner periphery of expanded efferent ducts and the occurrence of maturing oocytes and definite ovarian cavities along the outer side of the ducts.

These results of treatment of *T. mossambica* with methyltestosterone at the much intense dosage level are of special interest in that the treatment fails to elicit gonadal masculinization in females notwithstanding the fact that it had been carried out through the particular period of sex differentiation, but most of all, in that it discloses a paradoxical feminizing potency of the androgen which may become prominent in the case of a long-lasting treatment. The feminization by androgen is not complete in the present study but is evident in the behaviour of both the somatic and germinal elements of the gonads of the males.

A paradoxical feminizing effect of male sex hormones had been noticed first by Müller²⁾ in the young of *Hemihaplochromis multicolor* reared in water with methyltestosterone or testosterone propionate ranging in concentration from 50 to 1,000 $\mu\text{g}/\text{l}$ water. The treatment caused a precocious development of male secondary sex characters whereas it induced an ovarian differentiation in genetic males which followed an essentially similar process of development to that seen in normal females. Similar gonadal feminization elicited paradoxically by androgens proved to occur in several cichlids such as *Tilapia mossambica*, *T. heudeloti*, and *Cichlasoma biocellatum*⁵⁾. In *T. mossambica*, according to Hackmann⁵⁾, methyltestosterone and testosterone propionate at the concentration of 500 $\mu\text{g}/\text{l}$ water provoked an oogenesis at admittedly high ratios in treated fish when given through the period of sex differentiation, though the treatment rather exerted an inhibitory influence of the gonadal development especially when the treatment with methyltestosterone lasted long. Moreover, Hackmann and Reinboth²⁾ evidenced the paradoxically feminized fish to be functional in respect to their reproductive capacity.

Feminizing modifications of the gonad of genetic males of *T. mossambica* observed in the present study seem to have some resemblance to those described by Hackmann⁵⁾, cited above. Thus it may be concluded that, at least in *T. mossambica*, methyltestosterone can disclose its feminizing action on the gonad whether it is given with food or added to rearing water, though Müller²⁾ suggested the way of hormone administration to be one of the possible causes of the difference in the effects of androgen. Furthermore, the androgen, if given orally sufficiently to the fish through the particular stage of sex differentiation, is capable of inducing either a complete masculinization of genetic females at lower dosage levels (10-50 $\mu\text{g}/\text{g}$), as evidenced also by Clemens and Inslee¹⁾, or a paradoxical feminization of genetic males at a higher dose (1,000 $\mu\text{g}/\text{g}$) combined with a long duration of treatment.

Reinboth⁴⁾ suggested that, in *Hemihaplochromis multicolor*, a long-term oral administration of testosterone at exceedingly high dosages (30-50 mg/g diet) was

required to cause gonadal masculinization while a short-term treatment with equal dosages resulted in gonadal feminization. This seems to be in contrast with the present results in *T. mossambica*, which might denote a significance of species differences in the response to the androgen treatment of the gonad in cichlid fishes. However, the substantial cause of these varying effects of androgen on sex differentiation of cichlid fishes remains to be elucidated. Careful investigations of characteristic changes of the somatic elements as well as the germinal one of androgen-influenced gonads seem to be an effectual approach for clarifying the mechanism of the dual effects of androgen on gonadal sex differentiation.

References

- 1) Clemens, H.P. and Inslee, T. (1968). The production of unisexual broods by *Tilapia mossambica* sex-reversed with methyl testosterone. *Trans. Amer. Fish. Soc.* 97, 18-21.
- 2) Müller, R. (1969). Die Einwirkung von Sexualhormonen auf die Geschlechts-differenzierung von *Hemihaplochromis multicolor* (Hilgendorf) — (Cichlidae). *Zool. Jb. Physiol.* 74, 519-562.
- 3) Hackmann, E. and Reinboth, R. (1974). Delimitation of the critical stage of hormone-influenced sex differentiation in *Hemihaplochromis multicolor* (Hilgendorf) (Cichlidae). *Gen. Comp. Endocrinol.* 22, 42-53.
- 4) Reinboth, R. (1969). Varying effects with different ways of hormone administration on gonad differentiation of a teleost fish. *Ibid.* 13, 527-528.
- 5) Hackmann, E. (1974). Einfluss von Androgenen auf die Geschlechts-differenzierung verschiedener Cichliden (Teleostei). *Ibid.* 24, 44-52.
- 6) Reinboth, R. (1972). Effects of steroid hormones on sex differentiation in cichlid fishes. *Ibid.* 18, 620 (abstr.).
- 7) Nakamura, M. and Takahashi, H. (1973). Gonadal sex differentiation in *Tilapia mossambica*, with special regard to the time of estrogen treatment effective in inducing complete feminization of genetic males. *Bull. Fac. Fish. Hokkaido Univ.* 24, 1-13.
- 8) Yamamoto, T. (1969). Sex Differentiation. p. 117-175. In Hoar, W.S. and Randall, D.J. (eds.), *Fish Physiology*, Vol. III. 485p. Academic press, New York and London.