



Title	Effects of Large Doses of Methyltestosterone on the Development of Reproductive Organs of Juvenile Guppy, <i>Poecilia reticulata</i>
Author(s)	TAKAHASHI, Hiroya; 高橋, 裕哉
Citation	北海道大學水産學部研究彙報, 28(1), 6-19
Issue Date	1977-04
Doc URL	https://hdl.handle.net/2115/23600
Type	departmental bulletin paper
File Information	28(1)_P6-19.pdf



Effects of Large Doses of Methyltestosterone on the
Development of Reproductive Organs of
Juvenile Guppy, *Poecilia reticulata*

Hiroya TAKAHASHI*

Abstract

In order to ascertain whether a paradoxical feminizing action of androgen demonstrated thus far in cichlid fishes is also the case in the guppy, *Poecilia reticulata*, methyltestosterone (MT) at doses of 1000, 1500 and 2000 $\mu\text{g/g}$ diet was administered to juvenile fish for 35 days following birth. The extremely high doses of MT resulted in the appearance of obscured sex coloration in the treated males and in the formation of atypical gonopodia in the treated females as well as males. In addition, oviduct and common sperm duct caudal to the gonad proper, and even urogenital sinus as well, did not exist in any treated fish. These abnormalities were not ameliorated even 2 months after the treatment. The liver of these fish showed some histological modifications denoting a probable intensification of protein synthesis in parenchymal cells; however, the condition returned to normal rapidly after the treatment was terminated.

Ovaries of the treated fish responded with a remarkable dilatation of the ovarian cavity lined by a thin epithelial wall and a scantiness of germ cells, which led to nearly complete sterilization of the gonad. Intersexual structures did not occur in any of the affected ovaries. The state of the ovary was not improved after hormone withdrawal. By contrast, all affected testes were liberated, after the treatment, from a severe developmental suppression to assume eventually a nearly normal histoarchitecture of the testis. Sterilization of the testis was complete only when the treatment was protracted over 70 days following birth. The paradoxical feminizing effect of large doses of MT was not evident in affected testes. However, an extensive proliferation of stromal tissue and an occasional occurrence of oviform germ cells in the testes were the features indicating the presumed paradoxical action of androgen on the testis of the guppy.

It has been well established that sex steroids are effective in modifying and directing the gonadal sex differentiation in teleost fishes when administered in adequate doses and during appropriate stages of gonadal development¹⁾. In general, androgens can induce a masculinization of genetic females and estrogens a feminization of genetic males. However, recent studies on cichlid fishes have raised an interesting subject of research about a paradoxical feminizing action of androgen on the fish gonad.

Müller²⁾ was first to report a complete ovarian differentiation in males of *Hemihaplochromis multicolor* reared in a water solution of androgen. Successive studies made by Reinboth³⁾ and Hackmann⁴⁾ revealed the phenomenon to be more or less common to other cichlids such as *Cichlasoma biocellatum* and *Tilapia*

* Laboratory of Fresh-Water Fish-Culture, Faculty of Fisheries, Hokkaido University
(北海道大学水産学部淡水増殖学講座)

heudeloti. Furthermore, Nakamura⁵⁾ disclosed that, in *Tilapia mossambica*, oral administration of androgen exerts a different influence on gonadal sex differentiation according to the dosage and the duration of androgen treatment: a long-term treatment combined with a large dose of androgen could admittedly feminize the gonad of genetic males.

Such a paradoxical action of androgen on gonadal sex differentiation has scarcely been examined in teleosts other than the cichlids, except for the medaka, *Oryzias latipes*, in which Yamamoto⁶⁾ did not admit the feminizing action of androgen to occur. The present study was undertaken to see if the oral administration of androgen at high dosages can feminize the gonad in the guppy as effectively as it does in the cichlids. The *orthodox* effects of androgen and estrogen on the gonad of the guppy have been reported earlier⁷⁾⁻⁹⁾.

Material and Methods

The experiments were carried out over a four-month period, from December to March. Four broods of the guppy, *Poecilia reticulata*, of the yellow variety, bred in the laboratory⁷⁾, were divided into experimental and control groups on the day following birth. They were raised under the natural light condition in glass aquaria containing 9 liters of water aerated constantly and regulated at about 25°C. The aquaria were cleaned and refilled with fresh water generally once a week. Juvenile guppies of the same brood constituted each of the four experimental series of the present study (Table 1).

Methyltestosterone was dissolved in 95% ethanol and added to a powdered diet at doses of 1000, 1500 and 2000 $\mu\text{g/g}$ diet. The fish of experimental groups were given the hormone-containing diet once a day for 35 days from the day after

Table 1. Treatment of juvenile guppies, *Poecilia reticulata*, with methyltestosterone (MT) mixed with diet.

Group	Age of fish			No. of fish treated	No. of fish examined	Distribution of genetic sex**	
	at the start of treatment	at the end of treatment	at the last fixation			F	M
MT 1000 $\mu\text{g/g}$ diet	1	35	90	27	27	15	12
Control	-	-	90	27	26	12	14
MT 1500 $\mu\text{g/g}$ diet	1	7	70	54	18	9	9
"	1	35	90		34	13	21
Control	-	-	90	55	55	27	28
MT 2000 $\mu\text{g/g}$ diet*	1	35	75	25	23	6	17
Control*	-	-	75	25	25	8	17
MT 2000 $\mu\text{g/g}$ diet	1	70	70	22	21	10	11

* The brood used was the offspring of a sex-reversed (XY) female mated with a normal (XY) male.

**F, female; M, male.

birth, and were subsequently fed on a normal diet until they were fixed for histological examination. The fish of control groups were fed on a diet prepared by adding the solvent ethanol only. In a brood of 22 guppies, the hormone administration at a dose of 2000 $\mu\text{g/g}$ diet was protracted to 70 days of age when they were sacrificed for observation. Mortality was negligible in all of the experiments.

The fish of both the experimental and control groups were fixed *in toto* in Bouin's fluid at the end of treatment and generally at 50, 70 and 90 days of age. Their gonads and associated duct system including the urogenital sinus, which were left intact in the coelomic cavity following a careful trimming of the body, were cut frontally in serial sections of 8–10 μ in thickness, and stained with Delafield's hematoxylin and eosin for microscopic observations.

The effects of methyltestosterone treatment on body growth, sex characters, gonads and their associated structures of the juvenile guppies were essentially similar for all at the three dosage levels used in the present study. Accordingly, no distinction of the dosage levels will be made in the following description unless otherwise stated.

Results

Body growth and external sex characters

As reported previously⁷⁾, a distinct inhibition of an increase in body length of juvenile guppies of both sexes is the general result of androgen administration. In cases where methyltestosterone was given at comparatively small doses of 50–300 $\mu\text{g/g}$ diet, the affected female guppies regained their body growth after the termination of treatment so that they might soon attain the size of the control females of the same age. In the present experiments, a marked retardation in body growth was noticed in the treated fish of both sexes. As shown in Fig. 1, the treated fish were fairly smaller in body length than the controls, at the end of treatment. The treated females could subsequently regain their body growth but quite slowly as compared to those treated at the smaller dose of 50 $\mu\text{g/g}$ diet. The treated males remained smaller than the control males 55 days after the treatment, but were similar in body length to the fish treated with 50 μg methyltestosterone. The inhibition of body growth was observed to be nearly the same in degree among the three dosage levels used in the present study.

The transformation of the anal fin into gonopodium was accelerated in the treated males and newly induced in the treated females during the early course of the treatment. The gonopodia were, however, always stunted in appearance and were generally of an atypical structure, showing most frequently an insufficient formation of their hoods and hooks, irrespective of the genetic sex of the fish. With the androgen treatment, a precocious appearance of orange-red spots of the male sexual coloration was also elicited in genetic males. However, the tint of the colour of the spots was, in most cases, notably paler than that of the coloration of maturing control males, even in the presence of exogenous androgen. The atypical structures of the gonopodia and the paleness of the male coloration were not changed at least as late as 50 days after the end of treatment.

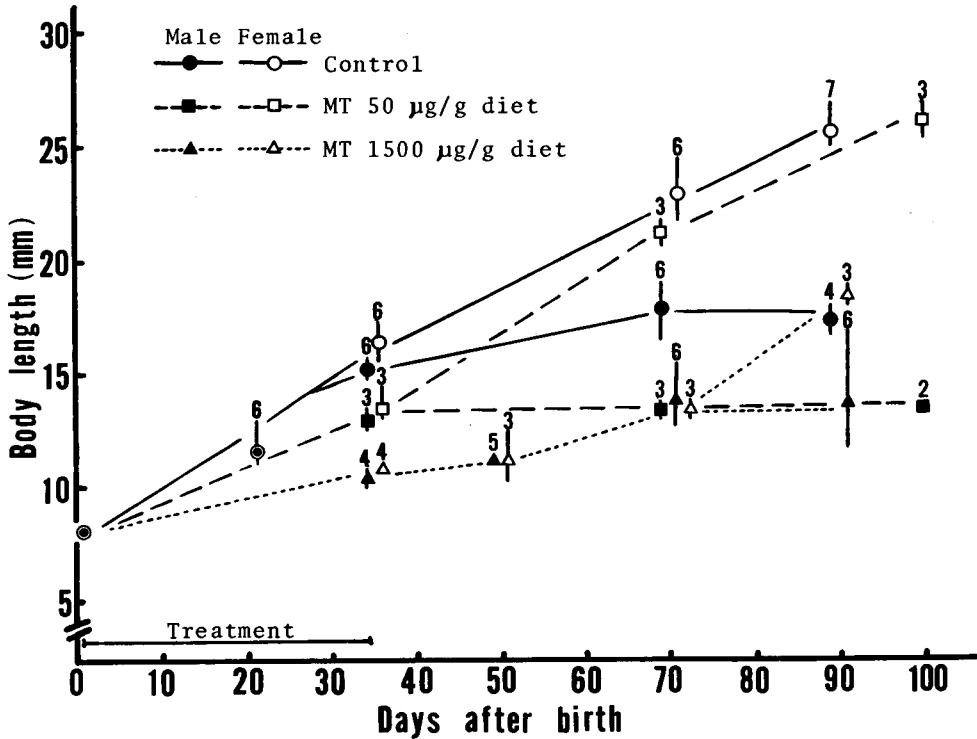


Fig. 1. Body growth in male and female guppies, *Poecilia reticulata*, during and after the oral administration of methyltestosterone (MT) for 35 days after birth. Vertical bars and numerals affixed to each mark indicate the range of individual variation around the mean and the number of fish measured, respectively.

Gonad

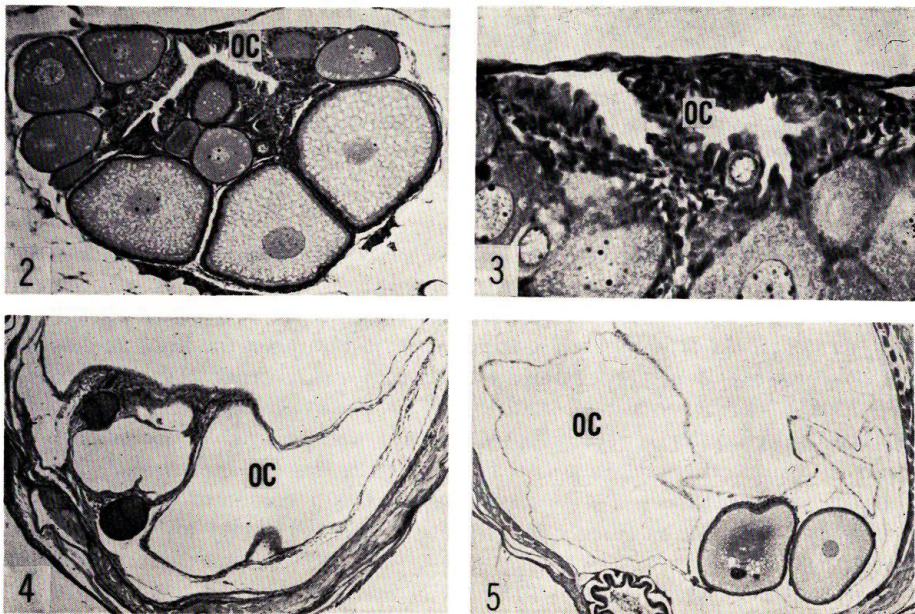
Ovaries of the juvenile females treated with extremely high doses of methyltestosterone for 35 days following birth were in no case furnished with any trait of testicular structure in any region of the ovaries. It contrasted sharply with the results of the treatment with smaller doses of androgen for the same length of days, in which the occurrence of female intersexes was recorded rather commonly⁷⁾. After 7 days of the treatment with 1500 µg methyltestosterone, only a slight structural modification in the affected ovaries was caused. Most oocytes were normal in aspect, their degenerative changes being hardly noticeable. The walls of the ovarian cavities were, however, made of tall columnar cells which were accompanied with young germ cells projecting into the cavity on many occasions (Fig. 3).

The control females, 35 days after birth, had ovaries with oocytes developing to the early oil drop stage (Fig. 2). In treated females of the same age, on the other hand, ovaries were no more than extremely expanded sacs lined with quite flat epithelial cells (Fig. 4). The sacs evidently represented the modified ovarian cavities. Only a few oocytes were present dispersedly along the wall of the cavity,

but were always small in size and abnormal in aspect. Younger germ cells such as oogonia and synaptic oocytes were undetected throughout the entire gonadal region. The abnormal histoarchitecture of ovaries remained little changed after the withdrawal of androgen. The ovaries of treated females, 35 days after the end of treatment, still had tremendously dilated ovarian cavities which, in some of the treated fish, swelled the abdomen conspicuously. The wall of the cavities were thin as before without exception. The surviving oocytes were seen to be developing, but were still very few in number and no younger germ cells existed (Fig. 5).

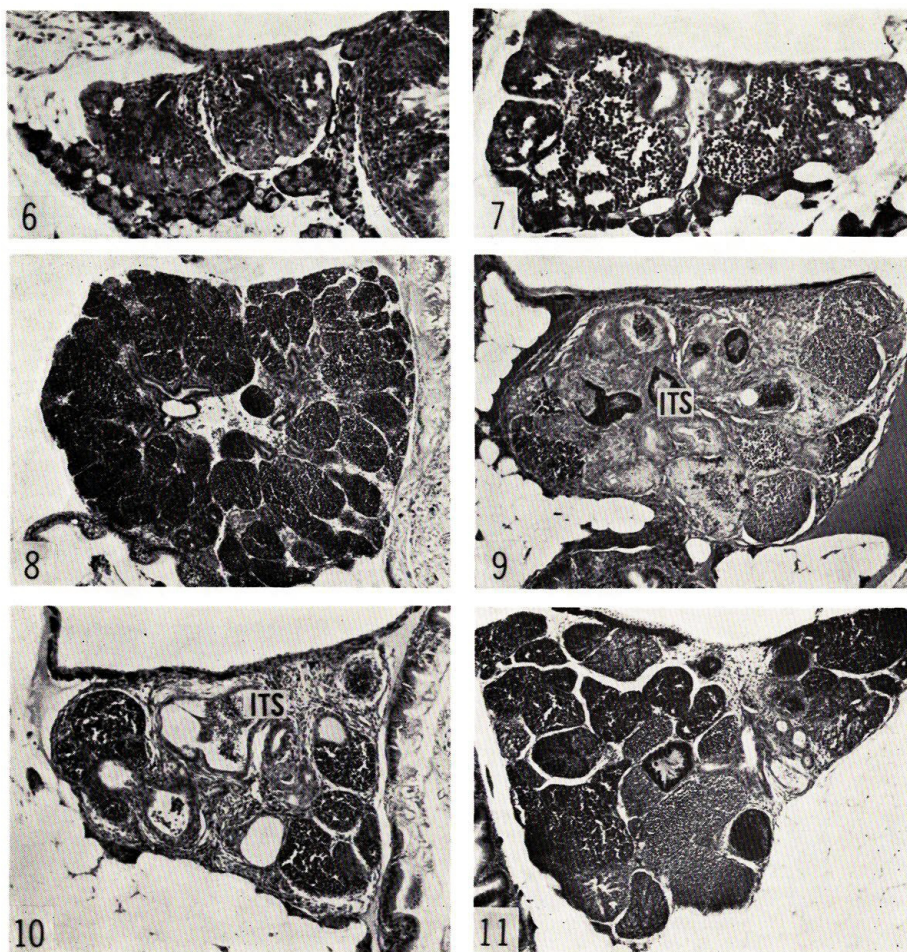
The spermatogenesis in the testis of the treated guppies was notably accelerated 7 days after the start of treatment (Fig. 7) when compared with that in the control males (Fig. 6). The development of the intratesticular sperm duct was also stimulated by the treatment. At the end of the 35-day treatment, however, the affected testes were small in size and were modified by a marked increase in the amount of connective tissue which filled compactly the interstices among the sperm ducts and germ cell cysts (Fig. 9). The sperm ducts were seen to be stimulated to develop, though atypically, as compared with those of the control testes (Fig. 8), the former being larger in size and mostly lined with hypertrophied cells. The germ cell cysts were, however, evidently small in number and those comprising transforming spermatids and spermatozoa were abnormal in feature.

In contrast to the condition seen in affected ovaries, the gradual amelioration of the development of affected testes was evident after the end of treatment.



Figs. 2-5. Cross sections of ovaries of a control guppy, 35 days of age (Fig. 2), and of female guppies 7 (Fig. 3) and 35 days after the start (Fig. 4) and 35 days after the end (Fig. 5) of the 35-day treatment with methyltestosterone (1500 μ g/g diet). OC, ovarian cavity. Fig. 2, \times 75; Fig. 3, \times 300; Fig. 4, \times 48; Fig. 5, \times 34.

The testes of treated males on 50 days of age were still small and atypically organized by proliferated fibrous connective tissue and expanded intratesticular sperm ducts (Fig. 10). However, the germ cell cysts of early spermatogenic stages including the spermatogonial ones were arranged peripherally, thus assuming a normal aspect, and those of more advanced stages had disappeared leaving some disorganized sperm balls dispersed in the sperm duct. The affected testes, examined when 70 days of age, were almost normal in histology with an advanced spermatogenesis (Fig. 11), and they became quite similar in developmental

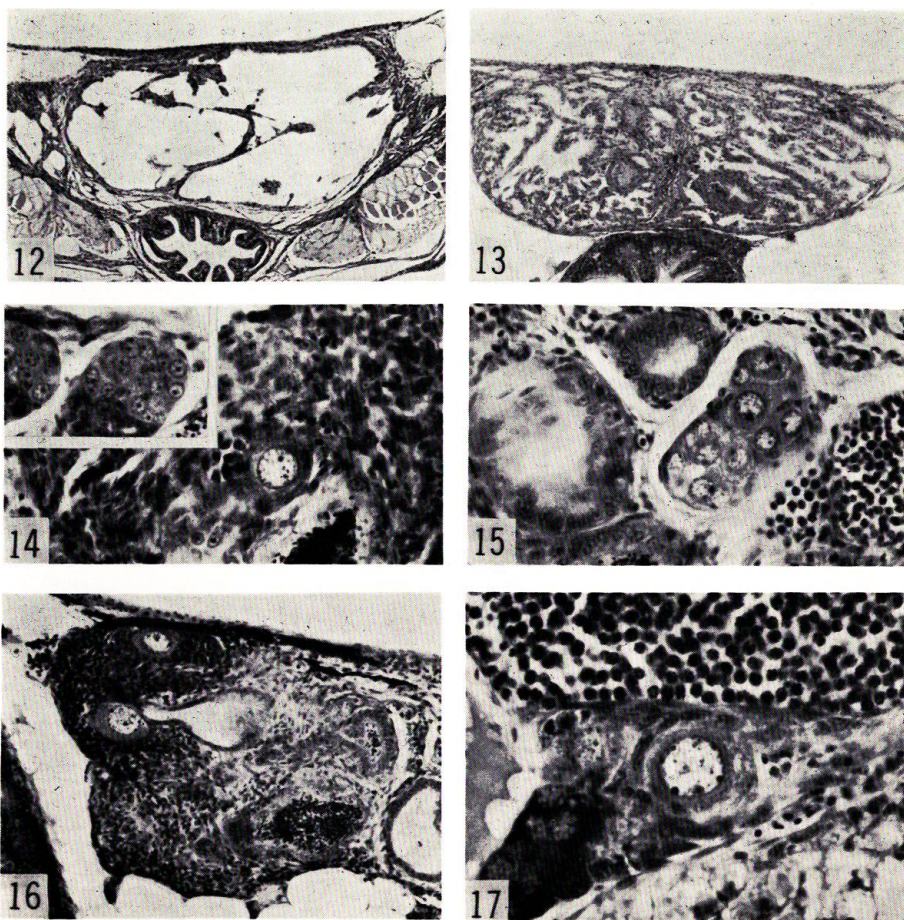


Figs. 6 and 7. Cross sections of testes of a control male guppy, 7 days of age (Fig. 6), and of a male guppy treated with methyltestosterone (MT, 1500 $\mu\text{g/g}$ diet) for 7 days after birth (Fig. 7). $\times 150$.

Figs. 8-11. Cross sections of testes of a control male guppy, 35 days of age (Fig. 8), and of male guppies at the end (Fig. 9), 15 (Fig. 10) and 35 days (Fig. 11) after the end of the 35-day treatment with MT (1500 $\mu\text{g/g}$ diet). *ITS*, intratesticular sperm duct. Fig. 8, $\times 60$; Figs. 9 and 10, $\times 83$; Fig. 11, $\times 60$.

states to those of the control males when 90 days of age.

With $2000\mu\text{g}$ methyltestosterone/g diet, a nearly complete sterilization of both sexes resulted when the treatment was protracted to 70 days following birth. The gonads of the genetic females at the end of treatment were merely a widely dilated sac with a thin epithelial layer. Oocytes were very scarce throughout the gonadal region. The gonads of the genetic males at the end of the 70-day treatment were composed of complicated lacunae of various sizes which were lined with a layer of cuboidal cells and separated from one another by dense connective tissue rich in blood capillaries (Fig. 13). The lacunae were possibly the ramifications of



Figs. 12 and 13. Cross sections of gonads of male guppies after 50 (Fig. 12) and 70 days (Fig. 13) of treatment with methyltestosterone (MT, $2000\mu\text{g/g}$ diet). Fig. 12, $\times 60$; Fig. 13, $\times 83$.

Figs. 14–17. Sections of testes of male guppies at the end (Fig. 14) and 15 days after the end (Figs. 15–17) of the 35-day treatment with MT ($2000\mu\text{g/g}$ diet). Figs. 14 and 15, $\times 330$; Fig. 16, $\times 160$; Fig. 17, $\times 450$. Inset in Fig 14 shows clusters of resting secondary spermatogonia in the testis of a control male of 50 days of age, $\times 330$.

the median sperm ducts that had lost their associated germinal components. Germ cells including spermatogonia were clearly reduced in number since 50 days of treatment (Fig. 12), and they had mostly disappeared from the gonads after 70 days of treatment.

Another interesting feature detected in the testes affected by large doses of androgen was the occurrence of oviform germ cells intermingled among male germ cells (Figs. 14-17). These cells were round in contour and measured up to $350\ \mu$ in diameter, appearing mostly on the peripheral region of the testes singly or in clusters of various numbers. They closely resembled the oocytes in the early periods of the first growth phase. Sometimes the nucleus of the oviform cell was provided with several small nucleoli arrayed in close contact with the nuclear membrane, and the cell was obviously enclosed by somatic cells which displayed a follicular arrangement (Fig. 17). The oviform germ cells were observed to occur in 1 out of 4 males of 35 days of age in the $1500\ \mu\text{g}$ group; in 3 out of 6 males of 35 days, and in 5 out of 6 males of 50 days of age in the $2000\ \mu\text{g}$ group. No oviform cells appeared in the testes of control males at any age.

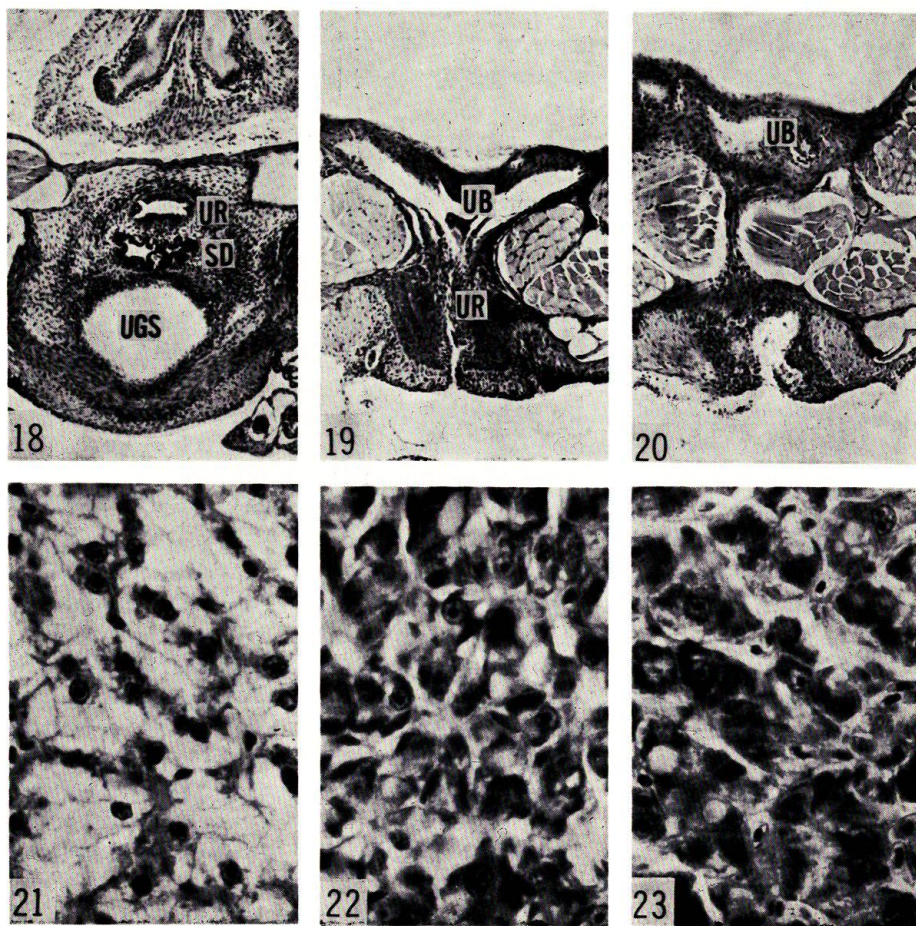
Gonoduct and urogenital sinus

In mature males of the guppy, the urogenital sinus is a cephalocaudally flat, slit-like cavity, and its orifice is overlaid by a transverse fold of the anterolateral wall of the sinus. A single, common sperm duct together with a urethra runs from the front caudalwards to open into the sinus at its cephalodorsal region (Fig. 18). In mature females, by contrast, the urogenital sinus is of an inversed triangular shape in a median sagittal section, the orifice of which being merely an oval pore without any overlaying fold. The oviduct opens into the sinus at the dorsal side, while the urethra runs almost perpendicularly from the urinary bladder to enter the sinus at its posterior corner. The treatment of juvenile guppies with androgen brings about the formation of a urogenital sinus of the male type heterotypically in females as well as precociously in males⁷⁾.

In the four experimental groups of the present study, all of the treated males and females lacked the gonoduct in the region caudal to the gonad proper. The intratesticular sperm ducts were always blind at the caudalmost region of the affected testes which were localized in the anterior part of the coelomic cavity. The ovarian cavities were, in all cases, changed to blind sacs which dilated remarkably to fill in the coelomic cavity.

Moreover, the treatment with large doses of androgen failed to induce the differentiation of male-typed urogenital sinus; on the contrary, the treatment suppressed the formation of the sinus in all treated males and females. After 35 days of treatment, when the urogenital sinuses of control fish had taken their sex-specific configuration, the urethra of treated fish of both sexes ran almost perpendicularly from the urinary bladder ventralwards, and opened directly to the exterior (Fig. 19), maintaining an aspect that could be seen before the sex differentiation of the urogenital sinus was initiated. In several cases, a small square-shaped depression was observed just behind the urethral aperture, assuming an aspect of a deformed urogenital sinus (Fig. 20).

The 7-day treatment with $2000\ \mu\text{g}$ methyltestosterone produced a similar



Figs. 18 and 19. Cross sections through the region of urethral opening of a control male guppy 35 days of age (Fig. 18) and of a male guppy treated with methyltestosterone (MT, 2000 $\mu\text{g/g}$ diet) for 35 days (Fig. 19). *SD*, common sperm duct; *UB*, urinary bladder; *UGS*, urogenital sinus; *UR*, urethra. Fig. 18, $\times 75$; Fig. 19, $\times 95$.

Fig. 20. Cross section through the region shortly posterior to the urethral opening of the same fish as in Fig. 19. $\times 95$.

Figs. 21-23. Sections of the liver of a control male guppy 35 days of age (Fig. 21) and of a male guppy treated with MT (1000 $\mu\text{g/g}$ diet) for 35 days (Fig. 23). For comparison, the liver of a male guppy treated with ethinylestradiol (100 $\mu\text{g/g}$ diet) for 40 days after birth is demonstrated in Fig. 22. Figs. 21-23, $\times 680$.

deformity of the gonoduct system in the treated fish, but the condition was improved by the withdrawal of androgen, except that the urogenital sinus appeared to remain as a simple, slit-like cavity without taking the characteristic sexual structure. On the contrary, the deformity of the gonoduct system of the fish treated for 35 days did not show any development toward recovery for as long as 2 months after the end of treatment.

Liver

In the course of a previous study⁹⁾, it was observed that parenchymal cells of the liver of the juvenile guppies treated with estrogen were modified to have darkly stained cytoplasm and a hypertrophied nucleus with a prominent nucleolus (Fig. 22). Such a change in the liver cells was never detected in juvenile guppies subjected to the treatment with 30 to 300 μg methyltestosterone/g diet. However, the same androgen at 1000–2000 μg levels induced changes in the liver cells which were similar in histological features to those observed after the estrogen treatment. In general, liver parenchymal cells of immature control guppies had clear cytoplasm and an elliptical nucleus of about 4 μ in diameter with one or more nucleoli (Fig. 21). Those of the androgen-treated fish were, however, came to have darkly stained cytoplasm, in which occasionally appeared clear eosinophilic vacuoles of various sizes, and a round nucleus hypertrophied to be 5–7 μ in diameter with a much prominent nucleolus (Fig. 23). The modification of the liver cells evidently occurred after 7 days of treatment, but was finished 15 days after the end of treatment, when the liver cells of the treated fish were nearly the same in histological figures as those of the controls of the same age.

Discussion

The modification of ovaries affected by large doses of methyltestosterone in the present study are essentially similar to those produced by smaller doses of androgen administered to guppies after birth⁷⁾. A marked dilatation of the ovarian cavities and a conspicuous scantiness of oocytes, the latter being suppressed in development, were characteristic of the ovaries of the androgen-treated juvenile female guppies if the treatment lasted for more than 35 days following birth. The changes in the ovaries seem to be irreversible except for recovered development of oocytes surviving at the end of the treatment, leading to eventual sterilization of the gonad of the treated females. The epithelial layer lining the modified ovarian cavity stayed flat fairly long after the cessation of treatment; that might account for the failure to replenish the affected ovary with germ cells which are to be developed subsequently into new oocytes as suggested previously⁷⁾.

Androgens, especially when given to fry or juvenile fishes at high dosage levels and for long duration of days, occasionally lead to complete sterility of the gonad. Yamamoto⁶⁾ reported that the medaka, *Oryzias latipes*, receiving methyltestosterone of more than 300 $\mu\text{g}/\text{g}$ diet during a juvenile period, eventually became completely sterile at the full-grown stage, irrespective of their genetic sex. In the rainbow trout, *Salmo gairdnerii*, Jalabert et al.¹⁰⁾ stated that the oral administration of androgen at dosage levels of 15 to 60 $\mu\text{g}/\text{g}$ diet for 5 months to juvenile fish could produce some sterilized adults.

Male germ cells, the spermatogonia in particular, of the guppy seem to be more resistant to such a destructive effect by androgen than those of the above two species of teleosts: methyltestosterone administered at 2000 $\mu\text{g}/\text{g}$ diet for 35 days after birth did not hinder the eventual recovery of affected testes from suppressed to normal conditions of the spermatogenetic activity. Complete sterilization of the testes was realized only when the same treatment was protracted at least to 70 days following birth. The high resistibility of the male gonidia to the

adverse effect of androgen may be related to the fact that the testicular differentiation is established in the guppy before birth, an age factor that can be involved in the phenomenon. The differential effect of androgen concerning the sterilization of male and female gonads of the guppy might be explained by the difference in the way of generating new crops of germ cells during the maturation cycle of the gonad in the guppy, as suggested by some authors¹¹⁾¹²⁾.

There are several morphological characteristics in the guppy which are considered to depend upon androgen for their differentiation and development. An optimal dosage level of androgen must be required for their morphogenesis in a typical pattern. Such a case has been demonstrated in the induced formation of gonopodial structures in the adult females of *Platypoecilus maculatus*¹³⁾ and *Lebistes reticulatus*¹⁴⁾. The dosage levels of methyltestosterone used in the present study were much above the optimal level for the induction of the male sex character of typical structural pattern. The induced gonopodia in both males and females were stunt and lacked some structural components; that added a confirmation of the results by the above two authors. The body coloration of treated males was obviously paler than that of the control males even during the presence of exogenous androgen, and it did not improve long after the withdrawal of androgen. Moreover, in addition to a complete deficiency in the formation of the oviduct and common sperm duct, the urogenital sinus also failed to be formed in the treated males and females. These phenomena might imply that androgen at extremely high doses acting on the target tissues some time prior to their differentiation, makes the structures irreversibly unresponsive to the morphogenic action of androgen. The precise mechanism involved remains to be clarified.

Contrasting to the treatment with methyltestosterone at small doses⁷⁾, those at large doses could not bring about even a partial transformation of ovaries into intersexual gonads in any of the dosage groups examined in the present study. It has been shown that the occurrence of intersexual animals among genetic females of the guppy tends to become more frequent by the treatment with methyltestosterone at 50 μg than at 100 μg /g diet⁷⁾. A similar tendency of a decrease in the masculinizing action with the elevation of dosage levels of androgen was observed also in *Tilapia mossambica* by Clemens and Inslee¹⁵⁾, and more certainly by Nakamura⁵⁾.

According to the latter author⁵⁾, methyltestosterone administered to the fry for a period of 19 days induces a complete masculinization of genetic females at the dose of 50 μg /g diet, but cannot operate any notable changes of the affected ovaries at the dose of 1000 μg . Furthermore, androgen at this high dosage exerted a paradoxical feminizing influence on the gonad of genetic males when it was given for as long as 40 days.

The feminizing action of androgen has been disclosed by some investigations on several cichlid fishes such as *Hemihaplochromis multicolor*, *Cichlasoma biocellatum* and *Tilapia heudeloti*²⁾⁻⁴⁾: gonads of male fry reared in water containing methyltestosterone or testosterone propionate in a concentration of 500 $\mu\text{g}/\text{l}$ water, came more or less to have ovarian characters, those in *H. multicolor* developing as ovaries which were indistinguishable from the ovaries of normal females. Reinboth³⁾ suggested that the way in which the hormone is administered is the cause of the different results of masculinization and feminization with the same androgen.

However, Nakamura's results cited above seem to stress that the adverse effect of androgen on the gonadal components, possibly resulting from its high dosage combined with a long-term treatment, is expressed as partial feminization of the gonad, whether the androgen is added to the diet or to the rearing water.

In the present experiments on *Poecilia reticulata*, the paradoxical feminizing action of methyltestosterone was not distinct in the effected testes. However, an extensive proliferation of stromal tissue of the affected testes strikingly resembled that caused by the estrogen treatment of juvenile male guppies⁹⁾. In addition, the occasional occurrence of oviform germ cells in these testes may possibly suggest a feminizing action of the administered androgen. Such oviform cells on no occasion appeared during the normal development of the testis in the guppy, but developed in the testis of estrogen-treated male guppies as reported first by Berkowitz¹⁶⁾.

Yamamoto⁵⁾ also observed the appearance of oviform cells in the testes of the medaka, *Oryzias latipes*, subjected to the androgen treatment, but he regarded them as degenerating enlarged gonidia but not as true oocytes because there were no follicle cells, no yolk formation, and the cells showed a strong affinity for dyes. The oviform germ cells existing in the affected testes of the guppy truly resembled the young previtellogenic oocytes of the ovary, and some of them were evidently enclosed by follicular somatic cells. They were too scanty and too sparse in distribution to be regarded as spermatogonia forced to undergo degeneration by the treatment. They occurred more frequently 15 days after the treatment than at the end of treatment, and disappeared thereafter with the recovery of the testicular development from which an impediment of their existence might ensue.

It was impossible to pursue the development of these oviform germ cells any longer during the prolonged treatment with androgen, because the treatment ended in eventual sterilization of the affected testes. The fact that the gonadal sex differentiation was completed at the time of birth in the guppy may be one of the factors which obscure the feminizing action of androgen given to juvenile fish after birth, though estrogen can successfully cause a functional feminization of genetic males when administered after birth⁹⁾.

The precise mechanism of the paradoxical action of androgen on teleost gonads is quite uncertain at present. An extensive disturbance of the testicular stromal tissue influenced by the androgen treatment in the present study might have some significance in the occurrence of oviform germ cells, or testis-ova, in the affected testes, for the testicular stroma tissue plays an essential role in the testicular differentiation of the guppy¹⁷⁾. Hackmann⁴⁾ postulated that the ovarian differentiation takes place autonomically in sexually indifferent gonads if they are devoid of a presumed masculinizing substance, and that exogenous androgen enables the gonad of genetic males to carry out the ovarian differentiation through an inhibition of the synthesis of the specific masculinizing substance.

It is interesting to note in this context that the liver parenchymal cells of treated guppies displayed some cytological features similar to those seen in the liver cells affected by estrogen. In the male and immature female teleosts, the treatment with estrogen is effective in inducing a marked proliferation of granular endoplasmic reticulum which may be associated with an augmented synthesis

of yolk precursor proteins in the liver cells¹⁸⁾¹⁹⁾. It is certain that the androgen at high doses is responsible for the changes in the liver cells, since the liver cells recovered to normal rapidly after the hormone withdrawal and the changes in liver cells were undetected when the androgen doses were lower than 500 $\mu\text{g/g}$ diet. It is not possible, on the basis of the present study, to determine the functional significance of the changes in the liver cells. If the synthesis of some protein substance is actually induced by the androgen, no interpretation of the phenomenon can be given unless the nature of the protein is explored precisely.

References

- 1) Yamamoto, T. (1969). Sex Differentiation. p. 117-175. In Hoar, W.S. and Randall, D.J. (eds.), *Fish Physiology*, Vol. III, 485p. Academic Press, New York and London.
- 2) Müller, R. (1969). Die Einwirkung von Sexualhormonen auf die Geschlechtsdifferenzierung von *Hemihaplochromis multicolor* (Hilgendorf)-(Cichlidae). *Zool. Jahrb. Physiol.* **74**, 519-562.
- 5) Reinboth, R. (1969). Varying effects with different ways of hormone administration on gonad differentiation of a teleost fish. *Gen. Comp. Endocrinol.* **13**, 527-528.
- 4) Hackmann, E. (1974). Einfluss von Androgenen auf die Geschlechtsdifferenzierung verschiedener Cichliden (Teleostei). *Ibid.* **24**, 44-52.
- 5) Nakamura, M. (1975). Dosage-dependent changes in the effect of oral administration of methyltestosterone on gonadal sex differentiation in *Tilapia mossambica*. *Bull. Fac. Fish. Hokkaido Univ.* **26**, 99-108.
- 6) Yamamoto, T. (1958). Artificial induction of functional sex-reversal in genotypic females of the medaka (*Oryzias latipes*). *J. Exp. Zool.* **137**, 227-260.
- 7) Takahashi, H. (1974). Modification of the development of female reproductive organs in the guppy, *Poecilia reticulata*, following androgen treatment in their juvenile period. *Bull. Fac. Fish. Hokkaido Univ.* **25**, 174-199.
- 8) Takahashi, H. (1975). Functional masculinization of female guppies, *Poecilia reticulata*, influenced by methyltestosterone before birth. *Bull. Jap. Soc. Sci. Fish.* **41**, 499-506.
- 9) Takahashi, H. (1975). Functional feminization of genetic males of the guppy, *Poecilia reticulata*, treated with estrogen after birth. *Bull. Fac. Fish. Hokkaido Univ.* **26**, 223-234.
- 10) Jalabert, B., Billard, R. and Chevassus, B. (1975). Preliminary experiments on sex control in trout: Production of sterile fishes and simultaneous self-fertilizable hermaphrodites. *Ann. Biol. Anim. Bioch. Biophys.* **15**, 19-28.
- 11) Goodrich, H.B., Dee, J.E., Flynn, C.M. and Mercer, R.N. (1934). Germ cells and sex differentiation in *Lebistes reticulatus*. *Biol. Bull.* **67**, 83-96.
- 12) Anteunis, A. (1959). Recherches sur la structure et le développement de l'ovaire et de l'oviducte chez *Lebistes reticulatus* (Téléostéen). *Arch. Biol.* **70**, 783-809.
- 13) Grobstein, C. (1948). Optimum gonopodial morphogenesis in *Platyopocilus maculatus* with constant dosage of methyl testosterone. *J. Exp. Zool.* **109**, 215-237.
- 14) Ishii, S. (1957). Effects of estradiol benzoate on induction of gonopodial-like structure by testosterone in females of the guppy, *Lebistes reticulatus*. *J. Fac. Sci., Univ. Tokyo*, IV, *Zool.* **8**, 149-162.
- 15) Clemens, H.P. and Insee, T. (1968). The production of unisexual broods by *Tilapia mossambica* sex-reversed with methyl testosterone. *Trans. Amer. Fish. Soc.* **97**, 18-21.
- 16) Berkowitz, P. (1938). The effects of estrogenic substances in *Lebistes reticulatus* (guppy). *Anat. Rec.* **71**, 161-175.

TAKAHASHI: Effects of large doses of androgen in guppy

- 17) Takahashi, H. (1975). Process of functional sex reversal of the gonad in the female guppy, *Poecilia reticulata*, treated with androgen before birth. *Devel. Growth Differ.* **17**, 167-175.
- 18) Ishii, K. and Yamamoto, K. (1970). Sexual differences of the liver cells in the goldfish, *Carassius auratus* L. *Bull. Fac. Fish. Hokkaido Univ.* **21**, 161-167.
- 19) Aida, K., Hirose, K., Yokote, M. and Hibiya, K. (1973). Physiological studies on gonadal maturation of fishes. II. Histological changes in the liver cells of ayu following gonadal maturation and estrogen administration. *Bull. Jap. Soc. Sci. Fish.* **39**, 1107-1115.