



HOKKAIDO UNIVERSITY

Title	Histological Characteristics of Cataractous Eye Lenses in Cultured Masu Salmon
Author(s)	WATANABE, Yoshirou; 渡辺, 良朗; YAMADA, Juro et al.
Citation	北海道大學水産學部研究彙報, 31(4), 290-296
Issue Date	1980-11
Doc URL	https://hdl.handle.net/2115/23729
Type	departmental bulletin paper
File Information	31(4)_P290-296.pdf



Histological Characteristics of Cataractous Eye Lenses in Cultured Masu Salmon

Yoshiro WATANABE* and Juro YAMADA*

Abstract

Histological investigations were carried out on cataractous and transparent crystalline lenses of cultured masu salmon. The abnormal lenses were classified into four types based on the affected regions and states. Type I: Collapse of lens fibers in the anterior cortex; Type II: Partial collapse of lens fibers in the deeper portion of the anterior pole; Type III: Disorder of lens fibers at the posterior cortex; Type IV: Increment in thickness or collapse of the hyaline layer around the anterior pole. Two lenses from a fish showed the same type of abnormality in almost the same extent. Among 68 opaque lenses examined, 26 were type I, 21 were type II, and more than 60% of these two types of lenses also showed the abnormalities of type III or type IV. Some lenses showing only type III or type IV abnormalities were not opacified. On the other hand, all of the type I or type II lenses were opacified.

Introduction

In recent years, fish farms throughout Japan reported frequent occurrence of a cataract in many salmonid species including *Oncorhynchus masou*, *O. rhodurus*, *O. nerka*, *O. kisutch*, and *Salmo gairdneri*¹⁾²⁾³⁾. Since 1974 in southern Hokkaido, a high percentage of cataractous masu salmon, *O. masou*, have been found in a hatchery at Mori. Although the cataract does not cause the death of fish, it affects the growth by lowering the visual activity at feeding⁴⁾, and it is desired to clarify the nature and the cause of this disease as soon as possible.

In mammals, various types of cataracts showing different histological characteristics are known to occur. Among those the human senile cataract has been best studied⁶⁾⁻¹⁶⁾. According to the site of an opaque region in the crystalline lens, this cataract is classified into two main types⁶⁾⁹⁾¹¹⁾¹⁴⁾¹⁶⁾: the cortical cataract, and the nuclear cataract. In the cortical cataract, the cause of opacification is the increment of the interfibrillar spaces in the cortical region of the lens¹¹⁾¹⁵⁾. On the other hand, lenses of the nuclear cataract show no histologically detectable changes and the opacification is considered to be caused by the degeneration of soluble lens proteins⁹⁾¹⁰⁾¹²⁾¹³⁾¹⁵⁾. In the hereditary cataract in mice, abnormal proliferation of the lens epithelial cells and collapse of the lens fibers are observed accompanied by the opacification of the lens¹⁷⁻²⁰⁾.

Studies of histopathology of cataracts in fishes are few¹⁾³⁾⁵⁾ and pathological characteristics of fish cataracts are not well understood. In examining cataractous lenses of masu salmon cultured in the hatchery at Mori, we have found

* Laboratory of Physiology and Ecology, Faculty of Fisheries, Hokkaido University
(北海道大学水産学部生理学生態学講座)

that a variety of histological abnormalities are involved in this disease. The histological characteristics of the normal and cataractous lenses will be described in this paper.

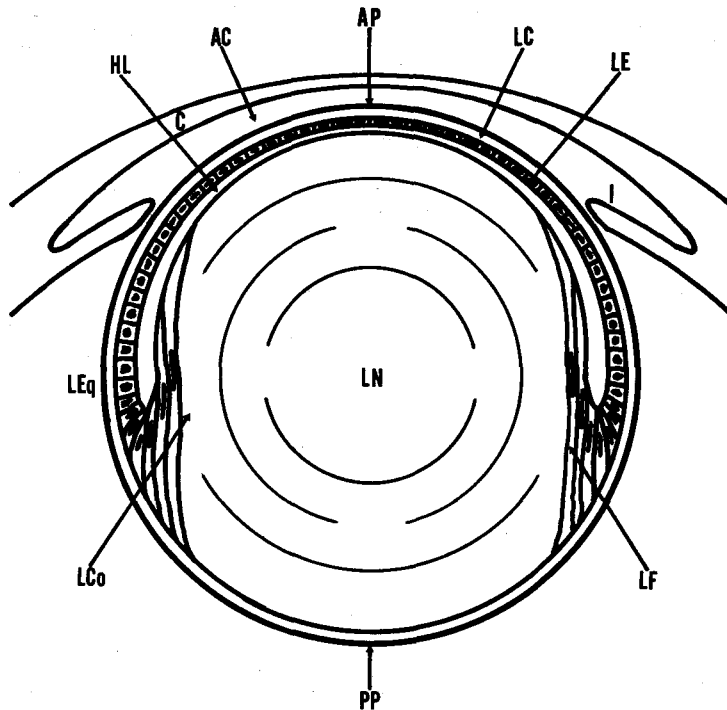
Materials and Methods

About eighty individuals of masu salmon (*Oncorhynchus masou*), hatched and reared at Mori Branch of Hokkaido Fish Hatchery, were used as materials. These included yearlings and 1- and 2-year-old fish having normal or turbid eyes in external appearance. The eyeballs were dissected out and fixed in 10% neutral formalin. The lenses were removed and sectioned at 6-8 μ by the routine paraffin method. The sections were stained with Delafield's hematoxylin and eosin and examined under a light microscope.

Results

The normal crystalline lens of masu salmon is a transparent, spherical body composed of, from the outer surface to inward, the lens capsule, the lens epithelium, the hyaline layer, and the lens fibers (Text-fig. 1, Fig. 1). The lens capsule covering the entire lens surface is a thin elastic tissue homogeneously and weakly stained with eosin. Beneath the anterior half of the lens capsule is a monolayer of flattened or cuboidal cells of the lens epithelium (Fig. 2). At the anterior pole, the epithelial cells are flat and have oval nuclei. Towards the lens equator the cells gradually become cuboidal with differently shaped nuclei (Fig. 3). These epithelial cells enter the interior of the lens at the equator becoming progressively elongated, and are transformed into fiber cells or lens fibers which constitute the bulk of the lens substance (Figs. 3, 4). The fiber cells maturing into the thin lens fibers show the cytoplasm faintly stained and the elongated nuclei strongly stained with hematoxylin (Figs. 3, 4). The fiber cells finally lose their nuclei, and the cytoplasm becomes to be stained both with hematoxylin and eosin. The nuclear region of the lens consists of most matured fibers which are stained only with eosin. They are so tightly packed in the nuclear region that the individual fibers are hard to be distinguished. The hyaline layer is observed at the anterior half of the lens between the epithelium and the cortical fiber layer (Fig. 2). It is a thin homogeneous layer stained slightly with hematoxylin. This layer usually thickens near the lens equator (Fig. 5). The thickness of this layer differs by individuals.

The two lenses from a fish suffering from cataract showed the same extent of opacification. The opaque region was always restricted to the center of the lens (Fig. 6). However, a variety of histological abnormalities in different degrees were observed in various portions of the cataractous lenses. The abnormalities observed were: swelling of the lens capsule, proliferation of epithelial cells, vacuolization of the hyaline layer, and disorder or collapse of the lens fibers. All these abnormalities were not always found in one lens. Since the opacification of lenses is considered to be related to abnormalities of the lens fibers, the cataractous lenses were classified into four types on the basis of affected regions and states of the lens fibers.



Text-fig. 1. Diagrammatic representation of the lens and related structures of masu salmon.
AC: anterior chamber, AP: anterior pole, C: cornea, HL: hyaline layer, I: iris, LC: lens capsule, LCo: lens cortex, LE: lens epithelium, LEq: lens equator, LF: lens fiber, LN: lens nucleus, PP: posterior pole

Type I: Collapse of lens fibers in the anterior cortex (Figs. 7-13)

In lightly affected lenses, the fiber layer of the anterior pole region showed a heterogeneous staining affinity with hematoxylin (Figs. 7, 8). With the progress of this abnormality, the heterogeneously stained fiber area extended toward the lens nucleus and the cytoplasm of the lens fibers degenerated becoming eosinophilic granular fragments (Figs. 13, 14). Lenses of this type were generally accompanied by an abnormal appearance of the epithelium around the anterior pole. In the normal lens, the epithelium was a monolayer of flat cells covering the anterior half of the lens (Fig. 2). Whereas in type I abnormality, a proliferation of cells formed a stratified epithelium invading into the fiber layer and the capsule (Figs. 8-10). The proliferated cells were varied in shape, mostly round or oval, some being under differentiation into fiber cells (Fig. 9). The lenses of this type were often accompanied by a heterogeneous and swollen lens capsule (Fig. 11).

Type II: Partial collapse of lens fibers in the deeper portion of the anterior pole (Figs. 14, 15)

The collapsed fibers were eosinophilic and granular as observed in the lenses of advanced type I but occurred only at the anterior portion of the lens nucleus (Figs. 14, 15). The affected area was smaller than that in type I. Lenses of this type

were not accompanied by the abnormal epithelium or collapsed cortical fibers but sometimes showed the swollen capsule as frequently observed in type I (Fig. 15).

Type III: Disorder of lens fibers in the posterior cortex (Figs. 16-18)

This abnormality was observed only in the posterior half of the lens cortex. In the early stage of this abnormality, the fibers of the cortical layer were arranged loosely and showed a low staining affinity with hematoxylin (Figs. 16, 18). Wide interstices appeared between the fibers with the progress of this abnormality (Fig. 17). A mass of homogeneous material stained slightly with hematoxylin was sometimes observed invading into the outermost portion of the affected area (Fig. 18).

Type IV: Increment in thickness or collapse of the hyaline layer around the anterior pole (Figs. 19, 20)

Lenses of this type did not show any abnormalities of the epithelium and the lens fibers. The hyaline layer was abnormally thick and granular (Fig. 19) or alveolar (Fig. 20).

The two lenses from a fish showed an abnormality of one particular type sometimes with a slight difference in extent. Among 68 opaque lenses examined, the number of type I and type II was 26 and 21, respectively. More than 60% of lenses of these two types also showed the type III or type IV abnormalities. The lenses of type I and type II were always opacified. On the other hand, the lenses showing only type III or type IV were not always opacified regardless of the extent of the abnormalities.

Discussion

It is known that the lens fibers of the mammalian lenses gradually reduce their metabolic activity with maturation of fiber cells^{21,22}, while the epithelial cells maintain a high activity and control the exchange of materials between the lens and the aqueous humor²³. Since the lens of masu salmon is similar to that of mammals in fundamental structure, the function of the lens epithelium in this fish must be the same as in mammals. Therefore, the collapse or disorder of lens fibers found in the affected lenses seems to have an intimate relation with a functional or structural disorder of the lens epithelium.

In the hereditary cataract in mice, an abnormal proliferation of epithelial cells occurs around the anterior pole accompanied by a deformation and collapse of the lens fibers¹⁷⁻²⁰. This abnormality was considered to be caused by a hereditary defect of the epithelial cells. Clayton²⁴ and Clayton et al.²⁵ reported a chicken cataract characterized by abnormalities in the differentiation and cellular properties of the hyperplastic lens epithelium in particular strains selected on the basis of a high growth rate. Since the characteristics of the type I abnormality were similar to those of the chicken cataract and the hereditary cataract in mice, the type I abnormality may be regarded to be caused by a defect, even if not hereditary, of the lens epithelium.

Kubota¹ reported the abnormal proliferation of epithelial cells and eosinophilic granular degeneration of lens fibers in the lenses of cataractous salmonids. This

histological abnormality may be common with the type I in masu salmon. Thioacetamide-induced cataract in the rainbow trout (*S. gairdneri*) reported by von Sallmann et al.²⁶⁾ shows the same characteristics as the type I in its invasive proliferation of the lens epithelium.

Type II lenses showed common characteristics in morphological features of the lens fibers and the lens capsule with type I lenses, but differed from them in that 1) no histological changes were found in the lens epithelium and 2) collapse of lens fibers was restricted to a small area of the deeper anterior region of the lens. If the epithelium is responsible for the maintenance of lens fibers as discussed above, possible explanations for the cause of the type II abnormalities would be either: 1) the epithelium seemingly normal in morphology was in a functional disruption, or 2) different mechanisms other than defects of the epithelium were involved in the collapse of fibers. In the first case, the type II abnormality can be regarded to be in the initial stage of the type I.

The disorder and swelling of the lens fibers in the type III lenses were histologically similar to the senile cortical cataract in man¹¹⁾¹⁵⁾. In the cortical cataract, these changes of the lens fibers directly correlate with the opacification of the cortex. In masu salmon, however, the opacified region did not coincide with the region of the disordered fibers.

Lenses of type IV were characterized only by an abnormality of the hyaline layer. The presence of the hyaline layer has not been reported so far in mammalian and fish lenses. This structure is considered to be formed by the lens epithelium because it was observed beneath the epithelium only at the anterior surface of the lens. The thickness of this layer differed with individual lenses. Moreover, there were a few normal lenses which did not show this structure. Therefore, it is not clear whether or not the hyaline layer is a structure persistent in the normal lens.

Lenses of type I and type II were always opacified, hence the abnormalities of these lenses may be regarded to have serious influences on the opacification. On the other hand, lenses of type III and type IV were not always opacified. When opacified, the sites of histological abnormalities were not in accord with the opacified region.

The degree of opacification of both lenses from a fish was the almost equal and the two lenses showed the same type of histological abnormality. Therefore, the opacification and histological abnormalities of the lens are considered to be caused by some physiological factors which influence on both lenses such as, for example, nutritional conditions²⁷⁾. Since some opaque lenses showed no histological changes in the opaque region, the cause of opacification should be some chemical changes of lens proteins as have been reported in the nuclear cataract in man⁹⁾¹⁰⁾¹²⁾¹³⁾¹⁵⁾. Changes of lens proteins and electrolytes are to be reported in another paper.

Acknowledgement

We wish to express our thanks to Messrs. Masaaki UCHIYAMA and Mitsunori ATODA, the Mori Branch of Hokkaido Fish Hatchery, who supplied us with material fish.

References

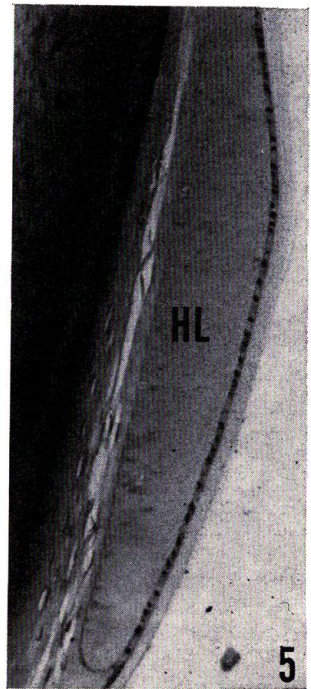
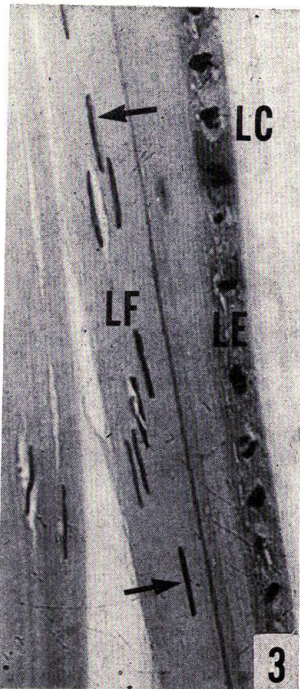


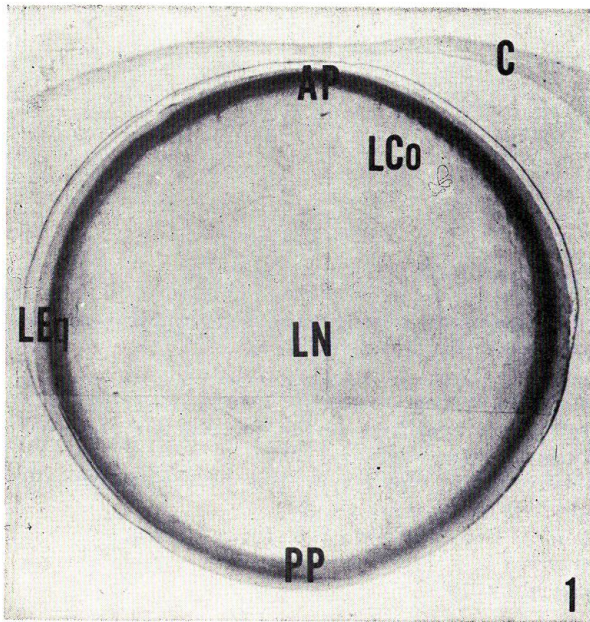
- 1) Kubota, S.S. (1976). Cataract in fishes: Pathological changes in the lens. *Fish Pathology*, **10**, 191-197.
- 2) Tashiro, F. and Kumazaki, T. (1974). Notes on the cataracta in the reared amago salmon, *Oncorhynchus rhodurus*. *Rep. Gifu Pref. Fish. Exp. Station*, **19**, 77-81. (In Japanese).
- 3) Matsuzato, T., Uematsu, K., and Tashiro, F. (1975). *Yōshoku amago no hakunaishō ni kansuru kenkyū - I. Gyobyō no hassei-jōkyō oyobi shyōjō ni tsuite*. *Fish Pathology*, **10**, 10-16. (In Japanese).
- 4) Hosoe, S. and Tashiro, F. (1979). Studies on the cataracta in salmonoid fishes - II. Influence of cataracta on the growth of amago salmon. *Rep. Gifu Pref. Fish. Exp. Station*, **24**, 51-54. (in Japanese with English abstract).
- 5) Awakura, T. (1978). *Sakeka-gyorui no hakunaishō* (Cataract). *Uo to mizu*, **17**, 10-13. (In Japanese).
- 6) Auricchio, G. and Testa, M. (1972). Some biochemical differences between cortical (pale) and nuclear (brown) cataracts. *Ophthalmologica*, **164**, 228-235.
- 7) Harding, J.J. (1972). Conformational changes in human lens proteins in cataract. *Biochem. J.*, **129**, 97-100.
- 8) Stauffer, J., Rothchild, C., Wandel, T., and Spector, A. (1973). Transformation of alpha-crystallin polypeptide chains with aging. *Invest. Ophthalm.*, **13**, 135-136.
- 9) Philipson, B. (1973). Changes in the lens related to the reduction of transparency. *Exp. Eye Res.*, **16**, 29-39.
- 10) Spector, A., Adams, D., and Krul, K. (1974). Calcium and high molecular weight protein aggregates in bovine and human lens. *Invest. Ophthalm.*, **13**, 982-990.
- 11) Maraini, G. and Torcoli, D. (1974). Electrolyte changes in the lens in senile cataract. *Ophthalm. Res.*, **6**, 197-205.
- 12) Dilley, K.J. (1975). The proportion of protein from the normal and cataractous human lens which exists as high molecular weight aggregates *in vitro*. *Exp. Eye Res.*, **20**, 73-78.
- 13) Dilley, K.J. and Harding, J.J. (1975). Change in proteins of human lens in development and aging. *Biochim. biophys. Acta*, **386**, 391-408.
- 14) Duncan, G. and Bushell, A.R. (1975). Ion analyses of human cataractous lenses. *Exp. Eye Res.*, **20**, 223-230.
- 15) van Heyningen, R. (1976). What happens to the human lens in cataract. *Scientific American (Japanese ed.)*, **6**(2), 62-70. (Translated into Japanese).
- 16) van Heyningen, R. (1969). The Lens: Metabolism and Cataract. p. 381-488. In Davson, H. (ed.), *The Eye*, Vol. 1. 679 p. Academic Press, New York.
- 17) Davidrof, F. and Eglitis, I. (1966). A study of a hereditary cataract in the mouse. *J. Morph.*, **119**, 89-100.
- 18) Zwaan, J. and Williams, R.M. (1968). Morphogenesis of the eye lens in a mouse strain with hereditary cataracts. *J. exp. Zool.*, **169**, 407-422.
- 19) Hamai, Y., Fukui, H.N., and Kuwabara, T. (1974). Morphology of hereditary mouse cataract. *Exp. Eye Res.*, **18**, 537-546.
- 20) Hamai, Y. and Kuwabara, T. (1975). Early cytologic changes of Fraser cataract. An electron microscopic study. *Invest. Ophthalm.*, **14**, 517-527.
- 21) Bloom, W. and Fawcett, D.W. (1975). *A Textbook of Histology* (10th ed.). 1033 p. Saunders, Philadelphia.
- 22) Waley, S.G. (1969). The Lens: Function and Macromolecular Composition. p. 299-350. In Davson, H. (ed.), *The Eye*, Vol. 1. 679 p. Academic Press, New York.
- 23) Duncan, G. (1974). Comparative Physiology of the Lens Membranes. p. 357-398. In Davson, H. and Graham, L.T., Jr. (ed.), *The Eye*, Vol. 5. 528 p. Academic Press, New York.
- 24) Clayton, R.M. (1975). Failure of growth regulation of the lens epithelium in strains

- of fast-growing chicks. *Genet. Res., Camb.*, 25, 79-82.
- 25) Clayton, R.M., Eguchi, G., Truman, D.E.S., Perry, M.M., Jacob, J. and Flint, O.P. (1976). Abnormalities in the differentiation and cellular properties of hyperplastic lens epithelium from strains of chickens selected for high growth rate. *J. Embryol. exp. Morph.*, 35, 1-23.
- 26) von Sallmann, L., Halver, J.E., Collins, E., and Grimes, P. (1966). Thiocetamide-induced cataract with invasive proliferation of the lens epithelium in rainbow trout. *Cancer Res.*, 26, 1819-1825.
- 27) Halver, J.E. (1957). Nutrition of salmonoid fishes III. Water-soluble vitamin requirements of chinook salmon. *J. Nutr.*, 62, 225-243.

Explanation of Plates

PLATE I

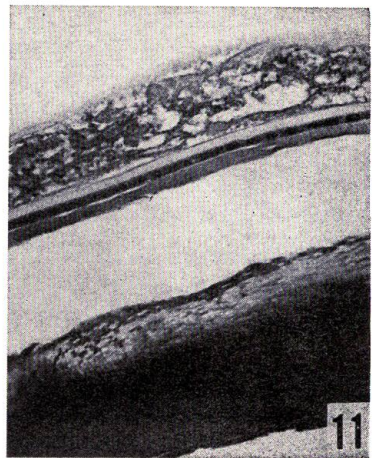
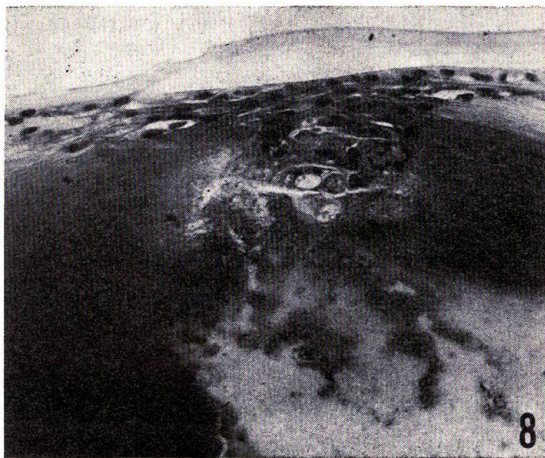
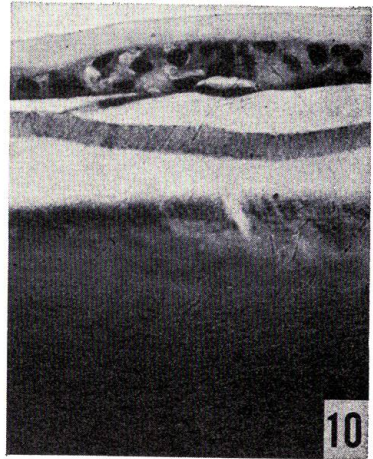
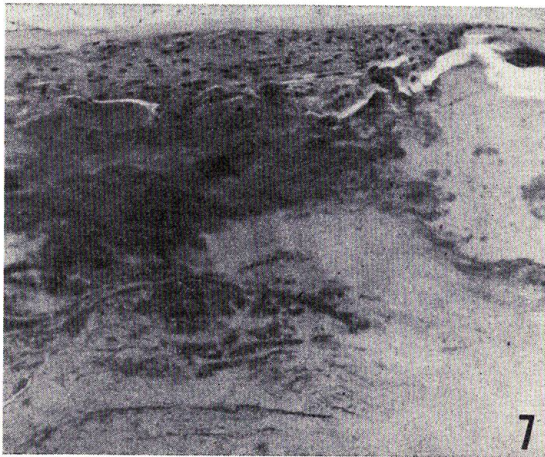
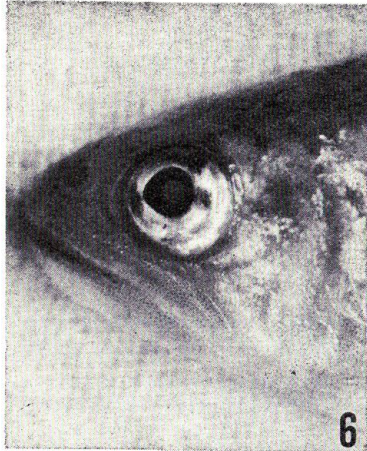
- Fig. 1. Vertical section of a normal lens through the anterior and the posterior poles. AP: anterior pole, C: cornea, LCo: lens cortex, LEq: lens equator, LN: lens nucleus, PP: posterior pole ($\times 26$)
- Fig. 2. Anterior pole region of normal lens. The epithelial cells (LE), having the oval nuclei, are thin and flat. The lens fibers (LF) take hematoxylin at the outermost layer and both hematoxylin and eosin at the inner layer. The lens capsule (LC) is homogeneous being slightly stained with eosin. The thin hyaline layer (HL) is observed under the lens epithelium (LE). ($\times 500$)
- Fig. 3. Normal epithelial cells and differentiating fibers at the lens equator. The epithelial cell nuclei are variable in shape. Differentiating fiber cells show their slender nuclei (arrow). ($\times 350$)
- Fig. 4. Normal epithelial cells transforming into lens fibers in the region posterior to the lens equator. ($\times 200$)
- Fig. 5. Thick hyaline layer (HL) observed at the lens equator of a normal lens. ($\times 100$)



WATANABE & YAMADA: Histology of salmon cataractous lens

PLATE II

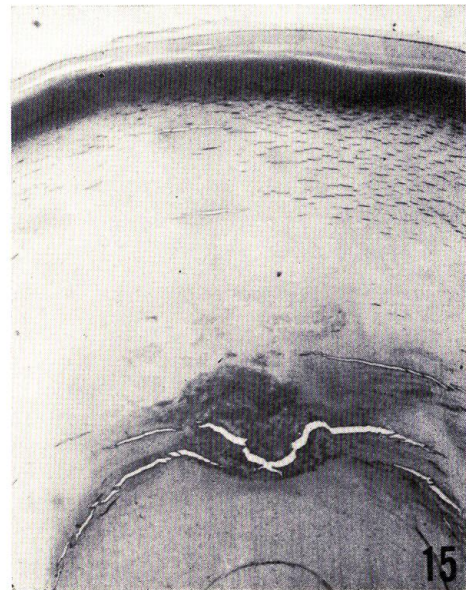
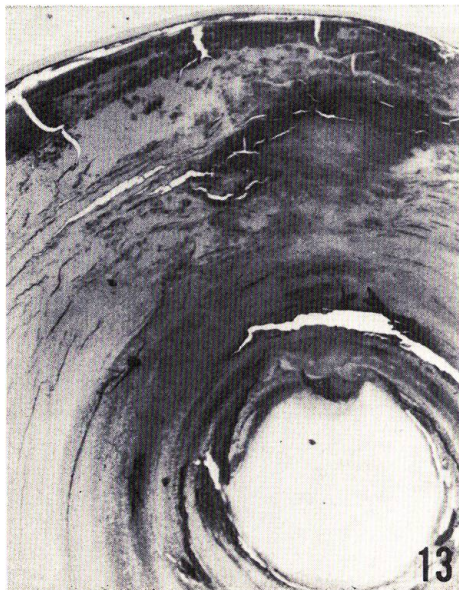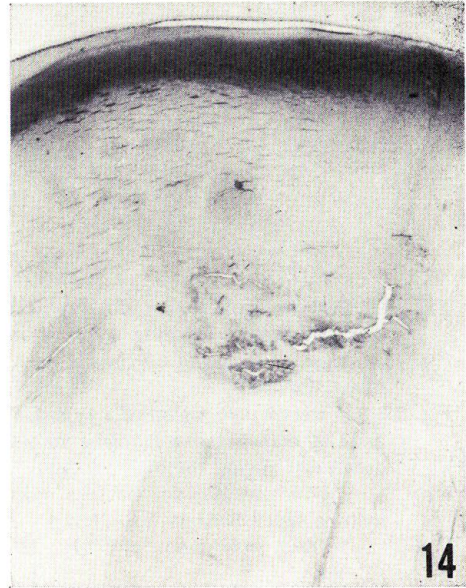- Fig. 6. Juvenile masu salmon (*Oncorhynchus masou*) showing the eye suffering from cataract. The opaque region is seen restricted to the center of the eye.
- Fig. 7. The anterior pole region of a type I lens. Stratified epithelial cells are invading into the fiber layer which is stained heterogeneously. ($\times 200$)
- Fig. 8. Massive epithelial cells invading into lens fibers at the anterior pole of type I lens. The fiber layer is stained heterogeneously. ($\times 200$)
- Fig. 9. Stratified epithelial cells observed in a type I lens. The inner epithelial cells appear to be transforming into fiber cells (arrow). ($\times 350$)
- Fig. 10. Epithelial cells invading into the lens capsule of a type I lens. ($\times 350$)
- Fig. 11. Abnormal lens capsule observed in a type I lens. The lens capsule shows a meshwork at the swollen portion. ($\times 150$)



WATANABE & YAMADA: Histology of salmon cataractous lens

PLATE III

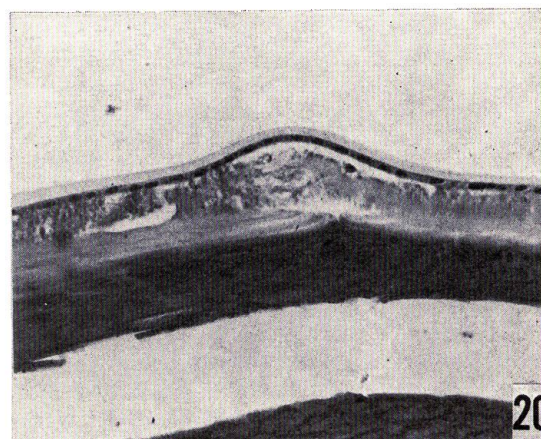
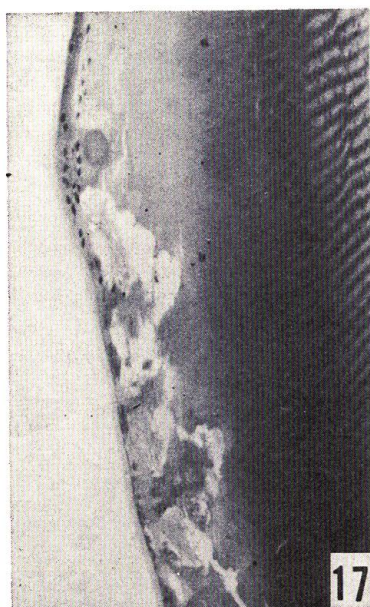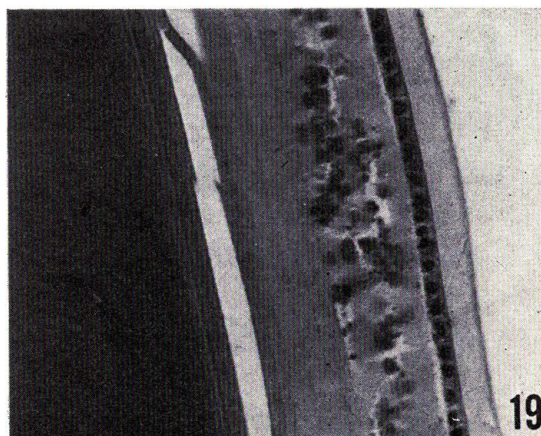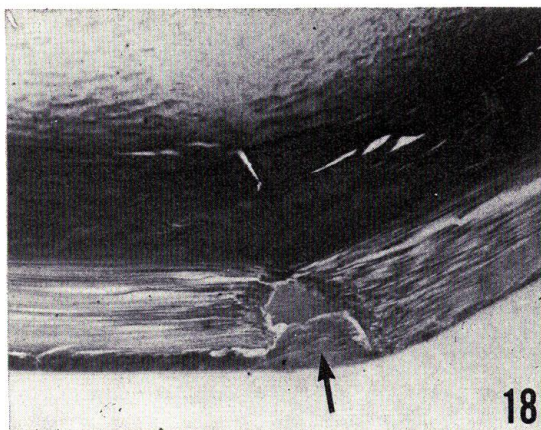
- Fig. 12. Advanced stage of the type I abnormality. Stratified epithelial cells are accompanied with the irregularly stained and degraded fiber layer in a large area. ($\times 35$)
- Fig. 13. Degradation of the lens fibers at the anterior half of a type I lens. ($\times 35$)
- Fig. 14. Anterior region of a type II lens. Inner fibers anterior to the lens nucleus are locally degraded and eosinophilic. ($\times 35$)
- Fig. 15. Advanced stage of the type II abnormality. Local degradation of lens fibers which became eosinophilic is seen just anterior to the lens nucleus. The swollen lens capsule is observed at the anterior pole region. ($\times 35$)



WATANABE & YAMADA: Histology of salmon cataractous lens

PLATE IV

- Fig. 16. Posterior pole region of a type III lens. The lens fibers of the cortical layer are arranged loosely showing a low staining affinity with hematoxylin. ($\times 200$)
- Fig. 17. Equator region of a type III lens. A number of gaps are observed between lens fibers. ($\times 100$)
- Fig. 18. Posterior pole region of a type III lens showing increased interfibrillar spaces. A mass of homogeneous material stained slightly with hematoxylin is observed at the outermost region (arrow). ($\times 100$)
- Fig. 19. Region anterior to the lens equator showing the type IV abnormality. The hyaline layer became granular. ($\times 200$)
- Fig. 20. Anterior pole region of a type IV lens. The degraded hyaline layer is noted. ($\times 200$)



WATANABE & YAMADA: Histology of salmon cataractous lens