



# HOKKAIDO UNIVERSITY

Title	Sexual Difference in Ultrastructure of the Ultimobranchial Gland of Mature Eels ( <i>Anguilla japonica</i> )
Author(s)	YAMANE, Shigetaka; 山根, 重孝
Citation	北海道大學水産學部研究彙報, 32(1), 1-5
Issue Date	1981-03
Doc URL	<a href="https://hdl.handle.net/2115/23737">https://hdl.handle.net/2115/23737</a>
Type	departmental bulletin paper
File Information	32(1)_P1-5.pdf



## Sexual Difference in Ultrastructure of the Ultimobranchial Gland of Mature Eels (*Anguilla japonica*)

Shigetaka YAMANE\*

### Abstract

The ultimobranchial gland of mature Japanese eels (*Anguilla japonica*) was examined by electron microscopy. The gland was composed of a pair of single follicles consisting of two types of cells, agranular and granular. Distinct sexual differences were observed between the glands of a mature male and a mature female. In the mature male, the height of the gland epithelium was low, the fine structural aspect of the granular cells suggested their low activity. In contrast, the gland of the mature female showed highly active features, i.e., increased height of the epithelium, and the markedly developed r-ER, accumulation of numerous secretory granules and well-developed Golgi apparatus in the granular cells.

### Introduction

Ultimobranchial glands of fishes are well-known to produce and secrete a peptide hormone called calcitonin. However, the physiological role of this hormone in fishes remains unclear. The histological observations on the ultimobranchial gland in *masu* salmon led us to the hypothesis that the gland may play some sex-related role in the female, because it was most active in pre-ovulating females but inactive in mature males.<sup>1)</sup> The same sexual difference was also observed in maturing or matured Japanese eels,<sup>2)</sup> zebrafish<sup>3)</sup>, goldfish (Yamane, unpublished) and rainbow trout (Yamane, unpublished). These findings are in accord with the biochemical results that the blood calcitonin concentration of mature females is remarkably higher than that of mature males in salmon<sup>4)5)</sup> and the Japanese eel.<sup>6)</sup>

In this paper, ultrastructural characteristics and sexual differences of the ultimobranchial gland in mature Japanese eels will be described to corroborate the previous histological observations.<sup>2)</sup>

### Materials and Methods

Silver eels (*Anguilla japonica*) were collected in autumn from rivers near Hiranuma, Aomori Prefecture, Japan. They were acclimated stepwise to

---

This work is a part of the thesis submitted for partial fulfillment of the requirements for the degree of Doctor of Fisheries at Hokkaido University.

\* *Laboratory of Physiology & Ecology, Faculty of Fisheries, Hokkaido University*

(北海道大学水産学部生理学生態学講座)

Present address: *Chemical Biotesting Center, Chemicals Inspection & Testing Institute, 19-14, Chuo-cho, Kurume, Fukuoka 830, Japan*

(現住所: 化学品検査協会 化学品安全センター 830 福岡県久留米市中央町 19-14)

seawater, and kept at  $18 \pm 1^\circ\text{C}$  without feeding. Sexual maturation was induced experimentally following the procedure by Yamamoto et al.<sup>7)8)</sup>; males were intramuscularly injected weekly with 200 IU human chorionic gonadotropin (HCG: Gonatoropin, Teikoku Hormone Mfg. Co., Tokyo) per 100 g body weight until the spermiation was attained, and females with 2 mg of acetone-dried powder of chum salmon pituitaries per 100 g body weight until ovarian maturation. One female and one male were chosen as materials among many matured fish. The female showed a high gonadosomatic index (45.2) calculated by the gonad weight  $\times 100/\text{body weight}$ .

After the eels were anesthetized with MS-222, the ventral abdomen was incised longitudinally to expose the esophagus. A mixture of 2.5% glutaraldehyde and 2% paraformaldehyde in 0.1 M phosphate buffer was poured around the esophagus, and the ultimobranchial gland was removed together with adjacent tissues. The gland was cut into several pieces by a razor blade and fixed in the same mixture for 2 hours. The tissues were then postfixed with 1% osmium tetroxide in 0.1 M phosphate buffer for 1.5 hours, rinsed, dehydrated and embedded in Epon-812. Thin sections were cut on a Porter-Blum ultramicrotome using glass knives, stained with uranyl acetate and lead citrate, and examined on a Hitachi HS-12 electron microscope. For light microscopy, semi-thin sections were cut on the same ultramicrotome, and stained by warming with 1% methylene blue in 1% borax.

### Observations

The ultimobranchial gland of mature Japanese eels was observed as a pair of single follicles in the connective tissue beneath the ventral wall of the esophagus. The gland of a mature male was ellipsoid in shape, and the follicular epithelium was low in height (Fig. 1). In contrast, the gland of a mature female was characterized by cellular hypertrophy and tissue hyperplasia that result in pseudostratification of the follicular epithelium (Fig. 2) and by a rich supply of blood capillaries, as described in the previous paper<sup>2)</sup>. In both sexes two distinctly different types of cells, agranular and granular, were distinguished in the epithelium.

The agranular cells, having no secretory granules, were small in size and counted about one third of the total number of gland cells. Most of them bordered the follicular lumen of the gland but some elongated from the luminal surface to the basement membrane through the epithelium. They were interconnected by desmosomes which were usually followed by extensive interdigitations of the cell surfaces (Fig. 3). A few microvilli and cilia were on the apical luminal surface of the cells. Their nuclei, stained with methylene blue in semi-thin sections, showed irregular outlines with marginal indentations and had rich chromatin distributed along the nuclear envelope. Many pinocytotic invaginations were found at the basal and lateral plasma membranes (Fig. 4). Free ribosomes of a rosette pattern and a fine network of tubules of the endoplasmic reticulum were detected throughout the cytoplasm. Small dense lysosomal bodies occurred occasionally. Mitochondria were small, and round or oval in shape.

Golgi apparatus were of small dimensions and exhibited frequent dilatations of the lamellae. Bundles of tonofilaments were running parallel with the lateral plasma membrane of the cells which elongated through the epithelium.

The granular cells were characterized by accumulation of numerous secretory granules (Fig. 5). The cells never bordered the follicular lumen. Their round or oval nuclei were larger and usually exhibited smoother surfaces than those of the agranular cells. In semi-thin sections the nuclei did not take methylene blue except for nucleoli. A few small clumps of chromatin were distributed along the nuclear envelope. The rough surfaced-endoplasmic reticulum (r-ER) and Golgi apparatus were well developed. Materials of a similar electron density to the secretory granules were frequently contained in the terminations of Golgi lamellae, around which some immature granules were observed. The secretory granules were round or oval and varied from 150 to 450 nm in diameter. Each granule had the core of a variable electron-density. In semi-thin sections the granules were stained with methylene blue. The granules tended to aggregate in the basal portion of the cell. Some multivesicular bodies and lysosomes were found among the granules. Bundles of tonofilaments were not as much as those found in agranular cells. Mitochondria of various shapes with tubular cristae and without mitochondrial granules were scattered throughout the cytoplasm. Smooth membrane-limited vesicles of various sizes were distributed among the secretory granules in the basal cytoplasm. Pinocytotic invaginations were rarely found at the basal and lateral plasma membranes.

#### *Mature male*

The epithelium was low in height. The agranular cells were sometimes found to extend from the luminal surface to the basement membrane. The plasma membrane of granular cells usually exhibited extensive infoldings because of poor development of cell organelles (Fig. 5). Small tubular profiles of the r-ER were often observed close to Golgi apparatus. The Golgi lamellae occasionally contained electron dense materials which appeared to be pre-secretory granules. Only a few immature secretory granules were found near the Golgi apparatus.

#### *Mature female*

Due to a marked development of the r-ER and accumulation of numerous secretory granules, the granular cells were hypertrophied and raised the epithelium high. The apical area of the cells was often occupied with extensive lamellar arrays of the r-ER (Fig. 6), while the basal area was tightly packed with numerous secretory granules (Fig. 7). Small tubular profiles of the r-ER often intruded among the granules. Well-developed Golgi apparatus with the saccules containing pre-secretory granules in their terminations were usually situated close to the r-ER. Many immature secretory granules of a high electron density were located in the proximity of the Golgi apparatus. The development of these cell organelles made the granular cells expand and the cell membranes smooth. A decrease in the number of secretory granules was observed in some of the granular cells facing the basement membrane (Fig. 8). On the other hand, apparently degenerating granules were detected in the cytoplasm of some granular cells (Fig. 9). These granules gathered closely with each other and

contained materials of a low electron density. Their limiting-membranes were often disrupted partially. Occasionally, degenerating granular cells characterized by their dark cytoplasm and swollen r-ER were found in places.

### Discussion

As shown in the previous light-microscopic examinations<sup>2)</sup>, the glandular activity of a mature female eel was much higher than that of a mature male. The female gland revealed cellular hypertrophy, tissue hyperplasia and extensive blood capillaries surrounding the parenchyma. The cellular hypertrophy was proved to be the result of the development of the extensive r-ER and accumulation of numerous secretory granules in the granular cells. In addition, the granular cells of the mature female exhibited an enlargement of Golgi apparatus with many immature secretory granules around them. All these features indicate a high activity in producing and secreting secretory granules. In some granular cells of the mature female the secretory granules appeared to be almost exhausted, although direct evidence of discharge of the granules could not be demonstrated. These morphological findings are consistent with the radioimmunological results by Yamauchi et al.<sup>6)</sup> that the concentration of blood calcitonin in mature female eels was much higher than in mature males. Yamauchi et al.<sup>9)</sup> reported that the function of the gland of Japanese eels may be most active at the spawning phase. The sexual differences in morphology of the ultimobranchial gland were also observed in *masu* salmon,<sup>1)</sup> zebrafish<sup>3)</sup>, rainbow trout (Yamane, unpublished) and goldfish (Yamane, unpublished). It appears certain, therefore, that the ultimobranchial glands or calcitonin in fishes are involved in the process of maturation of the ovary or in some related processes.

The sexual differences were more distinct in the Japanese eel, *masu* salmon, and rainbow trout than in zebrafish and goldfish. It is of interest to note that in the Japanese eel, *masu* salmon, and rainbow trout the gland consists of a pair of single large follicles while in zebrafish and goldfish it is a mass of many small follicles.

Two types of cells, agranular and granular, were definitely distinguished in the gland of the Japanese eel. The agranular cells exhibited essentially the same topographical and morphological characteristics as in *masu* salmon, zebrafish and goldfish; they border the follicular lumen and have no secretory granules and poor cell organelles. Kitoh<sup>10)</sup> also described two types in the ultimobranchial gland of two species of elasmobranchs, *Mustelus manazo* and *Dasyatis akajei*, viz., the barrel cells having secretory granules, and the finger cells thinly elongated between the barrel cells. The barrel cells and the finger cells may correspond respectively to granular cells and agranular cells in this study.

Possibility for the discharge of secretory granules into the lumen may be excluded because the granular cells never faced the follicular lumen in the Japanese eel.

### Acknowledgements

I wish to express my deepest appreciation to Professor Jurô Yamada of the Faculty of Fisheries, Hokkaido University, for his kindness in reading the manuscript. Thanks are also due to Professor Hiroya Takahashi and Assistant Professor Kazunori Takano, and Dr. Kouhei Yamauchi of the Faculty of Fisheries, Hokkaido University, who allowed me to examine the material fish.

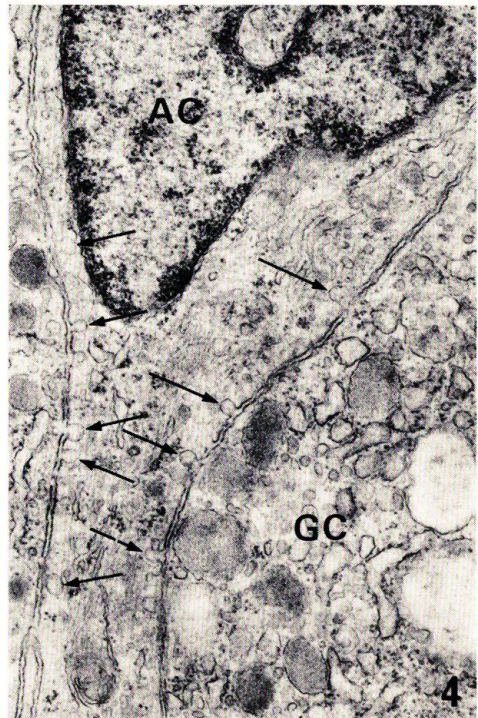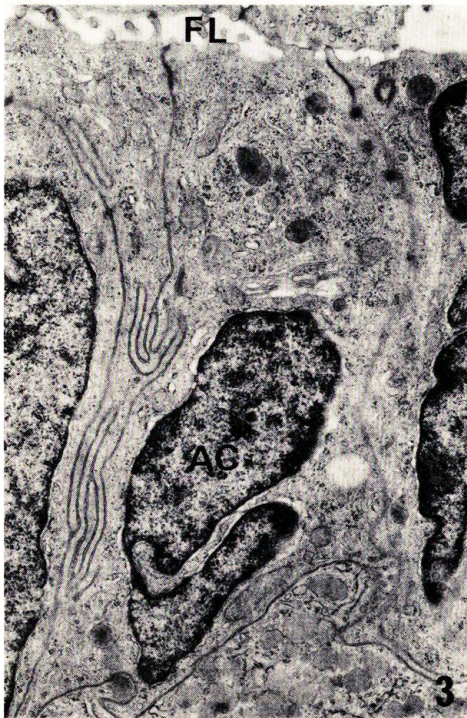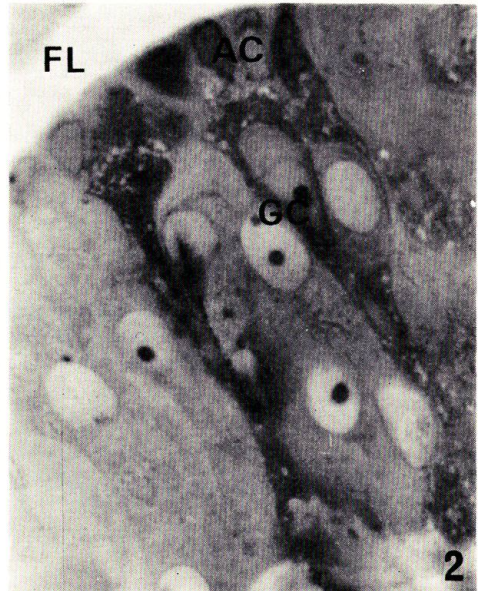
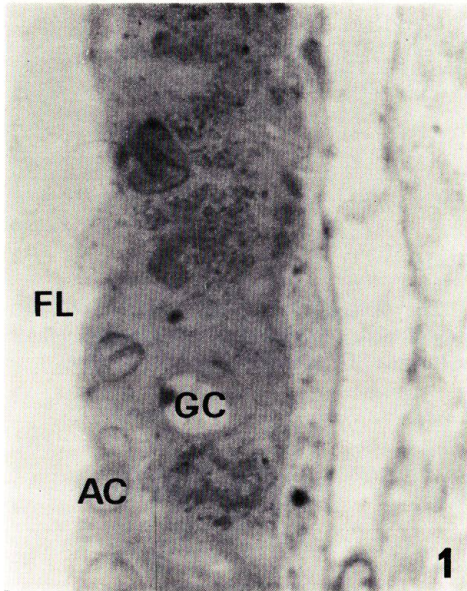
### References

- 1) Yamane, S. & Yamada, J. (1977). Histological changes of the ultimobranchial gland through the life history of the *Masu* salmon. *Bull. Japan. Soc. Sci. Fish.*, **43**: 375-386.
- 2) Yamane, S. (1977). Sexual difference in histology of the ultimobranchial gland of mature Japanese eels (*Anguilla japonica*). *Zool. Magazine*, **86**: 261-263.
- 3) Yamane, S. (1978). Histology and fine structure of the ultimobranchial gland in zebrafish, *Brachydanio rerio*. *Bull. Fac. Fish. Hokkaido Univ.*, **29**: 213-221.
- 4) Deftos, L.J., Watts, E.G., Copp, D.H. & Potts, J.T. Jr. (1974). A radioimmunoassay for salmon calcitonin. *Endocrinol.*, **94**: 155-160.
- 5) Watts, E.G., Copp, D.H. & Deftos, L.J. (1975). Changes in plasma calcitonin and calcium during the migration of salmon. *Endocrinol.*, **96**: 214-218.
- 6) Yamauchi, H., Matsuo, M., Yamauchi, K., Takano, K. & Takahashi, H. (1976). Studies on ultimobranchial calcitonin. 4. Serum calcitonin levels in eel. *Igaku no Ayumi*, **99**: 499-500. (in Japanese).
- 7) Yamamoto, K., Hiroi, O., Hirano, T. & Morioka, T. (1972). Artificial maturation of cultivated male Japanese eels by synahorin injection. *Bull. Japan. Soc. Sci. Fish.*, **38**: 1083-1090.
- 8) Yamamoto, K., Morioka, T., Hiroi, O. & Omori, M. (1974). Artificial maturation of female Japanese eels by the injection of salmon pituitary. *Bull. Japan. Soc. Sci. Fish.*, **40**: 1-7.
- 9) Yamauchi, H., Orimo, H., Yamauchi, K., Takano, K. & Takahashi, H. (1978). Increased calcitonin levels during ovarian development in the eel, *Anguilla japonica*. *Gen. Comp. Endocrinol.*, **36**: 526-529.
- 10) Kitoh, J. (1970). Electron microscopic studies of the ultimobranchial body of the elasmobranchs. *Arch. histol. Jpn.*, **31**: 269-281.

## Explanation of Plates

### PLATE I

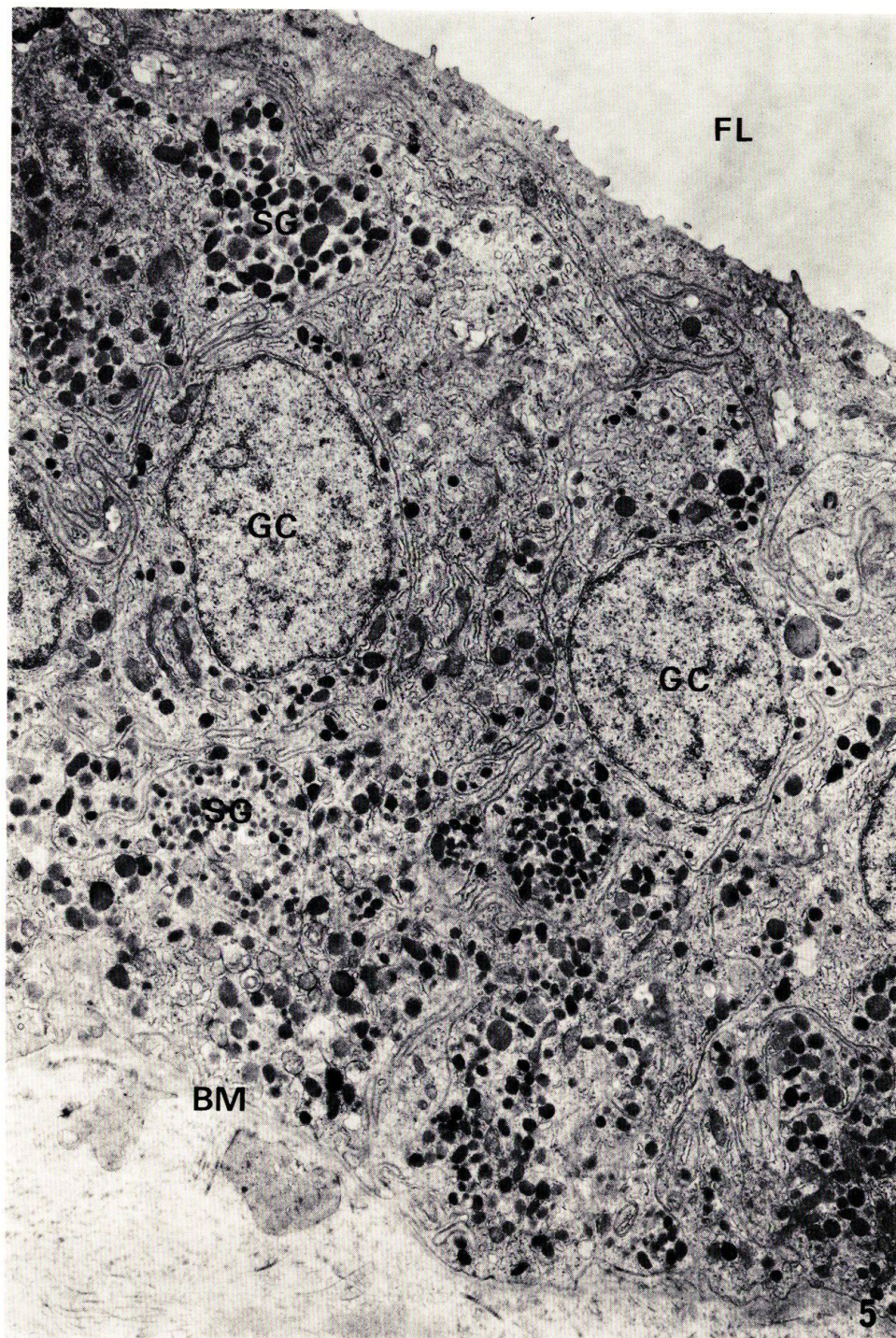
- Fig. 1 Epithelium of the ultimobranchial gland of a mature male. Semi-thin section stained with methylene blue. AC: agranular cell; FL: follicular lumen; GC: granular cell.  $\times 1500$ .
- Fig. 2. Epithelium of the ultimobranchial gland of a mature female. Granular cells (GC) show extensive cellular hypertrophy. Semithin section stained with methylene blue. AC: agranular cell; FL: follicular lumen.  $\times 1500$ .
- Fig. 3. Agranular cells (AC) bordering the follicular lumen (FL) (mature female).  $\times 10400$ .
- Fig. 4. Agranular cell (AC) showing many pinocytotic invaginations (arrows) along the lateral cell membrane (mature female). GC: granular cell.  $\times 20800$ .



YAMANE: Ultimobranchial gland of eel

**PLATE II**

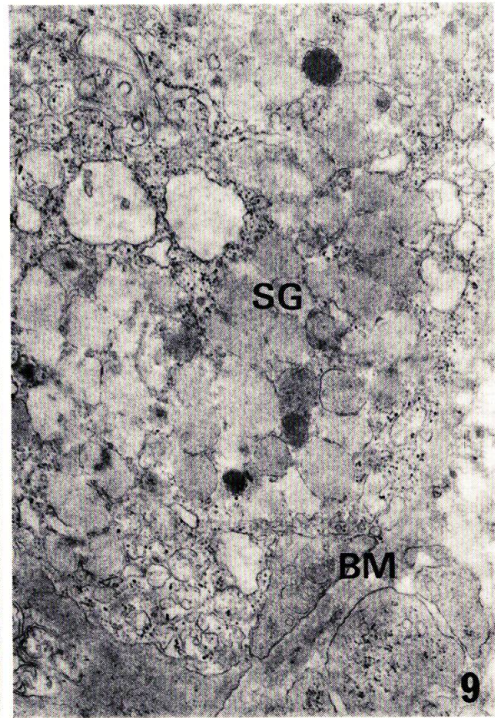
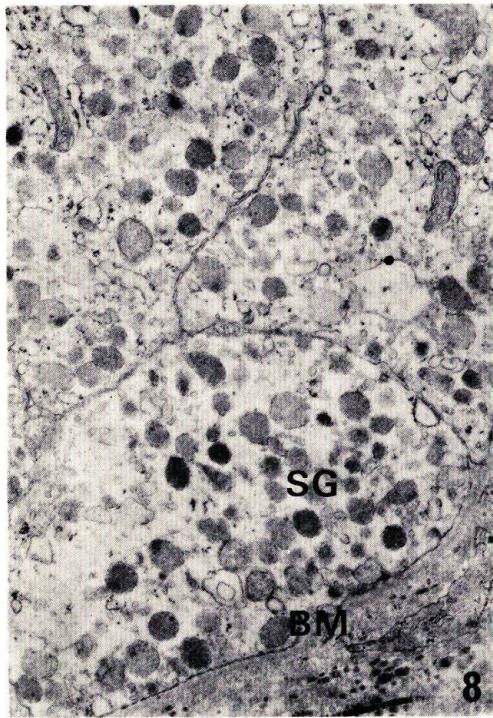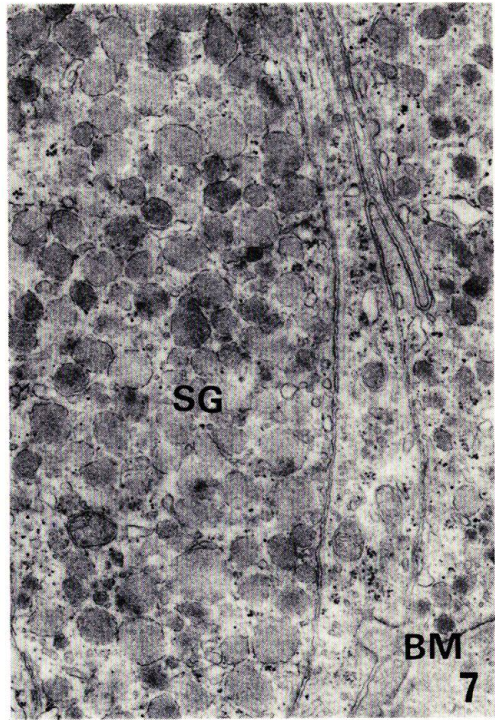
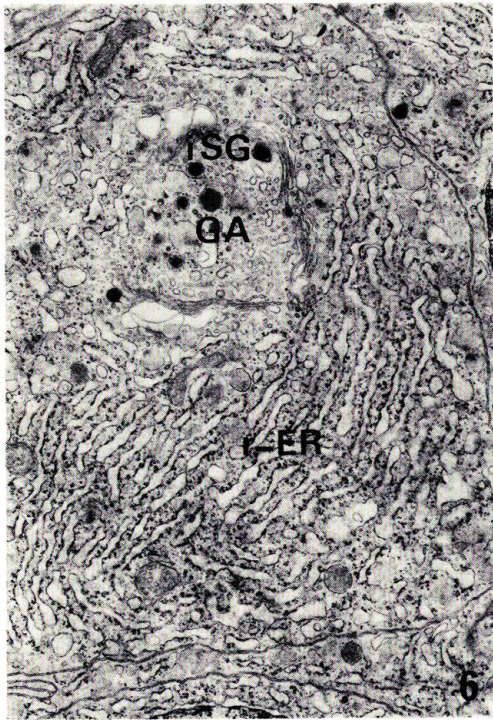
**Fig. 5.** Gland epithelium of a mature male. The plasma membranes of granular cells (GC) exhibit extensive infoldings because of poor development of cell organelles. **BM:** basement membrane; **FL:** follicular lumen; **SG:** secretory granule.  $\times 6600$ .



YAMANE: Ultimobranchial gland of eel

### PLATE III

- Fig. 6. Extensive lamellar arrays of the r-ER and a well-developed Golgi apparatus (GA) in a granular cell (mature female). iSG: immature secretory granule.  $\times 10300$ .
- Fig. 7. Basal area of granular cells packed with numerous secretory granules (SG) (mature female). BM: basement membrane.  $\times 14900$ .
- Fig. 8. Basal area of granular cells in which a decrease in number of secretory granules (SG) is observed (mature female). BM: basement membrane.  $\times 12600$ .
- Fig. 9. Basal area of a granular cell in which secretory granules (SG) are under a degenerative phase (mature female). BM: basement membrane.  $\times 14400$ .



YAMANE: Ultimbranchial gland of eel