



HOKKAIDO UNIVERSITY

Title	DISSEMINATED INTRAVASCULAR COAGULATION (DIC) IN RABBIT HAEMORRHAGIC DISEASE
Author(s)	UEDA, Kaoru; PARK, Jae-Hak; OCHIAI, Kenji et al.
Citation	Japanese Journal of Veterinary Research, 40(4), 133-141
Issue Date	1992-12-28
DOI	https://doi.org/10.14943/jjvr.40.4.133
Doc URL	https://hdl.handle.net/2115/2404
Type	departmental bulletin paper
File Information	KJ00002377608.pdf



DISSEMINATED INTRAVASCULAR COAGULATION (DIC) IN RABBIT HAEMORRHAGIC DISEASE

Kaoru UEDA, Jae-Hak PARK, Kenji OCHIAI, and Chitoshi ITAKURA

(Accepted for publication: Sep. 19, 1992)

ABSTRACT

Seven rabbits experimentally infected with rabbit haemorrhagic disease virus were examined haematologically and histologically. Haematologically, activated partial thromboplastin time and prothrombin time were markedly prolonged in the terminal phase of the disease, just prior to death (all the animals died between 27 and 40 hr after inoculation with rabbit haemorrhagic disease virus). There was an increase in the titre of fibrin degradation products and a decrease in antithrombin III activity during the same interval. Acute necrotic hepatitis and disseminated intravascular coagulation (DIC) in many organs, including the lung, kidney, spleen and heart were the characteristic histopathological changes. Thus, the haematological and histological changes suggested that DIC was induced by rabbit haemorrhagic disease virus infection. Severe liver necrosis was considered to be a factor causing DIC by inducing a hypercoagulable condition in the systemic blood circulation.

Key words: rabbit haemorrhagic disease, DIC, blood, hepatitis, calicivirus.

INTRODUCTION

Rabbit haemorrhagic disease (RHD) is an acute viral disease characterized by high mortality and necrotic hepatitis^{6,8)}. Recently, based on the morphological and physicochemical characteristics, the causative agent of RHD has been suggested to be a calicivirus^{7,9)}.

RHD virus has a predilection for hepatocytes and replicates in their cytoplasm⁸⁾. The liver is the principal site for the synthesis of several coagulation proteins²⁾. This organ also synthesizes protease inhibitors such as antithrombin III and protein C, and clears the activated clotting factor from the blood¹⁾. Disseminated intravascular coagulation (DIC) has been reported to follow acute hepatocellular necrosis in human patients^{3,5,10)}. In RHD characterized by necrotic hepatitis, DIC has been also reported histologically in many organs.

This article describes the haematological and histochemical findings related to DIC in rabbits experimentally infected with RHD virus, and discusses the cause of DIC.

MATERIALS AND METHODS

Inoculum and animals: A 20% suspension of liver homogenate from a rabbit experimentally infected with RHD virus originating from Korea was prepared in phosphate-buffered saline⁹. This suspension was used as the inoculum for the experiment.

Seven Japanese White rabbits weighing 2.9 to 4.1 kg were inoculated intramuscularly with 1.0 ml of the inoculum (HA titer of 2^{11}). Four age-matched rabbits were served as non-infected controls.

Haematology: From the 7 infected and 4 control (non-infected) rabbits, blood samples were collected into 3.8% trisodium citrate (9 parts blood and 1 part trisodium citrate) just prior to the experiment, at 12 hr after virus challenge and in the terminal phase of the disease just prior to death (at 24 hr after the start of the experiment in case of the control). The mean values of all blood examinations for the non-infected animals were used as the control.

The haematocrit value (%) was read after centrifugation of whole blood at 5000 g for 5 min in a capillary tube. Red blood cells, total leukocytes and platelets were counted in the whole blood by the Turk, Hayem and Rees-Ecker methods, respectively. Activated partial thromboplastin time (APTT), prothrombin time and the amount of fibrinogen were measured in blood plasma using an automated analyzer (Cobas Fibro, Roche, Swiss). Antithrombin III was determined according to the modified von Kaulla and von Kaulla¹⁴ method. Briefly, in order to remove the fibrinogen, blood plasma was heated at 54°C for 3 min followed by centrifugation at 1500 g for 10 min. The supernatant plasma diluted with the same volume of veronal buffer (pH 7.35) was reacted with the same volume of thrombin solution (10 units/ml, bovine thrombin, Sigma) at 37°C for 5 min. After the same volume of fibrinogen solution (1%, bovine fibrinogen, Sigma) was added to the mixture, clotting time was checked and demonstrated as a per cent against those of the samples collected just prior to the experiment. Titres of fibrin degradation products were determined by latex agglutination using a reagent for D dimer (Boehringer Mannheim Yamanouchi, Japan)

Histopathology: Tissues from the infected (dead) and control (killed at 24 hr after the start of the experiment) rabbits were fixed in 10% formalin and embedded in paraffin wax. Sections were stained with haematoxylin and eosin (HE), phosphotungstic acid haematoxylin (PTAH), Masson trichrome and Weigert's fibrin methods.

RESULTS

Clinical observations: The survival time of the infected rabbits from inoculation to death ranged from 27 to 40 hr. They became depressed at 12 to 24 hr post

inoculation (PI). The animals died within a few hr after losing the ability to stand up. Some rabbits exhibited seizures and also emitted a queer-sounding cry.

Haematological findings: There were no significant differences between the infected and control rabbits in the haematocrit values and red blood cell counts (Fig. 1a and 1b). Although there were considerable individual variations, the total leukocyte count in the terminal phase of the disease generally decreased to under the control range (Fig. 1c). The mean platelet count in the terminal phase of the disease was decreased to about half as compared to that of the control, and moderately reduced in 3 rabbits (Fig. 1d).

APTT in the terminal phase of the disease was prolonged markedly in 3 rabbits and slightly in another 3 cases (Fig. 1e). The mean APTT was markedly prolonged, although the controls showed no significant changes.

The prothrombin time in the terminal phase of the disease was markedly lengthened in 6 rabbits, of which 5 cases showed values over or around the upper limit of the control range (Fig. 1f).

Considerable individual variations in fibrinogen values were present in the infected and control animals. The fibrinogen value in each case, including the controls, was slightly increased at 12 hr PI, while that in the infected animals was decreased mildly in the terminal phase of the disease (Fig. 1g).

Antithrombin III activity was slightly increased in both the controls and infected animals at 12 hr PI and thereafter, moderately decreased in the terminal phase of the disease only in infected rabbits (Fig. 1h). The titres of fibrin degradation products at the terminal phase of the disease were markedly increased in all the infected rabbits (Table 1).

Necropsy findings: The following changes were observed in the infected (dead) rabbits: mild swelling and discoloration of the liver with distinct lobules in all cases; congestion and haemorrhage in the kidney of 4 rabbits, dilatation of the right ventricle of the heart in all animals, and petechial haemorrhages in the lung of 3 individuals.

Histopathological findings: There was diffuse solitary or focal necrosis of hepatocytes with congestion and haemorrhage. Many hepatocytes showed vacuolar degeneration. The nuclei of the necrotic hepatocytes were either pyknotic or karyolytic. There was moderate heterophilic infiltration in these necrotic foci. DIC was observed in some of the central veins.

There was severe congestion, especially around the follicles, in the spleen in all rabbits. Fibrin deposits were found in the red pulp and capillaries around follicles (Fig. 2).

In the kidneys, fibrin thrombi were observed in the glomerular capillaries and interstitial small blood vessels (Fig. 3). There were slight haemorrhages in the Bowman's spaces and proximal tubules.

DIC was also seen in the interstitial capillaries of the myocardium in all cases.

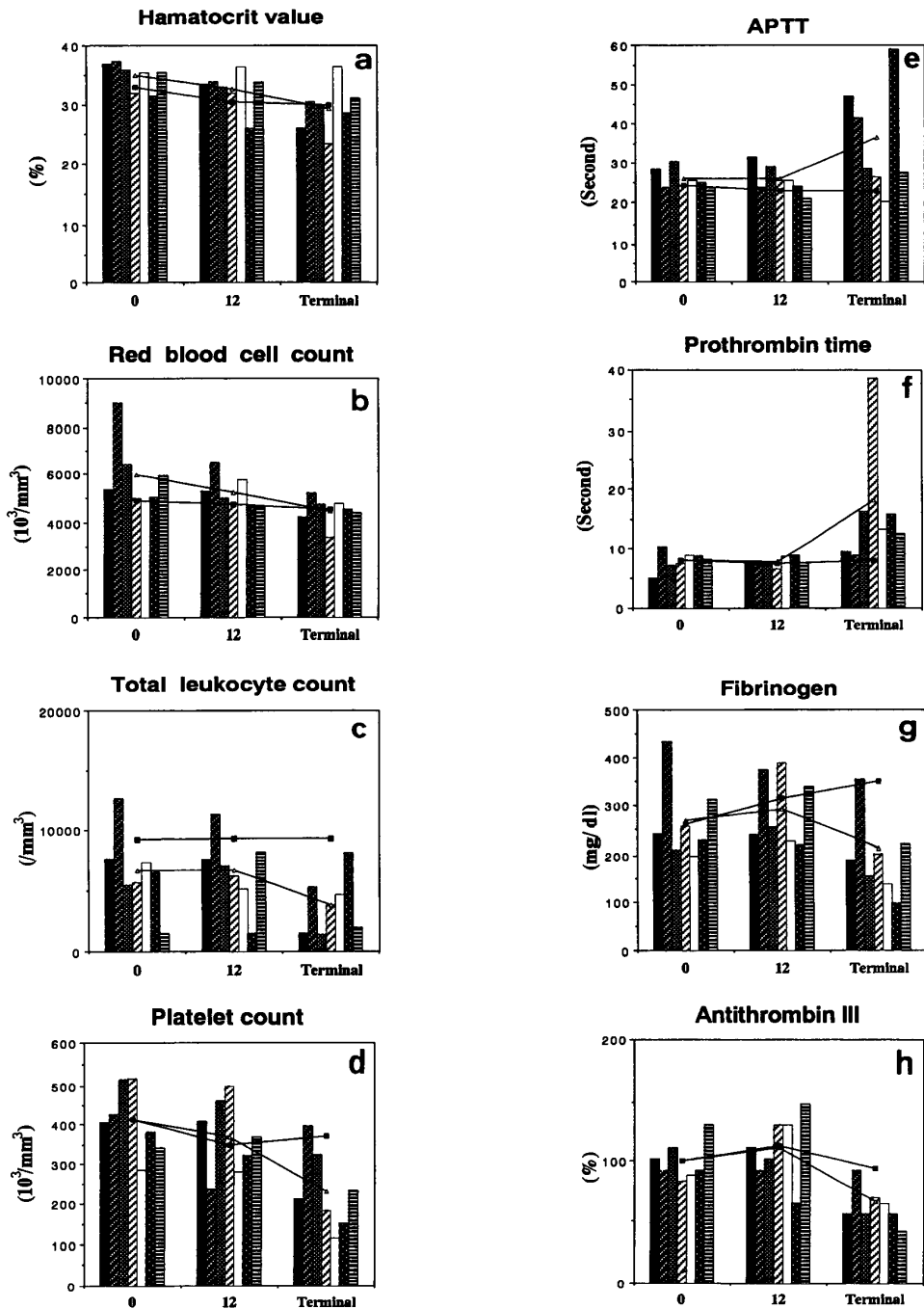


Fig. 1. Haematological changes in RHD virus-infected and control rabbits. The mean values from the infected (—△—) and control (—■—) rabbits were examined just prior to the experiment (0), at 12 hr and in the terminal phase of the disease (at 24 hr after the start of the experiment in the control). Each column in the histogram shows the value from each case No. for RHD virus-infected rabbits :

■; No. 1, ▨; No. 2, ▩; No. 3, ▪; No. 4, ▫; No. 5, □; No. 6, ▣; No. 7.

Table 1. Titres of fibrin degradation products in RHD virus-infected rabbits

Animal No.	0*	12 hr*	Terminal*
1	<1**	<1	16
2	<1	<1	64<
3	<1	<1	64<
4	<1	<1	64<
5	<1	<1	64<
6	<1	<1	64<
7	<1	<1	64<

* : 0 ; before inoculation, 12 hr ; after inoculation, and terminal ; terminal phase of the disease.

** : Titre.

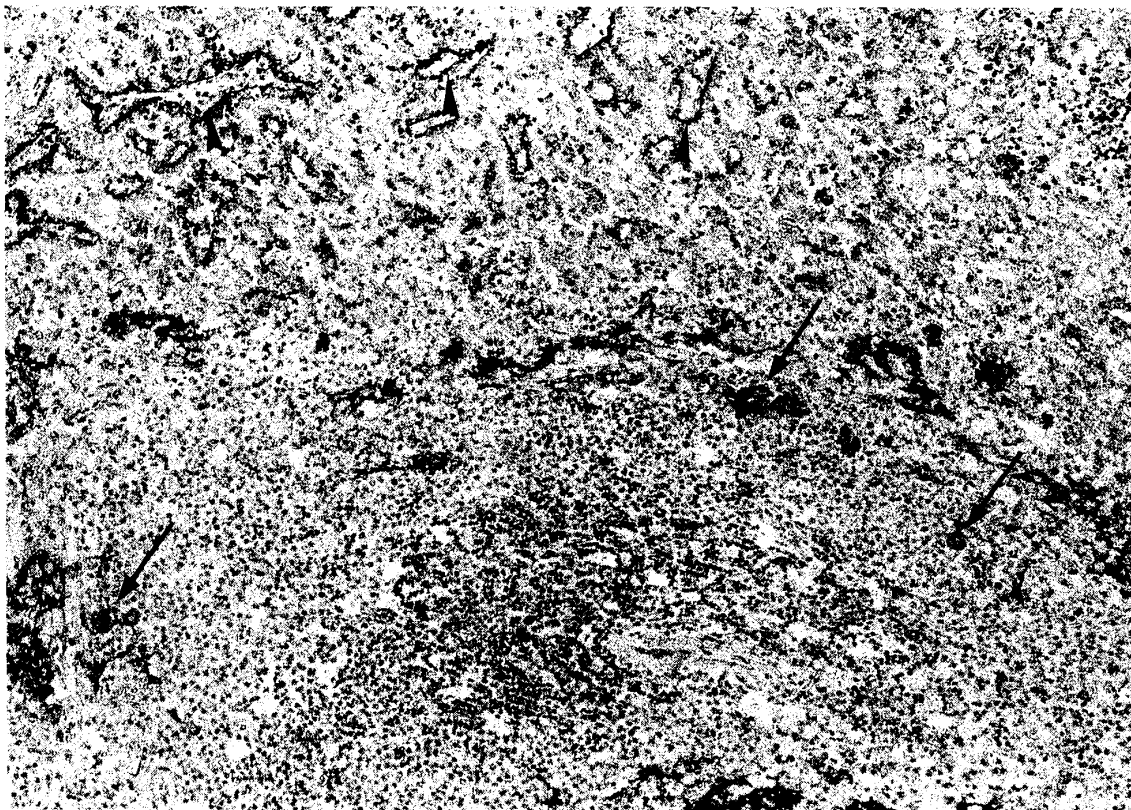


Fig. 2. Spleen in a RHD virus-infected rabbit (55 hr PI). Fibrin stained positively with PTAH method is deposited in the red pulp (arrowheads) and blood vessels around a follicle (arrows). $\times 157$

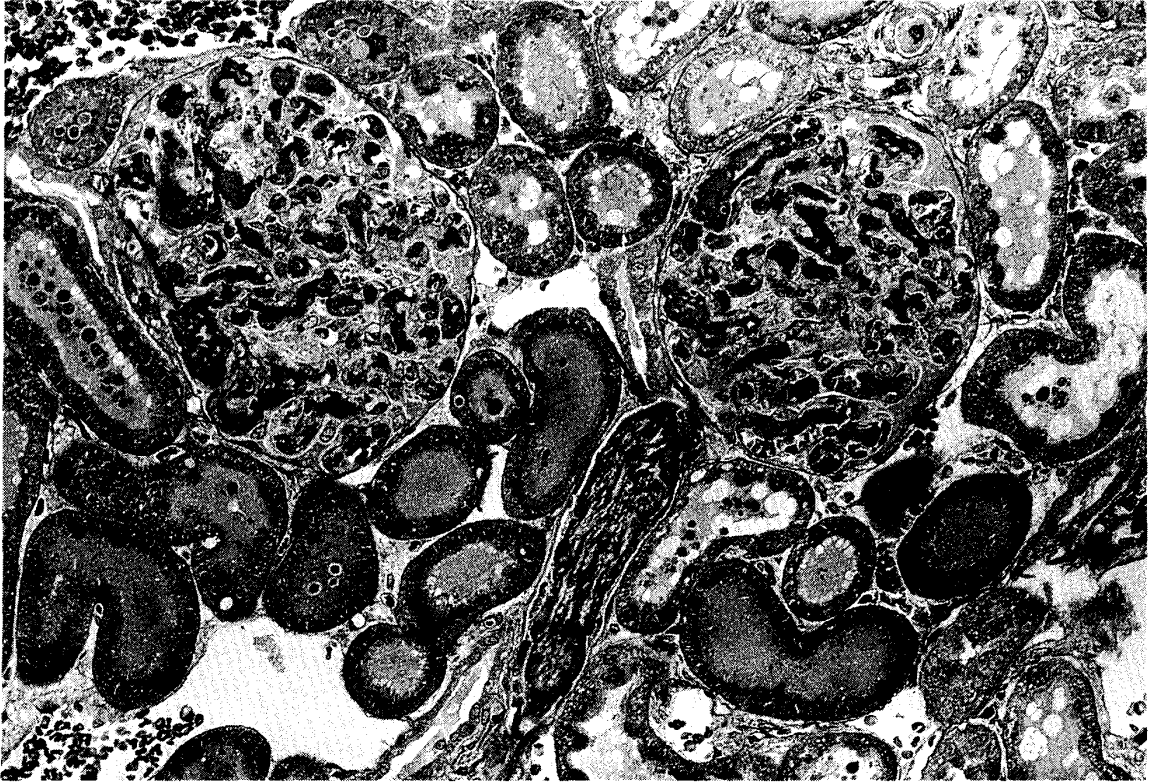


Fig. 3. Kidney in a RHD virus-infected rabbit (49 hr PI). Fibrin thrombi stained positively with Masson trichrome method are seen in glomerular capillaries and an interstitial small blood vessel (arrows). $\times 280$

Haemorrhages in the alveoli and interlobular connective tissue of the lung were seen in 3 infected rabbits. DIC in the capillaries of the alveolar septa and interlobular connective tissue was found in 4 rabbits (Fig. 4). A slight increase in the number of heterophils was observed in the blood vessels of the lungs.

Blood absorption was seen in some superficial and mesenteric lymph nodes. In the central nervous system, DIC was found in all rabbits. Haemorrhages were seen in the adrenal glands, retina and lamina propria of the urinary bladder.

The fibrin thrombi were stained blue, red and bluish violet with PTAH, Masson trichrome and Weigert's fibrin methods, respectively.

No significant histological alterations were detected in the control rabbits.




Fig. 4. Lung in a RHD virus-infected rabbit (55 hr PI). Fibrin thrombi stained positively with Masson trichrome method are scattered in capillaries of the alveolar wall (arrows). $\times 500$

DISCUSSION

Rabbits infected with RHD virus in the present study showed marked haematological changes only in the terminal phase of the disease. A decrease in the platelet count suggested a high rate of consumption of platelets for formation of fibrin thrombi.

Hypofibrinogenemia might have been caused by the following changes of fibrinogen; decreased synthesis, consumption for intravascular coagulation, loss due to marked haemorrhages, and destruction by abnormal plasma fibrinolytic activity¹¹). The fibrinogen level in the blood plasma of RHD was slightly decreased in the terminal phase of the disease, although fibrinogen was expected to be massively consumed for intravascular coagulation. A more detailed study is needed for this unexpected result.

The prothrombin time and APTT have been employed as useful tests for indicating DIC and a coagulation defect in human patients with hepato-biliary disease¹²). In this study, prolongation in both prothrombin time and APTT was noticed. Gallus et al.³) reported that blood coagulation factors II, V, VII and X synthesized in the liver

were markedly reduced in human patients with liver failure, in addition to a prolongation of prothrombin time and APTT.

The changes of the antithrombin III activity and titres of fibrin degradation products suggested that DIC was severe in the terminal phase of the disease. The decrease of the antithrombin III activity might be attributed to either its massive utilization or impaired hepatic synthesis¹⁴⁾. Increases of circulating fibrin degradation products with a fall of other coagulation factors and platelets were demonstrated in patients with fulminant hepatitis¹⁰⁾.

Histological findings in the present study showed that both DIC and hepatitis occurred in RHD. The pathogenesis of DIC in acute hepatic necrosis is multifactorial. Verstraete et al.¹³⁾ have suggested that necrotic hepatocytes might activate blood coagulation factors in circulating blood plasma. They also reported that defective clearance of the activated factors by the liver and reticulo-endothelial system, combined with depressed levels of inhibitors of coagulation of the plasma, might enhance the effects of these activated factors allowing intravascular coagulation to occur.

Because severe hepatic necrosis is common in RHD, it is likely that large amounts of tissue thromboplastin flow out from the hepatocytes, with reductions in clearance of activated coagulation proteins and synthesis of antithrombin III. Based on the haematological and histological findings of this study, it is suggested that hepatic injury causes DIC and subsequent haemorrhages in various organs and tissues.

Acknowledgements. We thank Prof. Y. Maeda, Department of Internal Medicine, Faculty of Veterinary Medicine, Hokkaido University, for helpful comments concerning this manuscript.

This work was supported in part by Grant-in-Aid for Scientific Research number 04454112 from the Ministry of Education, Science and Culture of Japan.

REFERENCES

- 1) DEYKIN, D., COCHIOS, F., DECAMP, G. & LOPEZ, A. (1986): Hepatic removal of activated factor X by the perfused rabbit liver. *Am. J. Physiol.*, **214**, 414-419
- 2) Fair, D. S. & MARLAR, R. A. (1986): Biosynthesis and secretion of factor VII, protein C, protein S, and the protein C inhibitor from a human hepatoma cell line. *Blood*, **67**, 64-70
- 3) GALLUS, A. S., LUCAS, C. R. & HIRSH, J. (1972): Coagulation studies in patients with acute infectious hepatitis. *Br. J. Haematol.*, **22**, 761-771
- 4) HILLENBRAND, P., PARBHOO, S. P., JEDRYCHOWSKI, A. & SHERLOCK, S. (1974): Significance of intravascular coagulation and fibrinolysis in acute hepatic failure. *Gut*, **15**, 83-88
- 5) LANE, D. A., SCULLY, M. F., THOMAS, D. P., KAKKAR, V. V., WOOLF, I. L. & WILLIAMS, R. (1977): Acquired dysfibrinogenemia in acute and chronic disease. *Br. J. Haematol.*, **35**, 301-308

- 6) MARCATO, P.S., BENAZZI, C., GALEOTTI, M. & SALDA, L. D. (1989): Infectious necrotic hepatitis of leporids. Further investigations on the pathogenesis on viral hemorrhagic disease of the rabbit and hare. *Riv. Coniglicol.*, **8**, 41–50
- 7) OHLINGER, V. F., HAAS, B., MEYERS, G., WEILAND, F. & THIEL, H-J. (1990): Identification and characterization of the virus causing rabbit hemorrhagic disease. *J. Virol.*, **64**, 3331–3336
- 8) PARK, J. H. & ITAKURA, C. (1992): Detection of rabbit haemorrhagic disease virus antigen in tissues by immunohistochemistry. *Res. Vet. Sci.*, **52**, 299–306
- 9) PARK, J. H., KIDA, H., UEDA, K., OCHIAI, K., GORYO, M. & ITAKURA, C. (1991): Etiology of rabbit haemorrhagic disease spontaneously occurring in Korea. *J. Vet. Med. B.*, **38**, 749–754
- 10) RAKE, M. O., FLUTE, P. T., PANNELL, G. & WILLIAMS, R. (1970): Intravascular coagulation in acute hepatic necrosis. *Lancet*, **14**, 533–537
- 11) RATNOFF, O. D. (1987): Disordered hemostasis in hepatic disease. pp. 187–207. In: Diseases of the Liver, 6th ed. Eds. Schiff, L. & Schiff, E. R. Philadelphia, J. B. Lippincott Company
- 12) SHERLOCK, S. (1989): The haematology of liver disease. pp. 49–69. In: Diseases of the Liver and Biliary System, 8th ed. Ed. Sherlock, S. Oxford, Blackwell Scientific Publications
- 13) VERSTRAETE, M., VERMYLEN, J. & COLLEN, D. (1974): Intravascular coagulation in liver disease. *Ann. Rev. Med.*, **25**, 477–455
- 14) von KAULLA, E. & von KAULLA, K. N. (1967): Antithrombin III and diseases. *Am. J. Clin. Pathol.*, **48**, 69–80