



HOKKAIDO UNIVERSITY

| | |
|------------------|---|
| Title | HISTOPATHOLOGICAL SURVEY OF PROTOZOA, HELMINTHS AND ACARIDS OF IMPORTED AND LOCAL PSITTACINE AND PASSERINE BIRDS IN JAPAN |
| Author(s) | TSAI, Shinn-Shyong; HIRAI, Katsuya; ITAKURA, Chitoshi |
| Citation | Japanese Journal of Veterinary Research, 40(4), 161-174 |
| Issue Date | 1992-12-28 |
| DOI | https://doi.org/10.14943/jjvr.40.4.161 |
| Doc URL | https://hdl.handle.net/2115/2407 |
| Type | departmental bulletin paper |
| File Information | KJ00002377611.pdf |



HISTOPATHOLOGICAL SURVEY OF PROTOZOA, HELMINTHS AND ACARIDS OF IMPORTED AND LOCAL PSITTACINE AND PASSERINE BIRDS IN JAPAN

Shinn-Shyong TSAI¹, Katsuya HIRAI² and Chitoshi ITAKURA¹

(Accepted for publication: Nov. 5, 1992)

ABSTRACT

A total of 534 psittacine and passerine birds consisting of 241 imported and 293 local birds were examined histologically. As a result, the following parasites were found: *Giardia* (86 cases), *Knemido-coptes* (26 cases), coccidia (10 cases), *Ascaridia* (6 cases), *Cryptosporidium* (5 cases), *Sarcocystis* (5 cases), tapeworm (4 cases), microfilaria (2 cases), *Hexamita* (1 case), and *Spiroptera* (1 case). High incidences of giardiasis and knemido-coptic infestation were detected in the local birds, but rarely in the imported birds. Giardial trophozoites were observed mainly in the duodenum of budgerigars (*Melopsittacus undulatus*). Knemidocoptic mites burrowed into the epidermis producing proliferative dermatitis in 25 budgerigars and 1 African Grey Parrot (*Psittacus erithacus erithacus*). This ectoparasite often infested the skin around the cloaca. Coccidiosis was seen only in the small intestines of the finch (*Poephila gouldiae gouldiae*), African Grey Parrot, Rainbow lory (*Trichoglossus haematodus*), Indian Ring-necked parakeet (*Psittacula krameri manillensis*) and peach-faced lovebird (*Agapornis roseicollis*). Two parrots (*Amazona aestiva aestiva* and *Psittacus erithacus erithacus*) and two budgerigars had intestinal cryptosporidiosis. Conjunctivitis associated with cryptosporidial infection was seen in a lovebird. *Sarcocystis* cysts containing crescent-shaped bradyzoites were found not only in the thigh and breast but also in the heart and cloacal muscles. Other organisms such as *Ascaridia*, tapeworm, microfilaria, *Hexamita*, and *Spiroptera* were clinically less significant. However, infections such as *Giardia* and *Cryptosporidium* might have zoonotic implications.

Key words: pet bird, protozoan, helminth, acarid, histopathology.

1. Department of Comparative Pathology, Faculty of Veterinary Medicine, Hokkaido University, Sapporo 060, Japan

2. Department of Veterinary Microbiology, Faculty of Agriculture, Gifu University, Gifu 501-11, Japan

INTRODUCTION

Parasitism is often overlooked in the companion birds because it does not seem to cause obvious clinical disorders. In addition, most of the pet birds kept in indoor cages or aviaries have little chance of contact with parasites. Contamination of food and water with infective materials either from humans, newcomers or wild birds may be a source of infection for captive birds^{9, 17, 20, 21}. Therefore, helminthic and protozoal diseases may be more frequent than previously recognized. Various parasites can cause high mortality and also have a significant adverse effect on the outcome of other diseases²⁶.

Helminthic and protozoal diseases of pet birds such as toxoplasmosis¹³, schistosomiasis⁸, giardiasis²⁸, and cryptosporidiosis² have been implicated in parasitic zoonoses. As far as we know, only a few studies have been carried out on protozoal and helminthic diseases in caged birds in Japan^{32, 39}. This paper is a retrospective histopathological study on parasitic infections in both imported and local pet birds.

MATERIALS AND METHODS

A total of 534 pet birds comprising 241 imported birds and 293 local budgerigars were examined. The imported birds consisted of 67 parakeets (*Psittacula krameri manillensis*) from India, 52 cockatiels (*Nymphicus hollandicus*) from Taiwan, 29 parrots (19 were *Amazona aestiva aestiva* from Argentina and 10 were *Psittacus erithacus erithacus* from Ghana), 18 lorries (*Trichoglossus haematodus*) from Indonesia, 8 lovebirds (*Agapornis roseicollis*) from Taiwan, 2 rosellas (*Platycercus emimius*) from Holland, 47 budgerigars (*Melopsittacus undulatus*) from the philippines and 18 finches (*Poephila gouldiae gouldiae*) from Taiwan. These imported birds died during the two-week quarantine period in a bird shop, and the local birds were obtained from bird dealers.

Tissue samples for histopathological examination consisted of the brain, heart, respiratory tract, digestive tract, kidney, spleen, thymus, bursa of Fabricius, parathyroid gland, thyroid gland, adrenal gland, bone marrow, genital organs, eye, conjunctivum, skeletal muscles and skin. The samples were fixed in 10% buffered formalin, embedded in paraffin, sectioned, and stained with either hematoxylin and eosin (HE), Gram, or periodic acid-Schiff (PAS) methods. The parasites were identified on the basis of their morphological features in the tissue sections.

RESULTS

Among the protozoal infections, giardiasis, found in the small intestine, especially in the duodenum (Table 1), was the most common disorder. Of the 86 budgerigars infected with *Giardia*, 85 were local and only one was imported. Histologically, large numbers of trophozoites admixed with mucus in the lumen were observed to adhere to

Table 1. Protozoal infection in imported and local birds

| Protozoan | No. of cases | | Bird host (No. infected) | Site of infection |
|-----------------|-----------------|-----------------|---|--------------------------|
| | IP ^a | LC ^b | | |
| Giardia | 1 | 85 | Budgerigar (86) | Small intestine |
| Coccidia | 10 | 0 | Finch (4), African Grey (2), parakeet (2), lory (1), lovebird (1) | Small intestine |
| Sarcocystis | 4 | 1 | African Grey (2), Amazon parrot (2), budgerigar (1) | Striated muscle |
| Cryptosporidium | 3 | 2 | Amazon parrot (1), African Grey (1), budgerigar (2) | Small intestine |
| | | | Lovebird (1) | Conjunctivum |
| Hexamita | 1 | 0 | Finch (1) | Small intestine Cecum |

^a Imported birds.^b Local birds.

the brush borders of the intestinal epithelium. They appeared as pear-shaped or small sickle-shaped bodies which were dorsally convex and had no undulating membrane (Fig. 1). It was difficult to demonstrate their nuclei and flagella. The epithelium was intact in the intestinal villi, but the lamina propria was often filled with chronic inflammatory cells, consisting mainly of lymphocytes and plasma cells. Some of the plasma cells had Russell bodies in their cytoplasm.

Coccidia were found in the small intestines in 4 finches, 2 parrots, 1 lory and 1 lovebird. Macrogametocytes, microgametocytes and immature oocysts were observed only in the villar epithelium and lamina propria of the small intestine (Fig. 2). No other visceral lesion was induced by these coccidia.

Sarcocystis cysts were observed in 4 parrots (2 *Amazona aestiva aestiva* and 2 *Psittacus erithacus*) and 1 budgerigar. All the birds had mature cysts in their breast and thigh muscles. In an Amazona parrot, the cysts were also observed in the heart and cloacal muscles. These cysts which contained crescent-shaped bradyzoites were elongated, and had a thick-wall with many villous protrusions on its internal surface (Fig. 3). The bradyzoites were stained positively with PAS, but not the cyst wall.

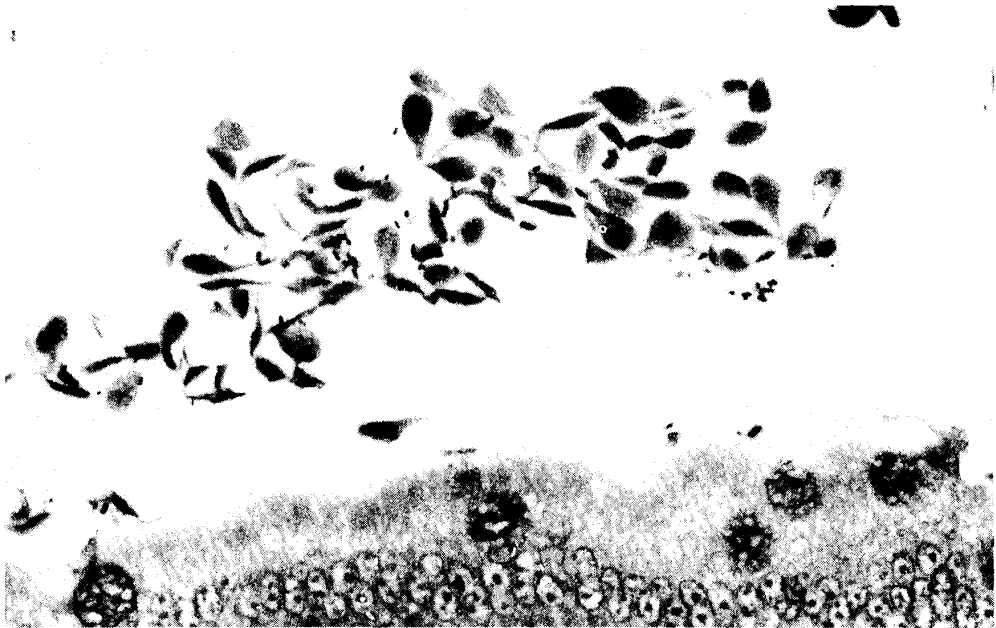


Fig. 1. Giardiasis in duodenum of a parakeet. Numerous trophozoites of *Giardia* species with sharp borders ends, frequently found between the intestinal villi. Gram stain. $\times 600$.

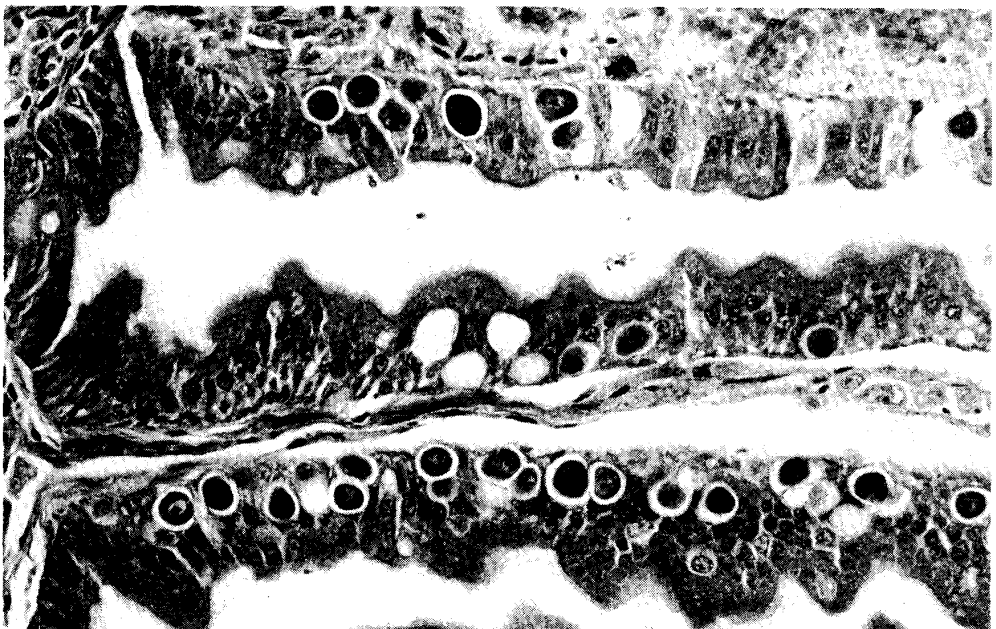


Fig. 2. Coccidiosis in small intestine of a finch. Many immature oocysts are seen in the intestinal epithelium. HE stain. $\times 440$.

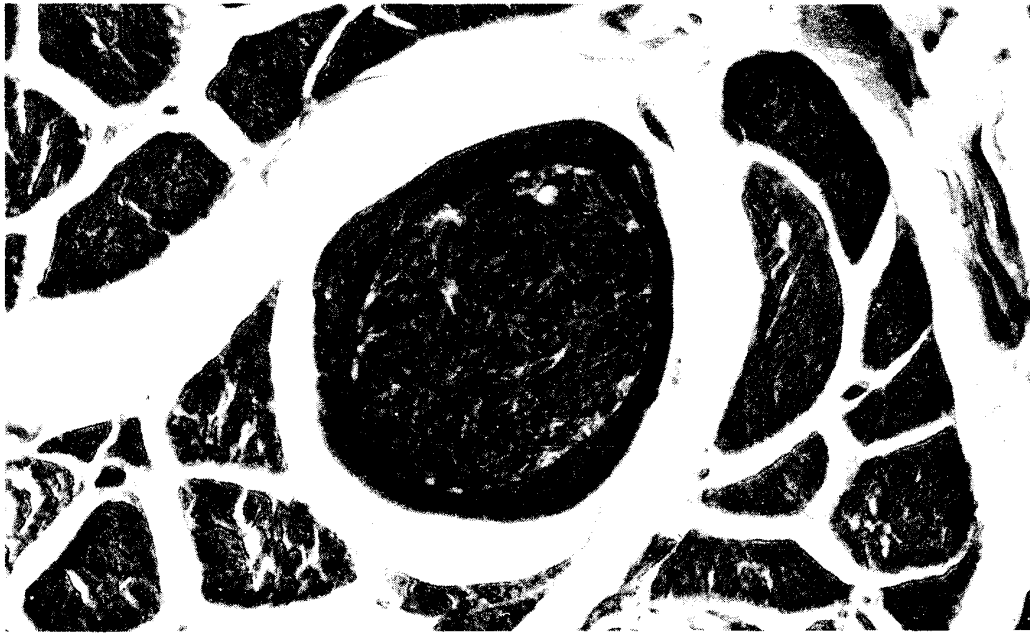


Fig. 3. Sarcocystosis in thigh muscle of a parrot. An intramuscular mature sarcocyst containing numerous crescent-shaped bradyzoites is encompassed by a cystic wall with many microvilli. HE stain. $\times 400$.

There was no inflammatory reaction around the cysts.

Intestinal infection with *Cryptosporidium* was seen in two parrots (*Amazona aestiva aestiva* and *Psittacus erithacus erithacus*), and 2 budgerigars. Cryptosporidia were detected in the bulbar and palpebral conjunctiva of a lovebird (*Agapornis roseicollis*). The striking feature was the presence of tiny oval protozoa on the surface of the hyperplastic mucosal epithelium (Fig. 4). Mild to moderate infiltration of heterophils, macrophages, lymphocytes and plasma cells occurred in the lamina propria. The protozoa were stained positively with PAS.

Infection, presumably *Hexamita* sp. was diagnosed in the lower jejunum and ceca of a finch (*Poephila gouldiae gouldiae*). It was pyriform in shape, smaller than *Giardia* sp., and had no undulating membrane (Fig. 5). The affected intestine showed hyperplasia of goblet cells and increased secretion of mucus in the lumen, associated with marked infiltration of plasma cells and lymphocytes in the lamina propria.

Infestation with knemidocoptic mites was encountered most frequently in budgerigars (Table 2). The local birds had a higher morbidity than the imported birds (22 : 4 cases). The skin around the cloaca was the most common site of predilection for this ectoparasite (19 cases), and in a few cases both the ceres and eyelids were also affected. The prominent lesions were hyperkeratosis and acanthosis of the epidermis in association with lymphocytic infiltration of the dermis (Fig. 6). These mites were

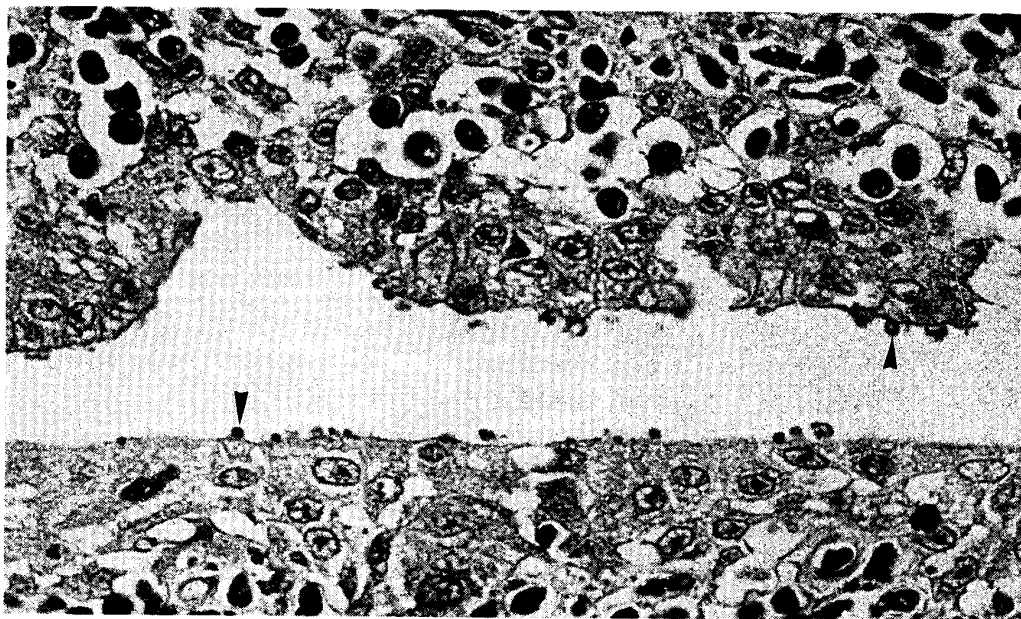


Fig. 4. Cryptosporidiosis in conjunctiva of a lovebird. Tiny oval cryptosporidial organisms (arrowheads) are attached to the hyperplastic epithelium in bulbar and palpebral conjunctiva. Note the infiltration of macrophages, heterophils, lymphocytes and plasma cells in the lamina propria. HE stain. $\times 900$.

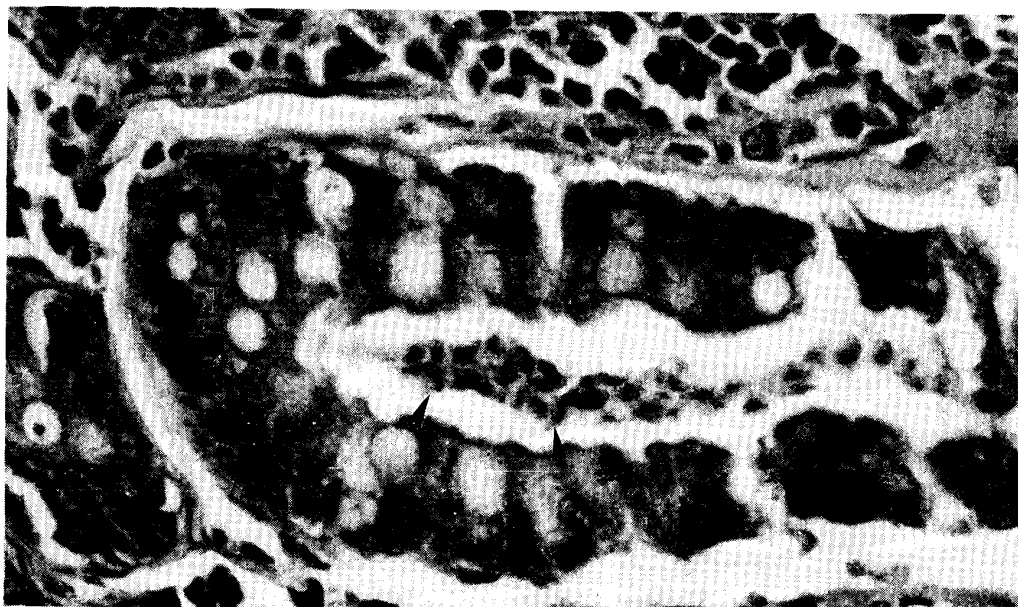


Fig. 5. Large numbers of pyriform-shaped *Hexamita* sp. trophozoites (arrowheads) are seen in the jejunum of a finch, associated with catarrhal inflammation. HE stain. $\times 400$.

Table 2. Helminthic and acarid infection in imported and local birds

| Parasite | No. of cases | | Bird host (No. infected) | Site of predilection |
|---------------|-----------------|-----------------|---|----------------------|
| | IP ^a | LC ^b | | |
| Ascaridia | 6 | 0 | Parakeet (3), cockatiel (1), Amazona parrot (1), African Grey (1) | Small intestine |
| Raillietina | 4 | 0 | Lory (2), lovebird (1), parakeet (1) | Small intestine |
| Microfilaria | 2 | 0 | Lovebird (1), lory (1) | Blood vessel |
| Spiroptera | 1 | 0 | Finch (1) | Gizzard |
| Knemidocoptes | 4 | 22 | Budgerigar (25), African Grey (1) | Skin |

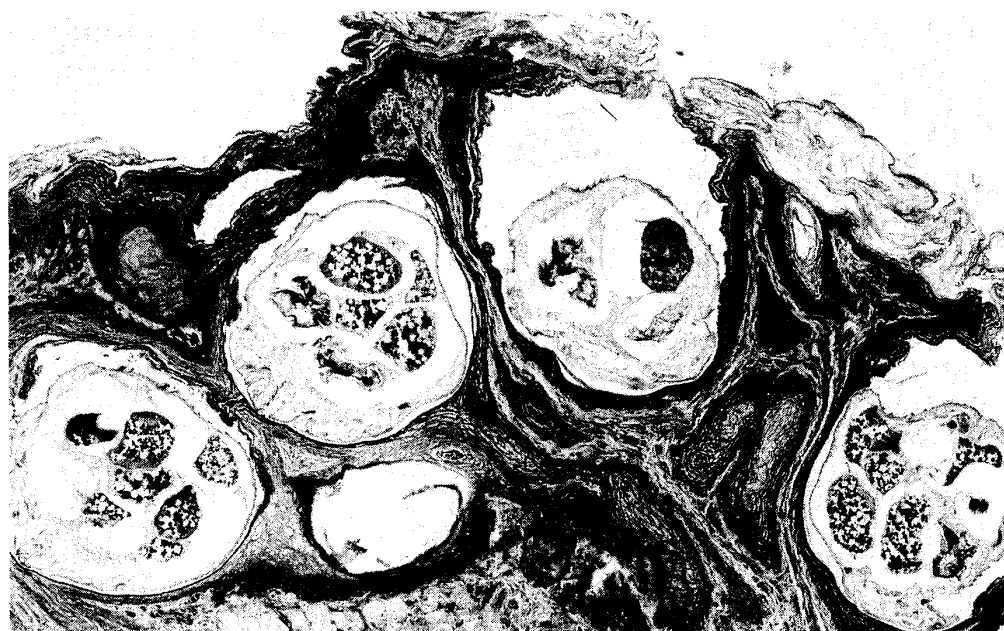
^a Imported birds.^b Local birds.

Fig. 6. Acaritic dermatitis in cloaca of a parakeet. Knemidocoptic mites burrowed into the skin around the cloaca, eliciting an intense hyperkeratosis and epithelial hyperplasia. HE stain. $\times 85$.

often embedded in the thickened keratin layer. Some burrowed into the epidermis, but not beyond the basal layer.

Ascaridia infection was not uncommon in pet birds. The roundworm was often observed in the duodenum and other parts of the small intestine. Its body walls had an external cuticle with an underlying muscular layer encircling the body cavity. In the cross-section of the alimentary canal and the uterus containing a large number of eggs could be easily identified (Fig. 7). Inflammatory or other tissue reaction to the worms was not discernible, although their presence may have caused obstruction of the intestinal tract.

Cestodiasis caused by *Railletina* sp. was found in the small intestine in 2 lorries (*Trichoglossus haematodus*), 1 lovebird (*Agapornis roseicollis*) and 1 parakeet (*Psittacula krameri manillensis*). Histologically, the cestode showed a segmented body, having one set of reproductive organs in each segment. Calcareous corpuscles were observed between the inner longitudinal muscles and the outer circular muscles. The gravid proglottids were filled with egg capsules, each containing several eggs (Fig. 8).

Microfilaria was found in a lovebird (*Agapornis roseicollis*) and a lory (*Trichoglossus haematodus*). Despite the numerous microfilariae in the blood vessels, no cellular reaction to their presence was observed (Fig. 9). The microfilariae had no sheath and were seen in a variety of organs such as the lung, liver, heart, kidney and bone marrow. No attempts were made to recover the adult worm in the present study.

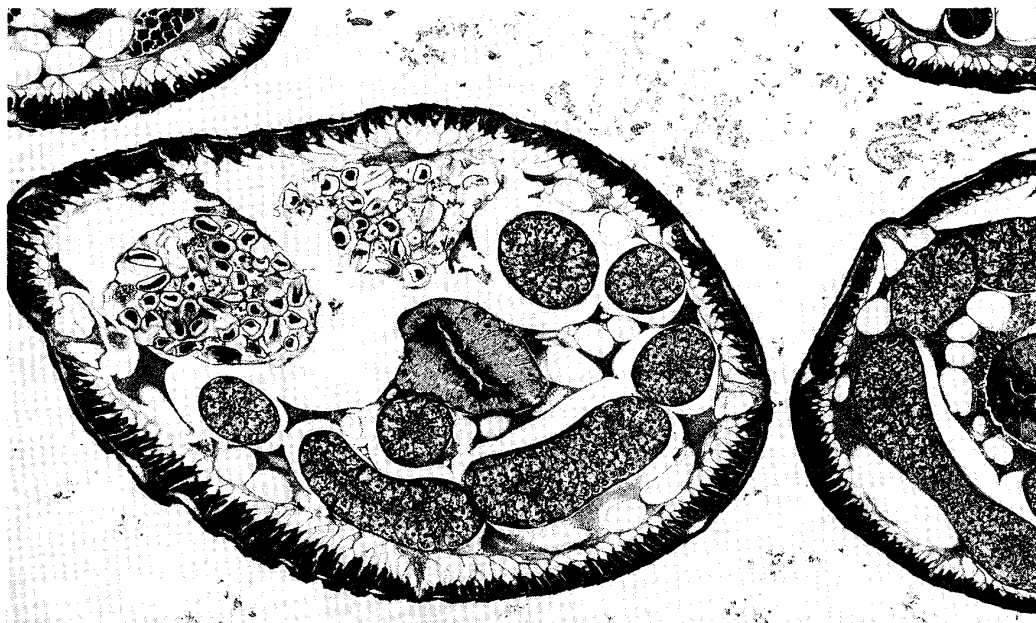


Fig. 7. Four cross sections of *Ascaridia* in small intestine of a cockatiel. The body cavity contains an esophagus, and many mature and immature ova in the uterus. HE stain. $\times 45$.

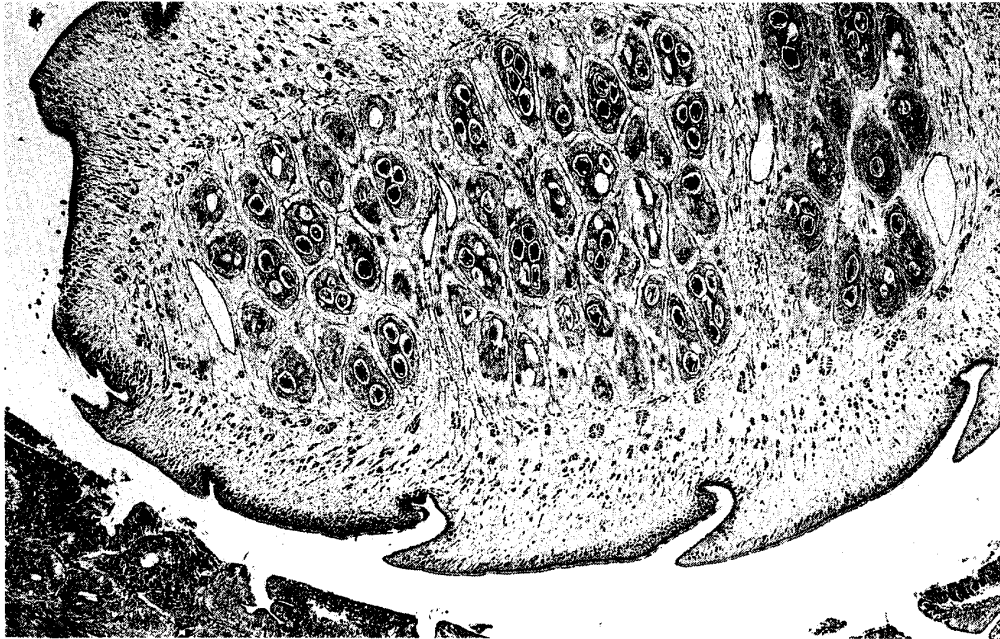


Fig. 8. *Raillietina* sp. in small intestine of a lory. The longitudinal section of the strobila reveals three segments, which contain many egg capsules filled with immature ova. HE stain. $\times 35$.




Fig. 9. Microfilariae in heart of a lovebird. Numerous microfilariae are seen in the lumen of the left atrium. HE stain. $\times 400$.

Infection presumably with *Spiroptera incerta* was diagnosed in the gizzard of one finch (*Poephila gouldiae gouldiae*). Numerous roundworms containing immature ova were seen in the region between the koilin layer and the mucosal glands (Fig. 10). The overlying koilin layer showed severe hyperkeratosis and degenerative change associated with superficial erosion. The underlying glandular epithelium revealed hypertrophic change. Cellular reaction to the worm was not observed.

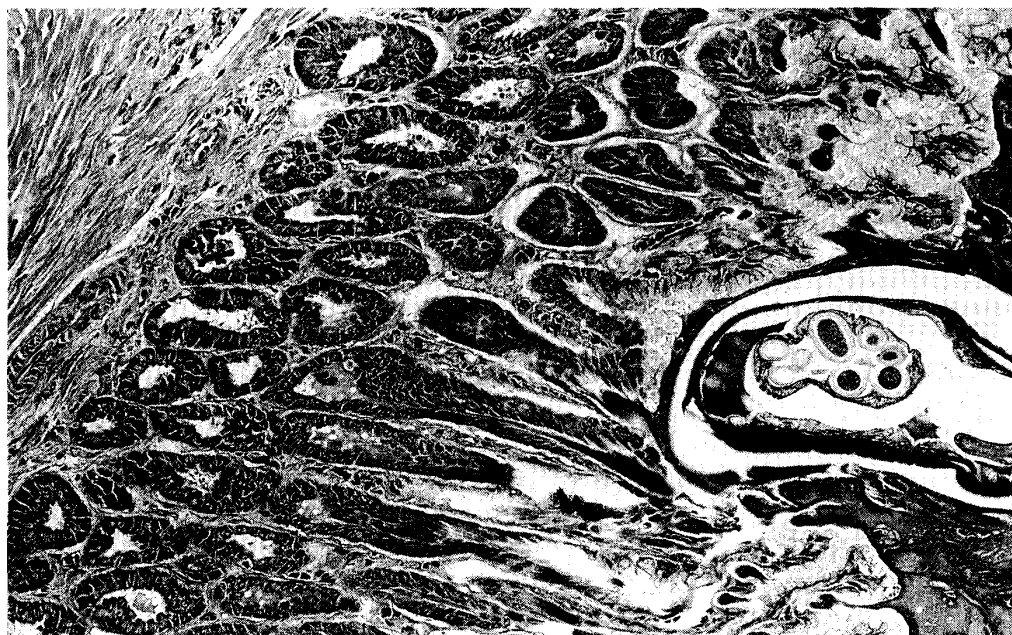


Fig. 10. A cross-section of a nematode, presumably of *Spiroptera incerta* in gizzard of a finch. Note the worm under the koilin layer, and the absence of cellular reaction. HE stain. $\times 150$.

DISCUSSION

The present study indicated that *Giardia* (86 cases) and *Knemidocoptes* (26 cases) were the most common parasites of pet birds in Japan. Other parasites recorded in the order of incidence were, coccidia (10 cases), *Ascaridia* (6 cases), *Cryptosporidium* and *Sarcocystis* (5 cases each), tapeworm (4 cases), microfilaria (2 cases), *Spiroptera* and *Hexamita* (1 case each).

Giardia is a binucleate, flagellate protozoan which causes intestinal disorders in mammals, birds, reptiles, and amphibians¹. A variety of birds, including herons, swamp sparrows, egrets, budgerigars and ducks, have been reported to harbor the *Giardia* species^{3, 17, 19, 39}. Among avian species, budgerigars are very susceptible to this protozoan and often have a high morbidity and mortality rate^{27, 29}. Recent

studies have shown that surface and filtered drinking water supplies could be contaminated with high levels of *Giardia* cysts and *Cryptosporidium* spp. oocysts^{20, 21}). This has been attributed to the high resistance of *Giardia* cysts to the routine chlorination recommended for drinking water⁹).

We found that *Giardia* species were more prevalent in the local budgerigars (85/293) than in the imported birds (1/241). Waterborne and contact infections might be the possible routes of transmission for this protozoan. Since all the infected budgerigars had large numbers of trophozoites in the upper small intestine, equally large numbers of cysts could be expected to be excreted in their feces. These cysts may contaminate the environment and present a possible source of infection to other birds.

Coccidiosis occurred primarily in companion birds that were given feed on the ground. *Eimeria* spp. have been reported to parasitize the small intestine, being confined mainly to the duodenum, and are host specific^{26, 33}). Although all cases of coccidiosis in this study showed sexual stages of their life cycle in the duodenum, it was difficult to identify their genera in tissue sections.

Sarcocystis falcatula has been reported to have a wide range of intermediate hosts, including psittaciforme, passeriforme, and columbiforme birds^{6, 7, 36}). It may cause debilitation and sometimes mortality in susceptible birds, due to obstruction of the pulmonary blood vessels³⁶). In chronic infection, cysts are formed in the skeletal muscles and, to a lesser extent, in myocardial fibers⁶). The parasites are characterized microscopically by the presence of merozoites encompassed by the cyst wall with microvilli, and the compartmentalization of the cyst^{5, 14}). We observed 4 cases with *Sarcocystis* cysts in the muscles of the breast and thigh, including an Amazona parrot with cysts in the heart, breast and cloacal muscles.

Cryptosporidiosis has been recorded in various mammals, birds and fishes^{24, 35}). Among the caged birds, this protozoan has been observed mainly in the digestive tract, kidney and respiratory tract of parrots¹²), canaries³⁸), finches¹⁶), lovebirds⁴) and budgerigars²⁵). Conjunctival cryptosporidiosis is occasionally found in chickens¹⁸), peacocks²³), pheasants³⁰) and ducks²²). This protozoan induces conjunctivitis and excess mucus in the nasal cleft. We found intestinal cryptosporidiosis in two parrots and two budgerigars, and conjunctival cryptosporidiosis in a lovebird. The organism has been proven to be monoxenous and interhost species transmission has been reported¹⁰). This may have public health implications²).

Knemidocoptes pilae commonly infests the skin of budgerigars, and feeds on keratin⁴⁰). This mite produces pruritic dermatitis with scaly epithelial proliferation which is characterized by the formation of chalk-like, honeycombed encrustations in the affected areas^{26, 37}). We found a higher incidence in local birds than in imported ones, and the skin around the cloaca was the most common site of predilection. This contradicts previous reports, which stated that the lesions were predominantly seen on

the beak, cere, eyelids and legs, thus leading to the name "scaly-leg and face mite" for this ectoparasite^{15, 31}). This discrepancy may be due to the culling of the birds with gross lesions on easily noticeable sites other than the cloaca by owners. Moreover, acaritic dermatitis around the cloaca can easily be overlooked. The higher morbidity in the local birds may be attributable to overcrowding or huddling together on a perch due to low room temperature.

Ascaridia and tapeworms were detected only in the imported birds in the present study. Unless in debilitated birds or those with heavy parasite burdens, they do not seem to present any problems in practice²⁶). Microfilariasis has been found in a wide variety of birds, including the orders Passeriformes, Psittaciformes and Falconiformes²⁶). In Japan, of 17 captured jungle-crows 7 were observed to harbor microfilariae³²). Our study showed that the imported lovebird and lory were also infected with microfilariae. These parasites were seen in the blood vessels of blood-rich organs such as the lung, liver, heart, kidney and bone marrow. Microscopically, they seemed to be nonpathogenic, because no lesion or cellular reaction was observed. However, parasitic emboli in the tiny blood vessels may lead to circulatory disturbances¹¹).

The gizzard lesions presumably caused by *Spiroptera incerta* in the finch in the present study were similar to those reported for the Bluefaced finch attributed to *Cheilospirura* infection³⁴). Cellular reaction to the infection with *Cheilospirura* sp. was rarely noticed, except for the marked degeneration of the koilin layer and the accumulation of necrotic debris in the mucosal glands.

We have previously encountered two parasites affecting the proventriculus and gizzard, including *Tetrameres fissispina* in ducks, and *Dispharynx nasuta* in guinea fowls (unpublished data.). Both the parasites induced chronic proliferative inflammatory reactions. However, the definite diagnosis of *Spiroptera incerta* in this study should be based on morphological examination of the intact worms.

REFERENCES

- 1) ADAM, R. D. (1991): The biology of *Giardia* spp. Microbiol. Rev., **55**, 706-732
- 2) ANDERSON, B. C., DONNDELING, T., WILKINGS, R. M. & SMITHE, J. (1982): Cryptosporidiosis in a veterinary student. J. Am. Vet. Med. Assoc., **180**, 408-409
- 3) ANSARI, M. A. R. (1951): Contribution a l'etude du gene *Giardia* Kunstler, 1882 (Mastigophora, Octomitidae). Ann. Parasitol. Hum. Comp., **26**, 421-490
- 4) BELTON, D. J. & POWELL, I. B. (1987): Cryptosporidiosis in lovebirds (*Agapornis* sp.). New Zealand Vet. J., **35**, 15
- 5) BOLON, B., GREINER, E. C. & CALDERWOOD MAYS, M. B. (1989): Microscopic features of *Sarcocystis falcatula* in skeletal muscle from a Patagonian conure. Vet. Pathol., **26**, 282-284
- 6) BOX, E. D., MEIER, J. L. & SMITH, J; H. (1984): Description of *Sarcocystis falcatula* Stiles, 1983, a parasite of birds and opossums. J. Protozool., **31**, 521-524

- 7) CLUBB, S. L., FRENKEL, J. K., GARDINER, C. H. & GRAHAM, D. L. (1986): An acute fatal illness in old world psittacine birds associated with *Sarcocystis falcatula* of opossums. Proc. Am. Avian Vet., pp. 139-149. (Madison, Omnipress)
- 8) CORT, W. W. (1950): Studies on schistosome dermatitis. XI. Status of knowledge after more than twenty years. Am J. Hyg., **52**, 251-307
- 9) CRAUN, G. F. (1986): Waterborne giardiasis in the United States 1965-1984, Lancet ii, 513-514
- 10) CURRENT, W; L. (1986): *Cryptosporidium*: its biology and potential for environmental transmission. CRC Critical Reviews in Environmental control, **17**, 21-31
- 11) DHARMA, D. N., DARMADI, P., PURNOMO & ARSANA, I. B. (1985): Filariasis and microfilariasis in parrots in the Eastern Islands of Indonesia. Avian Dis., **29**, 881-885
- 12) DOSTER, A. R., MAHAFFEY, E. A. & MCCLEAREN, J. R. (1979): Cryptosporidia in the cloacal coprodeum of red-lored parrots (*Amazona autumnalis*). Avian Dis., **23**, 654-661
- 13) DUBEY, J. P. & BEATTIE, C. P. (1988): Toxoplasmosis of animals and man. CRC Press, Boca Raton, Fla. pp. 1-220
- 14) DUBEY, J. P., SPEER, C. A. & FAYER, R. (1989): Sarcocystosis of animals and man. CRC Press, Boca Raton, Fla. pp. 1-215
- 15) FROST, C. (1961): Experiences with pet budgerigars. Vet. Rec., **73**, 621-626
- 16) GARDINER, C. H. & IMES, G. D. Jr. (1984): *Cryptosporidium* sp. in the kidneys of a black-throated finch. J. Am. Vet. Med. Assoc., **185**, 1401-1402
- 17) GEORGI, M. E., CARLISLE, M. S. & SMILEY, L. E. (1986): Giardiasis in a great blue heron (*Ardea herodias*) in New York State: Another potential source of waterborne giardiasis. Am. J. Epidemiol., **123**, 916-917
- 18) GOODWIN, M. A. (1989): Cryptosporidiosis in birds-A review. Avian Pathol., **18**, 365-384
- 19) KULDA, J. & NOHYNKOVA, E. (1978): Flagellates of the human intestine and of intestines of other species. In: J. Krier (Ed) Parasitic Protozoa, pp. 1-138, New York, Academic Press
- 20) LECHÉVALLIER, M. W., NORTON, W. D. & LEE, R. G. (1991a): Occurrence of *Giardia* and *Cryptosporidium* spp. in surface water supplies. Appl. Environ. Microbiol., **57**, 2610-2616
- 21) LECHÉVALLIER, M. W., NORTON, W. D. & LEE, R. G. (1991b): *Giardia* and *Cryptosporidium* spp. in filtered drinking water supplies. Appl. Environ. Microbiol., **57**, 2617-2621
- 22) MASON, R. W. (1986): Conjunctival cryptosporidiosis in a duck. Avian Dis., **30**, 598-600
- 23) MASON, R. W. & HARTLEY, J. W. (1980): Respiratory cryptosporidiosis in a peacock chick Avian Dis., **24**, 771-776
- 24) O'DONGHUE, P. J. (1985): *Cryptosporidium* infection in man, animal, birds and fish. Aust. Vet. J., **62**, 453-458
- 25) O'DONGHUE, P. J., THAM, V. L., de SARAM, W. G., PAULL, K. L. & MCDERMOTT, S.

- (1987): *Cryptosporidium* infections in birds and mammals and attempted cross-transmission studies. *Vet. Parasitol.*, **26**, 1-11
- 26) OLSEN, D. E. & DOLPHIN, R. E. (1978): Parasitism in the companion bird. *Vet. Med./Small Anim. Clinic.*, **73**, 640-644
- 27) PANIGRAPHY, B., ELISSALDE, G., GRUMBLES, L. C. & HALL, C. F. (1978): Giardiasis infection in parakeets. *Avian Dis.*, **22**, 815-818
- 28) PANIGRAPHY, B., GRIMES, J. E., RIDEOUT, M. I., SIMPSON, R. B. & GRUMBLES, L. C. (1979): Zoonotic diseases in psittacine birds: Apparent increased occurrence of chlamydiosis (psittacosis), salmonellosis, and giardiasis. *J. Am. Vet. Med. Assoc.*, **175**, 359-361
- 29) PANIGRAPHY, B., MATHEWSON, J. J., HALL, C. F. & GRUMBLES, L. C. (1981): Unusual disease conditions in pet and aviary birds. *J. Am. Vet. Med. Assoc.*, **178**, 394-395
- 30) RANDALL, C. J. (1986): Conjunctivitis in pheasants associated with cryptosporidial infection. *Vet. Rec.*, **118**, 211-212
- 31) RICHARD, D. A. (1975): Cnemidocoptic mange in parakeets. *Vet. Med./Small Anim. Clinic.*, **70**, 729-731
- 32) SAKAMOTO, T., KONO, I., YASUDA, N., SAKOH, T. & KAWABATA, S. (1981): Studies on parasites of corvus 1. Parasites of *Corvus macrorhynchos* in Kagoshima District. *Bull. Fac. Agr., Kagoshima University*, **31**, 83-93 (in Japanese)
- 33) SCHOCK, R. C. & COOPER, R. (1978): Internal parasitism in captive birds. *Mod. Vet. Prac.*, **59**, 439-443
- 34) SHANTHIKUMAR, S. R. (1987): Helminthology, In: E. W. Burr (Ed) *Companion Bird Medicine*, 1st Edn, Ames, Iowa State University Press, pp. 135-146
- 35) SIRONI, G., RAMPIN, T. & BURZONI, G. (1991): Cryptosporidiosis in game birds. *Vet. Rec.*, **129**, 337-338
- 36) SMITH, J. H., MEIER, J. L., NEILL, P. J. G. & BOX, E. D. (1987): Pathogenesis of *Sarcocystis falcatula* in the budgerigar: I. Early pulmonary schizogony. II. Pulmonary Pathology. *Lab. Invest.*, **56**, 60-84
- 37) STEINER, C. V. & DAVIS, R. B. (1979): Scaly-leg and face-mite infestation in a parakeet. *Vet. Med./Small Anim. Clinic.*, **74**, 965-968
- 38) TSAI, S. S., HO, L. F., CHANG, C. F. & CHU, R. M. (1983): Cryptosporidiosis in domestic birds. *Chin. J. Microbiol. Immunol.*, **16**, 307-313
- 39) YAMASHITA, T., HIRAI, K., SHIMAKURA, S., ITOH, K., HIRATA, A. & HASHIMOTO, A. (1981): Recent occurrence of chlamydiosis and giardiasis in budgerigars (*Melopsittacus undulatus*) in Japan. *Jpn. J. Vet. Sci.*, **43**, 963-965
- 40) YUNKER, C. E. & ISHAK, K. G. (1957): Histopathological observations on the sequence of infection in knemidocoptic mange of budgerigars (*Melopsittacus undulatus*). *J. Parasitol.*, **43**, 664-669