



HOKKAIDO UNIVERSITY

Title	ULTRASONOGRAPHY AND ANGIOGRAPHIC EXAMINATION OF NORMAL CANINE LIVER VESSELS
Author(s)	MWANZA, Timothy; MIYAMOTO, Toru; OKUMURA, Masahiro et al.
Citation	Japanese Journal of Veterinary Research, 44(3), 179-188
Issue Date	1996-12-18
DOI	https://doi.org/10.14943/jjvr.44.3.179
Doc URL	https://hdl.handle.net/2115/2570
Type	departmental bulletin paper
File Information	KJ00002398265.pdf



ULTRASONOGRAPHY AND ANGIOGRAPHIC EXAMINATION OF NORMAL CANINE LIVER VESSELS.

Timothy MWANZA, Toru MIYAMOTO, Masahiro OKUMURA,
Mitsuyoshi HAGIO and Toru FUJINAGA.

(Accepted for publication: Nov. 13, 1996)

ABSTRACT

The aim of this study is to provide a description of the ultrasonographic and angiographic anatomy of the hepatic and portal veins in normal dogs. Knowledge of this anatomy is essential for the proper diagnosis and correction of hepatic vessel anomalies like portal systemic shunts. Cranial mesenteric portography was done in 10 adult mongrel dogs to visualize the portal vein and its branches while the hepatic veins were visualized using the transvenous retrograde angiography method. Longitudinal and transverse ultrasound scans of the liver were done in the same dogs in left and right lateral positions in order to determine the best positions for imaging the different liver vessels. The distribution pattern of the hepatic and portal veins could be demonstrated by both ultrasonography and contrast angiography. Hepatic arteries are not usually visualized ultrasonographically. Ultrasound provided dynamic information that could not be obtained by contrast radiography. Super imposition of all vessels in the angiographic studies made the description of the branches of the liver vessels difficult. The results of the present study suggest that both methods may provide important complementary information in the diagnosis and planning of surgical procedures for the correction of vessel anomalies in the canine liver.

Key Words: Ultrasonography, angiography, liver vessels, dog

Radiography is an indispensable tool in veterinary diagnostics. On the other hand the role of diagnostic ultrasound in all aspects of veterinary medicine has been steadily increasing. It provides the best safe and non invasive method of evaluating the liver and it's vessels. It's easy availability and portability favor it as a primary method of evaluating the hepatic vascular system^{1,2,17)}. A complete examination of the liver includes the evaluation of the parenchyma, portal and hepatic veins and the biliary

system. The choice of imaging modality depends on the information required and on the facilities available³⁻⁶. Accurate ultrasound diagnosis of liver vessel anomalies is based on the information obtained from the history, physical examination, laboratory data and on the results of other imaging procedures, especially radiography. Knowledge of the normal radiographic anatomy of the liver vessels enables the examiner to conduct the ultrasound examination in an efficient manner⁷. It is also essential for proper interpretation of the ultrasonographic findings⁸. Surgery is the best treatment for vascular anomalies in the liver like intrahepatic or extrahepatic portal systemic shunts. This requires a profound understanding of the anatomy of the liver vessels⁹.

The purpose of this report is to provide a description of the ultrasonographic and angiographic anatomy of the hepatic and portal veins of the normal dog. This is important for the diagnosis and subsequent correction of liver vessel anomalies.

MATERIALS AND METHODS

Experimental dogs

Ten adult mongrel dogs from the experimental animal pool of the Laboratory of Veterinary Surgery were randomly selected for this study. Six were males and four were females weighing between 10 and 14 kg. The dogs were evaluated to be healthy on physical and clinical laboratory examinations. They were housed in individual cages and were fed a balanced standard dry food diet without restriction. The examinations were carried out after an overnight fast.

Ultrasound examination

Ultrasound examinations were performed using a HITACHI EUB-565A ultrasound system (Hitachi Med. Co., Tokyo, Japan). Sedation of the dogs was often not necessary. Manual restraint was usually enough. If needed flunitrazepam (0.03 mg/kg, iv.) and atropine sulfate (0.03 mg/kg, sc.) were administered to overcome operator difficulties. The dogs were fasted overnight before the examination because food and gas in the gastrointestinal tract disturbs the propagation of the ultrasound waves. The cranial ventral abdomen up to the rib cage was clipped. An ultrasonic coupling gel was applied to the transducer. Transducer selection depended on the animal size. We used a 3.5 MHz electronic sector transducer for most of the animals and a 5.0 MHz and 6.5 MHz electronic transducer for the smaller animals^{13,14}.

With the animal laying on it's right side, the transducer was placed caudal to the xiphoid process and the ultrasound beam directed cranially. Then the transducer was moved along the rib cage until all of the left side had been examined. Starting again at the xiphoid but with the transducer turned around 90° transverse scans were done. The procedure was repeated with the animal on its left side, starting in the 5th intercostal space progressing cranially in order to determine the best locations for visualizing the gallbladder, the portal and hepatic veins and the caudal vena cava (CVC)^{5,7}.

Ultrasound examination was done before angiography.

Angiographic examination

For the angiographic studies, the dogs were sedated with flunitrazepam (0.03 mg/kg, iv.) and atropine sulfate (0.03 mg/kg, sc.). Anesthesia was induced with thiopental sodium (10–15 mg/kg, iv.) and maintained with 0.5–2.0% halothane in oxygen by an endotracheal tube. Cranial mesenteric or splenic vein portography was done according to the methods described by Schmidt & Suter¹⁵⁾ and Suter¹⁶⁾. The dogs were placed in dorsal recumbency and the site for a midline incision surgically prepared and draped. The jejunum or the spleen was exteriorized and a cranial mesenteric or splenic vein identified. A 6 Fr. general purpose tube (Atom Co. Ltd, Tokyo, Japan) was introduced into the vein and tied into place. A test injection of 2 to 3 ml Urografin (Schering AG, Berlin, Germany) was made and fluoroscopically monitored for proper positioning of the catheter. Ten to 15 ml Urografin, depending on the weight of the dog, was then rapidly injected by hand and an X-ray taken at the end of the injection. The contrast injections were repeated in left lateral and right lateral positions.

In the hepatic vein contrast studies, we used the transvenous retrograde angiography method described by Orima *et al.*¹¹⁾ for the detection of portal systemic shunts. A 6–8 Fr. general purpose tube was inserted via a surgically prepared medial saphenous vein and advanced under fluoroscopic guidance cranially to the renal venous anastomosis of the vena cava and caudally to the hepatic venous anastomosis. After compressing the vena cava in the thorax by applying pressure to the breathing bag, a bolus injection of Urografin was made. A radiograph was then taken at the end of the injection or the flow of the contrast media was recorded on video from the fluoroscope.

RESULTS

Ultrasonographic findings

The structures observed in the liver on ultrasound examination were the gallbladder, seen as a round or oval anechoic structure towards the midline, the CVC, the portal veins and the hepatic veins. In all the dogs examined the portal veins and hepatic veins could be displayed. With the transducer placed immediately caudal to the xiphoid process and directed cranially, the portal vein and the gallbladder were located (Fig. 1). These two structures served as important landmarks for further examination. By rotating the transducer into a transverse position and slightly caudal to the gallbladder neck, some hepatic veins were seen. The right and left branches of the portal vein could not be clearly visualized in the same scan because their branching does not occur at the same place. The intrahepatic branches of the portal vein could be differentiated from the hepatic veins by their echogenic walls (Figs. 2a and 2b), that the hepatic veins do not have (Fig. 3). Through the 11th or 12th right

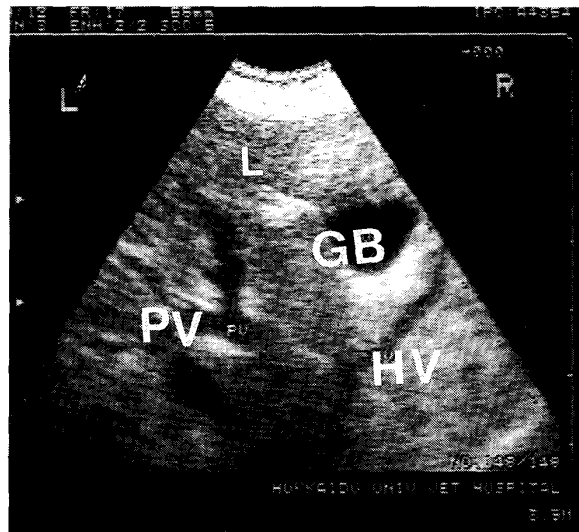


Fig. 1. Transverse scan through the liver (L) showing the gallbladder (GB), the portal vein (PV) and the hepatic vein (HV). The echogenic walls of the portal vein and the anechoic ones of the hepatic vein can be clearly seen.

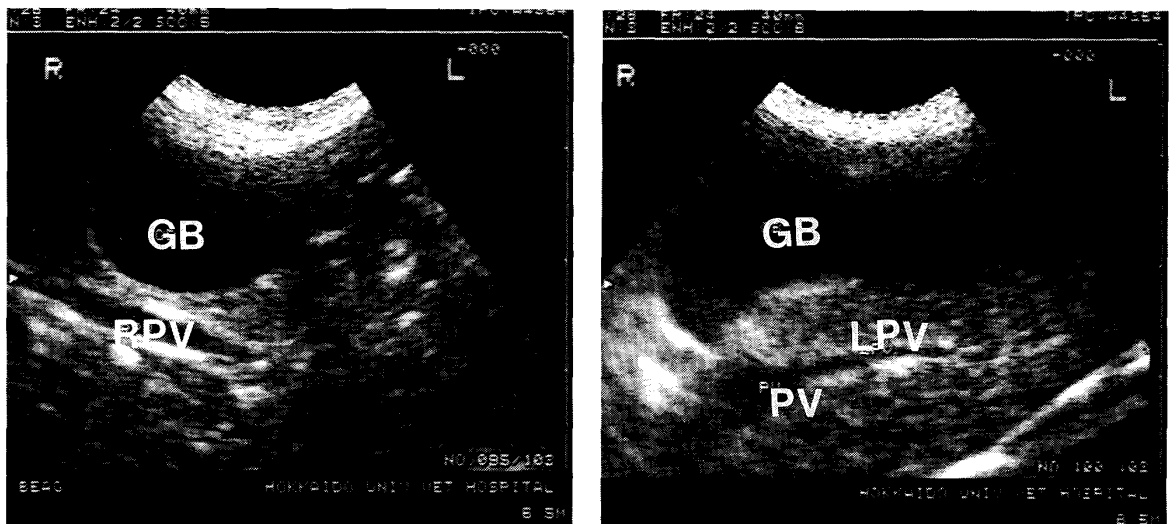


Fig. 2a and 2b. Transverse scan through the liver. The right and left portal veins can be seen in different planes. The hyperechoic walls can be seen.

GB : Gallbladder.

PV : Portal vein.

RPV : Right portal vein.

LPV : Left portal vein.

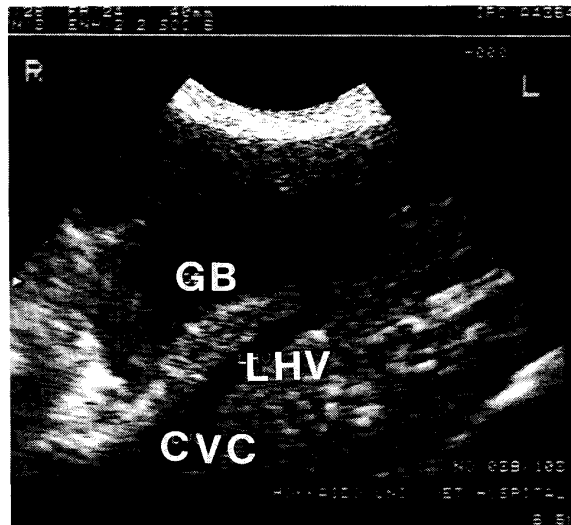


Fig. 3. The left main hepatic vein (LHV) draining into the caudal vena cava (CVC).

intercostal space, the portal vein and the CVC were easily visualized in transverse scans. From the left side, hepatic veins could be recognized near the diaphragm. Here the veins from the left and medial lobes of the liver join to form the main left hepatic vein, a major trunk draining into the CVC (Fig. 3). The portal veins become smaller as they go deeper into the parenchyma while the hepatic veins become larger as they flow towards the CVC.

Angiographic findings

Portal veins

In all the dogs examined, the main portal vein and all its intrahepatic branches were well filled with the contrast medium. After entering the liver, the portal vein gave off a branch to the right which divided into two further branches. These branches supply the right lateral and right medial lobes of the liver. The portal vein continued cranial making a slight curve to the left. Here another branch went off to the right which again divided into two branches. The portal vein then divided into 3 to 5 more branches supplying the rest of the liver lobes (Fig. 4 and 5). This branching pattern differed very little in all the dogs examined. The number of intrahepatic branches of the portal vein which could be outlined depended on the amount of contrast media injected and on the rate of injection. Too slow an injection lead to dilution of the contrast media and poor visualization of the peripheral branches.

Hepatic veins

In the retrograde angiography studies, the contrast media filled the CVC and flowed back into the hepatic veins. The flow back depended on the amount of

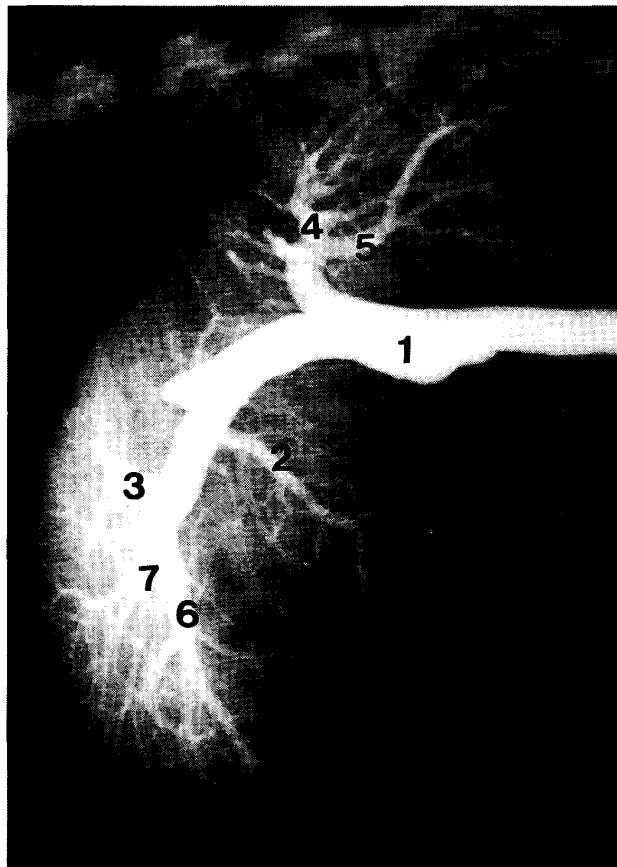


Fig. 4. Mesenteric portography with the catheter in the main portal vein. The main branches of the portal vein are clearly opacified (Left lateral).

1. Main portal vein.
2. Right medial.
3. Quadrate.
4. Right lateral.
5. Caudate.
6. Left lateral.
7. Left medial.

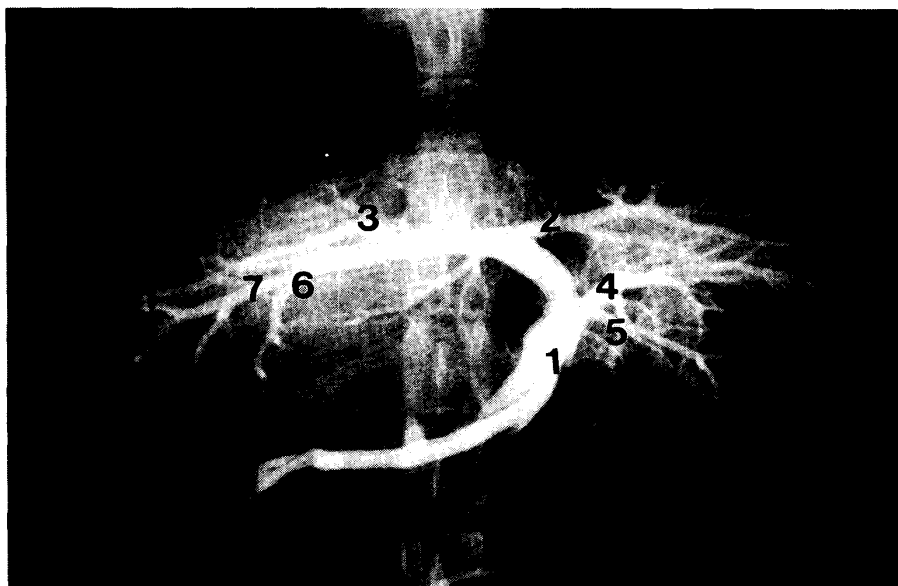


Fig. 5. Vento-dorsal projection of the same cranial mesenteric portograph in Fig.

- 4.
1. Main portal vein.
2. Right medial.
3. Quadrate.
4. Right lateral.
5. Caudate.
6. Left lateral.
7. Left medial.

contrast media needed to fill the CVC, the amount of blood in it and the pressure (20–30 cm H₂O) achieved in the thoracic cavity¹¹). Most of the contrast media tended to flow to the left side of liver. Peripheral vessels could be identified in most of the examinations although it was not possible to clearly allocate the vessels to any particular liver lobe (Fig. 6).

DISCUSSION

In this study, we demonstrated the branching pattern of the hepatic and portal veins in normal dogs using ultrasonography and angiography. In agreement with previous reports^{2,3,8,10}, the distribution pattern of the portal and hepatic veins could be confirmed. However, ultrasound did not show good images of the hepatic veins on the right side due to their small size. Radiographic examination provided good images of the portal venous system. The images of the hepatic veins were of good quality

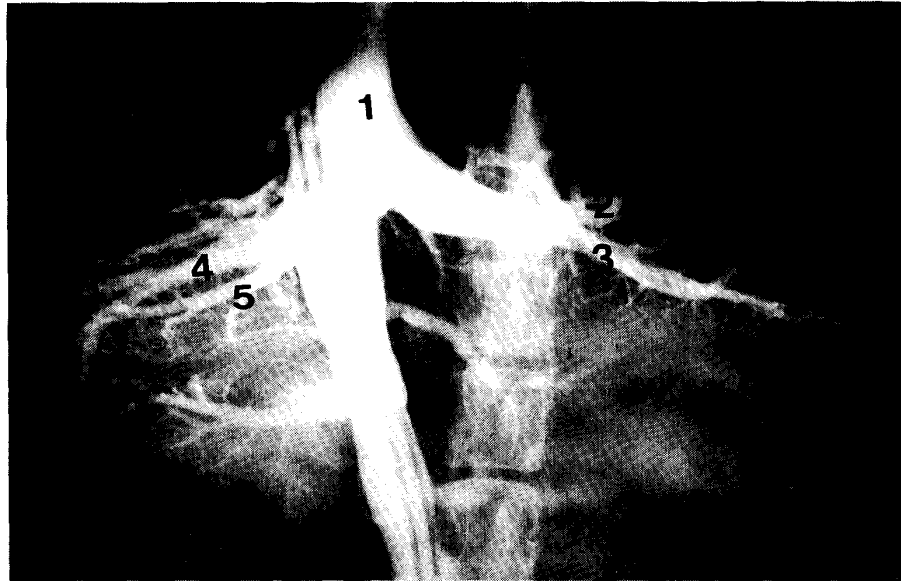


Fig. 6. Retrograde hepatic venography. Not only the major hepatic veins are opacified but also some smaller ones depending on the pressure and amount of contrast media injected.

1. Caudal vena cava.
2. Left medial.
3. Left lateral.
4. Right lateral.
5. Caudate.

when there was adequate retrograde flow from the CVC.

Since hepatic arteries are not usually visualized ultrasonographically, no attempt was made to image them. Hepatic arteriovenous fistulae are a rare vascular anomaly between the portal vein and a hepatic artery. This leads to the inversion of portal flow, a typical sign of this disease¹⁶⁾. The common bile duct may be observed in the dog only if it becomes distended.

The major disadvantage of the angiographic method lay in its invasiveness and the need for general anesthesia. This is important in patients in a poor coagulative state who might bleed for a long time following angiographic studies. The need to separately inject contrast media into the two systems makes it more time consuming. However, with ultrasound, portal and hepatic veins can easily be differentiated by their echogenicity.

A complete overview of all vessels could be obtained in the angiographic examination. Superimposition of structures on the film made it difficult to describe the

different branches accurately. Angiography is important for the differentiation of intrahepatic from extrahepatic shunts and single from multiple shunts. In human medicine, angiography, in spite of its invasiveness is still indicated when ultrasonography or computed tomography is inconclusive¹⁸⁾.

Ultrasound provided images without the disadvantages of angiography and also provided additional information on the internal architecture of the liver that could not be obtained from plain or contrast radiography without the potential for intra-abdominal hemorrhage or contrast media leakage^{8,15)}. If it is performed early in the diagnostic process, ultrasound is of great value in the planning of further diagnostic and therapeutic procedures. It can be repeated without risk to patient or operator. The inability to visualize the different vessels over a long distance without relocating the transducer proved to be a major constraint. Ascites, intestinal gas or body type at times obscured some details¹²⁾.

The major reason for selecting a particular imaging modality is to get as much accurate information as is possible about the pathological changes in the patient. Other factors such as prolonged scan times in ultrasound examination, and the risk of radiation to both the patient and the examiner during X-ray examination must also be considered in addition to the final cost of the examination⁴⁾. Both methods have advantages and disadvantages. Neither method replaces the other. They provide valuable complementary information. Angiography, although still important can now be used more selectively. A sensible variation or combination of contrast radiography and ultrasonography may provide very useful information especially in the planning of surgical procedures for the correction of vessel anomalies in the liver.

REFERENCES

- 1) ADAMS, C. D. & EVANS, L. E. : Ultrasound as a diagnostic tool in equine and small animal practice. *Iowa State Vet.* **51** : 43–47, 1989.
- 2) BECKER, C. D. & COOPERBERG, P. L. : Sonography of the hepatic vascular system. *Am. J. Radiol.* **150** : 990–1005, 1988.
- 3) CARTEE, R. E. : Diagnostic real time ultrasonography of the liver of the dog and cat. *J. Am. Anim. Hosp. Assoc.* **17** : 731–737, 1981.
- 4) DAVIS, L. P. & MCCARROL, K. : Correlative imaging of the liver and hepatobiliary system. *Sem. Nucl. Med.* **24** : 208–218, 1994.
- 5) HITTMAR, K. : Clinical and technical comparison of ultrasound instruments and a sonographic examination method for small animal diagnostics. *Ph.D.Thesis Vet. Med. Univ. Vienna*, (1991).
- 6) HOLT, D. E., SHELLING, C. G. & SAUNDERS, M. H. & ORSCHER, R. J. : Correlation of ultrasonographic findings with surgical, portographic, and necropsy findings in dogs and cats with portosystemic shunts: 63 Cases (1987–1993). *J. Am. Vet. Med. Assoc.* **207** : 1190–1193, 1995.
- 7) JIAN-XIN, WU & CARLISTLE, C. H. : Ultrasonographic examination of the liver based

- on the recognition of hepatic and portal veins. *Vet. Rad. & Ultrasound* **36**: 234–239, 1995.
- 8) KLEIN, J. L. & LAMB, C. R. : Comparative organ imaging : The gastrointestinal tract. *Vet. Radiol.* **30** : 131–141, 1989.
 - 9) LAMB, C. R. : Ultrasonography of the liver and biliary tract : *Prob. Vet. Med.* **3** : 555–573, 1991.
 - 10) NYLAND, T. G. & PARK, R. D. : Hepatic ultrasonography in the dog. *Vet. Radiol.* **21** : 74–84, 1983.
 - 11) ORIMA, H., FUJITA, M., WASHIZU, T. & WASHIZU, M. : Transvenous retrograde angiography for the detection of portal-caudal caval shunt. *J. Vet. Med. Sci.* **56** : 1187–1189, 1994.
 - 12) PARVEY, R. H., EISENBERG, R. L., VISHAN, G. & KREBS, C. A. : Duplex sonography of the portal venous system. *Am. J. Radiol.* **152** : 765–770, 1989.
 - 13) PROBST, A. & KUNZEL, W. : Anatomische Grundlagen zur sonographische Differenzierung der Leberlappen des Hundes. *Wien. Tieraerztl. Mschr.* **80** : 200–207, 1993.
 - 14) SANTILLI, R. A. & BILLER, D. S. : Ultrasonography of the liver and biliary tract. *Veterinaria* **3** : 19–26, 1993.
 - 15) SCHMIDT, S. & SUTER, P. : Angiography of the hepatic and portal venous system in the dog and cat : An investigative method. *Vet. Radiol.* **21** : 57–77, 1980.
 - 16) SUTER, P. F. : Portal vein anomalies in the dog. Their angiographic diagnosis. *Vet. Radiol.* **16** : 83–97, 1980.
 - 17) VOORHUT, G. : Diagnostic imaging in dogs : Radiography, ultrasonography, and computed tomography for the examination of the abdomen. *Vet. Quart.* **17** : S 30–S 31, 1995.
 - 18) ZAJKO, A. B., BRON, K. M., STARZL, T. E., VAN THIEL, D. H., GARTNER, J. C., IWATSUKI, S., SHAW B. W., ZITELLI, B. J., MALATAK, J. J., URBACH, A. H. : Angiography of liver transplantation patients. *Radiology* **157** : 305–311, 1985.