HOKKAIDO UNIVERSITY

Title	A MONOCLONAL ANTIBODY, 169.1,AGAINST CANINE LEUKOCYTE SURFACE ANTIGEN IDENTIFIES CYTOSKELETAL COMPONENTS IN EPITHELIAL CELLS AND PERIPHERAL NEURONS
Author(s)	IWAMI, Yukihiko; HASHIMOTO, Yoshiharu; IWANAGA, Toshihiko
Citation	Japanese Journal of Veterinary Research, 44(4), 193-206
Issue Date	1997-02-28
DOI	https://doi.org/10.14943/jjvr.44.4.193
Doc URL	https://hdl.handle.net/2115/2573
Type	departmental bulletin paper
File Information	KJ00002398273.pdf

Hokkaido University Collection of Scholarly and Academic Papers : HUSCAP

Jpn. J. Vet. Res. **44**(4): 193–206 (1997)

FULL PAPER

A MONOCLONAL ANTIBODY, 169.1, AGAINST CANINE LEUKOCYTE SURFACE ANTIGEN IDENTIFIES CYTOSKELETAL COMPONENTS IN EPITHELIAL CELLS AND PERIPHERAL NEURONS

Yukihiko IWAMI, Yoshiharu HASHIMOTO and Toshihiko IWANAGA

(Accepted for publication: Jan. 13, 1997)

ABSTRACT

Monoclonal antibodies were produced by immunizing BALB/c mice with freshly prepared canine thymocytes and peripheral blood leukocytes. Flow cytometric analysis of canine peripheral blood leukocytes showed that an antibody, designated 169.1, recognized about 60% of non-lymphoid cells, but reacted with less than 3% of lymphocytes. Immunohistochemistry using frozen sections showed that several types of epithelial cells such as epithelial reticulum cells in the thymus and ductal system in the parotid gland exhibited an intense positive reaction to antibody 169.1. Moreover, the ellipsoidal sheath in the spleen and non-myelinated nerve fibers in the peripheral nervous system had selectively positive reactions; in the latter, filamentous structures were visible under a light microscope. In contrast to the data from the flow cytometric analysis, no leukocytes on sections reacted with 169.1. Immunoblot assay revealed that 169.1 recognized antigens with molecular weights of 48 and 52 kDa under reducing conditions. These findings characterize 169.1 as an antibody against a cytoskeletal protein rich in epithelial cells and neurons.

Key Words: monoclonal antibody, canine leukocyte, flow cytometry, immunohistochemistry, cytoskeletal protein

INTRODUCTION

Monoclonal antibodies against leukocyte surface antigens have been used extensively for identification of various types of immune cells in humans and rodents. In the field of veterinary medicine such monoclonal antibodies would be of value in large animal species including ruminants[10], horses[6] and pigs[14]. Numerous monoclonal antibodies have also been raised against canine leukocyte surface antigens, as submitted for inclusion in the first international leukocyte surface antigen workshop[2].

Laboratory of Anatomy, Department of Biomedical Science, Graduate School of Veterinary Medicine, Hokkaido University, Kita 18–Nishi 9, Kita-ku, Sapporo 060, Japan.

However, few antibodies are available for both flow cytometric (FCM) and histological analysis of immune cells in the dog.

The aim of the present study was primarily to produce novel monoclonal antibodies against canine leukocytes and identify immunoreactive cells by flow cytometry and immunohistochemistry. One of those monoclonal antibodies, designated 169.1, reacted with non-lymphoid leukocytes in FCM analysis, while immunohistochemical staining demonstrated a predominant distribution of the immunoreactivity in epithelial cells and neurons.

MATERIALS AND METHODS

Animals, immunization schedule and cell fusion: BALB/c mice, originally purchased from Nippon Clea (Tokyo, Japan), and mongrel dogs were raised in our breeding facilities.

Two mice were immunized with a subcutaneous injection of an emulsion consisting of 2×10^7 freshly prepared thymocytes from a 2-month-old puppy and Freund's complete adjuvant. At 16 weeks after the initial immunization, the mice were boosted intravenously and intraperitoneally with 2×10^6 leukocytes obtained from the peripheral blood of another dog aged 4y. The canine peripheral blood leukocytes (PBL) were isolated from the buffy coat and treated twice with a red cell-lysis buffer (140 mM NH_4Cl in 17 mM Tris-HCl buffer, pH 7.4) to remove platelets and erythrocytes. Four days after the boost, mouse spleens were prepared aseptically for cell fusion. Fusion of the mouse spleen cells and myeloma P3X63 Ag 8-U1 was performed according to the general procedure described by Köhler and Milstein[5].

Screening assay, cloning and isotype analysis: Hybridoma supernatants were tested primarily by FCM analysis. The method, including the selection of buffers for indirect immunofluorescence labeling, was based on the protocol suggested by the Canine Leukocyte Antigen Workshop[2]. Culture supernatant (50 μl) was incubated for 45 min with 1×10^6 PBL of dogs. After the cells were washed three times, they were incubated with fluorescein isothiocyanate (FITC)-labeled goat anti-mouse immunoglobulins (Organon Technica Corp., USA) diluted 1:100 for 45 min, and then analyzed by EPICS PROFILE (Coulter, USA) after three washing steps and formaldehyde fixation.

Some of the hybridoma supernatants, which exhibited different histogram patterns for lymphoid and non-lymphoid cells in the primary FCM analysis, were subsequently screened on tissue sections using the peroxidase-anti-peroxidase (PAP) method. The lymphoid organs of a 2-month-old puppy and a 1-year-old dog were used for the immunohistochemical examination. The thymus, mesenteric lymph nodes, spleen and palatine tonsils were removed and snap-frozen in liquid nitrogen. Cryostat sections, 6 μm-thick, were air-dried and fixed with ice-cold acetone for 5 min. They were incubated overnight with the undiluted hybridoma supernatants or a normal mouse serum diluted 1:100 with 0.01M phosphate-buffered saline (PBS, pH 7.4) as a negative

control, followed by peroxidase-labeled goat anti-mouse immunoglobulins (Organon Technica Corp., USA) diluted 1:100 in PBS for 60 min. After washing in PBS, the sections were incubated with mouse-PAP (Serotec, England) diluted 1:100 in PBS for 60 min. Peroxidase activity was detected by incubation for several minutes in a solution of 0.05M Tris-HCl buffer (pH 7.6) containing 0.2 mg/ml 3,3'-diaminobenzidine tetrahydrochloride (DAB) and 0.03% hydrogen peroxide. The reaction product was intensified by incubation for 5 min in 1% $CuSO_4$ dissolved in 150 mM NaCl. The immunostained sections were counterstained with hematoxylin.

An antibody-producing hybridoma, reactive only with non-lymphoid cells in FCM analysis and exhibiting a broad distribution of immunoreactivity on tissue sections, was recloned twice by limiting dilution and denominated 169.1. Immunoglobulin class and subclass of the antibody were determined by means of a mouse monoclonal antibody isotyping kit (Amersham, England). The hybridoma supernatant was stored at 4°C with 0.1% NaN_3 before use.

Characterization of monoclonal antibody 169.1 :

(1) *Additional FCM analysis* : To characterize non-lymphoid cells intensely reactive with 169.1, PBL collected from three adult mongrel dogs were resuspended, at a concentration of 2×10^6 cells per ml, in RPMI-1640 medium containing 10% fetal calf serum and incubated in cell culture dish (Corning, USA) for 1 h at 37°C. Non-adherent cells were collected with PBS and subjected to FCM analysis.

(2) *Immunohistochemistry* : Distribution of antigens detectable with antibody 169.1 was examined on tissue sections. Five mongrel dogs of either sex, aged 2–3y, were killed by deep anesthesia. Fresh tissues were obtained from the following organs and snap-frozen in liquid nitrogen : the lymphoid organs mentioned above, central nervous system (the cerebrum, cerebellum, medulla oblongata and spinal cord), peripheral nervous system (the spinal ganglion, vagosympathetic trunk, optic nerve, maxillary nerve, facial nerve and hypoglossal nerve), digestive tract (the parotid gland, tongue, liver, pancreas and gastrointestinal tract), skin, urinary organs (the kidney and urinary bladder), and endocrine organs (the thyroid gland, adrenal gland and hypophysis). Cryostat sections were stained with 169.1 using the same method as for the histological screening.

(3) Molecular weight analysis : The western blot technique using electrophoretically separated tissue antigens was carried out to determine the molecular weight of the antigen recognized by monoclonal antibody 169.1. Tissue antigens were extracted from the parotid gland, since immunohistochmically it showed the most intense reaction with 169.1. The parotid gland from a 2-month-old puppy was minced in a minimal volume of PBS. Then 3 ml of cell lysis buffer (150 mM NaCl, 2 mM phenylmethylsulfonyl fluoride, 2.5 mM iodoacetamide and 1% Nonidet P-40 in 10 mM Tris-HCl buffer, pH 7.4) per 1g of tissue was added and voltexed. After a 15 min incubation on ice, non-solubilized material was removed by centrifugation at $2,500\times g$ for 15 min and

filtration through 0.45 μm membrane filter, and the resultant product was subjected to 10% sodium dodecyl sulfate-polyacrylamide gel electrophoresis in a minigel apparatus (Atto, Japan) according to Laemmli[7]. Samples (8 μl) used were either non-reduced or reduced with 0.1M dithiothreitol.

The separated proteins were transferred at 2 mA/cm^2 for 1 h onto a nitrocellulose membrane in a semidry-type transfer chamber (Atto, Japan). Free binding sites on the membrane were blocked with PBS containing 5% powder milk (PBS-PM), and incubated with either undiluted 169.1 supernatant or 1% normal mouse serum as a negative control. Following incubation with peroxidase-labeled goat anti-mouse immunoglobulins diluted 1:1,000 with PBS-PM, peroxidase activity was detected by immersing the membrane in DAB solution containing hydrogen-peroxide.

RESULTS

Screening, cloning and isotype analysis of monoclonal antibody 169.1 : Ninety-nine clones among 169 hybridomas obtained showed positive reactions to PBL by FCM screening. Immunohistochemistry revealed that one of them (hybridoma No.169) showed intense and characteristic staining results on tissue sections. An antibody 169.1 was established after two-time cloning by limiting dilution and further analyzed. In the isotype analysis, 169.1 was determined to be of mouse IgM.

FCM analysis of PBL using antibody 169.1 : Antibody 169.1 hardly reacted with lymphocytes (Fig. 1a), but did so with other populations of leukocytes (Fig. 1b). Moreover, analysis of cytograms demonstrated its intense affinity to the monocyte population and moderately intense affinity to granulocytes (Fig. 1c). The cell population intensely labeled by 169.1 was completely deleted after cell-culture-dish treatment (Fig. 1d), implying that immunopositive cells were adherent cells.

Immunohistochemistry :

(1) *Lymphoid organs* : In the thymus, a positive reaction with 169.1 was localized selectively in the cytoplasm of epithelial reticulum cells throughout the thymus (Fig. 2). Stellate-shaped reticulum cells and their fine processes in the cortex were moderately stained (Fig. 2b), while in the medulla both reticulum cells projecting thick processes and Hassall's bodies had intensely positive reactions (Fig. 2c).

In the palatine tonsil, overlying epithelium was intensely positive from the stratum basal to the stratum spinosum. The epithelium facing to tonsilar crypts was also intensely stained through whole layers, and contained numerous lymphocytes which were negative, resulting in a mosaic pattern of staining (Figs. 3a, b).

Positive reaction in the spleen was restricted to the sheathed arteries (Fig. 3c). Entire cell-layers of the ellipsoidal sheath were stained darkly leaving clear spaces for vascular endothelial cells and the lumen (Fig. 3d). Surrounding reticular cells and other cell elements in the red pulp remained unstained. No immunoreactive cells, except for nerve fibers, were recognizable in the mesentery lymph nodes or in Peyer's

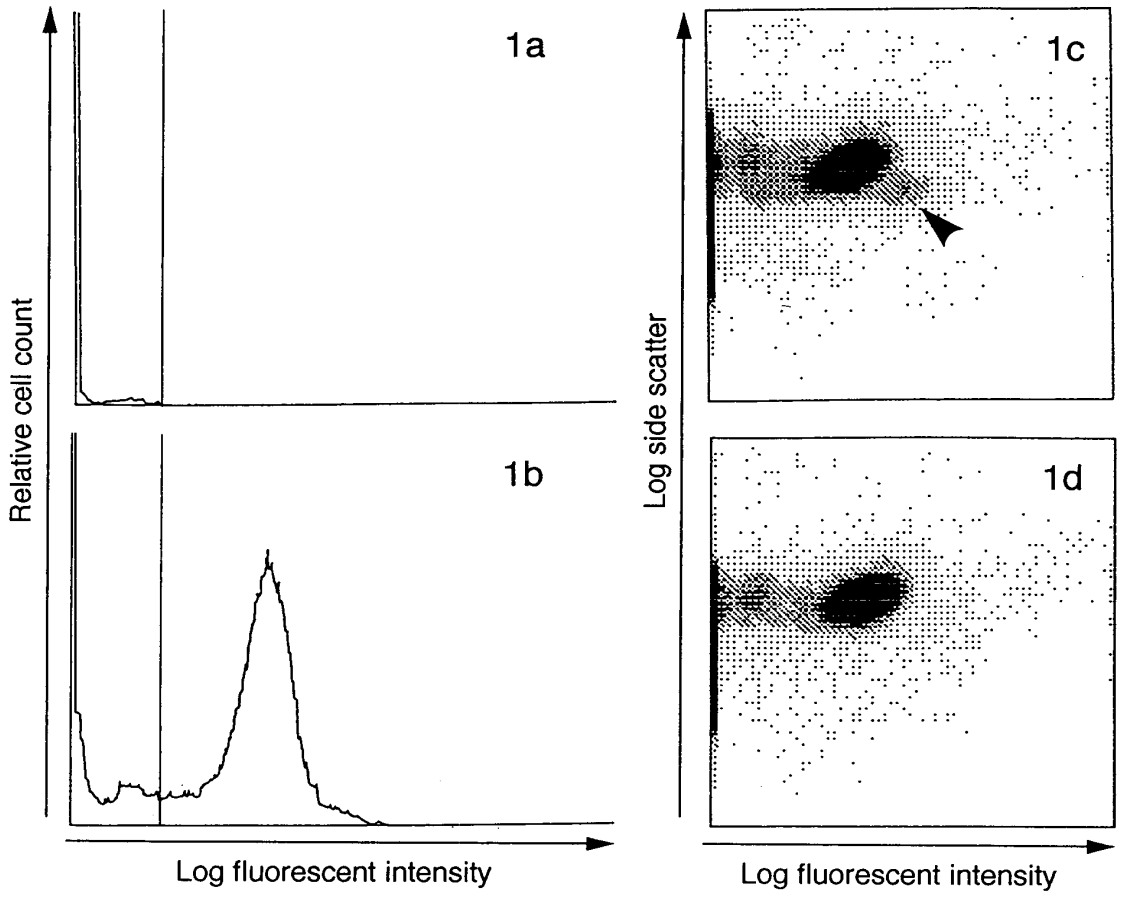

Fig. 1. Representative FCM histograms (1a, b) and cytograms (1c, d) of canine peripheral blood leukocytes reactive with antibody 169.1. 1a ; Only a few lymphoid cells (less than 3% of all lymphoid cells) are immunolabeled. 1b ; 58% of non-lymphoid cells have positive reaction. The vertical line represents the border between the negative and positive reactions. The most intensely reacting cell population (1c, arrowhead), adjacent to a major granulocyte population, is completely deleted after cell-culture-dish treatment (1d).

patches, including covering epithelium. In these tissues, lymphocytes and monocytes were negative.

(2) *Nervous system* : Positive staining with 169.1 was recognized in neurons, but not in glial elements or any supporting structures such as the perineurium. The immunoreactivity in neurons was localized exclusively in the cytoplasm, frequently being filamentous in appearance.

Central nervous system : In the cerebrum and cerebellum, no distinct immunoreactivity was found in the gray and white matters. In the medulla oblongata, positive

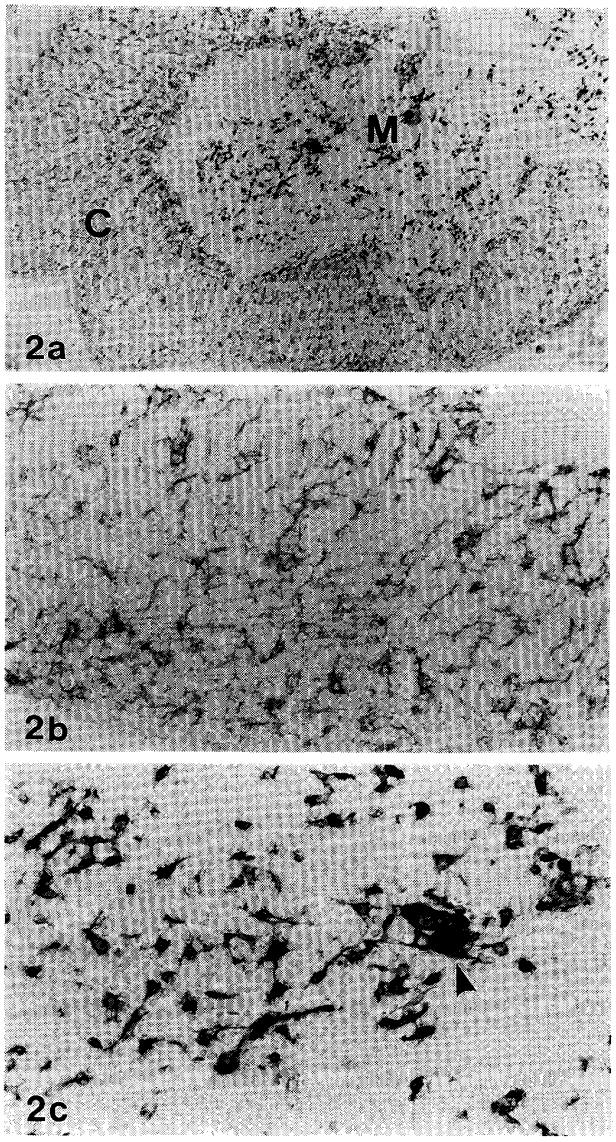

Fig. 2. Immunoperoxidase reaction of canine thymus with antibody 169.1. (2a) Antibody 169.1 labels epithelial reticulum cells throughout the cortex (C) and medulla (M). ×80. (2b) Reticulum cells with their fine processes in the cortex are stained moderately. ×320. (2c) In the medulla both reticulum cells and a Hassal's body (arrowhead) are intensely stained. No thymocytes are labeled with 169.1. ×320.

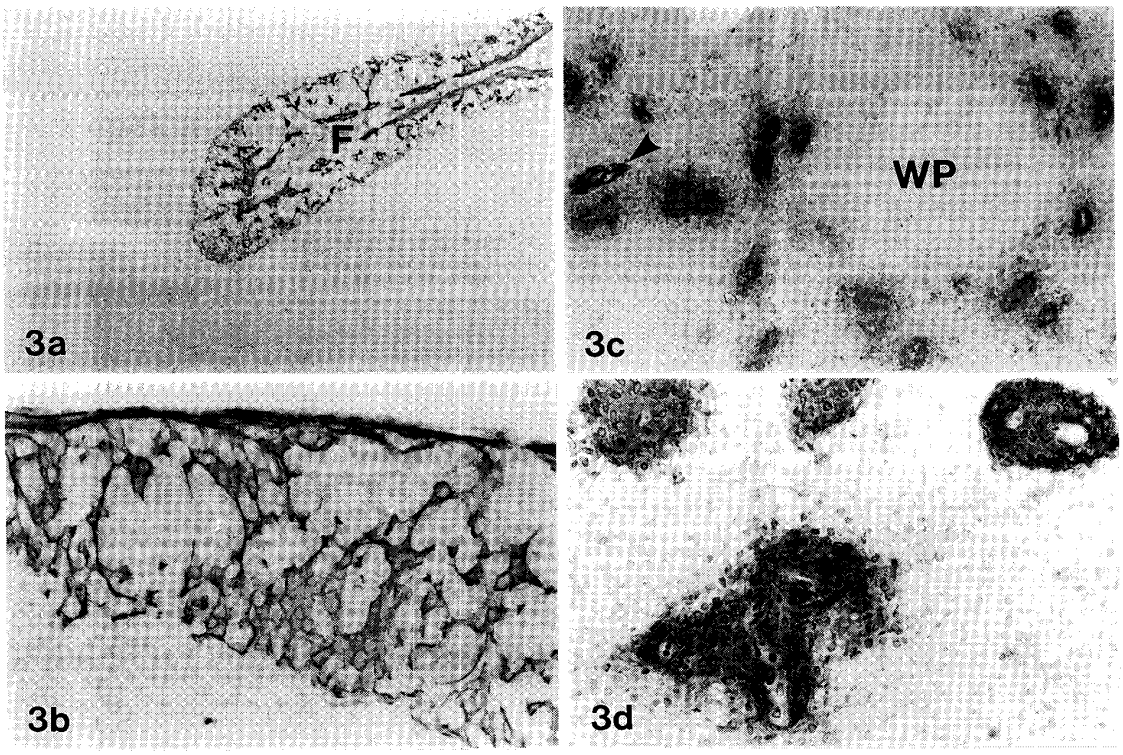

Fig. 3. Immunoperoxidase staining of canine palatine tonsil (3a, b) and spleen (3c, d) with antibody 169.1. (3a) In the palatine tonsil, the stellate-shaped epithelial cells facing to the tonsilar fossa (F) are positively stained. ×80. (3b) A mosaic pattern is formed by the reticulated epithelial cells and immunonegative lymphocytes. ×320. (3c) In the spleen, the ellipsoidal sheath is selectively stained. Nerve fibers (arrowhead) are also stained positively. White pulp (WP) is free from labeling. ×100. (3d) Ellipsoidal sheath is stained darkly leaving clear spaces for vascular endothelial cells and lumen. × 320.

reaction was found in nerve fibers in the fasciculus gracilis, fasciculus cuneatus and the spinal tract of the trigeminal nerve, which are all sensory in nature.

In the spinal cord and associated structures, the immunoreactivity was restricted to sensory elements. Immunoreactive nerve fibers gathered at the apex of the dorsal horn and the funiculus dorsalis. In the latter, the fasciculus gracilis was stained more intensively than the fasciculus cuneatus. Ependymal cells in the central canal were stained positively. The dorsal root contained intensely positive nerve fibers in contrast to the ventral root, which lacked immunoreactive fibers. Immunoreactivity in the dorsal root ganglia was localized selectively in the small nerve cells and their processes, but not in large nerve cells (Figs. 4a, b).

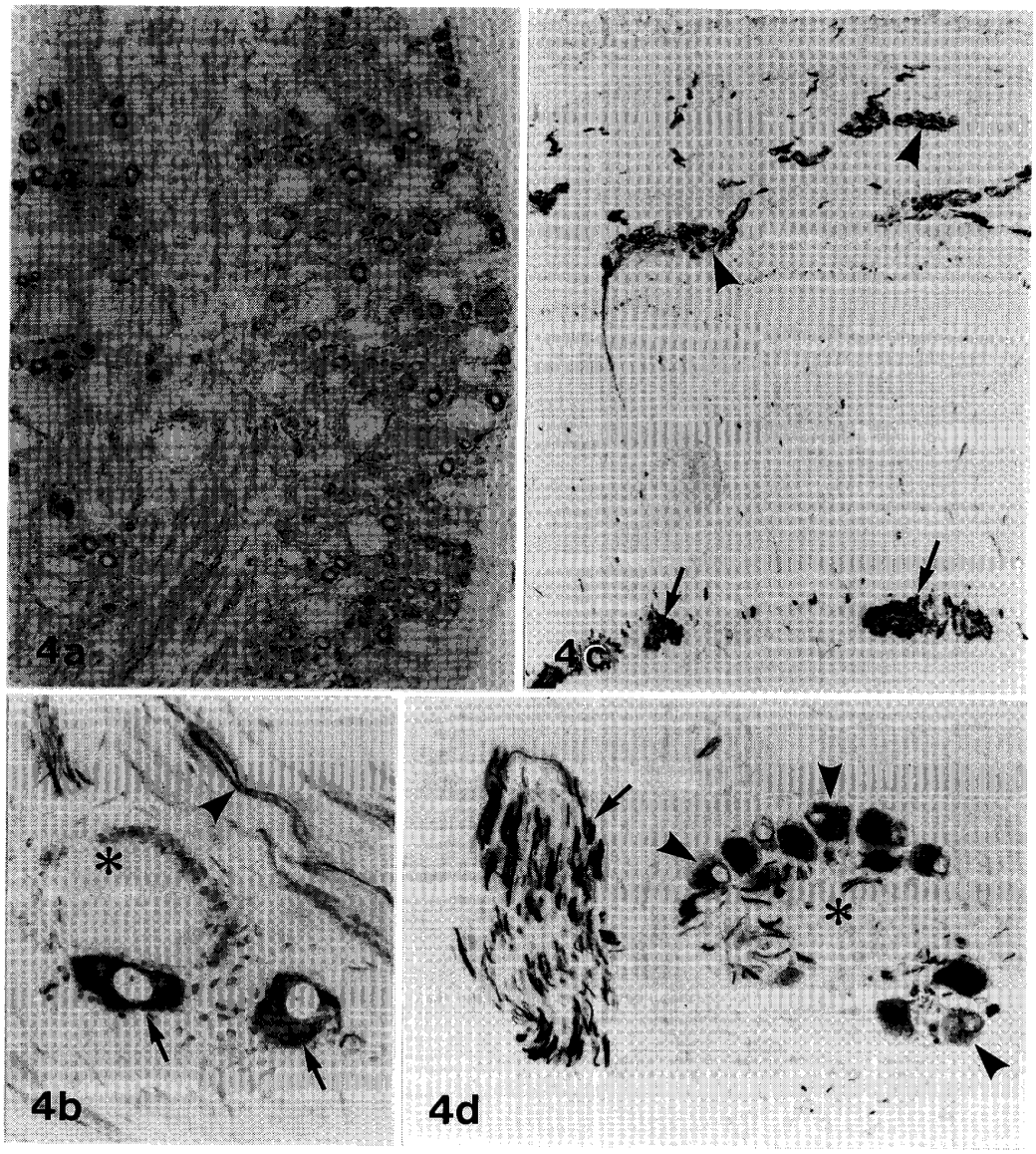

Fig. 4. Immunoperoxidase staining of the canine peripheral nervous system with antibody 169.1. (4a) Relatively small ganglion cells in the spinal ganglion are positively stained, while larger ganglion cells remain unlabeled. ×80. (4b) In a higher magnification of the spinal ganglion, the entire cytoplasm of small ganglion cells (arrows) is intensely stained. A large ganglion cell (asterisk) is unlabeled. Thin nerve fibers (arrowhead) are also intensely stained. ×320. (4c) In the ileum, the submucosal plexus (arrowheads) and myenteric plexus (arrows) are intensely stained. ×80. (4d) In the lingual parasympathetic ganglion, ganglion cells (arrowheads) and non-myelinated thin fibers within a nerve fiber bundle (arrow) are intensely stained, while myelinated thick fibers (asterisk) are negative. ×320.

Peripheral nervous system: The immunoreaction with 169.1 was found exclusively in the sensory and autonomic neurons. Among afferent cranial nerves, the maxillary nerve contained numerous fine immunoreactive nerve fibers, while no immunopositive fibers were contained in the optic nerve. In the hypoglossal nerve, efferent in type, only a few fine nerve fibers were intensely immunoreactive. In the autonomic nervous system, nerve fibers were intensely stained in various organs as clearly shown in the intestine (Figs. 4c, d), while the cell bodies were weakly positive.

(3) *Other organs; Gastrointestinal tract*: In the parotid gland, the immunoreactivity with 169.1 was restricted to the ductal system (Fig. 5a). Intercalated ducts were intensely stained, both the striated portion and excretory duct being less intense in reaction. The stainability of the ductal system tended to decrease in intensity as the diameter of ducts became larger. Glandular cells of acini were completely negative, while myoepithelial cells were weakly stained.

In the tongue, only the epithelium in the filiform papillae was intensely stained with 169.1. The whole layer of the epithelium overlaying the core projection of lamina propria was positive, but their cornified tips were negative (Fig. 5b). In the liver, the epithelia of bile ducts of various sizes were moderately positive, but hepatocytes were only faintly stained. Intense stainability was recognized in the cytoplasm of epithelial cells in the gallbladder. Pancreatic acini were weakly positive, in contrast to intensely or moderately immunoreactive ducts that showed a gradient of staining intensity similar to that of the parotid gland. No immunoreactivity was found in pancreatic islets.

Skin: The immunoreactivity with 169.1 was restricted to the stratum germinativum and stratum spinosum of the epidermis. The external root sheath of hair follicles, sebaceous glands and sweat glands were also positively stained. The stratum corneum in the epidermis and hair itself, however, was unlabeled (Fig. 5c).

Urinary organs: In the kidney, the distal portion of collecting tubules and the papillary ducts were stained positively. Intense immunoreactivity was recognizable in the transitional epithelium of the calyces and pelvis. The transitional epithelium of the bladder, four or five cells thick, was evenly stained positively.

Endocrine organs: In the thyroid gland, follicular epithelium was free from immunoreactivity, and parafollicular cells were only faintly immunopositive. No glandular cells in the cortex and medulla of the adrenal gland were immunoreactive to 169.1. In the hypophysis, no positive reaction was recognizable in any endocrine cells. On the other hand, the epithelium lining the hypophyseal cleft was intensely positive.

Molecular size of immunoreactive substances: A blot run under reduced conditions showed two strong signals at 48 and 52 kDa for the 169.1 with Nonidet P-40-soluble canine parotid gland proteins. Under non-reduced conditions, two weak signals were seen at the same position as those under reduced conditions (Fig. 6).

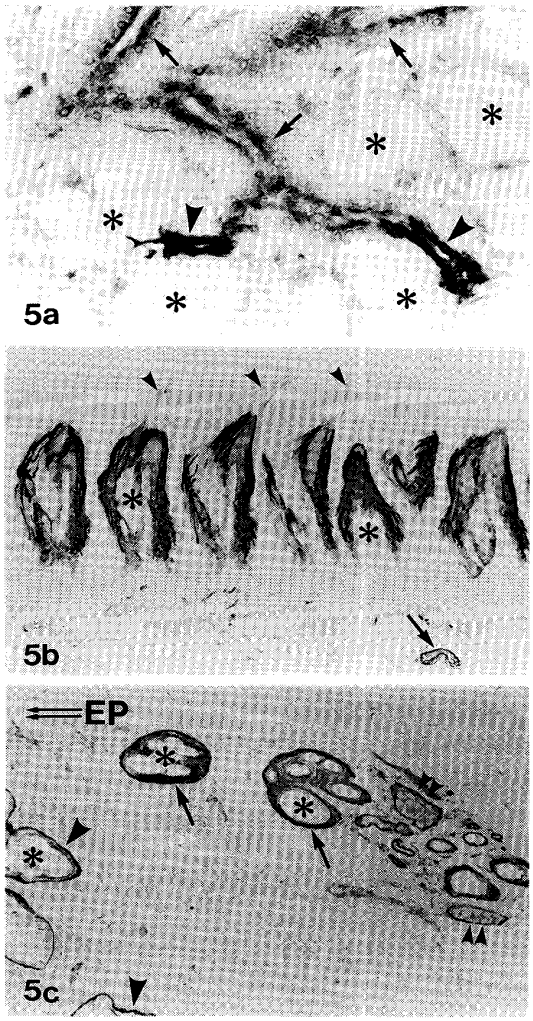

Fig. 5. Immunoperoxidase staining of canine parotid gland (5a), tongue (5b) and skin (5c) with antibody 169.1. (5a) Intercalated ducts (arrowheads) are intensely stained, but striated portions (arrows) have less intense positive reactions. Glandular cells of acini (asterisks) are completely negative. ×320. (5b) In the filiform papillae, only the epithelium overlaying the core projection of lamina propria (asterisks) is positively stained, while the cornified tips (arrowheads) are negative. Nerve fibers (arrow) are also stained positively. ×160. (5c) Intense positive reaction is identified in the epidermis (EP) (arrowheads) and external root sheath of hair follicles (arrows), while the hair itself (asterisks) is negative. The sebaceous glands (double arrowheads) are also positively stained. The direction of epidermis is exhibited with double arrows. ×80.

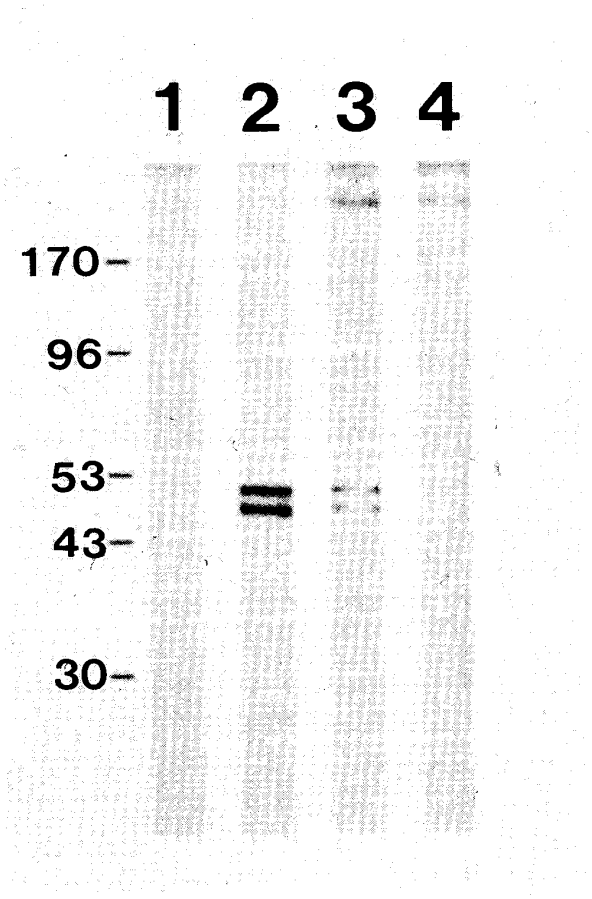

Fig. 6. Western blot after electrophoresis (10% gel) under reduced with 0.1M dithiothreitol (Lanes 1, 2) or non-reduced conditions (Lanes 3, 4) of Nonidet P-40-soluble canine parotid gland proteins. Blots were stained by either 169.1 supernatant (Lanes 2, 3) or 1% normal mouse serum as a negative control (Lanes 1, 4). Molecular weight markers (kDa) are indicated on the left.

Discussion

Epithelial cells and neurons contain some kinds of intermediate filaments in their cytoplasm. Keratins and neurofilament proteins are the most typical filamentous protein contained in epithelial cells and neurons, respectively[9]. Although monoclonal

antibodies against these filaments were used to investigate the origin of human neoplasms[11], few monoclonal antibodies, recognizing both epithelial cells and neurons, have been reported[4,12]. In the present study, a monoclonal antibody was raised against thymocytes and leukocytes obtained from the peripheral blood of dogs, and the distribution of immunoreactive cells with it was examined on tissue sections. The immunoreactivity with the monoclonal antibody designated 169.1 was localized predominantly in the cytoplasm of epithelial cells and neurons in various organs. In the latter cells, filamentous structures were occasionally visible. On the other hand, western-blot analysis revealed the existence of two immunoreactive substances with each molecular weight of 48 and 52 kDa. It is worth noting that the molecular weight of proteins constituting several intermediate filaments was ranging from 40 to 80 kDa[10]. These immunohistochemical and immunoblot analyses of 169.1 reminded us of the immunoreaction with the cytokeratin, a major cytoskeletal protein of epithelial cells, which has a molecular weight of around 50 kDa. In fact, the distribution of immunoreactive cells with 169.1 in the canine tissues was partially consistent with that of monoclonal antibodies against human cytokeratins[15,16]. However, cytokeratins are known to be insoluble in nature, and difficult to extract from tissues if neither denaturing solvents such as 8M urea nor reducing agents such as 2-mercaptoethanol are used[9]. Furthermore, in the present study, the samples used for the identification of molecular weight were obtained by means of the buffer used for the extraction of membrane proteins. Therefore, the antigen recognized by 169.1 might not be identical to keratin, but be a different molecule contained in the cytoplasm, possibly related to the cytoskeleton.

Our immunization schedule was primarily designed to produce some monoclonal antibodies recognizing surface antigens specific to the early stage of T-cell differentiation. However, 169.1, examined in the present study, was not able to label lymphocytes, but reacted with non-lymphoid cells in FCM analysis. Most intensely labeled cells were monocytes, and this finding was confirmed by the fact that they were completely eliminated after cell-culture-dish treatment. In the immunohistochemical analysis, on the other hand, it mainly reacted with epithelial cells and nerve fibers. A similar finding has been presented by Laster et al., who reported that monoclonal antibody 3–40, raised against T lymphoblastic leukemia-associated surface antigen, was also able to identify vimentin and keratin in normal cells[8].

One of the most interesting aspects of stainability with 169.1 was the selective staining of sheathed arteries in the spleen. The sheath is generally believed to consist of a closely knit network of fibers and cells. The latter cellular components are mainly reticular cells, some of them being invading macrophages[1]. Although the selective staining of sheath-reticular cells with 169.1 can not be explained well, this monoclonal antibody is useful for studying distribution of the sheathed arteries and their developmental changes. Additional intense immunoreactivity with 169.1 was

found in the intercalated portion of the parotid gland, in contrast to anti-keratin antibodies showing broad positive staining of the ductal system, including the striated portion and intercalated portion[15]. The selective and intense staining of the intercalated portion with 169.1 also showed its utility for histochemical identification of the functionally unknown portion.

Heterogeneous immunoreactivity of neurons with the monoclonal antibody was recognized in the present study. No immunoreactive neurons were found in the central nervous system. In the peripheral nervous system, non-myelinated nerve fibers showed intense reactivity, while the stainability of myelinated fibers was complicated; thin fibers were positively stained, but thick fibers of large caliber had weak or negative reactions. This staining result is in contrast to that for neurofilament protein, which is richly localized in myelinated fibers but poorly so in non-myelinated fibers[3]. The heterogeneous staining with 169.1 in myelinated fibers was recognized in both afferent and efferent fibers. The dorsal radix and hypoglossal nerve, consisting of comparatively thin fibers, were positively stained, while the ventral radix and optic nerve composed of thick myelinated fibers were negative. It is well known that the dorsal root ganglion contains large cell bodies with myelinated fibers and small cell bodies with non-myelinated fibers[13]. The selective staining of the latter ganglion cells with 169.1 coincides with the stainability mentioned above. Such selective staining of the nervous system may be useful for tracing nerve fibers, and may also provide some information about the functional significance of the antigen. Immunostaining of neurons in developing stages and various culture conditions may give us important information on the antigen.

In conclusion, the immunohistochemical results suggest that the protein recognized by 169.1, a monoclonal antibody immunized with canine leukocytes, serves as a cytoskeletal component in a restricted number of cells. At the present time, we consider the following to be possible: (1) antibody 169.1 is raised against cytoskeletal components associated with the cell membrane of non-lymphoid leukocytes, and (2) it recognizes an epitope common to a cytoskeletal protein and a surface antigen on non-lymphoid leukocytes. However, more detailed chemical analyses of the protein are needed to reveal its functional significance.

References

1) Blue, J. & Weiss, L.: Electron microscopy of the red pulp of the dog spleen including vascular arrangements, periarterial macrophage sheaths (ellipsoids), and the contractile innervated reticular meshwork. *Am. J. Anat.* **161**: 189–218, 1981.
2) Cobbold, S. & Metcalfe, S.: Monoclonal antibodies that define canine homologues of human CD antigens: summary of the first International Canine Leukocyte Antigen Workshop (CLAW). *Tissue Antigens* **43**: 137–154, 1994.
3) Iwanaga, T., Takahashi, Y. & Fujita, T.: Immunohistochemistry of neuron-specific and glia-specific proteins. *Arch. Histol. Cytol.* **52** Suppl.: 13–24, 1989.

4) IVANYI, D., ANSINK, A., GROENEVELD, E., HAGEMAN, P. C., MOOI, W. J. & HEINTZ, A. P. : New monoclonal antibodies recognizing epidermal differentiation-associated keratins in formalin-fixed, paraffin-embedded tissue. Keratin 10 expression in carcinoma of the vulva. *J. Pathol.* **159** : 7–12, 1989.

5) KÖHLER, G. & MILSTEIN, C. : Continuous culture of fused cells secreting antibody of predefined specificity. *Nature* **256** : 495–497, 1975.

6) KYDD, J., ANTCZAK, D. F., ALLEN, W. R., BARBIS, D., BUTCHER, G., DAVIS, W., DUFFUS, W. P. H., EDINGTON, N., GRÜNIG, G., HOLMES, M. A., LUNN, D. P., MCCULLOCH, J., O'BRIEN, A., PERRYMAN, L. E., TAVERNOR, A., WILLIAMSON, S. & ZHANG, C. : Report of the first international workshop on equine leucocyte antigens, Cambridge, UK, July 1991. *Vet. Immunol. Immunopathol.* **42** : 3–60, 1994.

7) LAEMMLI, U. K. : Cleavage of structural proteins during the assembly of the head of bacteriophage T4. *Nature* **227** : 680–685, 1970.

8) LASTER, A. J., PALKER, T. J., HARDEN, E. A., HO, W., NAITO, K., DUPONT, B. & HAYNES, B. F. : Antibody against T lymphoblastic leukemia-associated antigen (3–40) identifies vimentin and keratin intermediate filaments in normal cells. *Blood* **66** : 642–648, 1985.

9) LAZARIDES. E. : Intermediate filaments : a chemically heterogeneous, developmentally regulated class of proteins. *Annu. Rev. Biochem.* **51** : 219–250, 1982.

10) NAESSENS, J. & HOWARD, C. J. : Leukocyte antigens of cattle and sheep. Monoclonal antibodies submitted to the second workshop. *Vet. Immunol. Immunopathol.* **39** : 5–10, 1993.

11) NAGLE, R. B. : A review of intermediate filament biology and their use in pathologic diagnosis. *Mol. Biol. Rep.* **19** : 3–21, 1994.

12) RAMAEKERS, F., HUYSMANS, A., SCHAART, G., MOESKER, O. & VOOIJS, P. : Tissue distribution of keratin 7 as monitored by a monoclonal antibody. *Exp. Cell Res.* **170** : 235–249, 1987.

13) RANSON, S. W. : The structure of the spinal ganglia and of the spinal nerves. *J. Comp. Neurol.* **22** : 159–169. 1912.

14) SAALMÜLLER, A., AASTED, B., CANALS, A., DOMINGUEZ, J., GOLDMAN, T., LUNNEY, J. K., MAURER, S., PESCOVITZ, M. D., POSPISIL, R., SALMON, H., TLASKALOVA, H., VALPOTIC, I., VIZCAINO, J. S., WEILAND, E. & ZUCKERMANN, F. : Summary of workshop findings for porcine T-lymphocyte antigens. *Vet. Immunol. Immunopathol.* **43** : 219–228, 1994.

15) VOS, J. H., VAN DEN INGH, T. S. G. A. M., DE NEIJS, M., VAN MIL, F. N., IVANYI, D. & RAMAEKERS, F. C. S. : Immunohistochemistry with keratin and smooth muscle actin monoclonal antibodies in canine digestive tract and extramural glands. *Zentralbl. Veterinarmed. [A]* **39** : 241–257, 1992a.

16) VOS, J. H., VAN DEN INGH, T. S. G. A. M., DE NEIJS, M., VAN MIL, F. N., IVANYI, D. & RAMAEKERS, F. C. S. : Immunohistochemistry with keratin monoclonal antibodies in canine tissues : urogenital tract, respiratory tract, (neuro-) endocrine tissues, chorioid plexus and spinal cord. *Zentralbl. Veterinarmed. [A]* **39** : 721–740, 1992b.