



HOKKAIDO UNIVERSITY

| | |
|------------------|---|
| Title | VETERINARY CLINIC AND IMAGING DIAGNOSIS |
| Author(s) | HIROSE, Tsuneo |
| Citation | Japanese Journal of Veterinary Research, 44(4), 220-223 |
| Issue Date | 1997-02-28 |
| Doc URL | https://hdl.handle.net/2115/2580 |
| Type | departmental bulletin paper |
| File Information | KJ00002398281.pdf |



VETERINARY CLINIC AND IMAGING DIAGNOSIS

Tsuneo HIROSE

*Department of Veterinary Clinical Radiology,
Obihiro University of Agriculture and Veterinary Medicine,
Obihiro, Hokkaido 080, JAPAN*

Fifteen years ago the word "imaging diagnosis" appeared in the field of veterinary clinic. This form of diagnosis has advanced very rapidly and thus at present information about imaging diagnosis often becomes invalid less than a year after publication.

Imaging diagnosis are expected to be widely applied in the field of veterinary clinic as an indispensable tool and to be developed and improved further. Thus, it is necessary to have proper knowledge from among the various imaging diagnosis necessary methods from among the various imaging diagnosis and determining the order of application of the methods.

The main purpose of imaging diagnosis in the field of veterinary clinic, especially clinics for large animals, is to observe morphologically abnormal foci of organs and tissues deep in the bodies of livestock.

I. Large Animals

For coelom X-ray fluoroscopy of the dairy cattle a stationary X-ray fluoroscopy was installed our university in 1971 to study morphology and kinetic functions of the digestive tract.

For 10 years after that time about 1,000 dairy cows were examined as to their body cavity, by which it was noted that the major diseases detectable were mainly terminal lesions in the thoracic or abdominal cavity, because animal had to be carried into the laboratory as such apparatus was of the stationary type. Thus, for the purpose of disclosing latent lesions in the early stage of development to prevent onset of diseases, a vehicle-loaded X-ray fluoroscope was developed in 1981. As the result of performing group health examinations (mass-screening) for about 11,000 dairy cows upon visits of dairy farms in more than 20 districts using this apparatus for 13 years, pathological abnormalities in regions of the cervix, chest and abdominal cavity were found at a rate of about 3.7%. Lesions involved injury of the reticulum by metallic foreign substances, pyogenic disease, various intrathoracic changes including tumors, peritonitis, and spinal disorders.

In 1994 having the above-mentioned X-ray car as a model, an overall diagnostic imaging car equipped additionally with the ultrasonic diagnosis unit and phono and electrocardiographic unit as well as the X-ray camera for radiographic film examinations, was developed. An X-ray film can be developed on the spot, and imputed in the apparatus for processing on the car, which makes diagnostic imaging feasible.

Accordingly by good use of these apparatuses, it is feasible to perform the overall diagnostic imaging any where, and by displaying the highly technical diagnosis it plays an important role in the stable dairy farm management.

Individual apparatuses for X-ray diagnosis are explained as follows :

1. Stationary Apparatus for Diagnosis of Large Animals(1971–1980)

Purpose ; morphological and functional studies of organs in the thoracic and abdominal cavities of large animals by fluoroscopy (Fig.1).

Number of animals examined : 1,200

2. Vehicle-loaded fluoroscope for diagnosis of large animals (1981–1994)

Purpose : Group examinations in the field for early diagnosis of latent lesions (Fig.2).

Number of animals examined : 10,978

3. Vehicle-loaded photofluoroscopic apparatus for large animals (1994-present)

Purpose : Mass-screening in the for early diagnosis of latent lesions (Fig.3).

Number of animals examined : 741

II. Small Animals

Almost all veterinarians for small animals in Japan have the X-ray apparatus as an indispensable measure. Recently according to the request of the much higher diagnostic technology, X-ray apparatus are being used increasingly. Thus, the authors developed an omnidirectional X-ray protective photofluoroscopic apparatus for small animals, with which it is feasible to reduce exposure doses in the routine clinical work and perform detailed X-ray examinations based on the protection from exposure. This is an equipment not only employing the measure for partial protection of the body with various protective devices including conventional protective clothing, but also having the X-ray tube, radiographic table, and photofluoroscopic mechanism in solid construction, fixing the X-ray generator and radiographic table into an omnidirectional protective chest, which has been planned to protect veterinarians and their coworkers from exposure. By automatic setting of the mechanism in this apparatus, clear X-ray photofluoroscopic images can be obtained easily under appropriate conditions, by which it is expected as the result to reduce exposure to X-ray on the patient by the shortened time of fluoroscope and the reduced number of films.

1. Omnidirectionally protected X-ray photofluoroscopy for small animal (1989-present)

Purpose : Observations of multidirectional photofluoroscopic images of small animals in view of protection from X-ray exposure (Fig.4).

Number of animals examined : 2,651

REFERENCES

- 1) ALBRIGHT, J. L., BRIGGS, J. L. and JESSUP, R. (1962). Long-term effects of magnets and management in the control of traumatic gastritis (hardware disease) in large commercial dairy herds. *Journal of dairy science*. 547–549.
- 2) CARROL, R. E. (1955). Magnets in the control of traumatic gastritis. *J. Am. Vet.*

Med. Assoc. 127, 311-312.

- 3) CARROL, R. E. (1956). The use of magnets in the control of traumatic gastritis of cattle. *J. Am. Vet. Med. Assoc.* 129, 376-378.
- 4) COOPER, H. K. (1956). A proposed procedure for controlling traumatic gastritis. *J. Am. Vet. Med. Assoc.* 125, 301-303.
- 5) DUNN, H. O., ROBERTS, S. J., MCENTEE, K. and WAGNER, W. C. (1964). Prevention of traumatic gastritis in bulls by use of magnets. *Cornell Vet.* 55, 204-209.
- 6) YAMADA, H. (1982). Clinical and pathological studies on the etiological factors of bovine abomasal displacement and atony. I. Clinical cases. *Jpn. J. Vet. Sci.* 44, 39-50.
- 7) YAMADA, H. (1982). Clinical and pathological studies on the etiological factors of bovine abomasal displacement and atony. II. Experimental cases. *Jpn. J. Vet. Sci.* 44, 51-62.

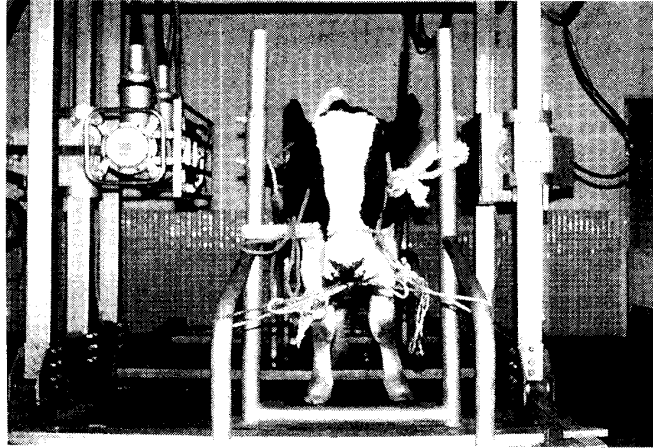


Fig. 1



Fig. 2




Fig. 3




Fig. 4