



HOKKAIDO UNIVERSITY

Title	ON THE PERPETUATION OF THE THIRD AORTIC ARCH IN HYNوبيUS RETARDATUS FOLLOWING THE LARVAL SYSTEMIC ARCH EXTIRPATION (With 9 Text-figures)
Author(s)	ICHIKAWA, Atsuhiko
Citation	北海道帝國大學理學部紀要, 1(4), 167-179
Issue Date	1932-04
Doc URL	https://hdl.handle.net/2115/26942
Type	departmental bulletin paper
File Information	1(4)_P167-179.pdf



ON THE PERPETUATION OF THE THIRD AORTIC
ARCH IN *HYNOBIUS RETARDATUS* FOLLOWING THE LARVAL SYSTEMIC
ARCH EXTIRPATION^{1), 2)}

BY

Atsubiko ICHIKAWA

(With 9 Text-figures)

Introduction

In the previous paper³⁾ the author engaged in a study on the metamorphosis of the salamander (*Hynobius retardatus* DUNN) after the fourth aortic (pulmonary) arch extirpation. Except the mandibular and hyoidean aortic arches, all the others of the original series found in the tetrapodous Vertebrates persisted in the larval stage of the salamander above mentioned. Whereas in *Necturus*, a representative of the Perennibranchiates, only three arches have persisted. Each of the aortic arches supplies a pair of external gills which persist throughout life. Assuming that the aortic arches in *Necturus* corresponded to arches I, II, and III, the fourth (pulmonary) having disappeared⁴⁾, the author had laid stress on whether *Hynobius* larvae in which the aortic arches conformed to the condition found in *Necturus* after the fourth aortic arch extirpation, had passed through metamorphosis successfully or not. And he had come to the conclusion that there was no significance in the metamorphosing processes in *Hynobius retardatus* larvae

-
- 1) Contribution No. 26 from the Zoological Institute, Faculty of Science, Hokkaido Imperial University.
 - 2) In the numbering of the aortic arches, the mandibular and hyoidean aortic arches which disappear during development are not taken into consideration, therefore the larval systemic and the third are primarily the fourth and fifth arches respectively.
 - 3) Journ. Fac. Sci., Ser. VI, Vol. I, No. 3, 1931.
 - 4) See FIGGE, F. H., Journ. Exp. Zool., Vol. 56, No. 2, 1930 and SCHUMWAY, W. and others, Anat. Rec., Vol. 47, No. 3, 1930 (abstract).

after the removal of the fourth aortic arch, since the operated animals underwent metamorphosis successfully. In the course of that investigation attention was called to a phenomenon—that the third aortic arch of the operated animal had developed and persisted as vigorous as the systemic arch in the control, in which the third had become a persisting vestige or had disappeared. Although in the previous paper he did not touch on the fact any further, yet it furnished a stimulus in the carrying-out of this research. The questions thus arose were: (1) Is it possible to remove the second aortic arch and make the animal lose the systemic arch after metamorphosis? (2) If the above is established what is the fate of the third aortic arch? (3) Does the persistent third aortic arch take over the function of the systemic arch carrying the blood from the heart into the root of the dorsal aorta?

In all adult Tetrapods except the Urodela, the third aortic arch (namely the fifth in the original scheme) is always small even in the embryo and is lost in the adult. Even in the hynobiid salamanders it is a persisting vestige in the adult or disappears, only appearing as a transient arch up to the metamorphosing stage. In *Hynobius retardatus* used in this experiment, the third aortic arch is usually reduced to a minute vessel or sometimes has already disappeared in about two months after metamorphosis. In the stage just after metamorphosis the fourth (pulmonary) arch has developed vigorously, the preceding three arches have lost their vessels supplying the external gills and thus four branches of the ventral aorta arising from the truncus arteriosus on each side, take on almost a uniform appearance in general. But soon after, the third arch is found to be in a very reduced state having almost vanished.

The experiment herein reported was undertaken in the hope of throwing some light on the causal analysis of the atrophying phenomenon of the third aortic arch in the hynobiid salamander. Before proceeding any further, the author wishes to express his sincere thanks to Professors K. OGUMA and T. UCHIDA for their interest in this experiment.

Material and Technique

The larvae of *Hynobius retardatus* used in the experiment were from the stock of our aquarium in which they were hatched from eggs. Being crowded into the limited aquarium the ravenous larvae fed on each other very often and thus only a limited number of the larvae came through safely. These were however exceptionally large in size being 50-60 mm in length by the end of June. Such larvae with fully grown external gills were found of the most satisfactory. During the actual process of the operation no anaesthetic was used. The operation was performed on a paraffin block under a binocular microscope field of which was illuminated with a strong electric lamp. Care was taken that the animal might be kept moist throughout the operation with a damp bandage exposing only its head region. A small longitudinal incision was made in the cutaneous fold on either side, growing back from the hyoid arch. Turning up the cutaneous fold along the longitudinal incision the branchial arches were exposed and then the second ceratobranchials of both sides were pulled out one after another by means of a fine straight forceps. The ceratobranchial so removed was invariably accompanied with the second aortic arti which was torn off. The removal of the second ceratobranchial was essentially important to avoid the completion of any anastomosis between the two cut ends of the arch. For the first twenty-four hours after the operation the animals were placed in a large glass vessel in which the water was bubbled with oxygen gas. After that time each individual was transferred to a separate bowl of similar size, and was reared upon earthworms. In the present experiment the mortality ascribed to the direct shock of the operation was quite low. Except a single case found dead soon after the operation, all operated animals were safe from the effect of it, and on the following day they again began to feed. It seemed to the author that the single case of death was due in all probabilities to the fact that the vein of the operated part had been broken and caused too much bleeding during the process of the operation. A considerable bleeding after removing the above named arch itself had no significance

in the present experiment. Among twenty four cases surviving, three (respective number is 12, 15 and 24) were found dead on the 22nd, 16th and 21st day of July respectively during the later part of metamorphic stage, namely the gills were atrophied to pigmented rods and the general appearance was of a terrestrial form. These were autopsied and it was found that no regeneration had taken place in the removed aortic arch in all cases.

All the operations were performed on June 27th to 30th of 1931 and the experimental animals on which results of this paper were based were reared for a period ranging from sixty to two hundred and ten days after the operation. For examining the operated part they were anaesthetized in 0.05 per cent aqueous solution of chloretone and the vivisection was made under the binocular microscope. In this way, the vessels in the operated part could be clearly shown on account of the blood circulation. After the vivisection they were fixed in 10 per cent formalin and once more examined by autopsy. The controls reared along the experimentals were taken from the same stock of the animals of our aquarium and therefore were of similar age with the experimentals.

Results

Among the experimentals which were included in the results, young salamander No. 3 of 55 mm in length was at first vivisected at sixty days after the operation. At the same time one of controls was killed for comparison. As all of the experimentals had passed through metamorphosis successfully during July, the above mentioned experimental as well as control animals had attained a typical terrestrial form. In the control the first and second aortic arches had become the carotid and the systemic arch respectively, whereas the third had showed a rapid atrophy and remained vestigial. The fourth arch had developed strongly and was continued as the pulmonary artery. In the vascular arches of the experimental animal two remarkable points should be noticed: 1) The second aortic arch which otherwise would have developed up to this stage into the vigorous systemic arch, had disappeared. 2) The third aortic arch, on the contrary, had developed and had become of

TABLE 1

Showing the fate of the removed second aortic arch in
Hynobius retardatus larvae. L, left side of the
arch ; R, right side of the arch

A

Conditions	Cases	Total
Cases in which the proximal remnant of the removed systemic arch is a small vessel arising from the truncus arteriosus and eventually tapering off*	No. 1 (L) No. 1 (R) No. 2 (L) No. 2 (R) No. 3 (L) No. 4 (L) No. 4 (R) No. 5 (L) No. 5 (R) No. 6 (L) No. 6 (R) No. 7 (L) No. 7 (R) No. 8 (L) No. 8 (R) No. 10 (L) No. 10 (R) No. 11 (L) No. 11 (R) No. 13 (L) No. 13 (R) No. 14 (L) No. 14 (R) No. 16 (L) No. 16 (R) No. 17 (L) No. 17 (R) No. 18 (L) No. 18 (R) No. 19 (L) No. 19 (R) No. 20 (L) No. 20 (R) No. 21 (L) No. 21 (R) No. 22 (L) No. 22 (R) No. 23 (L) No. 23 (R)	39
Cases in which the proximal remnant of the systemic arch is a vessel of considerable size opening into the root of the external carotid	No. 3 (R)	1
Anastomosis between the proximal remnant of the removed systemic arch and a branch of the external carotid	No. 9 (L) No. 9 (R)	2

* A pair of small vessels from the truncus arteriosus are found to pass forwards and eventually taper off. These are the proximal remnants of the extirpated systemic arch. In many cases these vessels appear to be stiffer and whitish in colour without circulation, but in a few instances some blood cells are found in the root of the vessel when the heart contracts.

B

Conditions	Cases	Total
Cases with no distal remnant of the removed systemic arch	No. 1 (L) No. 2 (R) No. 3 (L)** No. 5 (L) No. 6 (L) No. 9 (L) No. 10 (L) No. 10 (R) No. 11 (L) No. 13 (R) No. 14 (L) No. 14 (R) No. 16 (L) No. 16 (R) No. 18 (L) No. 18 (R)** No. 20 (L) No. 21 (L) No. 21 (R) No. 22 (L) No. 22 (R)** No. 23 (L) No. 23 (R)	23
Anastomosis between the distal remnant of the removed systemic arch and the distal part of the third arch	No. 5 (R) No. 6 (R) No. 8 (L) No. 20 (R)	4
Anastomosis between the distal remnant of the removed systemic arch and the internal carotid	No. 1 (R) No. 3 (R) No. 4 (L) No. 4 (R) No. 7 (L) No. 7 (R) No. 8 (R) No. 11 (R) No. 13 (L) No. 17 (R) No. 19 (L) No. 19 (R)	12
Anastomosis between the distal remnant of systemic arch and the carotid gland	No. 2 (L) No. 9 (R) No. 17 (L)	3

** In these cases the distal remnant of the systemic arch is found to be a minute vessel with no circulation, adhering to the wall of the internal carotid artery.

similar size as the systemic arch would be in normal condition. Namely it should be considered that when the second aortic arch was removed in the larval stage of *Hynobius retardatus* with the corresponding ceratobranchial, the systemic arch had not developed up to the time when the animal was killed, with no likelihood of its regeneration or collateral anastomosis between the two cut ends. Whereas on the other hand the absence of the above mentioned aortic arch induced the fur-

ther development of the third which otherwise would have almost disappeared.

The fate of the removed second aortic arch in all experimental cases is given in Table I. And as the results of the present experiment are found to be essentially uniform, only a few will be reported in detail as illustrative.

Description of cases

No. 23 (Figs. 1 and 2). The animal was reared for ninety-three days and reached a length of 57 mm. At the vivisection it was anaesthetized in 0.05% aqueous solution of chloretone. The aortic arches of the left side are shown in Fig. 1. In this specimen the

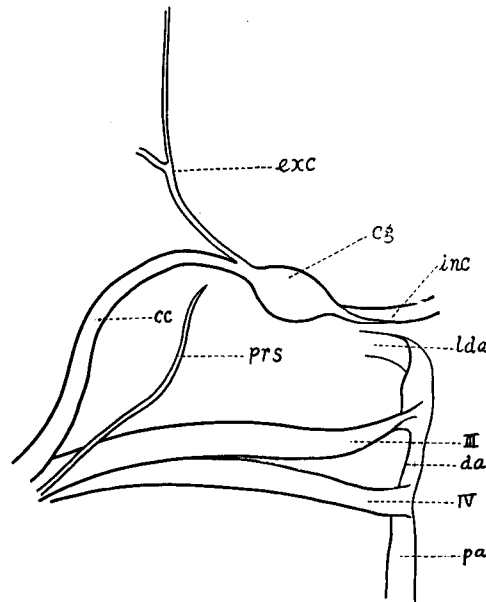


Fig. 1. Diagrammatic ventral view of the aortic arches in the experimental animal No. 23. Only the left side is shown. cc, common carotid; cg, carotid gland; da, ductus arteriosus; exc, external carotid; inc, internal carotid; lda, lateral dorsal aorta; pa, pulmonary artery; prs, proximal remnant of systemic arch; III, persistent third aortic arch; IV, fourth (pulmonary) aortic arch.

right side showed a fair coincidence with the left. The proximal remnant of the removed second aortic arch was a small vessel which passed forwards and eventually tapered off. When vivisection was made the vessel appeared to be stiffer and whitish in colour without circulation. Except a pair of such minute vessels arising from the truncus arteriosus, no trace of the arch could be found in the distal part. Photographs of this experimental case and its control animal are shown in Fig. 2, in which no significant difference can be pointed out.

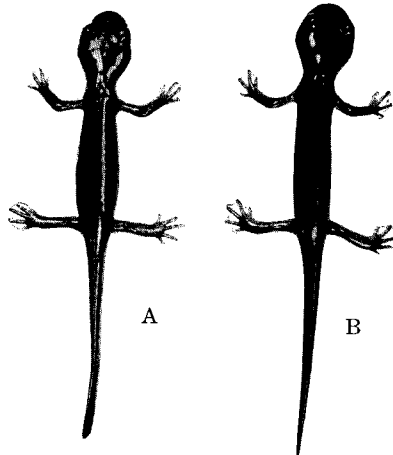


Fig. 2. Photograph of the experimental (A) and control (B) animals; natural size. (Experimental animal No. 23; ninety-three days after operation; 57 mm.)

No. 20 (Fig. 3). This animal was killed one hundred and six days after the operation. The total length was 58 mm. The aortic arches of the right side are shown in Fig. 3. The distal remnant of the removed systemic arch of this side joined into the distal portion of the following persistent third aortic arch of the same side, whereas the left remnant disappeared. The proximal remnant was found to be of the same condition, which was a functionless vessel stiffer and whitish in colour on either side.

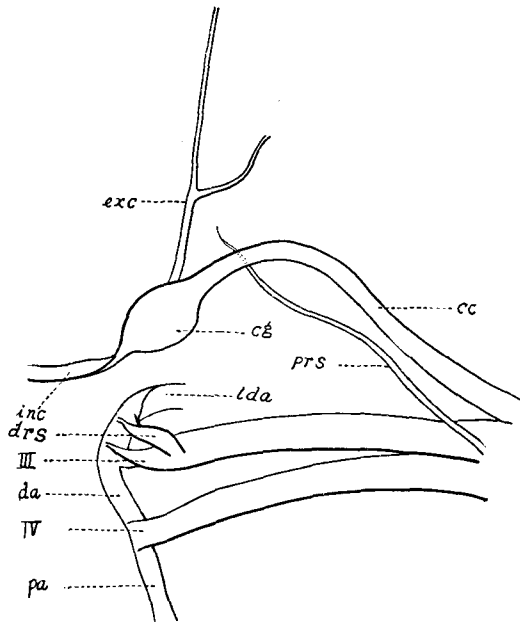


Fig. 3. Diagrammatic ventral view of the aortic arches of No. 20 experimental animal; the right side. *drs*, distal remnant of systemic arch. For other lettering of this and the following figures see Fig. 1.

No. 2 (Fig. 4). This animal was reared for one hundred and seven days and when vivisected it measured 60 mm. Fig. 4 shows the ventral view of the aortic arches of the left side. The carotid gland had received the distal remnant of the removed arch, thus a direct connection between the carotid arch and the lateral dorsal aorta had taken place and persisted. The blood of the common carotid in part went into the lateral dorsal aorta through this anastomosis. The proximal remnant was a minute vessel as described in above cases.

No. 17 (Fig. 5). This animal was reared for ninety-three days and when vivisected it measured 60 mm. Fig. 5 shows the aortic arches of the right side seen from the ventral side. The distal remnant was a rather small vessel which opened into the root of the internal carotid artery and received the blood from the latter.

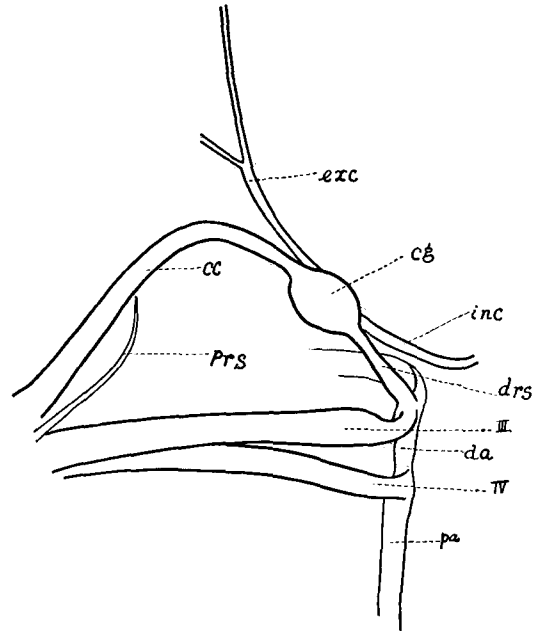


Fig. 4. Diagrammatic ventral view of the aortic arches of No. 2 experimental animal; the left side.

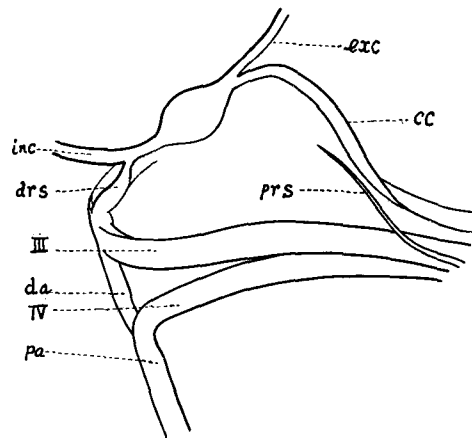


Fig. 5. Diagrammatic ventral view of the aortic arches of No. 17 experimental animal; the right side.

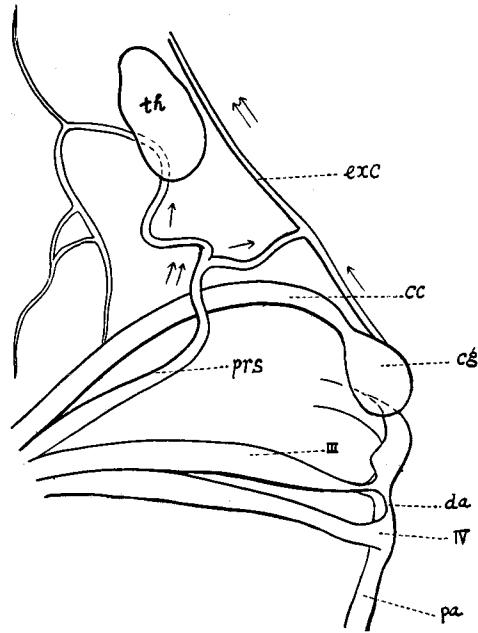


Fig. 6. Diagrammatic ventral view of the aortic arches of No. 9 experimental animal; the left side. th, thyroid gland. For other lettering refer to above explanation.

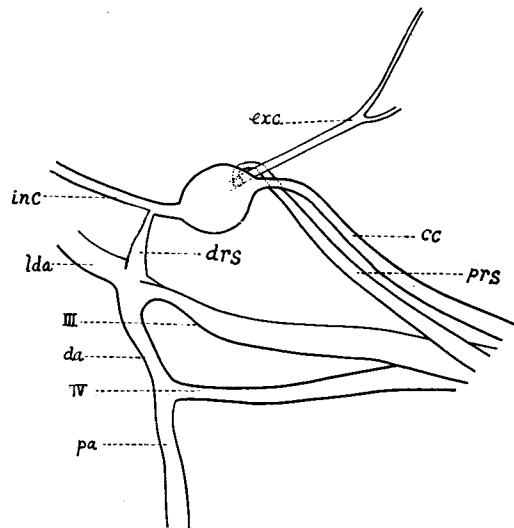


Fig. 7. Diagrammatic ventral view of the aortic arches of No. 3 experimental animal; the right side.

No. 9 (Fig. 6). This animal was vivisected at ninety-six days after the operation. The total length was 62 mm. This case showed a peculiar case of anastomosis between the proximal remnant of the systemic arch and a branch of the external carotid and so far as this anastomosis was concerned the right and the left side were found to be similar. The proximal remnant of the removed systemic arch now appeared to be quite a considerable vessel passing forwards across the common carotid and branching, and thus supplying the surrounding branchial muscles. This vessel joined a branch from the external carotid and thus assumed, as well as the common carotid, the task of carrying the forward stream of the external carotid.

No. 3 (Fig. 7). The description of this case was already above mentioned. In addition to the above description the illustration of the aortic arches of the right side is given in Fig. 7. The proximal remnant of the systemic arch was a vessel of considerable size running parallel to the common carotid and opened into the root of the external




Fig. 8. Photograph of the experimental (A) and control (B) animals; $\times 1\frac{1}{4}$. (Experimental animal No. 19; two hundred and ten days after operation.)

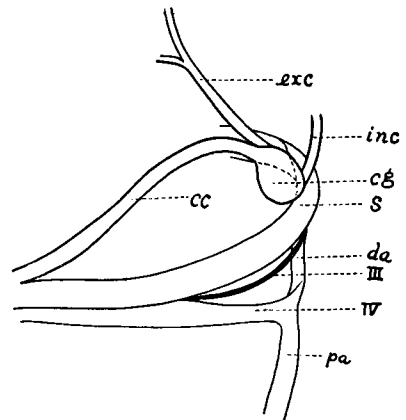


Fig. 9. Diagrammatic ventral view of the aortic arches of the control accompanied with No. 19; two hundred and ten days after operation. Only the left side is shown. s, systemic arch. For other lettering refer to above explanation.

carotid, whereas on the opposite side it showed as a minute vessel without circulation.

No. 19. This animal was vivisected at two hundred and ten days after the operation and reached a length of 54 mm. Both sides of the proximal remnant of the systemic arch were minute vessels without circulation. The third aortic arch had developed vigorously and been perpetuated as a definite aortic arch. Photographs of No. 19 and a control of similar age, but slightly larger are shown in Fig. 8. Fig. 9 shows a diagram of the aortic arches of the left side of the latter.

Summary

1. The second aortic (larval systemic) arch of *Hynobius retardatus* larvae with fully grown external gills was removed by means of a fine forceps. In order to prevent any regeneration or collateral anastomosis between two cut ends of the arch, extirpation of the corresponding ceratobranchials was found to be successful.

2. Except one which was found dead in the following day of the operation, twenty-four operated animals were safe from the effect of it. Among twenty-four animals surviving, only three died during the course of metamorphosis. All the other animals passed through metamorphosis successfully. Deducing from this fact it is evident that operated larvae have experienced no significant difficulty in metamorphosing.

3. The operated animals which were included in the results of this experiment were reared at least for sixty days when they invariably appeared to be normal in every respect so far as could be determined from their external characters.

4. In the aortic arches of the experimentals, the systemic arch, as such, has not developed. On the contrary, the third aortic arch has developed and been perpetuated as a definite arch substituting the extirpated larval systemic arch.

5. The fate of the extirpated larval systemic arch in all experimental cases is given in Table I.
