HOKKAIDO UNIVERSITY

Title	THE STRUCTURE OF THE TRUNCUS ARTERIOSUS IN FOUR SPECIES OF JAPANESE ANURANS (With Twelve Text Figures)
Author(s)	PEELLE, Miles L.
Citation	北海道帝國大學理學部紀要, 1(4), 181-190
Issue Date	1932-04
Doc URL	https://hdl.handle.net/2115/26943
Type	departmental bulletin paper
File Information	1(4)_P181-190.pdf

Hokkaido University Collection of Scholarly and Academic Papers : HUSCAP

THE STRUCTURE OF THE TRUNCUS ARTERIOSUS IN FOUR SPECIES OF JAPANESE ANURANS[1]

BY

Miles L. PEELLE.

(*With Twelve Text Figures*)

Investigation of the literature concerning the *Truncus arteriosus* of *Bufonidae* and *Hylidae* resulted in only a few references to that structure. BOAS ('82) has made note of *Pipa* but has no reference to *Bufo* proper. KATHELEEN OLIVER ('10) has detailed notes concerning two species of *Bufonidae*, *Notaden benetti* and *Pseudophryne semimarmorta* and one species of *Hyla*, *Hyla aurea*, which are found in Australia. Recently BHADURI ('30) gives a general description in one Indian *Bufo*. Due to lack of detailed work in these groups and to the apparent differences recorded by OLIVER. I have devoted considerable time and effort to determine what the structure is like in the more common forms found in Japan. It was surmised that new data would be found and this hope was not unfounded as will be pointed out in the following paragraphs. Acknowledgment of thanks is due to Dr. KAN OGUMA under whose direction this work was carried out.

Material and Methods

The following species were examined: *Bufo vulgaris*, *Bufo sachalinensis*, *Hyla arborea* and *Rhacophorus schlegelii schlegelii*. These species together with *Rana nigromaculata* and *Rana temporaria* reported in my former paper,[2] complete the list of the

---

1) Contribution No. 27 from the Zoological Institute, Faculty of Science, Hokkaido Imperial University, Sapporo.

2) Further Studies on the Truncus arteriosus of Rana—Jour. Fac. Sc. Series VI, Vol. 1, No. 2.

tailless Amphibia that I have investigated here in Japan. In general they represent the more common species and will thereby be taken as typical for the country.

The method of study in this investigation was carried out along similar lines to that employed in the investigation of American *Rana*. Dissection and serial sectioning were the principal means employed. In the case of *Bufo vulgaris* in which the structure of the truncus is larger than in any other Anuran form, except that of *Rana catesbiana* the method was to examine under low power of a good dissection microscope and to work with only fresh material. Other than this species, all the material used was taken from the preserved stock of the Institute. For fixation BOUIN's fluid was most suitable. Bulk staining gave good results and was very practical. For *Bufo vulgaris* India Ink injection in the living state gave a distended heart to some extent and was thereby helpful. Gum arabic for distension as used in my former studies was omitted.

The Internal Structure of the Truncus arteriosus

BRONN ('97) has given the number of valves of the posterior and anterior region of the truncus of *Bufo* and *Rana* as three. OLIVER ('10) reports for Australian *Bufo* only two. Consequently it was my intention to check these numbers in the Japanese *Bufo* to see if any variation occurred from what is probably normal, namely three. As I have already pointed out (1931) the number of valves in *Rana nigromaculata* is three. I have found that in *Bufo* this number is always the same as in *Rana*. In addition however there is a decided modification in the origin of the carotid arteries which will be described in detail further on.

Bufo sachalinensis. As was to be expected the valves were of normal shape and number. This at once threw some doubt on OLIVER's observations. Unless her species were decidedly primitive as they perhaps might well be, coming from Australia, it is difficult to reconcile her observations to what is found in Japanese *Bufo*. It

must be remembered that her work was made by longitudinal sectioning and perhaps such a method did not show up all the small and minute valves. However the fact that she reported only two valves from the anterior region brings up the question of primitiveness quite decidedly, since normally the third valve is always heavy and well developed.

As a whole when the *Truncus arteriosus* of *Bufo sachalinensis* is studied in comparison with that structure in *Rana*, there is very little difference to be found. The differences in part are as follows: The spiral valve, *Septum bulbi* is free in the lumen of the truncus and without a developed crest of tissue for a very short distance. Consequently it has beside it in the aortic cavity the three posterior valves. In *Rana* the spiral valve passes through a considerable portion of the truncial length free and without the three posterior valves beside it.

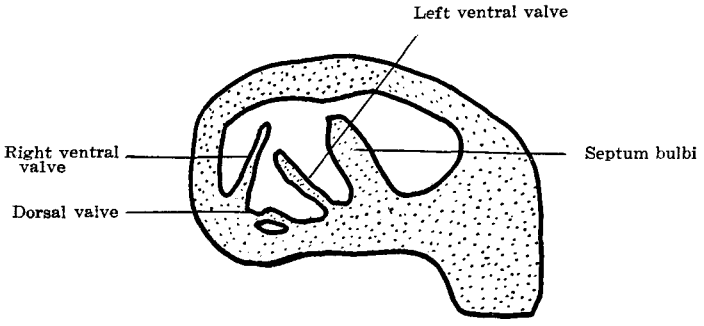

Fig. 1. Cross section through the posterior region of the *Bulbus cordis* of *Bufo sachalinensis* showing the existence of the three posterior valves beside the uncrested *Septum bulbi*.
ca. ×10.

From this condition we can draw the conclusion that in *Bufo sachalinensis* the spiral valve is shorter than in *Rana* since the posterior valves are approximately the same size in each family.

The *Septum bulbi* in *Rana* is usually broadened along its fusion basis with the dorsal wall of the truncus. In *Bufo sachalinensis* the structure is in most cases not so broad. With *Rana catesbiana* the

Septum bulbi is distinctly crested and was so in that species of *Rana* only. Likewise in *Bufo sachalinensis* we find such a situation but instead of being only slightly crested it is greatly so, in fact to such an extent that this crest is the most outstanding feature of the truncus. The crest in this species appears suddenly in a series and is quite easy to see. Toward the anterior cordis valves this crest goes over to the left will near *Valve 3* and fuses there at that point.

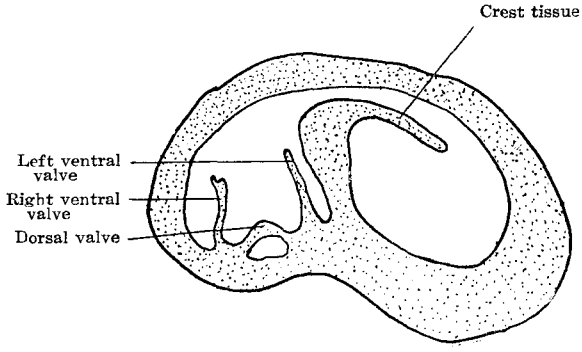

Fig. 2. Cross section through posterior region of the *Bulbus cordis* of *Bufo sachalinensis* showing sudden appearance of the crested tissue of the *Septum bulbi*. Crest present while posterior valves still strong. ca. ×12.

The *Septum bulbi* in *Bufo sachalinensis* has always been observed with this decided flange to its ventral edge. The development is of such an extent as said before, that one might take it to be a species variation since it was so pronounced and was not found in *Bufo vulgaris*. The dorsal fusion ridge of the *Septum bulbi* in this species is narrower than in the typical condition seen in *Rana sphenocephala*.

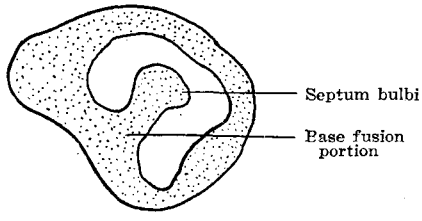

Fig. 3. *Rana sphenocephala*, typical *Rana* form of the central portion of the *Bulbus cordis* showing the width of the *Septum bulbi*. ca. ×12.

Bufo vulgaris. The *Truncus arteriosus* other than in the origin of the carotids, which will be discussed further on, approaches

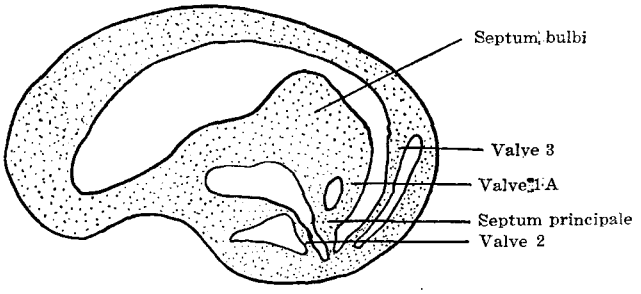

Fig. 4. Cross section through the anterior valves of *Bufo sachalinensis* showing normal arrangement. ca. ×12.

the condition found in *Bufo sachalinensis*. Both posterior and anterior valves are normal. The *Septum bulbi* is slightly different in that the crest tissue is not developed. However the structure is again similar to the above described species in that it is shorter than *Rana*.

Other variations in the truncus appear in one or two instances. There were several series of *Bufo vulgaris* in which there was a slight modification in the way the *Septum bulbi* arose. In *Rana* one found it beginning first on the ventral wall of the cordis and rapidly swinging in an arc to the dorsal floor, in fact so rapidly was this change in location in the earlier portion of its course through the truncus that one had difficulty in ascertaining its exact direction. In *Bufo vulgaris* there is nothing like this in general plan. Instead we find the *Septum bulbi* apparently arising from both ventral and dorsal walls, being fused to both for a short distance. Thus in this way there is a blind pocket formed. This shows in cross section (fig. 5).

Hyla arborea. In this species complete serial sectioning simulates what is met with in *Rana sphenocephala*. In all individuals studied both posterior and anterior valves were the same as in *Rana*. No variation in the nature of the *Septum bulbi* occured. Likewise the origin of the carotids was the same as in *Rana*.

Rhacophorous schlegelii schlegelii. The internal nature of the *Truncus arteriosus* is the same as in *Rana*. However the external

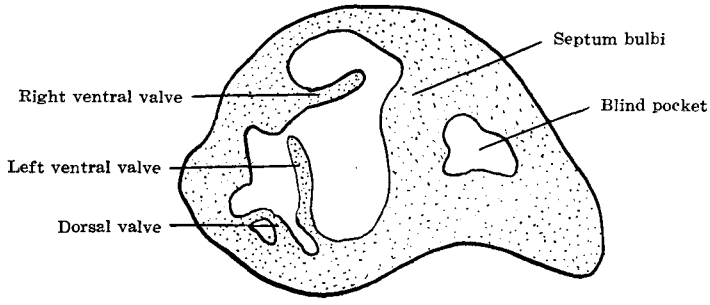

Fig. 5. Cross section through the posterior region of the *Bulbus cordis* of *Bufo vulgaris* showing the *Septum bulbi* fused to the ventral wall of the *Bulbus cordis* and the blind pocket thereby formed.

morphology is quite interesting and a little different. This difference lies in the nature of the angle of the truncial arms. It will be recalled that in the physiology of the blood separation, the acuteness of the bend of the right arm in the right direction helps bring about a more complete blood separation. In *Rhacophorus* we find this right arm bent even more to the right than in *Rana*. In a few cases this angle was not so great. However the sketch fig. 6 shows a more general form met with in this species. As can be seen from this figure the angle between the two arms, angle A–B is much greater than in *Rana*. (see previous paper 1931) Whether this affects the process of blood separation to any greater extent than in *Rana* is questionable. In theory it only helps to make the aortic and carotid blood assume the proper direction and not flow into the right arm before the pressure is low enough.

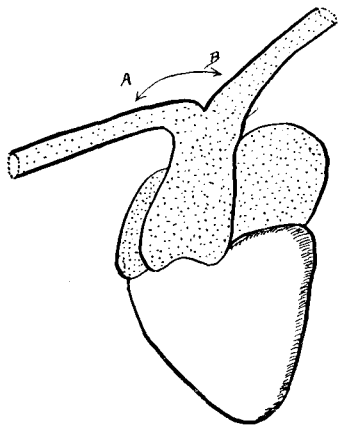

Fig. 6. External morphology of the heart and *Truncus arteriosus* of *Rhacophorous schlegelii*.

The Origin of the Carotids in *Bufo*

In *Bufo* the development of the *Canalis caroticus dexter*, or the right carotid arch is quite different in origin from what it is in *Rana*. Instead of each carotid artery having a separate origin (see previous paper-1931) in the right aortic arch, we find that in *Bufo* there is only one opening into this arch from the aortic trunk. This condition holds true in both *Bufo vulgaris* and *Bufo sachalinensis* for the marjority of cases investigated. However in two out of nineteen individuals of *Bufo* I found a condition exactly alike to *Rana* and in one case almost the same. The latter case gave rise to the right and left corotids almost at the same level, so that the openings of these two canals were found side by side in the right aortic arch. Hence we cannot conclude that this family is entirely different from *Rana* in relation to the carotid origin. Just why there should be variability in all cases except these three individuals is difficult and at present impossible to account for. In many specimens I have investigated of *Rana* and *Hyla*, I have never met with this type of fluctuation within the same species. As has already been pointed out, *Hyla* and *Rhacophorus* are constant in this respect and do not vary from the *Rana* form.

Those individuals in *Bufo vulgaris* that showed similarity to *Rana* in respect to the carotid origin were serial sectioned in a like manner to all the remaining ones studied. So there is nothing questionable in respect to the method of study. In such cases the situation can clearly be seen in the sketches, Figs. 7–8. From this can clearly be seen how the *Septum aortico carotideum dexter* developes in the right aortic arch. This we may recall is the normal way of development in *Rana* and *Hyla* and likewise in *Rhacophorus*. However in a ratio of about nine to one the situation in *Bufo* differs in exactly the opposite fashion from *Rana*. Thus if one sections through the same level in the majority of cases, the development in a serial series is as shown in Figures 9 to 12. Since I have found this variation and method of origin so frequently and have only met

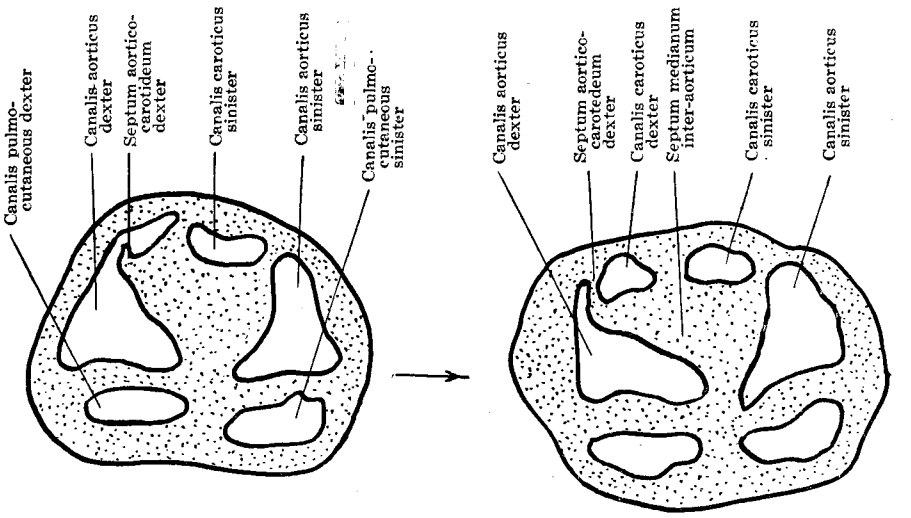

7 8

Fig. 7–8. Consective cross sections through the area of carotid origin in one case of *Bufo vulgaris* where the *Canalis caroticus dexter* originates from the *Canalis aorticus dexter*.

with the other type in three individuals, I have come to the conclusion that it is a difference of major importance so far as morphology is concerned.

The septum that comes into the common carotid duct in its early development and divides it into the right and left carotid branches, thus making it Y shaped, is not a different septum from what serves the same purpose in *Rana*. For *Rana* this septum was labeled by GAUPP ('96) in conjunction with the *Septum medianum aorticum* and he made no differentiation in terminology when that septum was extended into the carotid arch. Hence because of the different way in which the carotids arise in *Bufo* I have had to label the septum in *Rana*, "*Septum medianum inter-carotideum.*" Now in *Bufo* this last mentioned septum arises more to the anterior than in *Rana*. It consequently appears to arise in the undivided carotid tube, which in reality is the case. This means that the *Septum aortico-carotideum dexter* in *Bufo* arises before (that is before in a

serial series from posterior to anterior) the *Septum medianum inter-carotideum.*

This method of development of the right and left carotid arteries from a single canal that opens into the aortic arch was noted in *Rana* by POHLMAN ('14). However in investigating the common forms of American *Rana* and likewise Japanese *Rana* I have never met with such a situation as POHLMAN describes. Normally in *Bufo* we have exactly what he described for *Rana*. This development of the right carotid artery makes the situation similar to that found in

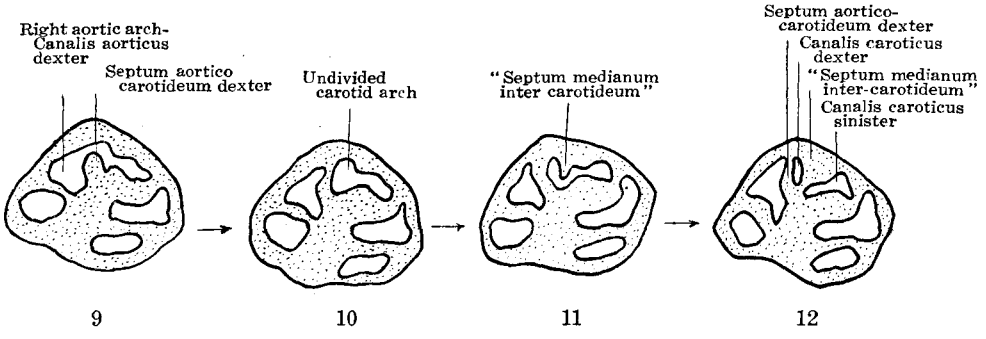

Figs. 9–12. Consective sections through area of carotid origin in normal condition of *Bufo vulgaris.*

reptiles. In my earlier paper (1931) I was not aware of this difference in *Bufo* or the possibility of it being plausible in *Rana* and I tried to point out that POHLMAN had not observed correctly. But there appears to be some possibility that he has found an individual that varied from the majority of cases. Likewise I tried to show that since the gap between Amphibians and Reptiles is quite distinct there would be no possibility of this conclusion being plausible. Now since I have found this condition as described above for *Bufo* I must revise my opinion even though it does contradict any expectation one might have in reference to homology and makes the question of relation between the two groups even more difficult to explain. It should be further noted that since this characteristic is common to both species of *Bufo* investigated, *Bufo sachalinensis*

from the north and *Bufo vulgaris* from Japan proper, it must be put down as a family variation differing distinctly from *Rana* and *Hyla*.

Postscript: In upper medium margin of Pl. IV (Contri. No. 10) change *Canalis aorticus dexter* to read *Canalis caroticus dexter;* likewise *Canalis aorticus sinister* to *Canalis caroticus sinister*.

REFERENCES CITED

BHADURI, J. 1930. Notes on the Arterial System of the common Indian Toad, Bufo melanostictus Schneid. Proc. Asiatic Soc. of Bengal NW. Series Vol. XXVI, 1930, No. 1.

BOAS, J.E.V. 1882. Ueber den Conus arteriosus und die Arterienbogen der Amphibien. Morph. Jahrb., Bd. VII.

GAUPP, E. 1896. Anatomie des Frosches. Braunschweig-Druck von Friedrich Vieweg und Sohn.

OLIVER KATHELEEN, K. 1910. The Structure of the Truncus arteriosus in species of Genera Hyla, Linnodynastes, Chiroleptes. Victoria Natural.

PEELLE, M. L. 1931. The Truncus arteriosus of American Frogs as contrasted to European species. Jour. Fac. Sc., Hok. Imp. Univ. Ser. VI, Vol. 1, No. 10. Sapporo, Japan.

Ibid. Further Studies on the Truncus arteriosus of Rana. Jour. Fac. Sc. Hok. Imp. Univ. Ser. VI, Vol. 1, No. 11.

POHLMAN, A. G. 1914. On the Phylogenesis of the Heart. Anat. Rec., Vol. 8.