



HOKKAIDO UNIVERSITY

Title	The effect of follicular hormone upon the sex differentiation in <i>Hynobius retardatus</i> (With 1 Textfigure and 2 Plates)
Author(s)	HANAOKA, Kin-itiro
Citation	北海道帝國大學理學部紀要, 7(4), 399-412
Issue Date	1941-03
Doc URL	https://hdl.handle.net/2115/27034
Type	departmental bulletin paper
File Information	7(4)_P399-412.pdf



The effect of follicular hormone upon the sex differentiation in *Hynobius retardatus*¹⁾

by

Kin-itiro Hanaoka

Zoological Institute, Faculty of Science, Hokkaido
Imperial University, Sapporo

(With 1 Textfigure and 2 Plates)

Introduction

Recent advance in the chemical preparation of sex hormones has provided more direct methods of attack on the problem of free-martin effect than have been hitherto available. In both birds and mammals an extensive series of experiments has been undertaken, concerning the influence of hormonal substances upon the sex differentiation.

In the amphibians an experiment of this type was first reported by Padoa (1936, 1938), who reared the tadpoles of *Rana esculenta* in the water solution of follicular hormone and found that the majority of the experimental animals were induced to differentiate into males. This report attracted the attention of some investigators and Witschi and Crown (1938) repeated similar experiment with *Rana pipiens*, but they failed to demonstrate the masculinizing effect of estrogens. Burns (1938, 1938) utilizing a more direct method of administration of hormone injected the crystalline estrone into the body cavity of young larvae of *Amblystoma punctatum*. He reported that the injection caused transformation of the testis of genetical male into ovary. The administration of the male hormone, on the other hand, "produced all degree of intersexuality in the developing ovary; the development of testis is not affected by a homotypic hormone." Puckett (1939, 1940) also made similar experiments of injection on *Rana catesbiana* but he concluded that "there is no suggestion of a stimulation of the gonads by the sex

1) Contribution No. 147 from the Zoological Institute, Faculty of Science, Hokkaido Imperial University, Sapporo.

hormone alone, but the injection of sex hormone in addition to a pituitary extract brings about striking modification in the gonads of both male and female." Recently Foote (1940) published a short report on the effect of sex hormones upon the sex differentiation of *A. punctatum* and *A. tigrinum*. He treated the animals with crystalline sex hormone added daily to aquarium water, but in *Amblystoma* testosterone had little influence on the differentiation and development of ovaries, while estrogens had a feminizing action upon the testis.

Thus the effects of sex hormones upon sex differentiation in amphibians are rather contradictorily reported and it seems important to study the comparative responses of various animals under the influence of various chemical preparations. The present report deals with the administration of follicular hormone upon the larvae of a Japanese salamander *Hynobius retardatus*. A part of the results of this experiment was preliminarily reported in 1939. The writer wishes to express his hearty thanks to Prof. Tohru Uchida, under whose guidance the work has been carried out.

Normal sex differentiation in H. retardatus and the follicular hormone employed

The early development of the reproductive organs in *H. retardatus* was described by the present writer in 1934. They belong to a semi-differentiated race in regard to sex differentiation and the testis assumes the structure of an ovary in early larval stages. The genetical males manifest themselves by the transformation of the ovaries into testes during the course of metamorphosis which occurs in laboratory condition about 3 months after fertilization. At the end of metamorphosis the sex ratio is about 50:50. In the second spring the gonads of either sex appear as thin threads hanging on the midventral surface of the mesonephros. The testis and the ovary cannot be distinguished macroscopically until the third spring, when the surface of the ovary becomes granulated by growing follicles. Fig. 1 illustrates a cross section of an ovary from a female of the third spring. In the fourth spring the ovaries increase conspicuously in size and become irregularly lobated organs. They contain various numbers of large pigmented eggs. In the male the spermatozoa mature also in the fourth spring.

The sex hormone used in the present experiment was pelanin (Tokyo Zōkiyaku-kenkyūsho). It is a preparation of crystalline oesterone containing 500 m. u. in every cubic centimeter.

Experiments

1. *Modification of sex in animals reared in the water solution of follicular hormone.* This part of the experiment was undertaken to examine whether the water solution of follicular hormone actually induces male sex differentiation in *H. retardatus* as Padoa (1936, 1938) reported on *R. esculenta*.

A lot of 20 animals were reared separately in the water solution of pelanin, which contains 5 m. u. of follicular hormone in every cubic centimeter. Later, as the animals grew, the concentration was raised to 8 m. u. per cubic centimeter. The solution was transparent for the first several days but gradually became opaque and viscous. It was filtered with filter paper every other day and was changed for a fresh one every fortnight. At the beginning of the experiment, the animals were about 21 mm in total length and the primordial gonad had just appeared. Two of them died within 10 days and were discarded and 18 were preserved at the end of the metamorphosis.

Among these 18 animals 11 had gonads of completely solid structure. Careful examination of these gonads, however, showed that, in some of them, the number of rete cells was extremely small and no differentiation of seminal tubules was observed. On the contrary, they contained an abnormally large number of germ cells compared with the normal testes of the same age. Fig. 2 represents a section of the typical structure of the gonads of this type. It is marked by the complete absence of rete cells and consists of a mere mass of germ cells covered with epithelium. This gonad was classified provisionally as testis because it had no cavity in the center, but in the normal testis at this stage, the rete cells migrate abundantly from mesonephros into the gonad and envelop the more proximal germ cells, forming the medulla, and therefore, the rete elements and gonidia are rather uniformly intermingled. In 4 animals among 18 the ovarian cavities are detected at several intervals of the sections, but they are extremely narrow and appear like slits between the thick cortical germ layers (Fig. 3). The gonads of

this type cannot be considered as ovaries merely because they have rudimentary cavities in the center; they show rather an intermediate form of male and female gonad. The gonad in Fig. 3 resembles very much the one in Fig. 2, which has been classified as testis. The difference between these two gonads seems not to be essential and moreover, there can be seen in both of them no proliferation of rete cells in the medulla which is characteristic of the normal differentiation of testis. In the remaining three animals, definitive cavities can be found in the center of the gonads, as illustrated in Fig. 4, but the cavities are small and about one-third or less of the normal in volume; sections of the gonad at other levels are similar to Fig. 2. The sex distribution of the 18 animals became, therefore, as follows:

$$11\sigma + 4\text{? (with vestigial ovarian cavities)} + 3\text{?} = 18$$

It is clear from the foregoing observation that the solution of female sex hormone interferes with the normal differentiation of cortex in the genetical females. It must be noticed, however, that no differentiation of the distinct testicular structure such as seminal tubules was ever observed. This calls for caution against the conclusion that the transformation of ovaries into testes actually occurs.

2. *Sex differentiation in animals injected with follicular hormone.* In the second series of experiments, the animals received injections of 5 m. u. of the follicular hormone at intervals of 5-7 days over a period of 1-5 months. At the beginning of the experiments they were at three different stages of development. In the first group they were 21 mm in total length and in the second group 35 mm. The gonads in the latter animals were in either sex in respect to the structure of ovaries with a distinct cavity in the center. In the last group the injections were begun a half month after metamorphosis. The sex differentiation in these animals was complete. At autopsy this experiment showed different results from those obtained in the preceding experiment (1); the gonads were diversely modified according to the ages of animals at the beginning as well as at the end of the experiments.

(A) In 120 animals the injection was begun at the stage of 21 mm in total length; sex differentiation in these animals was modified as described below.

a) *Before or during metamorphosis.* Thirty animals, 16 males and 14 females, were preserved before or during metamorphosis. In some of them the gonads were a little smaller than normal ones, but microscopical observation confirmed that both testis and ovary were similar in histological structure to those of normal animals of similar age. The testes were in early stages of rete cord formation and the ovaries had distinct ovarian cavities and a cortical germ layer well differentiated. It is evident that the hormone injection had not been able to modify differentiation of the testes or accelerate development of the ovaries.

b) *One or one and half month after metamorphosis.* In 34 animals, preserved one or one and half months after metamorphosis, the gonads were in different conditions. Twenty-three animals among them were provided with ovaries of normal structure, which, however, showed more advanced stages of development than those of normal females and contained many large germ cells with vesicular nuclei and dense protoplasmic substance (Fig. 5). In 11 animals which were supposed to be genetical males 8 had small but normally differentiated testes. In the gonads of the remaining 3, the rete cord was well differentiated and most of the germ cells were normal, but intermingling with the normal male germ cells of small size, one could find various numbers of abnormally large germ cells. These germ cells showed characteristics of oocytes in having large vesicular nuclei and dense protoplasmic substance and were always surrounded by typical follicular cells (Fig. 6). Thus the gonads on the whole had the appearance of a mosaic structure of male and female characteristics.

c) *Two or more months after metamorphosis.* In animals preserved two or more months after metamorphosis, the effect of the hormone injection was more conspicuous and the more the animals advanced in development the more pronounced influence was observed in the sex differentiation. The sex distribution in these animals was as follows:

2 months after metamorphosis	$2\sigma + 5\text{♀}$ (with mosaic gonads) + 12♀ = 19
3 months after metamorphosis	$3\sigma + 2\text{♀}$ (with mosaic gonads) + 7♀ = 12
4 months after metamorphosis	$7\sigma + 4\text{♀}$ (with mosaic gonads) + 14♀ = 25

However, since no essential difference of sex modification occurs among them, all will be included in one description.

In the female, differentiation of oocytes proceeded far ahead of normal ones, and at the end of 4 months after metamorphosis they have grown as large as those found in the females of 3 years old (Fig. 7). In most of these ovaries small but distinct ovarian cavities were observed, but sometimes the cavities were almost occluded by the enlarged oocytes and became nearly solid (Fig. 8). In the mosaic gonads the oocytes became larger in size and in number. Figs. 9, 10, show sections of a mosaic gonad of a male, 4 months old. In Fig. 9, a large oocyte is differentiated side by side with rudiments of the rete cord. In the other levels, however, the gonad shows perfectly normal male structure as may be seen in Fig. 10. It must be added here that in some mosaic gonads the cortical component of the rudimentary testis survived and hypertrophied in various degrees, causing more or less regression of medulla, (Figs. 11, 12, 14). These changes, however, are generally limited to only short stretches and no cavity has ever been formed in the center.

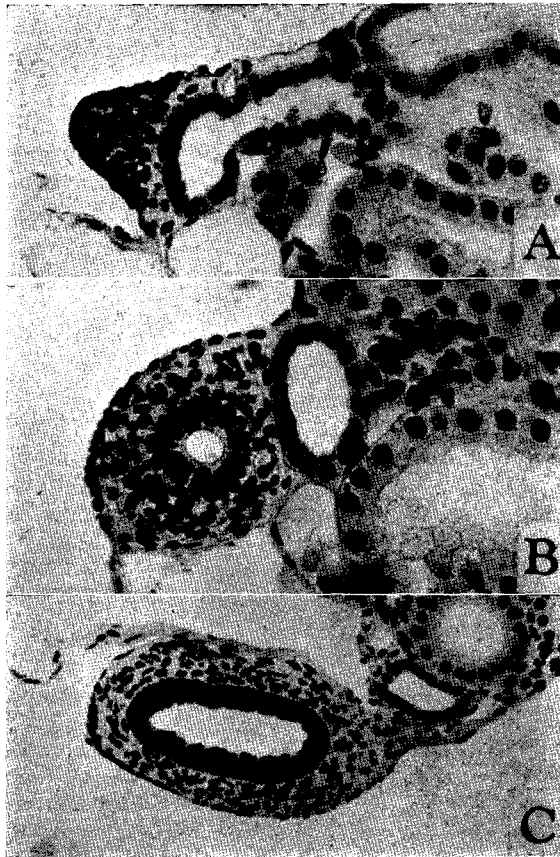
In another gonad of mosaic structure, the number of oocytes becomes greater every section containing several large cells. In extreme cases, with the increased number of oocytes, the section of the gonads appears like an ovary which becomes compact by the enlarged eggs as shown in Fig. 15. This gonad, however, shows distinct testicular structure in more anterior region.

d) *The influence upon the differentiation of mullerian duct.*

In the normal development of *H. retardatus* the rudiment of mullerian duct at the stage of metamorphosis is represented by a longitudinal thickening of the peritoneal epithelium which runs along the lateral border of each kidney (Textfig. 1, A). Later, some of the cuboidal cells of the epithelium migrate to the space between the wolffian duct and epithelial wall and make a solid cord. The duct persists in this condition in both sexes until the next spring. Sexual dimorphism of the mullerian duct occurs in the second year when lumen appears in the solid cord in the female, and in the third spring the entire tube increases in diameter and becomes surrounded by the sheath of connective tissue (Textfig. 1, C). In the male the duct remains permanently in the solid condition.

In animals injected with follicular hormone the lumen appeared in both sexes at the end of two months after metamorphosis. At

the end of four months, the lumen became pretty wide and a small amount of connective tissue appeared surrounding the tube. A



Textfig. 1. Differentiation of mullerian duct. A, section through the rudiment of mullerian duct in a normal male (2 months after metamorphosis). $\times 200$ B, section through the rudiment of mullerian duct of a male injected with follicular hormone. (2 months after metamorphosis). $\times 200$ C, section of a mullerian duct of a normal female, 3-years old. $\times 120$

comparison of Figs. A, B, C in Textfig. 1 shows the rate of acceleration of differentiation in the mullerian ducts in injected animals.

(B) In the second group the injection was begun at the stage of 35 mm in total length. At this stage the gonads were found to display the ovarian structure in both sexes. The dosage and the interval

Table 1

Distribution of sex in *H. retardatus* injected with pelanin.

At the beginning of the experiment	Autopsy performed	Distribution of sex	Total
21 mm in total length	Soon after metamorphosis	16♂ + 14♀	30
"	1 or 1½ months after metamorphosis	8♂ + 3♀ + 23♀	34
"	2 months after metamorphosis	2♂ + 5♀ + 12♀	19
"	3 months after metamorphosis	3♂ + 2♀ + 7♀	12
"	4 months after metamorphosis	7♂ + 4♀ + 14♀	25
Total		36♂ + 14♀ + 70♀	120
35 mm in total length	1 month after metamorphosis	3♂ + 8♀	11
"	2 months after metamorphosis	3♂ + 1♀ + 10♀	14
Total		6♂ + 1♀ + 18♀	25
2 weeks after metamorphosis	2 months after metamorphosis	6♂ + 4♀	10
"	3 months after metamorphosis	10♂ + 7♀	17
Total		16♂ + 11♀	27

of the injection were similar to the first group. Among 25 animals preserved one or two months after metamorphosis the following distribution of sex was found:

1 month after metamorphosis	3♂	+ 8♀ = 11
2 months after metamorphosis	3♂ + 1♀ (with mosaic gonads)	+ 10♀ = 14

Microscopical observation confirmed that in the female a similar acceleration of sex differentiation occurred to that in the

first group. The ovaries were provided with large oocytes and the mullerian duct had a distinct lumen in the center. In the male the differentiation of the mullerian ducts could not be distinguished from those of the females but the testis was quite normal except in one, which had mosaic gonads similar to those of the first group.

(C) In the third group the injection was began 2 weeks after metamorphosis. The sexes in these animals had distinctly differentiated. Autopsy was made of 10 animals two months and of 16 four months after metamorphosis. The distribution of sex was as follows:

2 months after metamorphosis	$6\sigma + 4\varphi = 10$
4 months after metamorphosis	$10\sigma + 7\varphi = 17$

The ovaries and the mullerian ducts showed again advanced stages of differentiation similar to those described in the preceding sections. In the male, however, little or no influence was observed in the sex differentiation except on development of the mullerian ducts. The testes were slightly smaller in size than normal ones, but their structure was quite normal for their age.

Table 1 contains the essential statistical data of the three experimental series.

Discussion

Padoa (1936, 1938) reported in his experiments on *R. esculenta* that the water solution of female sex hormone induced complete sex reversal in the genetical females. After him several investigators repeated the similar experiments on various forms of amphibians but none of them could observe masculinizing effects of estronogens. The present experiment confirmed that the water solution of follicular hormone inhibits more or less the development of the ovarian cavity in the female, though not to the extent of complete suppression. This cannot, however, be admitted as an initial step toward sex transformation. In the normal testis of *H. retardatus*, the ovarian cavity, which appears as the female phase in sexual semi-differentiation, becomes obliterated by active migration of rete cells from the mesonephros, which envelop the germ cells in more proximal region. But in animals treated with hormone solu-

tion, the ovarian cavity becomes closed, not by the proliferation of rete cells but by the abnormal thickening of the cortical germ layer. Consequently rete cells in the affected ovary are extremely few in number and no differentiation of distinct testicular structure such as seminal tubules is observed in the medulla.

It is well known that in other forms of vertebrates the female sex hormone cause female sex differentiation and in amphibians, also, the feminizing influence of follicular hormones has been repeatedly reported by Burns (1938), Gallien (1938) and others. The writer cannot find at the present time the proper explanation for the masculinizing effect of follicular hormone observed in *R. esculenta*. But Padoa proposed in his paper of 1938 two hypotheses as follows. (i) The gonads of tadpoles, and more particularly the medulla, transform follicular hormone into male hormone. (ii) Various animals, which are ambisexual in genetical constitution, respond diversely to the same substance according to the relative value of their male and female determining factors, and while the follicular hormone exerts feminizing effects on the sex differentiation of birds and mammals, the same substance might have masculinizing effect in amphibians. These hypotheses of Padoa, however, do not meet the fact that in the present experiment, the same substance produced different sex modifications according to the different methods of administration. If the follicular hormone exerts male determining influence in *H. retardatus*, or is actually transformed into male hormone, it must induce male differentiation in both cases irrespective to the methods of administration.

The result obtained in *H. retardatus* by the injection of follicular hormone was different also in some important points from Burns' with *A. punctatum*. Burns stated that the injection of esterone caused transformation of testes of genetic males into ovaries and that the process of sex reversal took the normal course of cavity formation in the medulla. The development of the ovaries, however, was not accelerated by the homotypic hormone. The development of gonads in *H. retardatus*, on the contrary, was not effected by the hormone injection before metamorphosis; neither modification of testicular differentiation nor the acceleration of ovarian development was detected. After metamorphosis, however, there took place marked precocious development of the ovaries; and the oocytes developed pronouncedly within a few months one or two years ahead

of the normal ones. In the males, on the other hand, female germ cells appeared in the testes, and the gonads assumed a mosaic structure of male and female characteristics. It may be said, therefore, that the differentiation of the larval gonad in *H. retardatus* proceeds independently of follicular hormone and the germ cells of both sexes become responsive to the follicular hormone only after metamorphosis. It is noteworthy that while the gonads before metamorphosis were not effected by the hormone injection, the appearance of the female cells in the genetically male gonads was especially conspicuous when the injection was made from the beginning of the experiment but when the treatment was begun after metamorphosis the influence became less marked.

The mechanism of oocyte formation in the genetical male gonads is of special interest. It is generally accepted in amphibians that the differentiation of female germ cells is induced by the cortical layer and the male germ cells by the medulla. In the gonads of *H. retardatus* injected with follicular hormone the medullary development proceeded, generally speaking, as in normal males. One may be inclined therefore to regard the differentiation of oocytes in the genetically male gonads as due to the direct action of the follicular hormone upon the germ cells. In other words it is independent of the medulla cortex relations. But if the differentiation of oocytes was a consequence of direct action of follicular hormone, the similar oocyte differentiation must also be observed in animals which received the injection only after metamorphosis. The present writer therefore conceives that the follicular hormone effects the germ cell differentiation through the action of cortical elements in the male gonads. It is generally observed that in the differentiation of medulla, "the sex cords carry not only the germ cells but also their follicular cells and adhering stroma cells into the medulla" (Witschi, 1936). These cells which originate from the cortical component might have retained for a certain period after metamorphosis the capacity to induce female germ cell differentiation, especially when the stimulation of follicular hormone was continued by repeated injections. And when the germ cells attained to the stages responsive to the cortical stimulation, they had been at once induced to differentiate into oocytes. Before metamorphosis the germ cells have no capacity in themselves to react to the cortical stimulation. If the injection had been begun after metamorphosis,

the medullary differentiation might have already proceeded beyond the control of the follicular hormone at least under the dosage employed in the present experiment and the cells originated from the cortical component might have lost their characteristics to induce oocyte differentiation.

As mentioned above, the injection of the follicular hormone interferes with the physiological differentiation of the medulla to induce male germ cell differentiation even after the structural male differentiation has set in. Consequently it seems to be logical to conclude that if a higher dose of follicular hormone were given, the balance of medulla-cortex antagonism would be reversed and the development of the medulla might be completely inhibited by favoring the development of cortex. This is perhaps the case of Burns with *A. punctatum*.

Summary

(1) The water solution of pelanin (follicular hormone), in which the larvae of *H. retardatus* were reared, interfered with the normal differentiation of ovaries in the genetical females but this was not followed by the actual differentiation of the medulla.

(2) The injection of pelanin, on the contrary, induced various modifications of sex differentiation according to the different ages of the animals at the autopsy.

a) Before metamorphosis neither modification of the testis differentiation nor acceleration of ovarian development was observed.

b) After metamorphosis some of the germ cells in the male gonads were modified to differentiate in the female direction and gonads of a mosaic structure of male and female characteristics were produced. In the female a pronounced acceleration of oocyte differentiation was observed within a few months.

(3) When the injection was begun after metamorphosis the influence of follicular hormone became less prominent.

(4) The differentiation of the mullerian ducts was accelerated in both male and female and exceeded the normal differentiation of the females of the second spring. The ducts had distinct lumens in the center and were covered with thick layer of stroma cells.

Literature

- BURNS, R. K. JR. 1938 The effect of crystalline sex hormones on the sex differentiation in *Amblystoma*. I. Esterone. *Anat. Rec.*, vol. 71, pp. 447-467.
- 1938 Hormonal control of sex differentiation. *The American Naturalist*, vol. 72, pp. 207-227.
- FOOTE, C. L. 1938 Influence of sex hormones on sex differentiation in amphibia (*Rana pipiens*). *Anat. Rec.*, vol. 72, Supplement, p. 120.
- 1940 Influence of sex hormones on development and differentiation of gonads in *Amblystoma*. *Anat. Rec.*, vol. 76, Supplement. No. 2, p. 88.
- GALLIEN, L. 1938 Action du benzoate de dilydrofolliculine dans la differentiation der sexe ches *Rana temporaria* L. *Compt. Rend. Acad. Sciences*, no. 4 pp. 282-284.
- HANAOKA, K. I. 1934 A semidifferentiated race in urodelans with regard to its gonadic development. *Jour. of Fac. Sci., Hokkaido Imp. Univ., Ser. 2. Zool.*, vol. 3, pp. 241-253.
- 1939 Influence of follicular hormone upon the sex differentiation in *H. retardatus*. *Proc. Imp. Acad. Tokyo*, vol. 15, pp. 265-268.
- PADOA, E. 1936 Effetto paradossale (mascolinizzazione) suela differenziazione sessuale di girini di *Rana esculenta* tratai con armone follicolare (Nota preventia). *Monitore Zoologico Italiano. Anno. XLVII, N. 10*, pp. 285-289.
- 1938 La differenziazione del Sesso invertita mediante la somministrazione di ormoni sessuali. *Ricerche con Follicolina in Rana esculenta. Archivio Italiano di Anatomia e di Embrologia*, vol. XL-Fosc. 7 pp. 122-172.
- PUCKETT, W. O. 1939 Some reactions of the gonads of *Rana catesbiana* tadpoles to injection of mammalian hormonal substance. *J. Exp. Zool.*, vol. 81, pp. 43-65.
- 1940 Some effect of crystalline sex hormone on the differentiation of the gonads of the differentiated race of *Rana catesbiana* tadpoles. *J. Exp. Zool.*, vol. 84, pp. 39-48.
- RODGERS, L. T. and P. L. RISLEY 1938 Sexual differentiation of reproductive ducts of *Amblystoma tigrinum*. *J. Morph.* vol. 63, pp. 119-142.
- WITSCHI, E. 1934 Sex deviations, inversions, and parabiosis. *Sex and Internal Secretion. Williams and Wilkins, Baltimore*, pp. 160-245.
- & E. N. CROWN 1938 Hormones and sex determination in fishes and frogs. *Anat. Rec.*, vol. 70. Supplement no. 1. p. 121.

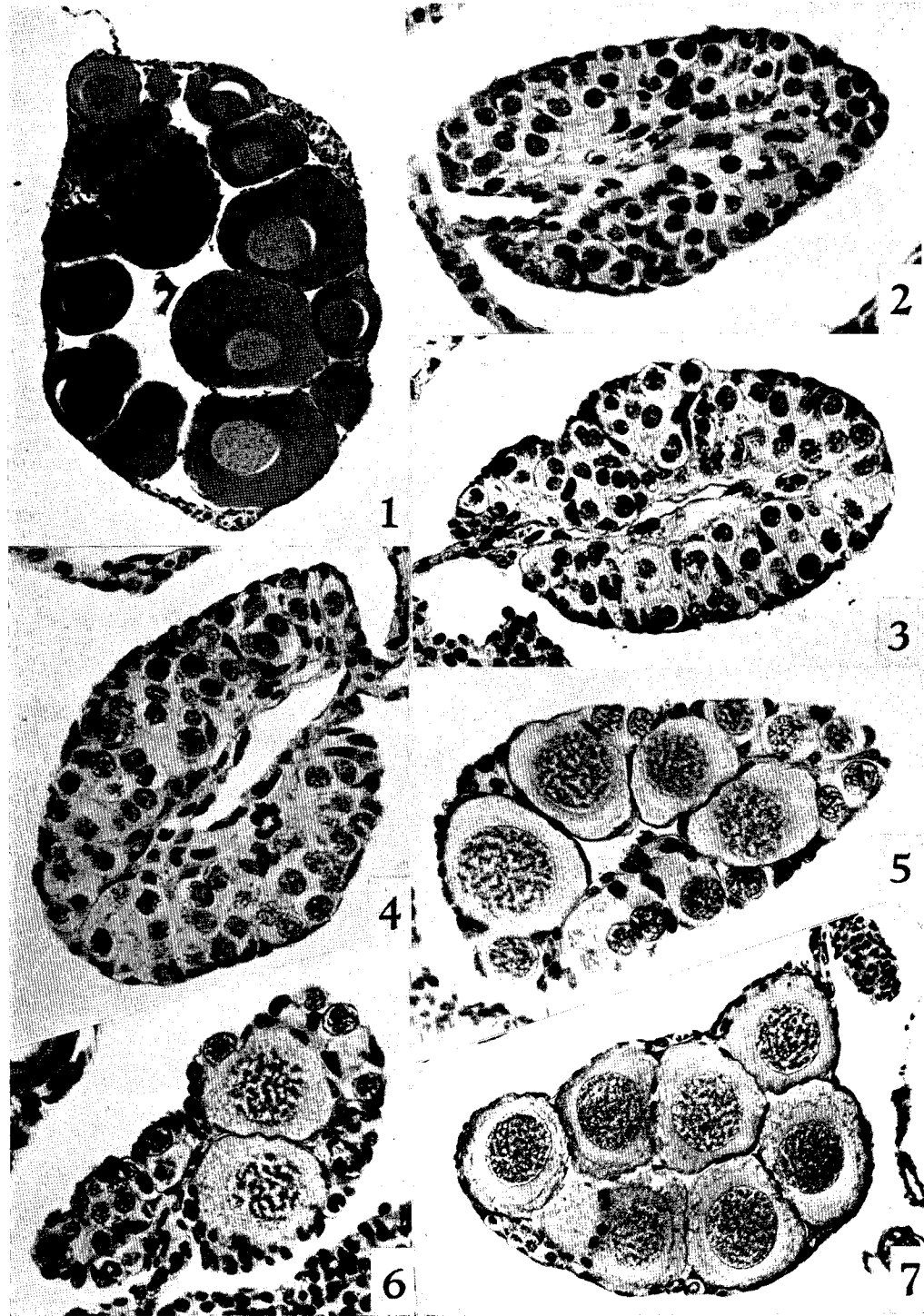
Explanation of Plate XXXI

1. Section through a normal ovary of 3-year-old female. $\times 50$.
- 2, 3, 4. Sections through the gonads of animals raised in the water solution of follicular hormone; 2. Gonad become solid by the thickening of the cortical germ layer, but no differentiation of rete apparatus observed.
3. Gonad with a slit-like rudiment of the ovarian cavity. 4. Gonad having a distinct ovarian cavity. $\times 250$.

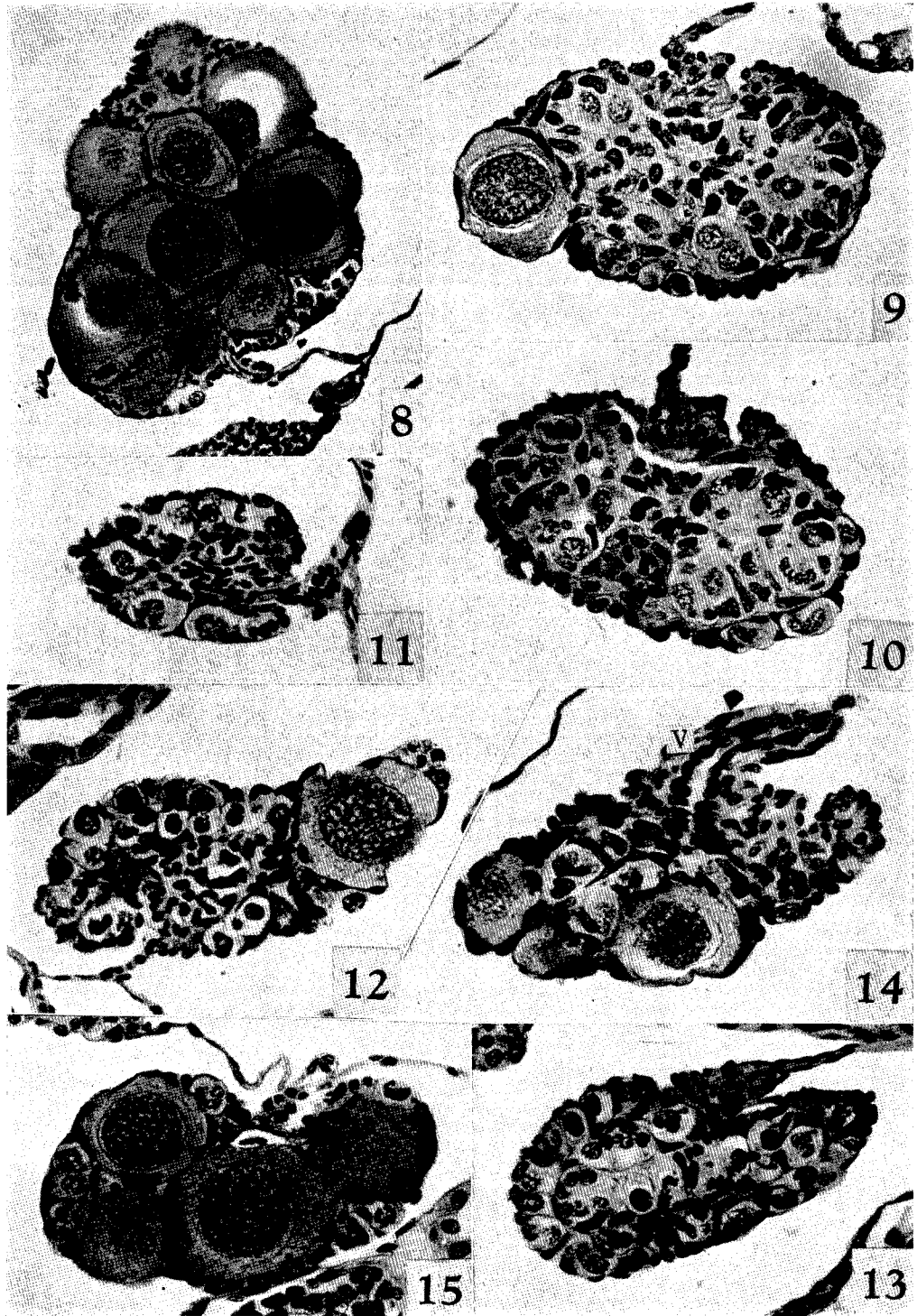
- 5, 6. Sections through gonads effected by the injection of follicular hormone (1½ months after metamorphosis). 5. Ovary showing accelerated differentiation of oocytes. 6. Testis of mosaic structure. ×250.
7. Section through an ovary affected by the injection of follicular hormone (2 months after metamorphosis), showing rapid growth of oocyte. Compare 7 with the normal ovary in 1. ×150.

Explanation of Plate XXXII

8. Section through an ovary effected by the injection with follicular hormone, the ovarian cavity having been completely occluded by enlarged oocytes. ×150.
- 9, 10. Sections through a mosaic gonad with relatively small number of oocytes, (2 months after metamorphosis). 9 shows a large oocyte lying side by side with the rudiments of rete apparatus, but another section of the same gonad shown in 10 is of the normal testicular structure. ×250.
- 11, 12, 13. Sections of a mosaic gonad. 11, 12 show predominant differentiation of the cortical germ layer, but 13 shows nearly normal testicular structure. ×250.
14. Section of mosaic gonad showing predominant cortical differentiation. V. rudiment of vasa efferentia. ×250.
15. Section of a mosaic gonad with increased number of oocytes. This figure resembles the ovary in 8, but no cavity was detected throughout the entire gonad. ×250.
-



K. I. Hanaoka, The Effect of Follicular Hormone



K. I. Hanaoka, The Effect of Follicular Hormone