



# HOKKAIDO UNIVERSITY

Title	The effect of testosterone-propionate upon the sex differentiation in <i>Hynobius retardatus</i> (With 2 Plates)
Author(s)	HANAOKA, Kin-itiro
Citation	北海道帝國大學理學部紀要, 7(4), 413-419
Issue Date	1941-03
Doc URL	<a href="https://hdl.handle.net/2115/27035">https://hdl.handle.net/2115/27035</a>
Type	departmental bulletin paper
File Information	7(4)_P413-419.pdf



# The effect of testosterone-propionate upon the sex differentiation in *Hynobius retardatus*<sup>1)</sup>

By

Kin-itiro Hanaoka

Zoological Institute, Faculty of Science, Hokkaido  
Imperial University, Sapporo

(With 2 Plates)

## I. Introduction

Regarding the influence of male hormone upon the sex differentiation in amphibians, several contradictory experimental results have been hitherto reported. Gallien (1937) reported that the injection of testosterone-propionate into tadpoles of an undifferentiated race of *Rana temporaria* caused transformation of developing ovaries into testes. Witschi and Crown (1938) reared newly hatched tadpoles of *R. pipiens* in a water solution of testosterone-propionate for four months and found only six survived males. Burns (1938, 1939) affirmed that repeated injections of small doses of the same substance into the larvae of *Amblystoma punctatum*, produced all degrees of intersexuality in the ovaries and evoked marked hypertrophy of wolffian ducts of both sexes. Puckett (1939, 1940), however, having repeated similar experiments with *R. catesbiana*, concluded that "there is no suggestion of a stimulation of gonads by the sex hormone alone", but "the injection of male sex hormone in addition to a pituitary extract produces marked changes in the ovaries of the female." Recently Foote (1940) published a short report on the influence of the sex hormone upon sexual differentiation of *A. maculatum* and *A. tigrinum*, reporting that in *Amblystoma* testosterone has little influence on differentiation and development of ovaries, but stimulates wolffian ducts and cloacal glands.

The present report deals with the effect of testosterone-

---

1) Contribution No. 148 from the Zoological Institute, Faculty of Science, Hokkaido Imperial University, Sapporo.

propionate upon the sex differentiation of *Hynobius retardatus*. The writer wishes to express his hearty thanks to Prof. Tohru Uchida for his helpful advice and encouragement during the progress of the experiment.

## II. Normal development of the reproductive system in *H. retardatus* and the method of experiment

The semidifferentiated characteristics of sex differentiation in *H. retardatus* was reported by the present writer in 1934. The male differentiation begins with the onset of metamorphosis at the age of about three months under laboratory conditions. The duct system, however, undergoes few changes in the two sexes at least until several months after metamorphosis; the mullerian ducts are represented by a row of high columnar cells of peritoneal epithelium along the lateral border of the kidneys and the wolffian ducts are developed, irrespective to sex. The rete apparatus in the male persists in loose cellular strands growing from mesonephros into testes. Fig. 11 exhibiting a section from the genital region of the kidney shows the average condition of genital ducts of control animals during several months after metamorphosis.

The experimental animals received injections of 0.01 cc of perandren (Ciba) which contains 5 mg. of testosterone-propionate in each 1 cc. Injections were executed at intervals of 10 days. At the beginning of the experiment, 58 animals of the first group were 21 mm in total length and the primordial gonads had just appeared. In 16 animals of the second group, the average length was 34 mm and the gonads assumed ovarian structure in both sexes. The first autopsy was made immediately after metamorphosis and the last one about three months thereafter. Since, however, no fundamental difference was observed among the groups of different ages, all will be described together.

## III. Results of administration of testosterone-propionate

The injection of testosterone-propionate produced striking modification of sex differentiation in either sex. In some animals all the gonads were so markedly changed in structure that it was difficult to distinguish male from female on usual grounds. The

exact percentage of sex distribution, therefore, could not be ascertained in the present experiment. The microscopical observation of the gonads and gonoducts was as follows.

(1) *Elimination of germ cells.* The present writer reported on the previous experiments with *H. retardatus*, in which testicular pieces were transplanted in addition to hypophyses, that some germ cells became eliminated from the gonads into the body cavity (Hanaoka, 1939). In the present experiment the similar elimination of germ cells occurred in either sex to a higher degree and the gonads were reduced to small vestigial organs. In general they were made up of an irregular mass of rete cells intermingled with a small number of germ cells and were found hanging to abnormally enlarged vasa efferentia. In extreme cases germ cells disappeared almost entirely and the gonad degenerated to a mere fold of peritoneal cells. Figs. 1, 2 and 3 show cross sections of the gonads of this type. The germ cells in Fig. 1 and Fig. 2 are just about to be eliminated from the gonads and in Fig. 3 only remnants of germ cell attachments are represented by the epithelial cells irregularly arranged.

(2) *Differentiation of vasa efferentia in relation to the development of the gonads.* The vasa efferentia are formed by the tubulation of rete cords, which grow from mesonephros into testis at the beginning of sex differentiation. In animals up to several months after metamorphosis, however, the rete cords retain the form of loose cellular strands and it is difficult to trace them within the confines of mesonephros. When injected with testosterone-propionate the differentiation of rete cords was accelerated precociously in both sexes by rapid proliferation of a large number of rete cells (Fig. 4). In general the tip of the growing rete cord does not connect with the medullary structure of the vestigial gonad. But in some animals a small number of germ cells were found strayed into the rete cells and the cross sections at the ends of rudimentary vasa efferentia gave the appearance of small testes (Fig. 5). On account of the more conspicuous proliferation of rete cells frequently occurring in the anterior region, the gonad becomes solid and assumes testicular structure in the anterior half, while in the posterior half, it shows the structure of a small ovary (Fig. 6).

In some other animals, the rete cord is tubular in structure with an enormously large lumen. In these instances the wall of the

tube became extremely thin and in some less completely modified cases the lumen of the duct is conveyed with the ovarian cavity (Fig. 7, 8). When the gonad had become extremely small and abnormal, a few germ cells were found scattering on the wall of tubular rete cord, or vas efferens. It is noteworthy that while vasa efferentia were accelerated in differentiation so markedly, the rete apparatus, which lies within the confines of the mesonephros, remained compact and the connection of gonads with wolffian ducts was always incomplete.

(3) *Precocious differentiation of oocytes two or more months after metamorphosis.* While many germ cells were eliminated in both sexes by the action of testosterone-propionate, some germ cells which survived in the gonads of presumably genetical females two or more months beyond metamorphosis were accelerated to differentiate into oocytes of considerable size. These oocytes resemble in size as well as in structure those found in the animals treated with female sex hormone (Hanaoka 1939). They are always of dense protoplasmic substance and have a large nucleus (Figs. 6, 10). The gonads containing such large oocytes are of completely ovarian structure; have in general distinct ovarian cavities. Though occasionally they are solid in structure, predominant development of cortical elements is seen.

(4) *The gonoducts.* As described in the foregoing section, the wolffian ducts, in normal animals up to several months after metamorphosis, are entirely under developed in both sexes (Fig. 11). In all injected animals, however, the wolffian ducts underwent great hypertrophy within a few months after metamorphosis. The region of greatest hypertrophy lay between the posterior end of the gonad and the cloaca. They were nearly equal in width to the entire kidney and were slightly convoluted, though the condition was not attained in all cases. Although hypertrophied, they were more slender in the region extending anterior to the kidney. Microscopical examination confirmed that the hypertrophy of the wolffian ducts is due mainly to the thickening of epithelial wall and the dilation of the tube. Less connective tissue surrounds the wolffian ducts and the constrictions which separate the ducts from the mesonephros was always incomplete. The rudiments of the mullerian ducts in normal animals at this stage are shown by the presence of stroma cells without any distinct lumen. In the injected animals the mullerian

ducts disappeared completely and no histological traces of ducts were found in either sex. Fig. 12 represents the cross section of the wolffian duct of an injected animal at the level of lumbar kidney. This figure is in extreme contrast to Fig. 11 which shows the average condition of gonoducts of the control animal a few months after metamorphosis.

The observations just described are markedly different from preceding investigators results mentioned at the beginning of this paper, except the fact that the wolffian ducts hypertrophied in a conspicuous condition in both sexes. In *H. retardatus* the injection of testosterone-propionate arrested the normal differentiation of both testis and ovary and produced irregular and vestigial organs in either sex. Neither reversal of ovarian development nor acceleration of testicular differentiation occurred, and the germ cells which survived in the ovaries two or more months after metamorphosis were stimulated to differentiate ahead of the normal rate of female germ cell differentiation.

It is of special interest to compare these results with those obtained by the present writer for *H. retardatus* which received transplantation of testicular pieces in addition to hypophyses. But the full discussion of these observations and of recent literature on sex deviation induced by the hormonal substances will be presented in a succeeding paper.

#### IV. Summary and conclusion

(1) Small doses of synthetic androgen, testosterone-propionate (perandren, Ciba) were injected repeatedly into larvae of *Hynobius retardatus*, a semidifferentiated race in regard to sex differentiation. At the beginning of the experiment, the primordial gonad had just appeared in one group of the larvae and in another the gonads assumed ovarian structure in both sexes. Autopsy was made one or three months after metamorphosis.

(2) The hormone produced striking modifications in the differentiation of gonads in either sex; in general the gonads were reduced to small vestigial organs by the elimination of a large number of germ cells.

(3) The rete apparatus was stimulated to precocious differentiation and in some animals large compact cords of rete cells

were caused to appear connecting the gonads and mesonephros. Frequently a small number of germ cells were enveloped in the developing rete cord, yielding the appearance of a small testis. In some other animals the cord acquired tubular structure with enormously large lumen. It must be noted, however, that the rete apparatus which lies within the confines of the mesonephros remained compact, and the connection between the gonads and wolffian ducts were always incomplete.

(4) While a large number of germ cells were eliminated from the primordial gonad by the action of testosterone-propionate, the differentiation of some germ cells, which survived in the ovary two or more months after metamorphosis, was accelerated far ahead of the normal rate of female germ cell differentiation. These germ cells resemble in size and in structure those found in the gonads treated with female sex hormone.

(5) The rudiments of the mullerian ducts completely disappeared in the experimental animals; the wolffian ducts on the contrary underwent marked hypertrophy in both sexes.

### Literature

- BURNS, R. K. JR. 1938 The effects of crystalline sex hormones on the differentiation of sex in *Amblystoma punctatum*. *Anat. Rec.*, vol. 70, p. 11.
- 1939 The effects of crystalline sex hormones on sex differentiation in *Amblystoma*. II. Testosterone propionate. *Anat. Rec.*, vol. 73, pp. 73-93.
- FOOTE, C. L. 1940 Influence of sex hormone on development and differentiation of gonads in *Amblystoma*. *Anat. Rec.*, vol. 76, Supplement no. 2, p. 88.
- GALLIEN, M. L. 1937 Action masculinisante de propionate de testosterone dans le differentiation du sexe chez *Rana temporaria*. *Académie de Sciences. Seance du Lundi 9 Aout. 1937*, pp. 375-377.
- HANAOKA, K. I. 1934 A semidifferentiated race of urodelans with regard to its gonadic development. *Jour. Fac. Sci. Hokkaido Imp. Univ. Ser. VI. Zoology*, vol. III, pp. 247-253.
- 1939 Modification of sex in a salamander, *Hynobius retardatus* induced by the implantation of testis and hypophyses *Japanese Jour. Zoology*, vol. V, pp. 255-264.
- 1939 Influence of follicular hormone upon the sex differentiation in *Hynobius retardatus*. *Proc. Imp. Acad. Tokyo*, vol. 15, pp. 265-268.
- PUCKETT, W. O. 1939 Some effects of crystalline sex hormone on the reproductive structure of several anurans. *Anat. Rec.*, vol. 75, Supplement no. 1, p. 127.

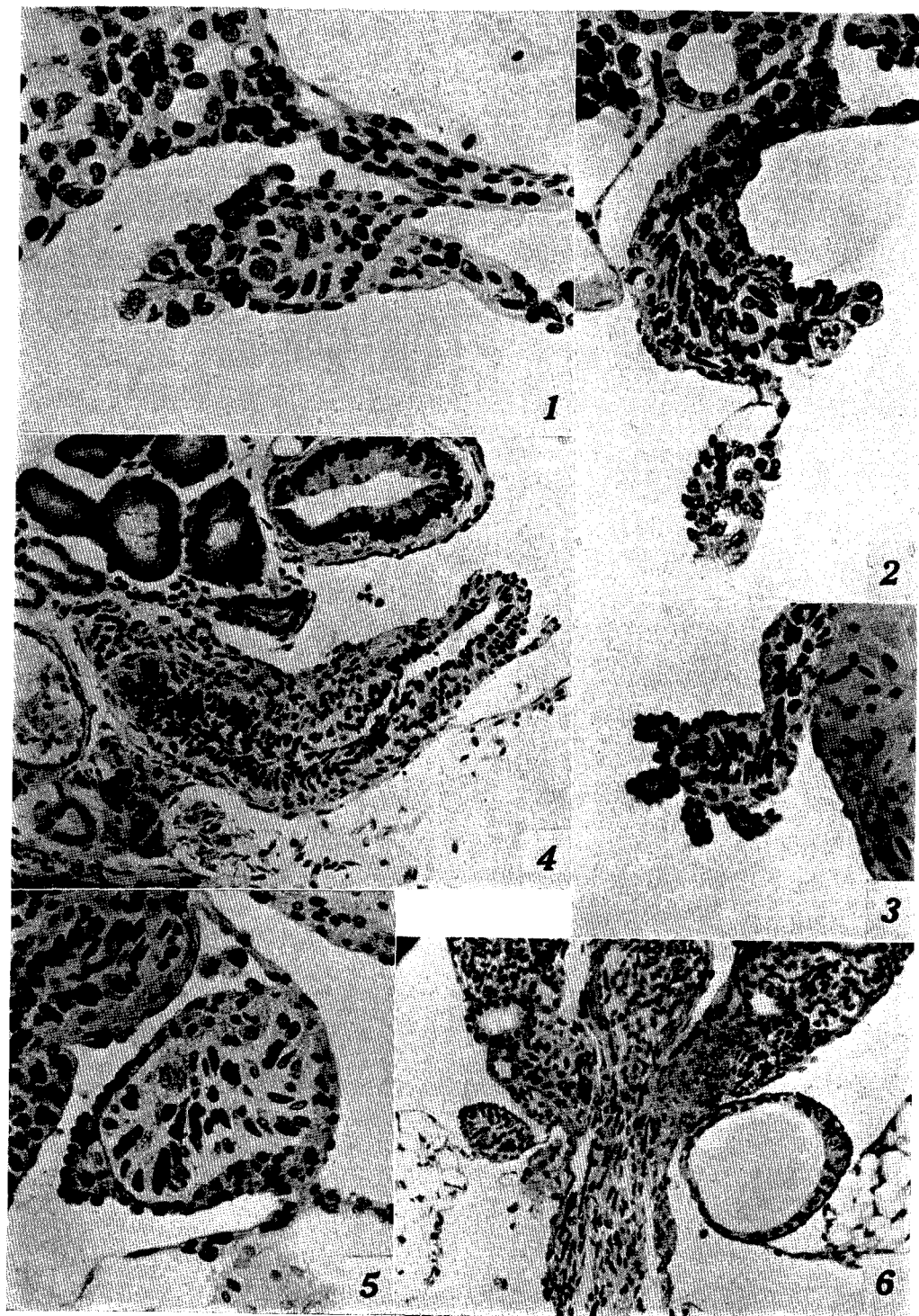- PUCKETT W. O. 1939 Some reactions of gonads of *Rana catesbiana* tadpoles to injections of mammalian hormonal substances. J. Exp. Zool. vol. 81, pp. 32-65.
- 1940 Some effects of crystalline sex hormone on the differentiation of the gonads of an undifferentiated race of *Rana catesbiana* tadpoles. J. Exp. Zool., vol. 84, pp. 39-48.
- WITSCHI, E. and E. N. CROWN 1938 Hormones and sex-determination in fishes and frogs. Anat. Rec., vol. 70, Supplement no. 1, p. 121.

### Explanation of Plate XXXIII

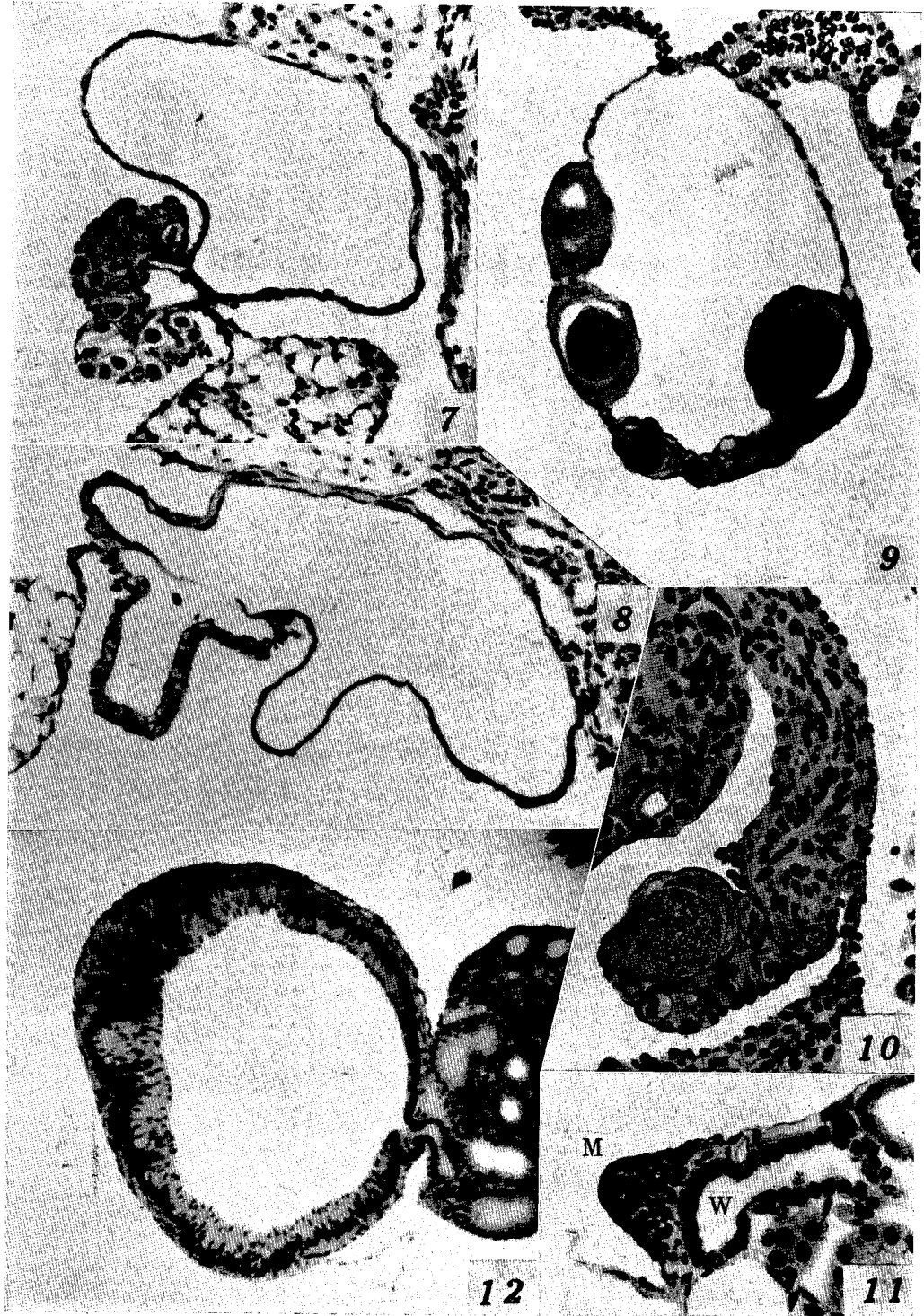
- 1, 2. Section through gonads effected by the injection of testosterone-propionate. The germ cells just about to be eliminated at the tip of the rudimentary vasa efferentia.  $\times 250$ .
3. Section through the vestigial gonad showing the remnant of the germ cell attachment.  $\times 250$ .
4. Section showing the accelerated differentiation of efferential duct. The end of the duct has acquired tubular structure.  $\times 120$ .
5. Section through the end of the duct containing a small number of germ cells.  $\times 250$ .
6. Section through gonads showing a less completely modified case. The gonad on the right side in the figure shows ovarian structure, but the one on the left side shows completely solid structure.  $\times 100$ .

### Explanation of Plate XXXIV

- 7, 8. Section showing the abnormally enlarged lumen of the vas efferens. In 8 the lumen of vas efferens is connected with the ovarian cavity.  $\times 100$ .
  9. Section through an ovary with large oocytes which were precociously differentiated by the action of testosterone-propionate.  $\times 220$ .
  10. Another gonad with precociously differentiated oocytes. The gonad was completely solid in entire length. Note too the development of vas efferens.  $\times 200$ .
  11. Section through the mesonephros showing the average condition of genital ducts a few months after metamorphosis. M, rudiment of the mullerian duct. W, wolffian duct.  $\times 200$ .
  12. Section through the wolffian duct effected by the injection of testosterone-propionate.  $\times 80$ .
-



*K. I. Hanaoka, The Effect of Testosterone-propionate*



*K. I. Hanaoka, The Effect of Testosterone-propionate*