



# HOKKAIDO UNIVERSITY

Title	Sexual Phases in a Japanese Salamander, <i>Hynobius lichenatus</i> Boul., in Relation to the Age of Animals (With 2 Tables and 1 Plate)
Author(s)	AOTO, Tomoji
Citation	北海道大學理學部紀要, 9(4), 389-395
Issue Date	1948-07
Doc URL	<a href="https://hdl.handle.net/2115/27070">https://hdl.handle.net/2115/27070</a>
Type	departmental bulletin paper
File Information	9(4)_P389-395.pdf



**Sexual Phases in a Japanese Salamander, *Hynobius lichenatus* Boul., in Relation to the Age of Animals<sup>1)</sup>**

By

**Tomoji Aoto**

Zoological Institute, Faculty of Science, Hokkaido  
University, Sapporo

(With 2 Tables and 1 Plate)

Collateral to the experimental studies on the sexuality of amphibians in this country, the normal sexual cycle of some species is now under investigation. This report concerns the sexual phase of a salamander, *Hynobius lichenatus*, which is one of most adequate species for experimental studies. The animals, used as material for this study, were caught as eggs in Aomori prefecture during 1940 to 1942 and reared in our laboratory with horse liver, meat and living earthworms for 2-4 years. After fixation they were preserved in the institute. The specimens showed various developmental stages probably due to feeding conditions. These specimens were intrusted to the writer for investigation. After separation of the gonads and the ducts from the body they were sectioned  $10\mu$  in thickness, and were stained with Delafield's haematoxylin and eosin.

Prior to the description of main subject, the writer takes pleasure in acknowledging the helpful suggestions and kind encouragement given by Prof. Dr. Tohru Uchida as well as by Assist. Prof. Dr. Atsuhiko Ichikawa, of our institute. On cytological details the writer received much valuable advice from Prof. Dr. Saijiro Makino, to whom the writer owes a great debt of gratitude for his kindness. The writer is also indebted to Prof. Dr. Kin-Ichiro Hanaoka, of the Yamagata Higher School, for the loan of microscopical preparations.

---

1) Contribution No. 203 from the Zoological Institute, Faculty of Science, Hokkaido University, Sapporo, Japan.

### Development of the testis

*First-year larvae* In the first stage. The gonads show triangular shape in cross section which is characteristic in young larvae. They are composed of the first spermatogonia with bilobed nuclei, crescent follicle cells wrapping the former and small basophilic epithelial cells. In a short time, the sex cord extends from adjacent of the mesorchium interiorly to the gonad but as yet forms no lobules. Masses of small basophilic epithelial cells exist in the peripheral region and distal margins of the gonads. Formation of the fat-vacuoles in the fat-bodies has been performed already.

*1-year-old animals* The formation of seven or eight lobules is now in progress along the central sex cord. The germ cells are almost the first spermatogonia, most of which have chromatin threads in nuclei, but the rest have bilobed nuclei.

*2-year-old animals* The formation of lobules is greatly advanced. Adjacent to the junction point of the gonad and mesorchium, there is formed by a mass of sex cord cells and intralobular tissue cells the longitudinal collecting duct, which is surrounded by a mass of young gonia. In comparatively well-developed testes, which are of the adult type, the formation of the longitudinal collecting duct has already been performed, and around this duct the spermatogenesis is now in progress along the walls of newly formed lobules. There are also seen many interstitial cells in masses among the distal lobules containing bundles of spermatozoa. The testis-ova were observed in one specimen (HP. 100). There is a tendency of feminization in this gonad with lobules somewhat lobated and a longitudinal collecting duct buried deep in the gonad.

*3-year-old animals* The process of lobule-formation is under unfavourable condition. The testis is constituted with five to eight lobules. The gonads indicate the appearance intermediate between the larval and adult stage. Each testis contains in its lobules gonia and cytes only, but no spermatozoa. These specimens seem to be placed in unfavourable circumstances.

*4-year-old animals* The gonads belonging to this group express divergent degrees of development (figs. 1 and 2). Well-developed ones are that of the normal adult, with twelve or thirteen lobules extending throughout the gonad radially around the main collecting duct. These lobules containing bundles of mature spermatozoa contain remaining interstitial cells in their distal portions. And the

dimension of such area is proportional to the volume or number of the bundle of spermatozoa. In testes in the favourable condition the process of spermioteleosis in addition to various stages of spermatogenesis is observable in one cross section (fig. 2).

### Development of the ovary

*First-year larvae* The ovaries contain several large oocytes which are arranged in one close layer surrounding the ovarian cavity. Outside of the oocytes there lies a thick layer of young oocytes and epithelial cells covering the whole gonad (fig. 3). Young small oocytes, found in the peripheral zone of the gonad, are in the leptotene, amphitene and pachytene stages respectively. And sometimes among them, there are seen a small number of oogonia showing nuclear polymorphism. The ovarian cavity is large and is filled with slightly basophilic fluid uniformly. The fat-bodies are well developed.

*1-year-old animals* Vacant.

*2-year-old animals* One ovary was observed (42-44, II. fig. 4). The oocytes become larger in size and in number than those in the preceding series. The ovarian cavity is almost occluded by means of proliferation of oocytes in surrounding cortical germ layer.

*3-year-old animals* The gonads are mainly represented in a cross section by approximately 20 to 25 oocytes and partly by many young cytes and gonia, which are forming a cortical layer (fig. 5).

*4-year-old animals* The ovary has become folded in outline, however, for details of germ cells, they are not different from those in the preceding series.

### Development of the urogenital ducts

*First-year larvae* The sexual differentiation of the ducts is observed in the width of lumina and in the number of constituting cells of the ducts; the müllerian duct is considerably larger in the females and the wolffian duct is slightly larger in the males. The cells constituting walls of the duct are round or somewhat oval in shape, especially in the müllerian duct of females.

*1-year-old animals.* This series contains only one male animal. In the wolffian duct cells are increased and become arranged more

thickly, compared with the former series. But the müllerian duct is rudimentary in shape and in size.

*2-year-old animals* **Males:** The wolffian ducts are much enlarged. The wall of the duct is formed of many columnar cells, which often contain several vacuoles near the periphery (fig. 6). The müllerian duct is rudimentary and is buried in the distal wall of connective tissue sheaths protecting the wolffian duct. The wall of the duct is composed of mere small cuboidal epithelial cells, with rather small cytoplasm. The duct is partly atrophied. The ducts of a specimen (HP., 100) containing a testis-ovum in its gonads show a slight tendency of feminization; the müllerian duct has a wide-opened lumen of which the wall is constructed from about thirty cuboidal cells, while the wolffian duct is made of barely thirteen to fifteen cells of the same nature. In short the müllerian duct (the prospective oviduct) of this animal develops to an abnormal extent.

**Females:** One specimen was observed. Both the müllerian and wolffian ducts are rudimentary and their lumina are very small. The wall of the müllerian duct is considerably thick, because of the elongated shape of its constituting cells which are approximately twenty in one cross section. The wolffian duct in gonadal region comprises seven to nine cells. These ducts are still in the postmetamorphic state.

*3-year-old animals* **Males:** The development of the ducts seems to be somewhat arrested, so the wolffian and müllerian ducts are not so different in cross section, the number of cells being about 15 to 20 in the former and about 25 to 28 in the latter. From these facts above mentioned, these ducts belong to the postmetamorphic type in spite of the age of animals.

**Females:** The development of the müllerian ducts is slightly different according to individuals. In cross sections the müllerian duct is formed of 60-90 cells; that of the adult has about 90 cells. In cross section of the wolffian duct the cells are counted 16 to 19.

*4-year-old animals* **Males:** The ducts of two specimens (40-44, II and VIII) are of the adult type and remaining four (40-44, III, IV, V and VI) have the ducts of postmetamorphic condition. The cells of the wolffian duct in a cross section is about 150 to 155 in the former and about 56 to 63 in the latter. In the müllerian duct the cells are about 14 to 18. The fact will be summarized in the following table (table 1).

Table 1. Table showing nuclear counts in cross sections of the ducts of adult males in postmetamorphic condition.

No. of specimens	Average number of nuclei		Order of gonadal development
	M. duct	W. duct	
40-44, VI	45	18	1
IV	27	18	2
III	24	15	3
V	20	15	4

**Females:** The ducts are fully developed. As to the nuclear counts of the ducts, the following table is given (table 2). It is evident from this table that the development of the ducts agrees exactly with that of the gonads.

Table 2. Table showing nuclear counts in cross sections of the ducts in 4-year-old females.

No. of specimens	Order of gonadal development*	Average number of nuclei		Order of development in the ducts
		M. duct	W. duct	
40-44, II	1	150	24	1
VII	2	123	23	2
IX	4	63	13	4
X	3	87	19	3

\* This order is based on the number of large oocytes seen in a cross section.

In regard to the sex differentiation, Hanaoka ('42) declared that the present species is "a true gonochorist", and that in male animals "neither formation of ovarian sac nor the development of cortical germ layer is detected during the whole process of testicular differentiation." The present writer could not find any facts conflicting with Hanaoka's result. To make manifest how many years would be taken for sexual maturity of this species is one of the objects of the present investigation. Concerning this point also, Hanaoka ('42) wrote briefly that "in laboratory both male and female mature in the

third spring." The material-animals are very irregular in body-length. The largest one in 4-year-old animal series, for instance, was about 80 mm. in total length, while the smallest was only 48 mm. Considering the above-described data, the animal seems to mature sexually two years after metamorphosis, only when their circumstance is favourable.

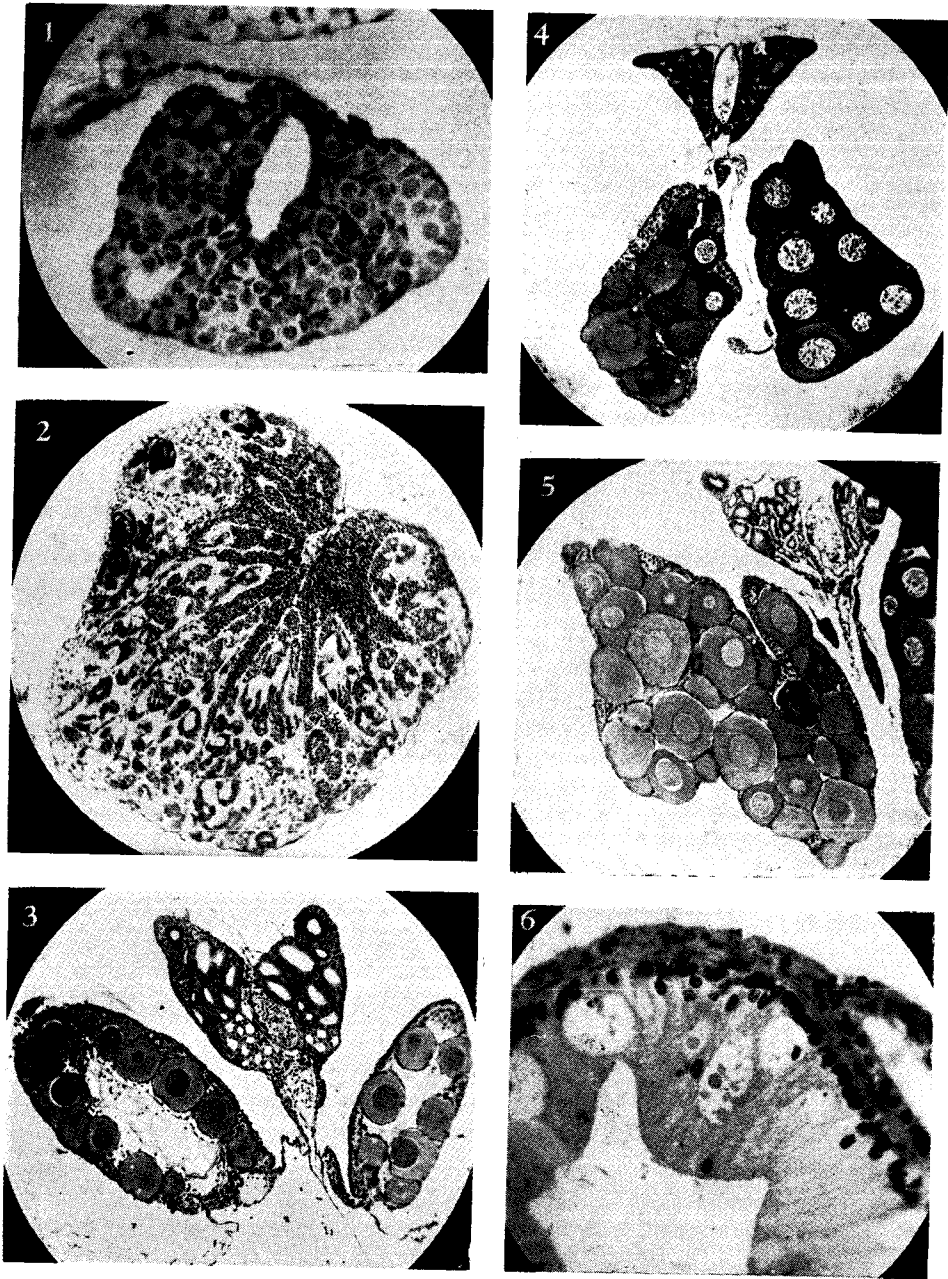
---

### Literature

- Asayama, S. 1940. Embryological studies of sex in amphibians. The differentiation of germ cells and the development of gonads in *Triturus pyrrogaster* (Boie) (Japanese). Zool. Mag. (Tokyo), vol. 52.
- Hanaoka, K. I. 1942. Experimental studies on sex-differentiation in two Japanese salamanders. Jour. Fac. Sci., Hokkaido Imp. Univ., Ser. 6, Zool., vol. 7.
- Humphrey, R. R. 1921. The interstitial cells of the urodele testis. Amer. Jour. Anat., vol. 29.
- Makino, S. 1931. The residual spermatogonia in the adult salamander, *Hynobius lichenatus* Boul. and their behavior during the seasonal cycle of the germ cells. Jour. Fac. Sci., Hokkaido Imp. Univ., Ser. 6, Zool., vol. 1.
- 1934. A cytological study on the maturation and fertilization of the eggs of *Hynobius retardatus* (an urodelan amphibian). Ibid., vol. 3.
- McCosh, G. K. 1930. The origin of the germ cells in *Amblystoma maculatum*. Jour. Morph. and Physiol., vol. 50.
- McCurdy, H. M. 1931. Development of the sex organs in *Triturus torosus*. Amer. Jour. Anat., vol. 47.
- Rodgers, L. T. and P. L. Risley. 1938. Sexual differentiation of urogenital ducts of *Ambystoma tigrinum*. Jour. Morph., vol. 63.
- Swingle, W. W. 1921. The germ cells of anurans. I. The male sexual cycle of *Rana catesbeiana* larvae. Jour. Exp. Zool., vol. 32.
- 1926. The germ cells of anurans. II. An embryological study of sex differentiation in *Rana catesbeiana*. Jour. Morph. and Physiol., vol. 41.
- Witschi, E. 1929. Studies on sex differentiation and sex determination in amphibians. I. Development and sexual differentiation of the gonads of *Rana sylvatica*. Jour. Exp. Zool., vol. 52.
-

**Explanation of figures (Pl. XXXV)**

1. Unfavourably conditioned testis of 4-year-old animal (40-44, V). Longitudinal collecting duct is abnormally large, and surrounding it the lobule-formation process is now proceeding.  $\times 250$ .
  2. Well-developed testis of the same series animal as fig. 1 (40-44, I). Around the main collecting duct, the spermatogenetic wave proceeds radially along the walls of lobules.  $\times 45$ .
  - 3.-5. Cross sections of ovaries.  $\times 45$ .
  3. First-year larvae (D. 96, HP). Large growth oocytes arrange in a row around the distinct ovarian cavity.
  4. 2-year-old animal (42-44, II). The ovarian cavities are almost eliminated. Oogenesis and vacuolization of the fat-bodies are delayed considerably in this animal.
  5. 3-year-old animal (41-44, I). The inner surface of the müllerian duct is uneven, and the area of cortical germ layer is reduced. The gonad is somewhat lobated.
  6. Cross section of the wolffian duct of 2-year-old male (39-41, B. HP). The duct seems to be in a high activity, because of the vacuoles existing among the wall-constituting cells. Note the rudimentary müllerian duct buried in the connective tissue sheath of the wolffian duct.  $\times 200$ .
-



*T. Aoto: Sexual phases in Hynobius lichenatus.*