



HOKKAIDO UNIVERSITY

Title	The Hemopoiesis in the Salamander, <i>Hynobius retardatus</i> (With 1 Plate and 1 Textfigure)
Author(s)	Ouji, Masami
Citation	北海道大學理學部紀要, 10(1), 55-59
Issue Date	1950-03
Doc URL	https://hdl.handle.net/2115/27077
Type	departmental bulletin paper
File Information	10(1)_P55-59.pdf



The Hemopoiesis in the Salamander,

*Hynobius retardatus*¹⁾

By

Masami Ouji

Zoological Institute, Faculty of Science,
Hokkaido University

(With 1 Plate and 1 Textfigure[●])

According to Noble ('31), the Hynobiidae are the most primitive representatives in the urodelans and include five genera. One of these, *Hynobius* is the least specialized genus and is found only in Asia and its adjacent islands. Of urodelans hynobiid salamanders are the most widely distributed in Japan, covering Kyushu, Hondo (Japan proper) and Hokkaido. The species with which this inquiry is concerned is *Hynobius retardatus* which is the sole insulator of the urodelan fauna in Hokkaido. Drzewina ('05) and Jordan ('32) has studied the formation of the blood cells of *Proteus anguineus*, the European blind salamander. Dawson ('32) has made a survey of homopoiesis in *Necturus maculosus*, the well-known Mud-Puppy of zoological laboratories of America. These two genera form a natural group of permanently larval salamanders and they are placed in a distinct family, the Proteidae. On the other hand, the American newt, *Triturus viridescens* (Jordan and Spiedel, '30) and *Triturus* (= *Diemyctylus*) *pyrrhogaster*, a common species of Japan (Ohuye, '27, '32) have been taken up for the study of the blood cell formation. From the standpoint of the phylogeny of the families of urodeles, the Salamandridae, to which *Triturus* belongs, is regarded as having evolved from some prehynobiid stock whereas the direct ancestry of the Protidae is unknown and their relationship to the hynobiid salamander is uncertain. Since the evolutionary history of the hemopoietic tissue follows to a certain extent the phylogenetic order, it will be not redundant to make a study concer-

1) Contribution No. 233 from the Zoological Institute, Faculty of Science, Hokkaido University, Sapporo.

ning the situation regarding hemopoiesis in *Hynobius* which is considered as the most primitive type living. Delafield's haematoxylin-eosin and azur-eosin were used for tissues after fixation in Helly's fluid. For blood smears, May-Giemsa's stain and Wright's stain were employed.

In publishing the results of this study, I wish to express my best thanks to Professor Atsuhiko Ichikawa, under whose guidance and supervision this work was carried out.

Observations

Spleen. The structure of the spleen of *Hynobius* is a typical urodelan type (Hartmann, '26 and later, Dawson, '32), and its function is the production of the blood cells of the erythrocytes series, e.g. erythrocytes and thrombocytes.

In the fall before hibernation of this animal, the function of the production of erythrocytes seems to be activated to some extent. The predominant erythrocytopoiesis in the meshes of the splenic reticulum is found in the spring animals. Except Hartmann ('26) who has observed granulocytopoiesis in the spleen of axolotl (*Ambystoma*), Jordan and Speidel ('30) in *Triturus viridescens* and Dawson ('32) in *Necturus maculosus* have agreed that practically no granulocytopoiesis is to be seen in the spleen. Also the writer can not find that granulocytes are differentiated in the intercellular spaces of splenic reticulum. Completely differentiated granulocytes found in this locus, in all probability, may have migrated from the general circulation.

Liver. Two different hemopoietic loci are found in the liver of the salamander. The first is the granulocytopoietic marginal layer which is mostly developed in the distal part of the lobes and extends to the median part under the serous capsule of the organ. These layers are composed of 4 to 12 cells thick. Liver taken from animals during the spring showed the evidence of increased mitosis of the lymphoid hemoblasts in these areas. Another hemopoietic locus is to be found around the part of the artery which runs parallel to the course of the bile-duct. In this dense lymphogranulocytopoietic tissue are to be found the reticular cells, lymphoid hemoblasts which give rise to the granulocytes, mature granulocytes and lymphocytes. The erythrocytes and some young cells of erythrocytes series are also encountered in this area. However, there is no sign of erythrocyte differentiation. In the main, there seems to be no striking differences between *Hynobius* and *Necturus* in the distribution of hemopoietic tissue in the liver. But in this animal are barely visible the isolated lymphoid masses interposed in the liver sinuses as described by Dawson ('32) in *Necturus*.

Heart The compensatory erythropoiesis in the cardiac reticuloendothelium has been clearly demonstrated by splenectomy in *Triturus viridescens* (Jordan and Speidel, '30), in *Triturus (=Dimyctylus) pyrrhogaster* (Ohuye, '27, '32) and in Axolotl (Wituschinski, '28). Ichikawa ('34) has demonstrated this phenomenon more clearly in the embryonal heart of *Hynobius retardatus* in his own new method. He cultured the embryos at a stage as early as gastrula in a high oxygen milieu and made them develop for about 10 to 20 days in it at a normal tempo. After the treatment the embryos are capable of living and further development in normal tap-water.

Sections of the heart of normal adult *Hynobius* show the production of typical hemoblasts which originate from the cardiac reticuloendothelium. These hemoblasts leave the wall and continue to undergo successive separation to be changed into the erythrocyte *in situ*. On the other hand, some hemoblasts in this locus may transform into monocytes. The endothelial cells in heart have a capacity of digesting carmine particles injected from without. Dawson ('32) has described a well-defined layer of granulocytopoietic tissue in the connective tissue of the visceral pericardium covering the heart (especially in the wall of the cenus arteriosts), however, in *Hynobius* there is no evidence suggesting differentiation of granulocytes in this area.

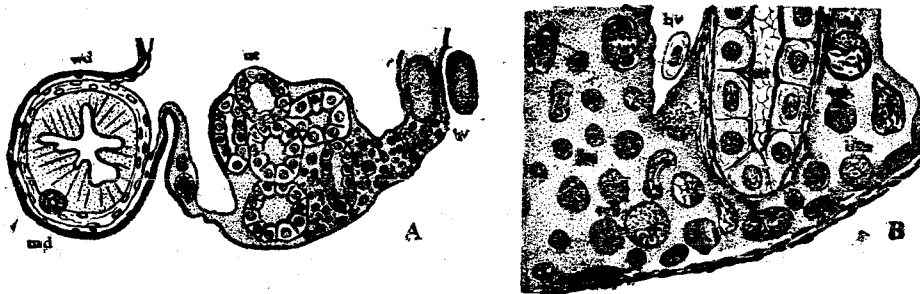


Fig. 1. A. A section through the anterior portion of the kidney showing the distribution of the lymphogranulocytopoietic tissue, slightly diagrammatic. B. The lymphogranulocytopoietic tissue drawn at higher magnification; bas, young basophile; bv, blood vessel; ebl, eosinophilic granuloblast; lm, lymphocyte; md, müllerian duct; rec, reticuloendothelial cell; sgb, special granuloblast in mitosis; ut, uriniferous tubule; wd, wolffian duct

Kidney. In *Hynobius*, the production of lymphogranulocytes is apparently restricted in the anterior portion of the kidney (Fig. 1. A and B). In these loci abundant granulocytes in process of differentiation are to be seen and

the lymphoid cells are situated at periphery of the cell mass. In the mesonephros of *Necturus*, Chase ('23) and Dawson ('32) observed in the intertubular lymphogranulocytopoietic tissue and Dawson stated that the tissue is less made in the anterior or genital portion of the kidney. Jordan ('32) found in *Proteus anguineus* that the mesonephros constitutes the sole organ of eosinophile and neutrophile production, lacking a hepatic subcapsular lymphogranulocytopoietic layer. Jordan and Spiedel ('30) described the kidney of the splenectomized animals (*Triturus*). They said that in one case a small locus of erythrocytopoietic activity was found at an end of the kidney.

In the normal kidney of *Hynobius*, the hemopoietic area is rather uniformly distributed throughout the anterior two-thirds of the entire length of the organ. The production of monocytes and erythrocytes is not observed in the kidney.

Thymus. In breeding season, the subcutaneous reticular tissue is produced in maximum amounts in the male of *Hynobius retardatus*. Scattered lymphocytes also occur in this location, especially about the thymus glands. The section of these areas strongly suggest that these lymphocytes would derive from the thymus glands. The predominating elements of these glands are the lymphoid cells. Completely differentiated granulocytes and also immature differentiating ones are rarely encountered. Histiocytes are to be seen in the reticular meshes of the capsular layer of these organs.

Summary

Though the perihepatic capsular layer of the granulocytopoietic tissue is rather well developed, the hemopoietic tissue in the liver is not restricted to this part. Within the liver the dense tissue is to be seen around the blood vessel. But the isolated masses of the lymphoid cells in the hepatic parenchyma are barely visible in this species.

Evidence is seen indicating the erythrocytopoiesis as taking place within the reticuloendothelium of the heart. In both ventricle and auricles this process can be observed.

The kidney is active and the lymphogranulocytopoietic tissue is restricted to the anterior two-thirds of the entire length of the organ. In this part the tissue is rather uniformly distributed.

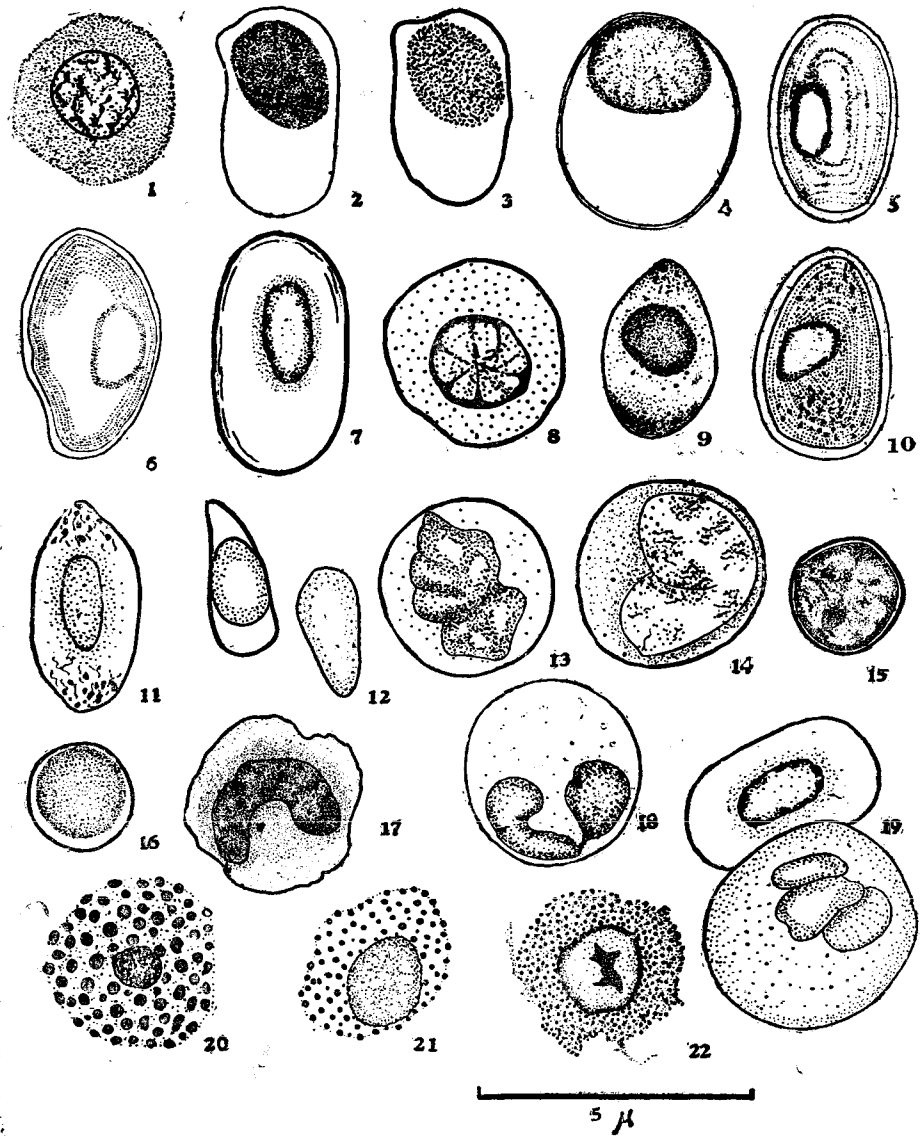
The thymus gland may be a unique locus in possessing lymphocytopoiesis. The lymphocytes develop in these organs to be distributed into the subcutaneous lymphatic spaces.

Literature Cited

- Chase, S. W. 1923. The mesonephros and urogenital ducts of *Necturus maculosus* Rafinesque. Jour. Morph., vol. 37, pp. 457-531.
- Dawson, A. B. 1932. Hemopoietic loci in *Necturus maculosus*. Anat. Rec., vol. 52, no. 4, pp. 367-379.
- Drzewina, A. 1905. Contribution à l'étude du tissu lymphoïde des Ichthyopsidés. Arch. de Zoo. Exp. et Gén., sér. 4, T. 3 pp. 145-338.
- Hartmann, A. 1926. Über die feineren Bau der Milz bei Urodelen Amphibien (Axoloti). Zeit. f. Anat. u. Entwickl., Bd. 80 S. 454-491.
- Ichikawa, A. 1934. An experimental study of the compensatory hemopoiesis in urodele embryos. Proc. Imp. Acad., vol. 10, pp. 240-243.
- Jordan, H. E. 1932. The lymphocytes of the urodele, *Proteus anguineus*. Anat. Rec., vol. 52, p. 21 (abstract).
- Jordan, H. E. and C. C. Speidel., 1930. The hemopoietic effect of splenectomy in the salamander, *Triturus viridescens*. Am. Jour. Anat., vol. 46, no. 1, pp. 55-90.
- Noble, G. K. 1931. The Biology of the Amphibia.
- Ohuye, T. 1927. On the changes in the blood, the liver, and the bone of the Newt following splenectomy. Sci. Rep. Tohoku Imp. Univ. ser., 4, Biol. vol. 3, no. 1, pp. 71-86.
1932. Hemopoietic effect of splenectomy in the Newt, *Diemyctylus pyrrhogaster*. Sci. Rep. Tohoku. Imp. Univ. ser., 4, Bio., vol. 7, no. 1, pp. 45-63.
- Wituschinski, V. 1928. Hämato-poiese beim Axolotl nach Milzextirpation. Zeit. f. Zellforsch. u. mikr. Anat., Bd. 6, s. 611-630.

Explanation of Plate III

Camera-lucida drawings illustrating the various blood cells of the salamander, *Hynobius retardatus*. Blood smears were made from the general circulation and stained with May-Giemsa's stain. All cells are drawn at the same magnification. 1. Hemoblast. 2. Immature erythroblast. 3. Erythroblast. The cytoplasm is moderately basophilic and the nucleus is large and stains bluish purple. 4. Transitional stage from hemoblast to erythroblast. 5. 6 and 7. Mature erythrocytes. 8. Immature thromboplast with azurophilic granules in cytoplasm. 9. Thromboplast. The cytoplasm has clusters of similar granules at both ends. The nucleus is surrounded by deeply stained azurophilic granules. 10. Transitional stage from thromboplast to thrombocyte. 11. Thrombocyte. The granules are larger than in the preceding cell. 12. Old thrombocyte. 13. and 14. Monocytes showing lobulated nucleus and archoplasmic zone which is marked by cluster of small azurophilic granules. 15. Young lymphocyte. 16. Lymphocyte with dense nucleus and bluish granules in cytoplasm. 17. Young special (neutrophilic) granulocyte. The nucleus is kidney-form. The ground substance of the cytoplasm is pale blue with reddish purple granules. 18. Special (neutrophilic) granulocyte with segment type nucleus. 19. Mature erythrocyte and poly-nucleated bluish granules. 20. Mature eosinophile. 21. Young basophile containing compact bluish granules. 22. Old basophile. The nucleus has a irregular chromatin block of considerable size.



M. Onji: Hemopoiesis in Hynobius retardatus