



# HOKKAIDO UNIVERSITY

Title	Notes on the Change in the Kidney of <i>Gasterosteus aculeatus aculeatus</i> (L.) Caused by the Estrogen Administration (With 2 Text-figures)
Author(s)	OGURO, Chitaru
Citation	北海道大學理學部紀要, 13(1-4), 404-407
Issue Date	1957-08
Doc URL	<a href="https://hdl.handle.net/2115/27265">https://hdl.handle.net/2115/27265</a>
Type	departmental bulletin paper
File Information	13(1_4)_P404-407.pdf



# Notes on the Change in the Kidney of *Gasterosteus aculeatus aculeatus* (L.) Caused by the Estrogen Administration<sup>1)2)</sup>

By

**Chitaru Oguro**

(Akkeshi Marine Biological Station, Akkeshi, Hokkaido)

(With 2 Text-figures)

It is well known that the kidney of the male stickleback becomes to be swollen in the breeding season. From the experimental results it has been clear that the swelling of the kidney is dependent on the testes, perhaps on an hormonal substance secreting by the testes (Craig-Bennett, '31; Ikeda, '33). In the present paper, the changes of the kidney caused by the injection of an estrogen are briefly described.

Before going further, the writer is deeply grateful to Prof. Tohru Uchida for his unfailing guidance and correction of the manuscript. The writer is also due to Dr. Kiichiro Yamamoto for his kindly encouragement.

The adult fish were reared in current sea water and fed with fish meat and liver. They were intraperitoneally injected with 0.02 mg of estradiol benzoate suspended in 0.1 cc of balanced saline generally at intervals of four days. Two days after each injection, several fish were sacrificed and preserved. After the fourth injection, the fish were also fixed on the fifth, ninth and thirteenth days. The kidney were removed from the totally Bouin-fixed fish and the width was measured by calipers. They were embedded in paraffin and sectioned in 10  $\mu$  thickness. The sections were stained with Delafield's hematoxylin-eosin, Heidenhain's iron hematoxylin or Mallory's triple staining.

## Results

In sexually inactive seasons, the kidneys of the both sexes showed similar histological pictures as described by Ikeda ('33). In the breeding season, the kidneys of the male fish became markedly swollen, measuring 3.0 mm in average width and pinkish white in color. The histological picture of such a kidney shows that the renal tubule is composed of high columnar epithelial cells filled with intensely eosinophilic granules of large size. The average height of the epithelial cell is 40  $\mu$ . The nucleus is placed at the basal portion of the cell. In

---

1) Dedicated to Professor Tohru Uchida, director of the Akkeshi Marine Biological Station, in commemoration of his sexagenary birthday.

2) Contributions from the Akkeshi Marine Biological Station, No. 94  
*Jour. Fac. Sci. Hokkaido Univ. Ser. VI, Zool. 13, 1957 (Prof. T. Uchida Jubilee Volume).*

the Delafield-stained sections, the nucleus is uniformly stained and no intra-nuclear apparatus is observable, while those by Heidenhain's iron hematoxylin show differential staining (Fig. 2, a, k). On the other hand, the kidneys of the female are about one-half the width of the male, showing deep red in color. The cells composing the renal epithelium are cubic in form, measuring  $16 \mu$  in average height. The cytoplasmic granules are stained rather faintly with eosin. The nucleus is generally situated in the central or luminal portion and the intra-nuclear apparatus is recognizable even in the Delafield-stained sections (Fig. 2, h, l).

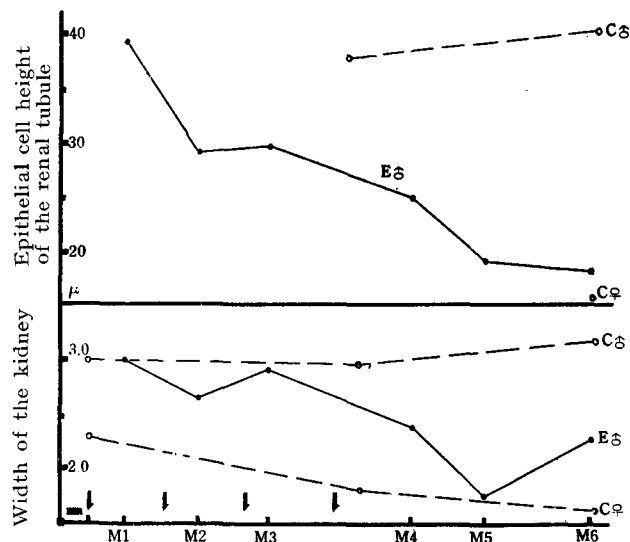


Fig. 1. Changes of the width of the kidneys and the height of the epithelial cells of the renal tubules. Vertical arrows indicate injections. C♂; normal male, C♀; normal female, E♂; estrogenized male.

In the followings, M1, M2, . . . M5 and M6 mean the firstly fixed males, the secondarily fixed males, . . . . . and the sixthly fixed males respectively.

**M1**: The nucleus became markedly larger in size, becoming to have conspicuous nucleoli which had formerly undistinguishable in the Delafield-stained sections. The cytoplasmic granules were reduced in eosinophilic character. In this stage, the height of the epithelial cells and the width of the kidneys remained yet unchanged (Fig. 2, a, m).

**M2**: The nucleus became more enlarged, measuring  $13 \mu$  across the widest diameter in the largest one (about twice the diameter of the normal male). In this stage, the height of the epithelial cells and the width of the kidneys were decreased, indicating  $28 \mu$  and  $2.8 \text{ mm}$  respectively. There could be observed

vacuolations in the luminal portion of the epithelial cells in some tubules (Fig. 2, b, n, o).

**M3**: The nucleus situating aloof from the basal end of the cell, the case occasionally found in M2, became to be found more frequently (Fig. 2, c).

**M4**: The average height of the epithelial cells was  $25 \mu$  and the width of the kidneys was 2.4 mm in average (Fig. 2, d, p).

**M5**: The nucleus migrated toward the central area of the cell. Again, the nucleus became somewhat decreased in size. The height of the epithelial cells and the width of the kidneys were  $19 \mu$  and 1.7 mm in average respectively (Fig. 2, e, q).

**M6**: The average height of the epithelial cells was more decreased and indicated  $18 \mu$ , although the width of the kidneys was slightly recovered, showing

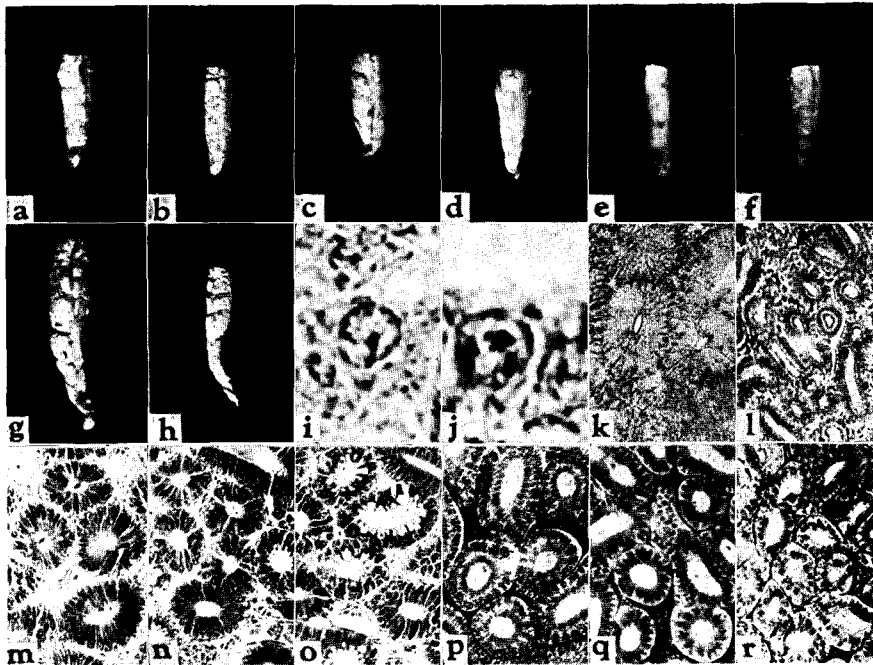


Fig. 2 a-h; Photographs of the kidney, upper half of each kidney is removed.  $\times$ ca. 2. a: M1. b: M2. c: M3. d: M4. e: M5. f: M6. g: normal male. h: normal female.

i-j; Microphotographs of the nucleus of the epithelial cell.  $\times$ ca. 1900 i: normal female. j: estrogenized male (M6).

k-r; Microphotographs of the renal tubules.  $\times$ ca. 190 k: normal male. l: normal female. m: M1. n: M2. o: M2. showing vacuolations in the luminal end of the epithelial cells. p: M4. q: M5. r: M6.

2.2 mm in average (Fig. 2, f, r). It was difficult to distinguish the kidneys of the estrogenized male at this stage from those of the female with respect to the height of the epithelial cells and the situation of the nucleus. On closer observation, however, the condition of the nucleus is somewhat different and the renal tubules are in rather irregular form (Fig. 2, i, j, l, r).

No change occurred in the kidneys of the estrogenized female, so far observed.

In the present study, the swelling of the kidneys in the breeding male was suppressed by the estrogen administration as was observed in the castrated male by Ikeda ('33). As noted above, however, the kidneys of the estrogenized male did not indicate exactly similar appearance as in the female organs. But the writer is of the opinion that the differences between them have been brought about by the inadequate dosage level or the toxicity of the reagent used and in reality the male organs have been feminized.

#### Literature

- Craig-Bennett, A. 1931. The reproductive cycle of the three-spined stickleback, *Gasterosteus aculeatus*, Linn. Philos. Trans. Roy. Soc. London Ser. B, 219: 197-279.
- Ikeda, K. 1933. Effect of castration on the secondary sexual characters of anadromous three-spined stickleback, *Gasterosteus aculeatus aculeatus* (L). Jap. J. Zool. 5: 135-157.
-