



# HOKKAIDO UNIVERSITY

Title	Time Relation between the Administration of Estradiol and the Occurrence of Abnormalities in Limbs and Gonads of Frog Larvae (With 13 Text-figures)
Author(s)	TAKAHASHI, Hiroya
Citation	北海道大學理學部紀要, 14(1), 101-110
Issue Date	1958-12
Doc URL	<a href="https://hdl.handle.net/2115/27292">https://hdl.handle.net/2115/27292</a>
Type	departmental bulletin paper
File Information	14(1)_P101-110.pdf



# Time Relation between the Administration of Estradiol and the Occurrence of Abnormalities in Limbs and Gonads of Frog Larvae<sup>1)</sup>

By

**Hiroya Takahashi**

(Zoological Institute, Hokkaido University)

(With 13 Text-figures)

In frog species, the masculinizing effect of a large dose of estradiol has been well established by many authors (Gallien 1940, 1941, Padoa 1942, Witschi 1953, Bellanca 1954, Chang & Witschi 1955, Takahashi 1957a). A severe inhibition of development of the gonadal cortex plays a leading role in this mechanism. Indeed, under certain conditions, the type of action of estradiol is evidently of toxic (cf. Witschi 1955).

Previously, the present writer reported the estradiol-induced malformation of the limbs in toad larvae (Takahashi 1957b). Such an effect is evidently dependent on dosage of estradiol used. In addition, it seems to be highly possible that the sensitivity of cells or tissues to administered substance is involved in the mechanism of malformation. This inference may be applicable also to the experimental modification of gonadal development.

It is the aim of this paper to report some results of morphological examination of the frog larvae affected by a large amount of estradiol, with special reference to any possible relation of occurrence of morphogenic disturbance of limbs and gonads to the time of treatment.

Before proceeding further, the writer wishes to express his cordial thanks to Professor Tohru Uchida for guidance and encouragement in the course of the study. Thanks are also due to the Teikoku Hormone Mfg. Co., Tokyo, for the donation of the hormone used in the present study.

## Material and method

Fresh, natural spawnings of *Rana* sp.<sup>2)</sup> were collected in the vicinity of Sapporo

1) Contribution No. 432 from the Zoological Institute, Faculty of Science, Hokkaido University, Sapporo, Japan.

2) The species used in the present study is that described as *Rana temporaria* in the preceding paper (Takahashi 1957a). It is the only Ranidae frog species distributed in Hokkaido. Recently, the opinion was expressed by Dr. E. Witschi of the State University of Iowa, U.S.A., that the present species cannot be regarded as *Rana temporaria*, but has a resemblance to *Rana avalis* in Europe. Then in the present paper *Rana* sp. will be substituted for so-called *Rana temporaria* in Hokkaido.

*Jour. Fac. Sci. Hokkaido Univ. Ser. VI, Zool. 14, 1958.*

Table 1. State of animals in each experimental group at

Group	At beginning of		
	Number of animals	Age after hatching days	Average body length (total length) mm
Exp. I ('57)	50	8 <sup>1)</sup>	5.0(13.4)
Exp. II ('58)	40	13	6.0(15.2)
Exp. III ('58)	18	20 to 25	10.0(25.0) to 11.8(30.5)
Control ('57) ( '58)	50 30	—	—

- 1) These larvae were at the stage just after closure of the gill  
 2) In another group of tadpoles administered with the solvent

and cultured in the laboratory. The experiment was performed in the early spring of 1957 and repeated in 1958, each with the same brood and under identical conditions, respectively.

A single concentration of 1.5 mg of estradiol per litre of the aquarium water was selected for the study. Crystalline estradiol (Teikoku Hormone Mfg. Co., Tokyo) was previously dissolved in propylene glycol (7 parts) mixed with 95% ethyl alcohol (3 parts), then added to rearing water. This solvent had proved non-effective on growth and gonadal differentiation of the tadpoles. About ten larvae were kept in each glass dish of 15 cm diameter, which contained 500 ml of water. The animals were fed on fish meal, boiled spinach and other vegetables. Water temperature was 14° to 16°C at beginning of the treatment, and gradually raised to 18° to 20°C in both years. Aquarium water was changed every second day.

In 1957, 50 tadpoles received the treatment from the 8th day after hatching to the late metamorphic stage (Group I). In view of the high mortality in Group I, in 1958 administration of estradiol was commenced on the 13th day or later after hatching (Groups II and III). State of the animals of these groups at beginning of the treatment is summarized in Table 1. Most of the treated animals were fixed in Bouin's or Zenker's fluid at their late metamorphic stage. Fourteen larvae of Group II were sacrificed after 14 days of treatment, and five tadpoles of Group III were returned to normal tap water after 12 days of treatment and fixed at the end of metamorphosis. Serial sections of the gonads and mesonephros were cut 10  $\mu$  in thickness and stained with Delafield's hematoxylin and eosin.

### Experimental results

In the previous experiment (Takahashi 1957b), some of the toad larvae survived in the dosage of 2 mg/1 of estradiol throughout the metamorphosis. In the frog, however, a dose of 2 mg/1 was found narcotic and even lethal for the larvae. In a dosage of 1.5 mg/1,

beginning of the treatment with 1.5 mg/1 of estradiol

the treatment		Duration of the treatment days	Mortality %
State of hind-limbs	State of gonads		
Limb buds just appear externally	Unpaired gonadal fold	51	44.0
Limb buds elongate conically to about 0.5 mm	Paired gonadal folds	40	12.5
Formation of foot-plates (1.2~1.8 mm)	Indifferent gonads to initial ovarian differentiation	25	5.5
—	—	—	2. (2) 0.0

sacs.

of the hormone only, mortality was 6.6 per cent.

estradiol did not act as a narcotic, though about 35 per cent of the larvae of Group I died during the first two weeks of treatment. In both Groups I and II, the animals were somewhat smaller than control ones at the time of fixation. However the tadpoles did not show any edematous features when treated with this dosage.

In the control animals of 1957, eruption of fore-limbs started to occur at the 39th day after hatching, and most of the animals were provided with protruded fore-limbs during the following week. On the other hand, the larvae of Group I had longer larval period, with their opercular perforation being noticed first at the 55th day after hatching. In Groups II and III, however, the larvae exhibited no delay of metamorphic changes. Of these animals, the development of limbs and gonads was studied histologically.

a) *Effect of estradiol on development of limbs*

In Group I, all the animals developed unfunctional hind-limbs at the end of metamorphosis (Fig. 1). During this period, the control tadpoles swam actively by means of paddling movement of the hind-limbs. On the contrary, the treated tadpoles could not fully stretch the hind-limbs, especially movement of the leg and foot being restricted. The protruded fore-limbs of the treated animals were also nearly unfunctional. The animals could not freely bend the arm nor the hand.

The limbs were removed at their base from the body after fixation and examined histologically. In some ones, the bones were stained *in situ* with methyl green (Figs. 2-4).

The femur was, in most cases, shorter in length than that of the normals. Generally, there were no significant changes in muscular development in the thigh region, while the leg and foot region possessed scanty muscle or was lacking in muscle. In a few cases, however, the treated animals had stumpy thighs with

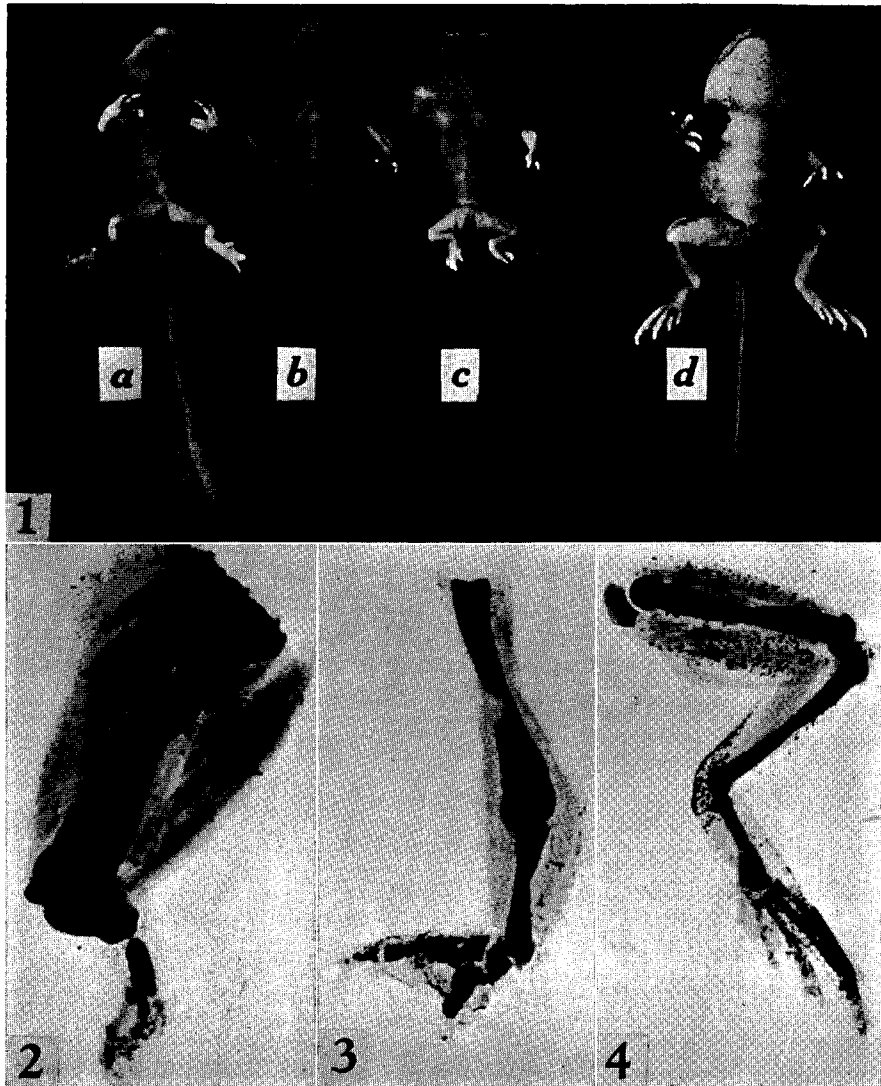


Fig. 1. Metamorphosing frog larvae showing normal and malformed features of the limbs. *a, b, c*; animals treated with 1.5 mg/l of estradiol (Group I). *d*; normal control.  $\times 2$ .

Figs. 2, 3. Deformed limbs of the same animal as Fig. 1*b*. Bones stained with methyl green, skin removed and cleared by xylol. 2; right hind-limb. 3; left fore-limb.  $\times 15$ .

Fig. 4. Normal hind-limb of the control animal.  $\times 5$ .

abnormally thick muscle, as seen in Figs. 1*b* and 2. Reduction in length of the tibio-fibula was evident; crural index (the percentage of length of the tibio-fibula to that of the femur) for the treated animals was 41.4–73.8, or about 57 on an average, while it was 85.7–94.8, or about 90 on an average, for the control animals. The tarsus was also shorter in the treated animals.

No abnormalities were seen in the histological feature of the bone and muscle tissue. In the distal part of the limbs, however, development of the bones was not only retarded but also disturbed. As in the normal, the tibio-fibula, in most cases, consisted of two bones. But, in some cases, there could, instead, be found only a single one in this region. Sometimes the leg bone was enlarged or curved slightly inwards. The foot was always unusual in external appearance, its degree of abnormality being evidently proportional to that in the leg region. Chiefly, branching of the toes was incomplete and abnormal, not always corresponding to the branching of the bones. An irregular syndactylism was the most frequent occurrence.

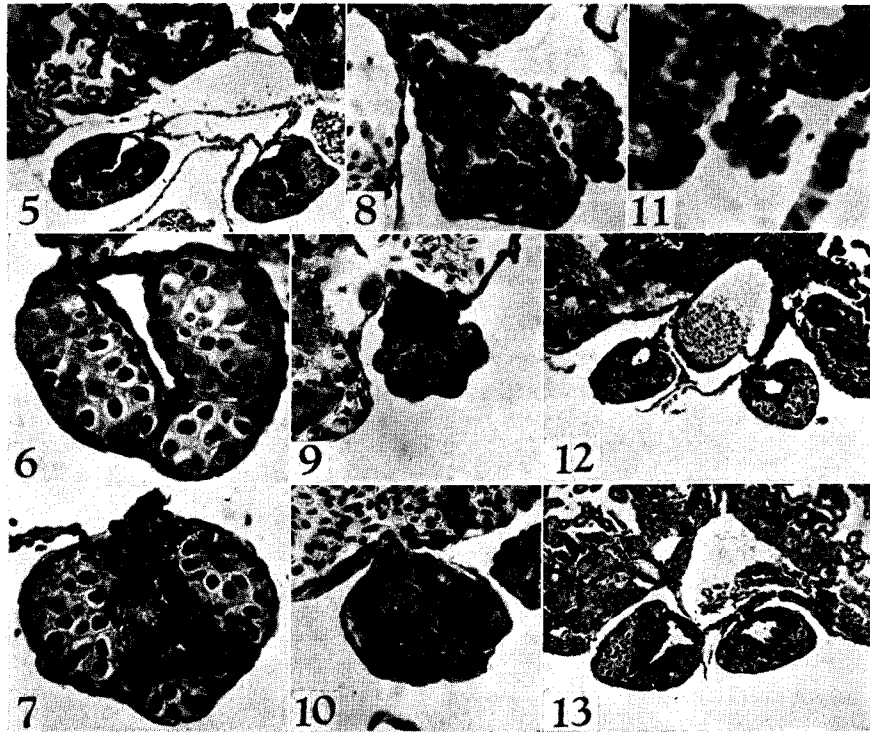
In the protruded fore-limbs, there could be noticed some anomalies of similar order as in the hind-limbs (Figs. 1, 3). The humerus was almost normal. In the fore-arm, the bone was single and slender; diaphysial enlargement had taken place. The hands showed various abnormalities in shape. Some were nearly normal, while others showed irregular branching of the digits. In the former, the first and the second digits approached each other, the first metacarpal bone tending to curve slightly inwards (Fig. 1*a*). In the latter, syndactylism was the chief feature of the abnormalities.

In contrast with the above-mentioned malformations in Group I, the hind- and the fore-limbs showed normal development in Groups II and III. Although some of the limbs were a little smaller than the control ones at the late metamorphosis, their crural index ranged from 85.3 to 95.0 in both groups. Morphological examination also revealed no notable differences between the limbs of the treated and the control animals.

b) *Effect of estradiol on gonadal differentiation*

The species used in this study is a sexually semidifferentiated race (Takahashi 1957a); the gonads of all the larvae pass through ovarian phase, and testicular differentiation starts at late metamorphosis in the male larvae. At the end of metamorphosis, most animals have ovaries with auxocytes (Fig. 5) or with no auxocyte. Degeneration of cortical germ cells is frequently observed in most of the latter type of gonad (Fig. 6). Also sometimes found in the larvae at this stage is the gonad with various degrees of intersexual features, with persisting medulla including some germ cells surrounded by cortical layer (Fig. 7).

In Group I, the effect of estradiol on the gonads was evidenced by severe reduction in number of the germ cells. None of the germ cells showed oogenesis; the majority of them were seen in the medullary tissue which made modest development, thus nearly attaining a testicular feature. These gonads were small. In some



Figs. 5-7. Cross sections of gonads of control animals at end of metamorphosis. 5 ;  $\times 80$ . 6, 7 :  $\times 250$ .

Figs. 8-11. Cross sections of affected gonads in Group I, showing differentiation of atrophic testes.  $\times 250$ . Fig. 11 showing a constriction found in median part of the testicular gonad.

Fig. 12. Cross section of affected gonad in Group II. Note the ovarian sacs lined with thick layer of the medullary tissue.  $\times 80$ .

Fig. 13. Cross section of affected gonad in Group III. The ovarian sacs were lined with thickened medulla, and auxocytes were seen in the cortex.  $\times 80$ .

cases, a few germ cells took position at the distal part of the gonads as a cap-like mass, leaving the medullary tissue at the proximal part (Fig. 9). There could still be found a cortical remnant, which consisted of rather thick epithelium with a few germ cells (Figs. 8, 10). Moreover, most of the gonads possessed one or more constrictions between cranial and caudal testicular regions, resulting from nearly complete deficiency of the germ cells in such a part (Fig. 11). Generally a portion between the invading rete cords was occupied by a loose mesenchym tissue which, in some cases, had a clear hole. Sometimes this part was deformed into the constriction.

Thus, in Group I, the treatment with estradiol caused masculinization of the gonads. The testicular differentiation seemed, however, to be disturbed, perhaps owing to very strong inhibitory action of an exceedingly large amount of estradiol on germ cell proliferation and oogenesis, and also on medullary development.

In Group II, the gonads were in the stage of paired gonadal folds when the treatment was started. After 14 days of treatment, the gonads still showed the indifferent structure, but the germ cells were small in number, whereas the normal gonads of the same age had started female differentiation such as formation of ovarian sacs and oogonial nests. At the end of metamorphosis, the affected gonads were evidently shorter in length as compared with the normals. Histologically the affected gonads had well differentiated cortex, but with no auxocyte (Fig. 12). The wall of the ovarian sacs was markedly thick, but included no germ cells. Such marked thickening of the wall was never seen in the normal gonads of genetic males at the same stage.

The masculinizing tendency in Group III was nearly the same as in Group II. The ovarian sacs were lined with thick medullary layer in all the gonads examined, whereas the cortical differentiation was seemingly normal (Fig. 13). The auxocyte formation was noted in the gonadal cortex in about a half of the animals.

Hyperplastic development of the adrenal tissue occurred more or less in all the animals of the three groups. It was more markedly noted in the cranial gonadal region of the mesonephros than in the caudal region, and in some cases the hyperplastic tissue formed a dorsal bridge over the caval vein. However, the degree of the hyperplasia seemed to have no relation with the time of starting the treatment.

### Discussion

Since the works of Padoa (1936-1938), it has been well established that the estrogens exert a masculinizing effect on sex differentiation in some anurans (cf. Padoa 1950, Witschi 1950, Gallien 1955). The results obtained in the present study are essentially identical with those previously reported in the present species, in respect to masculinization (Takahashi 1957a). Estradiol in a large dose causes an inhibition of oogenesis and multiplication of the germ cells. Such effect fairly coincides with the observation made by Bellanca (1954), who stated that 1mg/1 of estradiol brings about hindrance of oogonial multiplication and inhibits the appearance of premeiotic oocytes. In the present study, furthermore, some facts suggest an inhibitory action of an exceedingly large amount of estradiol on the medullary development. Thus the resulted testes are of more atrophic type than those induced by 1 mg/1 of estradiol. The cortical suppression may be greater than the medullary inhibition. In this respect, the present results seem to support Witschi's opinion (1950, 1951) that the hormonal action on the gonads is of inhibitory nature.

In the present study, when the hormonal treatment was commenced on the 13th day after hatching (Group II), the resultant gonads were modified ovaries with no auxocytes and with thickened ovarian theca. In Group III, the result was nearly similar to that obtained in Group II, except that the auxocytes were

developed in some of the affected ovaries. In Groups I and II, the treatment was begun before the morphological sex differentiation of the gonads had taken place. Accordingly, it may be deemed that one of the chief causes of the difference among the experimental groups is the difference of the time at which the treatment starts. One importance of the time factor in experimental sex differentiation has also been emphasized by Chang (1953) in *Xenopus laevis*.

The malformed development of the limbs is also limited to the animals of Group I. In this case, also, the time factor must be taken into consideration. In the previous study of the toad larvae, the animals were 3 days of age after hatching at beginning of the treatment with 2 mg/l of estradiol (Takahashi 1957b). In the present case, the limb malformation was induced in the group of animals which were exposed to the treatment from the 8th day after hatching. The other groups treated in the later stage never showed the teratological features in the limbs. When the treatment was stopped during the initial period of the treatment, no abnormalities were found in the limb development. On the contrary, when the treatment was continued to late larval period and then was ceased, the limbs did not recover from deformation.

Recently, Nishimura and Kuginuki (1958) reported digital malformations in the mouse fetuses subjected to ethyl-urethan solution by injection into mother mice. They suggested that the critical periods for inducing the skeletal abnormalities fall between the 9th to 12th day after gestation, and that the effect is due to the disturbed organogenesis caused by some mitotic poisoning property of ethyl-urethan.

It is reported that, in mammals, large doses of estrogens inhibit skeletal growth by acting directly upon the growth zone of the bones (cf. Gardner & Pfeiffer 1943). In addition, antimitotic action of excessive dose of estrogens is found on embryonic tissues and organ primordia such as eyeballs and limb buds (Töndury & Cagianut 1951, Töndury 1953). Development of malformed limbs seen in the present study also gives evidence of a toxic action of estradiol. Such an action may be a cumulative one, and the longer the cells maintain embryonic nature, the more they may be liable to injury. In this regard it is interesting that the animals were less masculinized in Group II than in Group I, although the treatment was commenced before the indifferent gonads were formed in both groups.

Thus it may be suggested that there is a critical period, during which the toxic action of a large dose of estradiol is most effective on germinal and somatic elements. In *Rana* sp. in the present study, this critical period can be sought around the 8th day after hatching when the gonad is at the stage of unpaired gonadal fold and the limb buds just appear externally.

### Summary

Tadpoles of a sexually semidifferentiated race of *Rana* sp. (so-called *Rana temporaria* in Hokkaido) were reared in a water solution of estradiol in a dosage of 1.5 mg per litre of rearing water from the 8th, 13th, and 20-25th day after hatching until the late metamorphosis. Following results were obtained:

1. When the treatment was started at the 8th day after hatching, the animals became to have longer larval period than normal one and, at the late metamorphic stage, showed some malformation in the limbs.

2. In this case, gonadal sex differentiation was directed to the male, showing development of atrophic testes as a result of suppressive action of estradiol upon oogenesis and multiplication of the germ cells and, moreover, upon concomitant growth of the medullary tissue.

3. The severe inhibition of gonadal development and the malformed development of the limbs give evidence of a toxic action of estradiol in an exceedingly high dose.

4. In case the tadpoles were exposed to the treatment from 13 days of age or later, no abnormalities were found in the limb development; the masculinizing action was limited to thickening of the wall of ovarian sacs and, at most, to nonformation of auxocytes.

5. The difference between the effects among the treated groups seems to be due chiefly to the difference of the time when the treatment starts. Thus it is suggested that there is a critical period, during which the toxic action of a large dose of estradiol is most effective, in the process of germinal and somatic differentiation.

### Literature

- Bellanca, A. 1954. Sul meccanismo delle azioni mascolinizzanti di alte dosi di estradiolo nelle gonadi di girini di *Rana dalmatina*. Arch. Zool. Ital. 39: 257-293.
- Chang, C.Y. 1953. Parabiosis and gonad transplantation in *Xenopus laevis* Daudin. J. Exp. Zool. 123: 1-28.
- Chang, C.Y. & E. Witschi 1955. Independence of adrenal hyperplasia and gonadal masculinization in the experimental adrenogenital syndrome of frogs. Endocrinology 56: 596-605.
- Gallien, L. 1940. Rôle du solvant et de la méthode d'administration de la di-hydrofolliculine dans la différenciation du sexe chez les Batraciens. C.R. Acad. Sci. 211: 570-571.
- 1941. Recherches expérimentales sur l'action amphisexuelle de l'hormone femelle (oestradiol) dans la différenciation du sexe chez *Rana temporaria* L. Bull. Biol. France Belg. 75: 369-397.
- 1955. The action of sex hormones on the development of sex in amphibia. Mem. Soc. Endocr. 4: 188-204.
- Gardner, W.U. & C.A. Pfeiffer 1943. Influence of estrogens and androgens on the skeletal system. Physiol. Rev. 23: 139-165.
- Nishimura, H. & M. Kuginuki 1958. Congenital malformations induced by ethyl-urethan in mouse embryos. Okajimas Fol. Anat. Jap. 31: 1-10.
- Padoa, E. 1936. Effetto paradossale (mascolinizzazione) sulla differenziazione sessuale di girini di *Rana esculenta* trattati con ormone follicolare. Monit. Zool. Ital. 47: 285-289.
- 1938. La differenziazione del sesso invertita mediante la somministrazione di ormoni sessuali. Ricerche con follicolina in *Rana esculenta*. Arch. Ital. Anat. Embr. 40: 122-172.

- 1942. Il differenziamento del sesso invertito mediante la somministrazione di ormoni sessuali e corticosurrenali. Ricerche con diidrofollicolina, progesterone e acetato di desossicorticosterone, in *Rana esculenta*. Pubb. Staz. Zool. Napoli 19 : 185-223.
- 1950. Grenouilles et stéroïdes. Arch. Anat. Micr. Morph. Exp. 39 : 257-293.
- Takahashi, H. 1957a. Some observations on the masculinizing effect of estradiol upon the larval gonads of *Rana temporaria*. Jour. Fac. Sci. Hokkaido Univ., Ser. VI, Zool. 13 : 423-427.
- 1957b. The malformed development of toad larvae treated with estradiol. Annot. Zool. Japon. 30 : 199-203.
- Töndury, G. 1953. Embryonales Wachstum und seine Störungen. Schweiz. Med. Wochenschr. 83 : 175-180.
- Töndury, G. & B. Cagianut 1951. Zur Wirkung der Sexualhormone auf Wachstum und Differenzierung. Biol. Rev. 26 : 28-58.
- Witschi, E. 1950. Génétique et physiologie de la différenciation du sexe. Arch. Anat. Micr. Morph. Exp. 39 : 215-246.
- 1951. Embryogenesis of the adrenal and the reproductive glands. Recent Progr. Hormone Res. 6 : 1-27.
- 1953. The experimental adrenogenital syndrome in the frog. Jour. Clin. Endocr. Metab. 13 : 316-329.
- 1955. On morphogenic capacities of the estrogens. Ibid. 15 : 647-652.
-