



HOKKAIDO UNIVERSITY

Title	Partial Feminization of Larval Gonads of <i>Hyla arborea japonica</i> Guenther Induced by Treatment with Estradiol (With 11 Text-figures)
Author(s)	TAKAHASHI, Hiroya
Citation	北海道大學理學部紀要, 14(2), 210-221
Issue Date	1959-12
Doc URL	https://hdl.handle.net/2115/27304
Type	departmental bulletin paper
File Information	14(2)_P210-221.pdf



**Partial Feminization of Larval Gonads of *Hyla*
arborea japonica Guenther Induced by
Treatment with Estradiol^{1) 2)}**

By

Hiroya Takahashi

(Zoological Institute, Hokkaido University)

(With 11 Text-figures)

It is a well known fact that the effects of hormone treatment on sex differentiation are variable according to taxonomic groups of amphibians to be tested. Among anuran forms, many species belonging to the family Ranidae form a group with respect to the type of gonadal modification caused by hormone administration during larval period (cf. Gallien, 1955; Witschi, 1957).

Recently, Witschi, Foote and Chang (1958) admitted hylid frogs into the group of ranid ones on the basis of the results of treatment with steroid hormones in a hylid frog, *Pseudacris nigrita triseriata*. In this tree frog, the type of gonadal response to hormone administration closely resembled that in the case of grass frogs in that androgen induced complete masculinization in female larvae and estrogen in a low dosage caused complete feminization in male ones. On the other hand, in the Japanese tree frog, *Hyla arborea japonica*, androgen in a wide range of dosages failed to bring about complete masculinization of larval gonads in females (Takahashi, 1958). This contradictory effect of androgen on the two hylid frogs excited the present writer's interest in studying more extensively the effects of hormone treatment on gonad development in the Japanese tree frog. This paper deals with the effect of treatment with estradiol on sex differentiation and development of larval gonads in *Hyla arborea japonica* Guenther.

The writer wishes first of all to express his cordial thanks to Professor Tohru Uchida under whose constant guidance and encouragement the present study has been performed. The writer is also indebted to Dr. Tomoji Aoto for his invaluable advice. The crystalline hormones used in the present study have been generously supplied by the Teikoku Hormone Mfg. Co., Tokyo.

Material and methods

In June, 1956, the effects of estradiol on sex differentiation of *Hyla arborea japonica* were preliminarily studied by rearing the larvae from a single spawn in aqueous solution of

1) Contribution No. 455 from the Zoological Institute, Faculty of Science, Hokkaido University, Sapporo, Japan.

2) This report has been presented to the faculty of Hokkaido University as a part of a thesis for the degree of Doctor of Science.

Jour. Fac. Sci. Hokkaido Univ. Ser. VI, Zool. 14, 1959.

estradiol at a dosage of 200 μg per liter of aquarium water. The treatment was continued for 56 days, starting at the stage just after hatching and continuing up to the late larval stage. Gonads of 34 treated animals and those of 33 control animals, both out of 40 at the time of starting the treatment, were histologically examined at the end of the treatment.

In early July, 1958, pairing adults of the tree frog were collected in the vicinity of Sapporo. Some of these pairs laid eggs within the next 24 hours, and the larvae from a single spawn thus obtained were used for the study. They were fed on boiled vegetables. The temperature of aquarium water ranged from 21° to 27°C during the period of this experiment.

Crystalline hormones were previously dissolved in 95% ethyl alcohol and then added to aquarium water, which was changed every other day. Forty larvae each were raised in solutions of 100, 400 and 800 $\mu\text{g}/\text{l}$ of estradiol, while 40 other animals served as controls. Besides these, another lot of 30 larvae was treated with 500 $\mu\text{g}/\text{l}$ of methyltestosterone in the same manner as in the case of estradiol treatment. Administration of the hormones was performed extending from the eighth day after hatching to the end of metamorphosis of control and experimental animals.

These animals were fixed with Bouin's fluid at the end of treatment. Their gonads and mesonephroi were serially cut 10 μ in thickness and stained with Delafield's hematoxylin and eosin.

Experimental results

1. Results of preliminary experiment in 1956

At the time of fixation, sex differentiation of gonads had been completed and 33 control animals examined were separable into 15 females and 18 males.

Out of 34 animals treated with 200 $\mu\text{g}/\text{l}$ of estradiol, 18 were females with ovaries showing neither acceleration nor repression in development. Among the remaining 16 larvae which could be statistically regarded as genetic males, 9 were provided with gonads of smaller size as compared with ovaries. These gonads had some resemblance to testes in gross appearance, but histologically the peripheral region of the gonads could be discriminated from the central region in that the latter was much more rich in interstitial cells than the former. Further, in a few cases, germ cells in the premeiosis stage were found among gonial germ cells in the peripheral region, while in the central region were included germ cells exclusively of the gonial stage. Accordingly, these gonads were judged to be those of an intersexual type, which were composed of both the peripheral ovarian region and the central testicular one. Gonads of the other 7 animals were testicular in structure. When compared with testes of control males, however, these gonads were clearly smaller in size and retarded in structural differentiation. Detailed observation disclosed that the typical testicular features were occasionally lacking on the periphery, where some vestigial structures like a primitive cortex remained in part. Such features in testes might be the first sign of the intersexual phase detained in developing testes as a result of continuous treatment with estradiol.

From the above results, the writer was led to the conclusion that the

administration of estradiol hinders the normal testicular differentiation of gonads and occasionally brings about incomplete feminization of genetic male larvae, by transforming testicular gonads into gonads of an intersexual type.

Table 1. Summary of experiments with estradiol in *Hyla arborea japonica* studied in 1958

♀₁ Females with well developed ovaries. ♀₂ Females with ovaries showing slight retardation in development. ♂₁ & ♂₂ Animals with intersexual gonads. ♂ Males with definite testes. El. Estradiol.

Group	Number of animals at start	Duration of treatment (days)	Sex distribution examined at the end of metamorphosis					Total
			♀ ₁	♀ ₂	♂ ₁	♂ ₂	♂	
El. 800 μg/l	40	37-39	1	7		4	2	14
		42-46	1	6	1		6	14
		48-52	4	3			3	10
		Total	6	16	1	4	11	38
El. 400 μg/l	40	37-39	3	3	4	1	6	17
		42-46	4	4	2	1	3	14
		52	3	1	1		3	8
		Total	10	8	7	2	12	39
El. 100 μg/l	40	37-39		7	6		4	17
		42-44	4	5	1		2	12
		52	6	1			3	10
		Total	10	13	7		9	39
Control	40	(44-46)*	3	1			3	7
		(49-51)*	6	1			6	13
		(56-58)*	9	4			5	18
		Total	18	6			14	38

* The numerals in the brackets indicate the age of animals after hatching at the time of fixation, corresponding each to the time of fixation of treated animals.

2. Results of experiment in 1958

Administration of estradiol in every dosage level used in the present study exerted no notable influences upon body growth and metamorphosis of the tree frog larvae. Mortality was low in all the groups studied.

The larvae at the time of starting the treatment had primordial gonads with a small number of primordial germ cells and somatic cells, being in the stage before formation of the sexually indifferent gonad. Sex distribution in control and experimental groups at the time of fixation is shown in Table 1. In this table, females are classified into two types according to the degree of ovarian

development which is revealed mainly in formation and growth of auxocytes.

a) Control group

At the end of metamorphosis, both ovaries and testes of control animals were in the well differentiated state. In males, some of the testes showed signs of formation of seminal tubules (Fig. 1). In females, all the ovaries were provided with various numbers of auxocytes and with well defined ovarian sacs (Fig. 2).

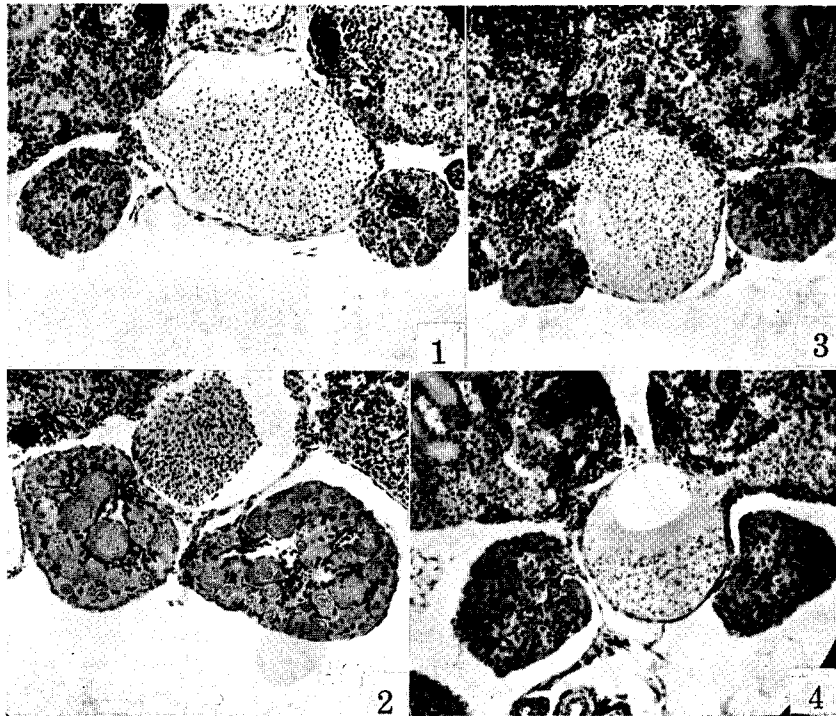


Fig. 1. Cross section through testes of a control male. $\times 85$.

Fig. 2. Cross section through ovaries of a control female. $\times 85$.

Fig. 3. Cross section through intersexual gonads of an animal treated with $800 \mu\text{g/l}$ of estradiol, showing actively proliferated germ cells in the peripheral region of gonads. $\times 85$.

Fig. 4. Cross section through intersexual gonads of an animal treated with $100 \mu\text{g/l}$ of estradiol. In this section, ovarian character of these gonads is manifested by appearance of some primary oocytes. $\times 85$.

As shown in Table 1, a moderate excess of females was noticed in the control group. It should be remarked that *Hyla arborea japonica* in Sapporo belongs to the differentiated type with respect to gonadal sex differentiation (Takahashi,

1958). Furthermore, in the present case, no tendencies of sex reversal were detectable in the females and males at the time of fixation.

b) Groups of animals treated with 100, 400 and 800 $\mu\text{g/l}$ of estradiol

The animals subjected to the treatment with estradiol from the eighth day after hatching to the end of metamorphosis could be divided into three types in regard to histological features of their gonads, irrespective of the concentrations of hormone used in the present study.

In animals of the first type (♂ in Table 1), differentiation of testes was evident. However, the testes were generally smaller in size as compared with control testes and the majority were in the state before formation of seminal tubules, lagging clearly in development behind those of control males (Fig. 5). The retardation of testicular development appeared to become more conspicuous in higher dosage group than in lower dosage group of the present estradiol treatment.

Such a tendency of suppression of gonad development could be seen also from a comparison of histological features of ovaries in animals of the second type (♀_1 and ♀_2 in Table 1). In these animals, no accelerated development of ovaries was caused through the influence of estradiol in any dosage levels used. Contrarily, when compared with control ovaries, slight repression of oogenesis in affected ovaries was indicative of the inhibiting action of estradiol on ovarian development. It was remarked that, in the experimental groups, individual differences in degree of ovarian development were generally greater than those observed in the control group. This unevenness of ovarian development became more pronounced as the hormone dosage was intensified. However, the suppression of ovarian development was not followed by structural changes suggestive of masculinization of gonad, even in the 800 $\mu\text{g/l}$ group.

Treated animals of the third type, designated as $\text{♀}'_1$ and $\text{♀}'_2$ regarding histological aspects of their gonads in Table 1, were provided with gonads in an intersexual phase of sex inversion. These gonads bore some resemblance to testes: they were various in size but rather smaller than control ovaries and were compactly filled up with germ cells; they bore no trace of ovarian sac (Fig. 3). On the other hand, superficial distribution of blood vessels, which is characteristic of typical testes, was also indiscernible in these gonads (compare Figs. 3 and 6-9 with Figs. 1 and 5).

These gonads were composed of two zones: the central zone was much more rich in interstitial cells than the peripheral zone which had a large number of germ cells as the predominant constituent (Figs. 6 and 7). It was also a peculiarity of the latter zone that the mitotic division of germ cells was very active. In the central zone, somatic cells surrounded several gonial germ cells without definite arrangement, forming a region discernible from the periphery. While the peripheral zone was occasionally invaded by rows of somatic cells originating from the central zone, the former zone was always retained as a thick, compact layer of germ cells, showing a structure that suggests a primitive gonadal cortex

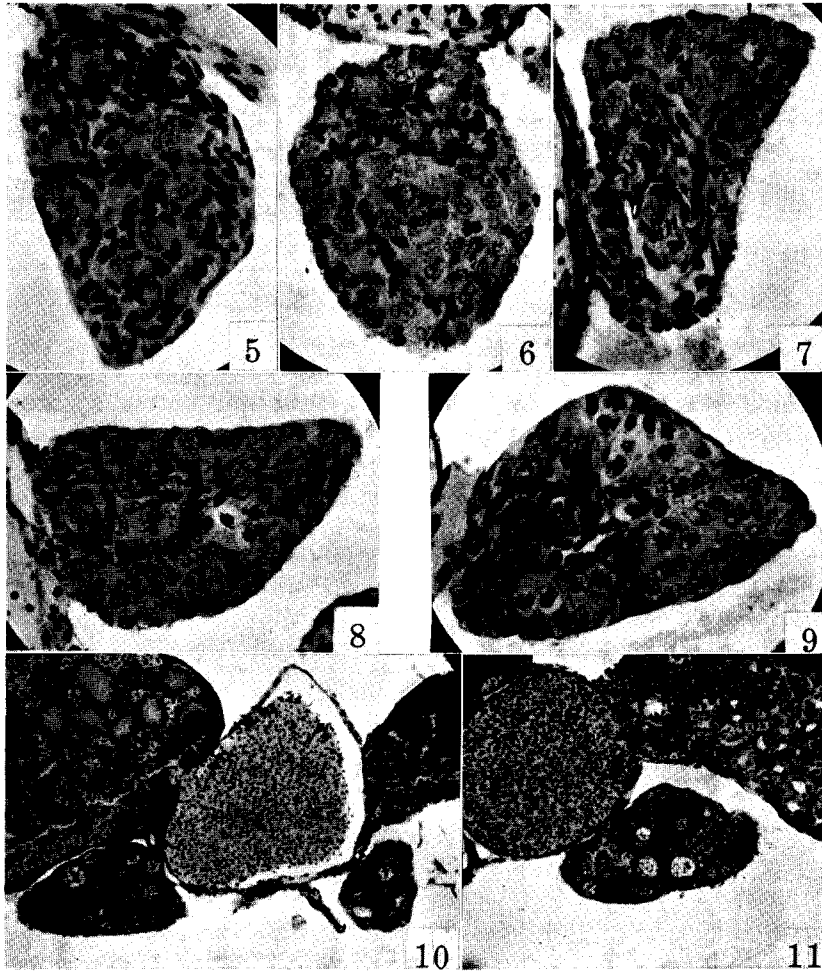


Fig. 5. Cross section through testis of a male treated with 100 $\mu\text{g}/\text{l}$ of estradiol. $\times 260$. Figs. 6-9. Cross sections through intersexual gonads of animals treated with estradiol. 6, 800 $\mu\text{g}/\text{l}$ group; 8, 100 $\mu\text{g}/\text{l}$ group; 7 and 9, 400 $\mu\text{g}/\text{l}$ group. Peripheral ovarian zone (cortex) and central testicular zone (medulla) are noticeable in these sections. Involution of medullary elements is not followed by formation of ovarian sac. $\times 260$. Figs. 10 and 11. Cross sections through modified ovaries of animals treated with 500 $\mu\text{g}/\text{l}$ of methyltestosterone, showing incomplete masculinizing changes of ovaries. Note the predominant persistence of ovarian structure in spite of remarkable hypertrophy of medulla. $\times 85$.

hypertrophied abnormally. In some animals of the third type (♀_2 in Table 1) the gonads kept in their peripheral zone the germ cells exclusively in the gonial stage (Figs. 6 and 7), while in the other animals of the third type (♀_1 in Table 1) the gonads were possessed of some germ cells in the premeiosis stage interspersed among gonial germ cells, though many of these oocytes had formed an appearance of very small nests (Figs. 4, 8 and 9).

Thus it seems fully probable that the peripheral zone is potentially ovarian whilst the central one is potentially testicular in nature, and that the gonads under question are an outcome of the process of transformation of testes into ovaries. Then, it is concluded that in the present study the administration of estradiol produced a partial and incomplete feminization of genetic males in *Hyla arborea japonica*, regardless of the dosages used. Furthermore, it seems worthy to be noted that the treatment with estradiol especially in a dose of $800 \mu\text{g/l}$ caused the retardation of gonad development, but did not show any signs of masculinizing or amphisexual action of the estrogen, bringing about a partial feminization at a rate of appearance of the intersexual animals similar to that by the other doses of the estrogen. An attempt to observe the action of more intense dosages of estradiol ($1000\text{--}1500 \mu\text{g/l}$) ended unfortunately in a failure, because of unexpected high mortality in the experimental animals. In these cases, however, inhibition of gonad development, which sometimes prevented the discrimination of sex, was generally observed, but differentiation of ovaries was noticed in some survivors at the end of metamorphosis.

Hyperplastic development of adrenal tissue was observed in the treated animals except those of the $100 \mu\text{g/l}$ group (Fig. 3), though the adrenal hyperplasia was rather slight in degree in the animals of the $400 \mu\text{g/l}$ group.

c) *Groups of animals treated with $500 \mu\text{g/l}$ of methyltestosterone*

Administration of methyltestosterone in a dosage of $500 \mu\text{g/l}$ failed to induce complete masculinization of genetic female larvae of the present species. Although the results were essentially in accord with those reported in a previous paper (Takahashi, 1958), the present treatment was effective in producing more pronounced modification of ovarian development than the previous treatment with androgens.

Out of 27 animals examined at the end of metamorphosis, 16 had gonads of predominantly ovarian structure. In these gonads, without exception, oogenesis had proceeded so as to form some auxocytes. On the other hand, the oocytes were smaller in number as compared with those in control ovaries, then affected ovaries were generally diminished in size. Clear indications of destruction of cortical tissue such as oocyte degeneration could be observed only upon rare occasions. However, the affected ovaries were provided with a compact mass of medullary tissue which completely occluded the region of the ovarian sac (Figs. 10 and 11). The hypertrophied medulla included in many cases either gonial germ cells or auxocytes.

Differentiation of testes was evident in the remaining 11 animals out of 27 examined in this group. However, development of the testes was not accelerated but appeared to be inhibited rather than unaffected by the androgen treatment. The testes were small in size and in length, and formation of the seminal tubule anlage was observed in much fewer cases than in controls.

As seen from the above-mentioned results, the treatment with methyltestosterone from the stage before sex differentiation of gonad occurs is incapable of bringing about complete masculinization of genetic female larvae and results at most in the change of ovaries into an intersexual structure in *Hyla arborea japonica*. This is in striking contrast with the well-known results of androgen treatment in grass frogs.

Adult males of the Japanese tree frog bear a small pad-like swelling on the base of the thumb as a secondary sex character. The present treatment was effective in inducing precocious development of such a character as well as typical masculine muscular development of the arm in all the metamorphosing animals.

Discussion

In regard to the effects of estrogen on sex differentiation of anuran amphibians, many workers have so far been in agreement that estrogen causes feminization of genetic males when administered in an adequate dosage through the larval period (cf. Gallien, 1955). Such is also the case for tree frogs (Hylidae), though few studies have hitherto been made on this group of frogs. In 1958, Witschi, Foote and Chang reported the feminization of genetic male larvae of a tree frog, *Pseudacris nigrita triseriata*, subjected to treatment with 50 $\mu\text{g/l}$ of estradiol. The aforementioned results of estradiol treatment in *Hyla arborea japonica* also confirmed the feminizing capacity of estrogen in tree frog larvae.

The occurrence of gonadal feminization is generally characterized by development of cortical elements associated with regression of medullary ones. These changes are manifested by a beginning of oogenesis in the gonadal cortex and by formation of an ovarian sac in the gonadal medulla. The case of feminization in the present study may be peculiar judging from these respects: in the resultant intersexual gonads, the medullary region was composed of several germ cells enclosed by somatic cells and showed no sign of transformation into ovarian sac; the cortical region was occupied by a large number of germ cells which were predominantly in the gonial stage. Excessive proliferation of germ cells in the cortex especially appeared to furnish a peculiar feature to the intersexual gonads. In other words, the feminizing effect of estradiol seems to be revealed most impressively in extraordinary multiplication of cortical germ cells.

Then the question arises as to whether the cortical hypertrophy is due to compensatory development resulting from medullary regression or to some direct stimulating effect of estrogen on cortical development. Witschi and his collaborators emphasized consistently that the mode of action of steroid hormones is

inhibitive in nature on both gonadal constituents, the medulla and the cortex, and that sex inversion of the gonad is attributable to the changes in antagonistic relationship between the cortex and the medulla induced by disproportioned suppression on the two gonadal elements (Witschi, 1950, 1957). On the contrary, Vannini (1946, 1950) asserted that estradiol has stimulating action on development of gonadal cortex in frogs. Further, there is a suggestion made by Padoa (1950), who stated that normal and experimentally induced sex differentiation may result from stimulation of development of one component and from inhibition of that of another component of gonad.

In the present cases of estradiol treatment, suppression of growth of the medullary component was more or less noticeable in any of the dosage series employed. Indeed, the inhibition seemed to be reflected also in retardation of testicular development in treated males. It should be emphasized, however, that the feminization of male gonads in the present case is characterized by an excessive proliferation of gonial germ cells in the cortex, and that such a feature of cortical development has never been observed in the course of normal ovarian differentiation in the present species. Accordingly, this phenomenon cannot necessarily be regarded simply as an expression of compensatory growth of the cortex consequent on medullary involution. In this connection, the observation made by Asayama and Miyamori (1957) in a salamander, *Hynobius nebulosus*, would be interesting to note. Treating the larvae with 330-660 $\mu\text{g}/\text{l}$ of estrone, they found an excessive proliferation of germ cells in the gonadal cortex, and stated that "the sex modification of larval gonads is brought about by an active growth, not by compensatory growth of the cortical layer."

It is of interest in another connection to note that, while the administration of estrone in *Hynobius nebulosus* caused acceleration of auxocyte growth in affected ovaries, the treatment with estradiol in *Hyla arborea japonica* did not promote but rather retarded the ovarian development in every dosage level used. In ranid anurans, some reports have offered the evidence of a stimulating effect of estrogen on ovarian development (Gallien, 1938; Bellanca, 1954). In the present study, however, the suppression of gonad development could be detected both in testes and ovaries, and it was more effectually evidenced in higher dosage level of the hormone than in lower one. So far as the writer's observations are concerned, it is not only estrogen but also androgen and adrenal cortical hormone that arrests to a certain degree the normal growth and development of gonad as a whole when they are administered in intense dosages (Takahashi, 1958; Uchida and Takahashi, 1959). Further, the more the dosage of hormone is intensified and the longer the hormonal treatment is prolonged, the more marked the inhibition seems to become. Thus the writer is of opinion that the suppression of gonad development can be considered as a rather general manifestation of toxic action of administered substances.

In the present study, the suppressing influence on ovarian development was

mainly noticed in a hindrance of development of primary oocytes into auxocytes. On the other hand, in the case of intersexual gonads produced by the estradiol treatment, while the checking of maturation of cortical germ cells was detected especially in higher dosage group, an extraordinary proliferation of the germ cells was observable regardless of the dosages of hormone used. Accordingly, it may be considered in the present case that the proliferation and the maturation of cortical germ cells are controlled by different intrinsic factors, upon which experimental procedures may act in different manner.

In ranid frogs, treatment with estrogen tends to induce different terminal effects depending on dosages used: feminization is induced in lower dosage levels, whereas masculinization is caused in higher ones (Padoa, 1942; Padoa and Vegni Talluri, 1951; Witschi, 1953). According to Witschi, Foote and Chang (1958), the results of estrogen treatment in a hylid frog, too, was dependent upon the dosages of hormone: in *Pseudacris nigrata triseriata*, complete feminization was realized by 50 $\mu\text{g}/\text{l}$ of estradiol, whereas the sex ratio was nearly normal in the group of animals treated with 100 $\mu\text{g}/\text{l}$ of estradiol mixed with 200 $\mu\text{g}/\text{l}$ of estrone. In *Hyla arborea japonica*, however, partial feminization of genetic males was the common result of estradiol treatment in doses of 100, 400 and 800 $\mu\text{g}/\text{l}$, showing no difference among the experimental groups at least with respect to the rate of occurrence of the intersexual animals. In this regard the present results have some resemblance to those obtained by Gallien and Collenot (1958) in *Pelodytes punctatus* in which partial feminization was the common result of treatment with estradiol benzoate in doses of 50 and 500 $\mu\text{g}/\text{l}$.

It is still open to question in the present species whether or not the feminizing effect is temporary and whether paradoxical masculinization of female gonad can be brought about by treating larvae with more intense doses of estrogen than those in the present case. It must be noted, however, that the occurrence of suppression of ovarian development cannot be regarded as a manifestation of a tendency of paradoxical masculinization induced by estrogen treatment.

The characteristic nature of *Hyla arborea japonica* in the type of gonadal response to hormone treatment is detectable also in the result of treatment with methyltestosterone. The masculinizing effect was confined to causing transformation of ovaries into gonads of an intersexual type. This is in marked contrast with the well-known cases in ranid frogs in which masculinization by androgen is complete in a wide range of dosages of hormone. In the present hylid frog, however, the androgen treatment induced the medullary hypertrophy and the cortical regression which is revealed chiefly in diminution in number of germ cells, and these may signify that the type of gonadal response to hormone treatment is rather close to that in ranid frogs. Thorough analysis of the characteristic nature of *Hyla arborea japonica* may contribute to clarifying the mechanism of the effect of taxonomy in the hormonal effects on sex differentiation and gonad development in amphibians.

Summary

Larvae of the tree frog, *Hyla arborea japonica* were reared in aqueous solutions of estradiol in doses of 100, 400 and 800 $\mu\text{g}/\text{l}$ from the eighth day after hatching to the end of metamorphosis, and their gonads were examined histologically at the end of treatment.

In these groups, differentiation of testes was observable in some males, though the testes were rather retarded in development as compared with those of controls. In the other treated males, the treatment modified the testicular development and gave rise to transformation of testes into gonads of an intersexual type. An excessive multiplication of gonial germ cells in the cortex provided the chief feature of gonadal feminization, which was suggestive of a stimulating influence of estradiol on proliferation of cortical germ cells. Some of the cortical germ cells in these intersexual gonads were in the premeiosis stage, but there could be found no trace of ovarian sac formation in the medullary region. It was remarked that the partial feminization was the common result of the estradiol treatment irrespective of the dosages of hormone used.

Development of ovaries in genetic females was not accelerated but rather suppressed by the treatment especially in higher dosage group without being followed by the occurrence of any masculinizing changes in the affected ovaries.

Another group of the tree frog larvae received treatment with methyltestosterone in a dosage of 500 $\mu\text{g}/\text{l}$ during the same period as the estradiol treatment. The procedures failed to induce complete masculinization of genetic females, only causing the change of ovaries into intersexual gonads in which the ovarian structure was still predominant. The result of the androgen treatment was essentially in accord with that reported in a previous paper (Takahashi, 1958).

Literature cited

- Asayama, S. & H. Miyamori 1957. Responses of larval gonads in *Hynobius nebulosus* to the administration of estrogen. Jour. Inst. Polytech. Osaka City Univ., Ser. D, 8: 129-137.
- Bellanca, A. 1954. Sul meccanismo delle azioni masculinizzanti di alte dosi di estradiolo nelle gonadi di girini di *Rana dalmatina*. Arch. Zool. Ital., 39: 257-293.
- Gallien, L. 1938. Action des hormones sexuelles dans la différenciation du sexe chez *Rana temporaria* L. Bull. Biol. France et Belg., 72: 269-296.
- 1955. The action of sex hormones on the development of sex in amphibia. Mem. Soc. Endocr., 4: 188-204.
- Gallien, L. & A. Collenot 1958. Inversion totale (féminisation) du sexe chez *Pelobates cultripipes* Cuv. et féminisation partielle des gonades (intersexualité) chez *Pelodytes punctatus* Daud., à la suite d'un traitement gynogène par le benzoate d'oestradiol, administré pendant la vie larvaire. C.R.Acad. Sc., 247: 1042-1044.
- Padoa, E. 1942. Il differenziamento del sesso invertito mediante la somministrazione di ormoni sessuali e corticosurrenali. Ricerche con diidrofollicolina, progesterone e acetato di desossicorticosterone, in *Rana esculenta*. Pubbl. Staz. Zool. Napoli, 19:

- 185-223.
- 1950. Grenouilles et stérols. Arch. Anat. Micr. Morph. Exp., 39 : 314-336.
- Padoa, E. & M. Vegni Talluri 1951. Estrone, progesterone e differenziamento sessuale in *Rana esculenta*. Arch. Ital. Anat. Embr., 56 : 349-372.
- Takahashi, H. 1958. Gonadal reaction in the tree frog larvae (*Hyla arborea japonica* Guenther) to the androgen. Jour. Fac. Sci. Hokkaido Univ., Ser. VI, Zool., 14 : 92-99.
- Uchida, T. & H. Takahashi 1959. A comparison of the effects of desoxycorticosterone on gonadal development between the two anuran species. Arch. Anat. Micr. Morph. Exp., 48 bis : 285-295.
- Vannini, E. 1946. Sex differentiation in amphibia. Nature, 157 : 812-813.
- 1950. Organogénèse des gonades et déterminisme du sexe chez les amphibiens et les amniotes. Arch. Anat. Micr. Morph. Exp., 39 : 295-313.
- Witschi, E. 1950. Génétique et physiologie de la différenciation du sexe. Ibid., 39 : 215-246.
- 1953. The experimental adrenogenital syndrome in the frog. Jour. Clin. Endocr. Metab., 13 : 316-329.
- 1957. The inductor theory of sex differentiation. Jour. Fac. Sci. Hokkaido Univ., Ser. VI, Zool., 13 : 428-439.
- Witschi, E., C.L. Foote & C.Y. Chang 1958. Modification of sex differentiation by steroid hormones in a tree frog (*Pseudacris nigrita triseriata* Wied). Proc. Soc. Exp. Biol. Med., 97 : 196-197.
-