



# HOKKAIDO UNIVERSITY

Title	Lymphoid Changes in <i>Xenopus laevis</i> Following Thymectomy at the Initial Stage of Its Histogenesis (With 1 Table and 2 Plates)
Author(s)	TOCHINAI, Shin
Citation	北海道大學理學部紀要, 20(2), 175-182
Issue Date	1976-04
Doc URL	<a href="https://hdl.handle.net/2115/27600">https://hdl.handle.net/2115/27600</a>
Type	departmental bulletin paper
File Information	20(2)_P175-182.pdf



# Lymphoid Changes in *Xenopus laevis* Following Thymectomy at the Initial Stage of Its Histogenesis

By

**Shin Tochinai**

Zoological Institute, Hokkaido University

(With 1 Table and 2 Plates)

Experimental analysis of the thymus in the development of the immune system of the toad, *Xenopus laevis*, has been exploited by Horton and Manning (1972), who thymectomized the stage 48 (8 days old) larvae without disturbance of the animals' growth. Thus the dependence on the thymus of antibody production against sheep erythrocytes and human gamma globulin (Turner and Manning, 1974) was demonstrated, although the ability to reject allografted skins was not totally impaired (Horton and Manning, 1972). Experiments from our laboratory (Tochinai and Katagiri, 1975) have shown that thymectomizing *Xenopus* at stage 45 (4 days old) completely abrogates not only their humoral response to rabbit erythrocytes (RRBC) but also their rejection of skin allografts, providing strong evidence that the period of 4 days between stages 45 and 48 is critical with respect to the functioning of the thymus for the establishment of alloimmune responsiveness in this animal.

On the other hand, research into the lymphoid histogenesis in relation to thymectomy in a number of amphibians (Du Pasquier, 1968; Manning, 1971; Tournefier, 1973; Horton and Manning, 1974; Charlemagne, 1974) has exposed to the rather surprising feature that a relatively normal development of the lymphoid system is observable in the thymectomized animals. It should be remembered that the thymus-dependency of the lymphoid differentiation, if any, can best be studied in cases where the abrogation of immune responsiveness is well defined. In this respect, a comparison of the lymphoid development after thymectomy at stages 45 and 48 of *Xenopus* will provide information of value for understanding the extent of the thymic function during this important period.

The present study was intended to correlate the lymphoid system development with the failure of the immune response in our thymectomized toads. The splenic histology accompanying the thymus-independent humoral response (Tochinai, 1976) will also be described.

### Material and Methods

*Material:* The material used was the South African clawed toad, *Xenopus laevis* (Daudin), from a colony which, as stated previously (Tochinnai and Katagiri, 1975), shares histocompatibility gene(s). Fertilized eggs were obtained by hormonally induced matings. Embryos and larvae were allowed to develop in aerated aquaria at 23°C. The developmental stages were determined according to the normal table of Nieuwkoop and Faber (1956). Tadpoles and metamorphosed animals were fed boiled alfalfa leaf powder and chopped liver, respectively.

Eight thymectomized- and 10 unoperated larvae of stage 56 were studied for their lymphoid tissues in the branchial region, alimentary tract, spleen, liver and mesonephros. Using 7 early-thymectomized- and 10 non-thymectomized toads, examinations were also made of the lymphoid tissues in the spleen, liver, kidney, bone marrow of the femur, and alimentary tract. For the gross and histological examinations, the spleens were dissected out of 18 RRBC-injected toads (8 thymectomized and 10 non-thymectomized) and 15 polyvinylpyrrolidone (PVP)-injected toads (6 thymectomized and 9 non-thymectomized).

*Thymectomy and Antigen Injection:* Bilateral thymectomy was carried out on the larvae at stage 45 (4 days after fertilization) according to the method described previously (Tochinnai, 1975b). After the operation, the larvae were placed overnight in Steinberg's solution containing antibiotics (100,000 IU/1 penicillin G and 0.1 g/l streptomycin sulfate). From the next day onward, the larvae were raised under the usual conditions. Frequent observations were made on the thymic regions of the operated larvae, to check for the absence of thymic remnant. The sham-operation was not set up in the present study, since the previous experiments (Tochinnai and Katagiri, 1975) showed no difference in the immune reactivities between sham-operated- and unoperated toads.

Thymectomized- and unoperated toads of 3-12 months after metamorphosis were injected with either RRBC or PVP, according to the methods described previously (Tochinnai and Katagiri, 1975; Tochinnai, 1976). The toads received 3 injections of each antigen, and were sacrificed 4 weeks after the last antigen injection, when the serum antibody titer was highest. The absence of the thymus was ascertained by autopsy, and the spleens were dissected for histological processing.

*Histology:* All the specimens for the histological study were fixed in Bouin's solution. They were embedded in paraffin by the methyl benzoate-paraffin method, serially sectioned at 6-8  $\mu\text{m}$  in thickness, and stained with Delafield's hematoxylin and eosin.

### Results

Thymectomy at stage 45 did not affect the growth rate of the animal, and thymusless tadpoles completed metamorphosis normally (Tochinnai, 1975b). In the histological aspects the early thymectomy affected the lymphoid tissues in

various degrees, according to the age of the animals and the type of organs, as described below.

#### *Larval gill-associated lympho-epithelial tissue (LET) bodies*

Of the 4 pairs of ventral cavity bodies (VCBs) and 2 pairs of dorsal cavity bodies (DCBs) in the larval branchial region (*cf.* Tochinai, 1975a), the anterior DCBs suffered the severest effect by thymectomy. In fact, no thymectomized larvae possessed these bodies. The effect was also evident in VCBs (Figs. 1 and 2) and the posterior DCBs (Figs. 3 and 4), although small lymphoid aggregations were occasionally discernible, particularly in the latter.

#### *Gut-associated LET bodies*

The larval gut-associated LET bodies (*cf.* Tochinai, 1975a) were affected by thymectomy: they were depleted considerably in number, size and degree of lymphoid invasion into the gut epithelium (Figs. 5 and 6). In contrast to the situation in larvae, the LET bodies along the alimentary tracts in the thymectomized toads were not obviously different from those in the non-thymectomized ones, either in their number or histological appearance (Figs. 7 and 8).

#### *Spleen*

During the larval stages, the spleen undergoes an increase in both its volume and the degree of white pulp-branching (*cf.* Manning and Horton, 1969). Because of this relative immaturity and the paucity of lymphoid population even in the unoperated larvae, the effect of thymectomy on the larval spleen was not clearly discernible.

For the metamorphosed toads, the size of the spleen was determined by taking the diameters of the sections passing through the broadest parts of the organs (Table 1). As indicated in the table, the overall size of the spleen varied among individuals even in the non-thymectomized and non-immunized animals, probably reflecting the variability of the myelopoietic- and lymphopoietic activities of this organ. A comparison of the values between thymectomized- and non-thymectomized toads, both before and after the antigenic challenge, revealed that neither the early thymectomy nor the antigenic stimulations had a significant effect on the spleen size.

However, the effect of thymectomy was evident on the histological features of the toad's spleen. In the thymectomized and non-immunized toads, the depletion of small lymphocytes was significant in the white pulp, leading to a reduction in the proportion of white- to red pulp areas in sections. It should be noted that a certain amount of small lymphocytes were still present in the white pulp. In the red pulp of thymusless toads, the depletion of lymphocytes was severer than in the white pulp so that lymphocytic aggregations were hardly observable.

The effect of thymectomy was pronounced when spleens of non-thymectomized-

Table 1. Measurement of the diameters (mm) of spleens on sections from early-thymectomized- and non-thymectomized toads, before and after injection of antigens.

Antigen	Non-thymectomized toads		Early-thymectomized toads	
	No. of animals	MEAN±S.D. (Range of values)	No. of animals	MEAN±S.D. (Range of values)
None (control)	10	1.95±0.42 (1.31-2.93)	7	1.81±0.43 (1.29-2.71)
RRBC	10	2.22±0.59 (1.62-3.32)	8	1.97±0.50 (1.55-2.81)
PVP	9	1.89±0.45 (1.33-2.86)	6	1.67±0.20 (1.27-1.91)

Student t-test revealed that there is no significant difference between these values.

and early-thymectomized toads were compared after they had received antigens. After receiving RRBC, a striking increase of the lymphocytic population occurred in both red- and white pulps of unoperated toads (Fig. 9). In contrast, virtually no response was observed in lymphocyte-depleted spleens of thymectomized toads (Fig. 10), providing a histological support for the previous observation (Tochinai and Katagiri, 1975) that the early-thymectomized toads fail to produce specific antibodies against RRBC.

It was recently shown that the early-thymectomized toads produce antibodies against PVP, as non-thymectomized toads do (Tochinai, 1976). Examination of the spleens of thymectomized and PVP-injected toads revealed the enlargement of the white pulp in association with the lymphocytic accumulation, in a similar degree to that found in non-thymectomized counterparts. In the splenic red pulp of thymectomized toads, however, lymphoid aggregations were hardly observable, in contrast with those which were highly developed in the non-thymectomized and PVP-injected ones (Figs. 11 and 12).

In summary, it can be said that the lymphocytic accumulation in the splenic white pulp corresponded well with the occurrence or absence of the humoral antibody response. On the other hand, the depleted lymphoid population in the red pulp of thymectomized toads was entirely unaffected by any antigenic challenge, even when a humoral antibody response was elicited.

#### *Other organs*

Lymphoid aggregations in the kidney and liver of larvae and adults are fairly variable, both in number and size, even in non-thymectomized animals. Nevertheless, in the thymectomized animals, the degree of these aggregations usually tended to be reduced. As in the observation by Horton and Manning (1974), bone marrow developed in a quite normal fashion in thymectomized toads.

*Notes on a disease associated with thymectomy*

Besides the above mentioned lymphoid aplasia, some comment should be given of the histological aspects of the thymusless toads which died of a particular syndrome. Lesions in the liver and lung were evident in these toads. In the liver, areas of focal necrosis with conspicuous melanin granules and basophilic debris were found, together with many monocytic cells (Fig. 13). The lesions found in the liver are thus similar to those observed in the "wasting" *Alytes* (Du Pasquier, 1968) and *Pleurodeles* (Charlemagne, 1974) as a result of thymectomy. Besides the liver, the alveoli of the attacked area of the lung were filled with blood including a number of monocytic cells. Quite unexpectedly, lymphoid aggregations were observed in the septa of necrotic lungs (Fig. 14). Another characteristic of this syndrome was an increase in the volume of the spleen: this was mainly caused by an increase of the red pulp area which contained an exceedingly large number of monocytic cells, as well as the cells of the erythrocytic series. This syndrome, although not occurring so frequently as in thymusless mammals (*cf.* Azar, 1964), arouses interest as an indication of the depressed immunological reactivity in our thymectomized toads against microorganisms, to which the intact animals will react more quickly and effectively.

**Discussion**

The present study shows that, despite the lack of the thymus since stage 45 (4 days after fertilization), the larvae and adult toads display lymphoid histogenesis to a certain degree. The extreme and consistent effect of thymectomy was confined to the total loss of anterior DCBs and the significant reduction of lymphocytes from the splenic red pulp of adult toads. This observation is essentially similar to that by Horton and Manning (1974) on *Xenopus*, who gave a full account of the lymphoid histogenesis after thymectomizing larvae at stage 48 (8 days old), although the degree of lymphoid depletion is apparently severer in the present study. The difference in the extent of lymphoid depletion between the toads thymectomized at stages 45 and 48 will probably reflect the degree of thymic function during the 3 day interval. For our thymectomized toads, the possibility is hardly conceivable that the "seeding" or peripheralization of thymus-derived cells had occurred before thymectomy, since the thymus, when extirpated, was only rudimentary, comprising less than 100 epithelial cells (Tochinai, 1975b) and the operated toads showed a complete abrogation of the immune response to skin allografts and RRBC (Tochinai and Katagiri, 1975). It should be emphasized that, even under this minimal (possibly non-existent) influence by the thymus, no selective absence of lymphocytes was defined in any particular areas of the peripheral lymphoid organs such as the periarteriolar lymphoid sheath of the mammalian spleen (*cf.* de Sousa, 1973). As postulated by Manning (1971), *Xenopus* is equipped with relatively primitive lymphoid organs and therefore lacks clearly delineated areas where only thymus-derived cells accumulated.

In the urodeles, *Triturus alpestris* (Tournefier, 1973) and *Pleurodeles waltlii* (Charlemagne, 1974), the lymphoid differentiation was reported to be relatively normal even if their ability to reject skin allografts was completely impaired by thymectomy. For the other anuran species (*cf.* Du Pasquier, 1973), the extent of thymus-dependency of both lymphoid histogenesis and immune reactivities is at present not well defined, because the lymphocyte peripheralization before thymectomy cannot be denied. In any event, the subnormal level of lymphocytic population, no matter where it originates from, may suffice to explain the relative resistance of the thymusless amphibians to antigenic challenge from the environment (*cf.* Du Pasquier, 1973; Manning, 1975).

A comparison of the histological features in the spleens before and after antigen injections into early-thymectomized toads provides an insight into the thymus-dependency of lymphoid tissues in immune responses. Thus, when the thymusless toads respond to a thymus-independent antigen such as PVP (Tochinai, 1976), there is a significant increase in the lymphoid population of the white pulp which, unlike the case of non-thymectomized toads, is not accompanied by an increase in the red pulp. Thus the splenic red pulp of thymusless toads invariably contains few lymphocytes. In support of this finding, Horton and Manning (1974) report that the striking feature of the spleen histology in their stage-48-thymectomized toads is the great variability of the white pulp from one toad to another. Taking all these findings into consideration, the histological and functional aspects of the splenic red pulp in relation to its dependence on the thymus warrant further investigation. Although the exact source of the thymus-independent lymphocytes is beyond the scope of the present study, the entirely normal features of the gut-associated LET bodies in our early-thymectomized toads deserve attention as a possible functional bursal equivalency (*cf.* Fichtelius *et al.*, 1968; Tochinai, 1975a). It has been shown that the gut-associated lymphocytes occur more extensively in anurans than had been expected previously (Goldstine *et al.*, 1975).

### Summary

The 4-day-old larvae (stage 45) of *Xenopus laevis* were thymectomized, and the lymphoid tissue development was studied on the thymectomized animals.

Early-thymectomy resulted in a complete lack of lymphocytes from the anterior dorsal cavity bodies of the larvae, and in a conspicuous lymphocytic diminution in the splenic red pulp of adult toads. However, the gut-associated lympho-epithelial tissue (LET) bodies in thymectomized toads possessed lymphoid accumulations in a similar degree to those in the non-thymectomized toads. The lymphocytic depopulation was considerable in other organs, such as the adult splenic white pulp, larval gill- and gut-associated LET bodies, and in the lymphoid aggregations of the liver and kidney. However, a small number of lymphocytes were clearly discernible in these organs.

The injection of rabbit erythrocytes into early-thymectomized toads did not

alter the lymphoid population of the spleen. However, the injection of polyvinylpyrrolidone into the same animals gave rise to an increase of the lymphoid population in the splenic white pulp, but not in the red pulp. The injection of these antigens into non-thymectomized toads resulted in an increase of lymphoid populations in both red- and white pulps.

In addition, a description was given of the particular syndrome which was characterized by the lesions in the liver and lung of the thymectomized toads, suggesting a possible "wasting disease".

The author wishes to express his sincere gratitude to Asst. Professor Ch. Katagiri for his constant encouragement and guidance throughout the course of this work, and for a critical reading of the manuscript.

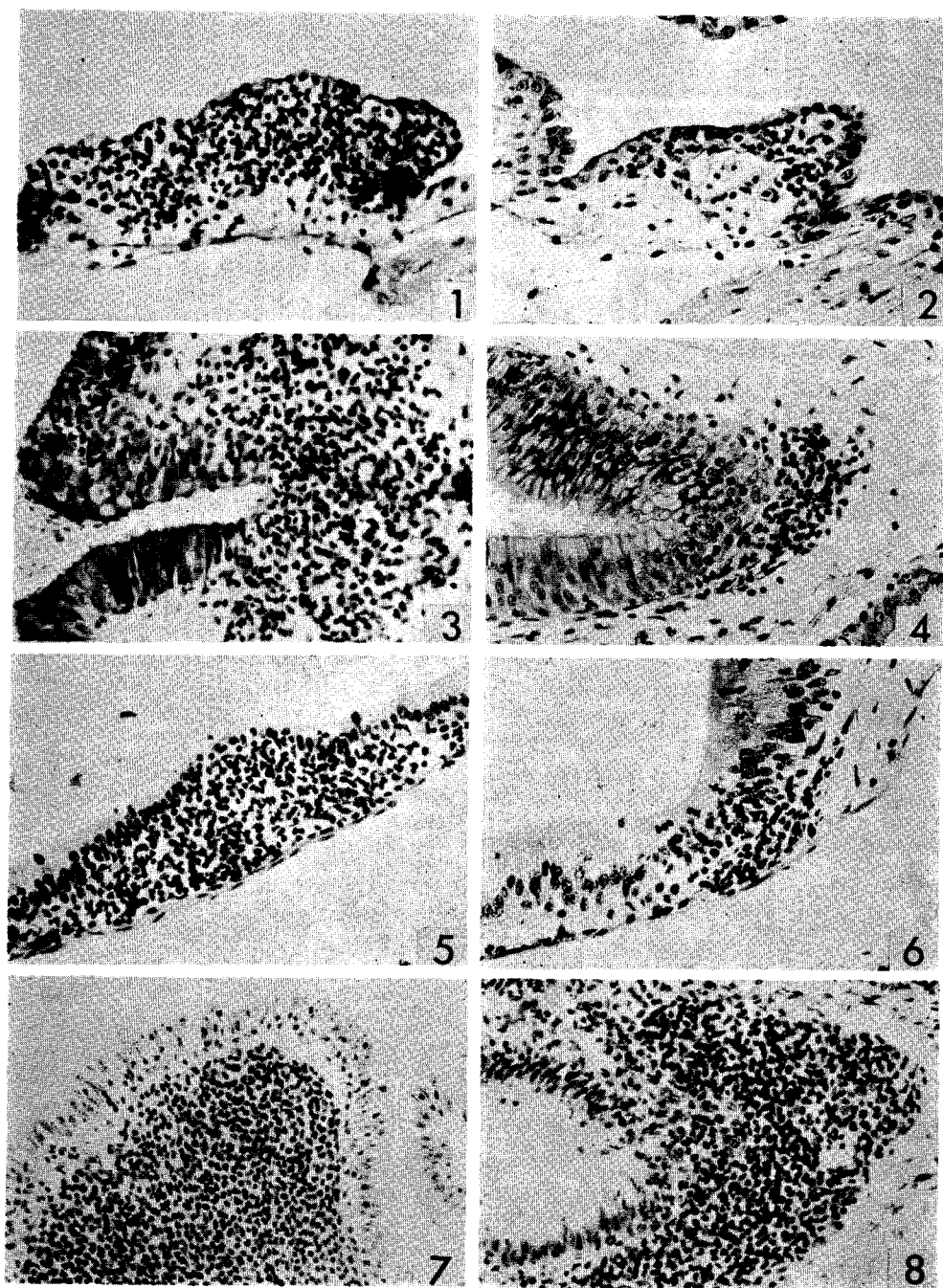
### References

- Azar, H.A. 1964. Bacterial infection and wasting in neonatally thymectomized rats. *Proc. Soc. exp. Biol. Med.* **116**: 817-823.
- Charlemagne, J. 1974. Larval thymectomy and transplantation immunity in the urodele *Pleurodeles wallii* Michah. (Salamandridae). *Eur. J. Immunol.* **4**: 390-392.
- de Sousa, M.A.B. 1973. Ecology of thymus dependency. *Contemp. Top. Immunobiol.* **2**: 119-136.
- Du Pasquier, L. 1968. Les protéines sériques et le complexe lympho-myéloïde chez le têtard d'*Alytes obstetricans* normal et thymectomisé. *Annls. Inst. Pasteur* **114**: 490-502.
- 1973. Ontogeny of the immune response in cold-blooded vertebrates. *Curr. Top. Microbiol. Immunol.* **61**: 37-88.
- Fichtelius, K.E., Finstad, J. and R.A. Good 1968. Bursa equivalents of bursaless vertebrates. *Lab. Invest.* **19**: 339-351.
- Goldstine, S.N., Manickavel, V. and N. Cohen 1975. Phylogeny of gut-associated lymphoid tissue. *Amer. Zool.* **15**: 107-118.
- Horton, J.D. and M.J. Manning 1972. Response to skin allografts in *Xenopus laevis* following thymectomy at early stages of lymphoid organ maturation. *Transplantation* **14**: 141-154.
- and ——— 1974. Lymphoid organ development in *Xenopus* thymectomized at eight days of age. *J. Morph.* **143**: 385-396.
- Manning, M.J. 1971. The effect of early thymectomy on histogenesis of the lymphoid organs in *Xenopus laevis*. *J. Embryol. exp. Morph.* **26**: 219-229.
- 1975. The phylogeny of thymic dependence. *Amer. Zool.* **15**: 63-71.
- and J.D. Horton 1969. Histogenesis of lymphoid organs in larvae of the South African clawed toad, *Xenopus laevis* (Daudin). *J. Embryol. exp. Morph.* **22**: 265-277.
- Nieuwkoop, P.D. and J. Faber 1956. Normal Table of *Xenopus laevis* (Daudin). North Holland Publ., Amsterdam.
- Tochinai, S. 1975a. Distribution of lympho-epithelial tissues in the larval South African clawed toad, *Xenopus laevis* Daudin. *Jour. Fac. Sci. Hokkaido Univ. Ser. VI, Zool.* **19**: 803-811.
- 1975b. Success of thymectomy from larval *Xenopus* at the earliest stage of its histogenesis. *Zool. Mag.* **84**: 138-141.
- 1976. Demonstration of thymus-independent immune system in *Xenopus laevis*:

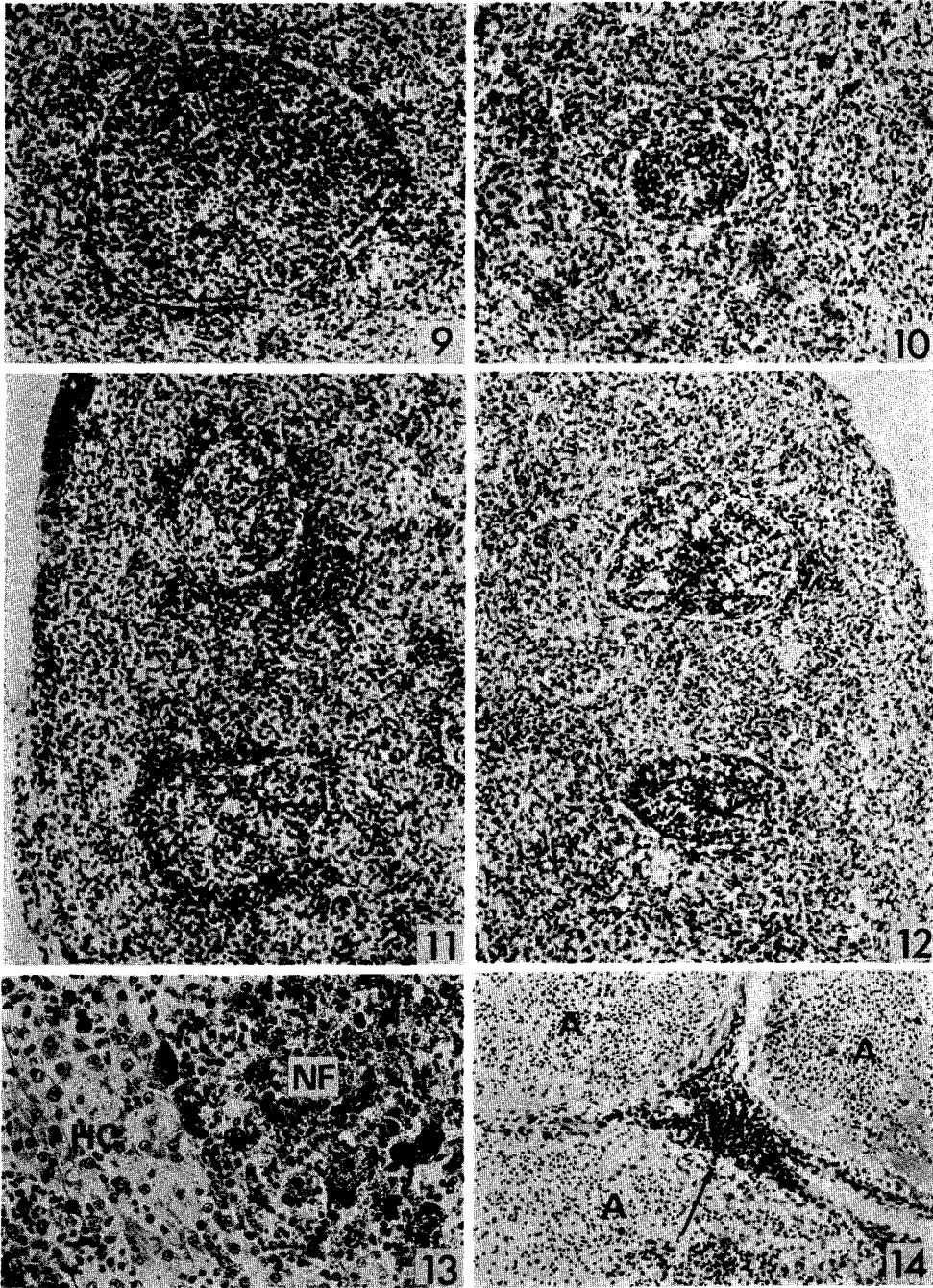
- Response to polyvinylpyrrolidone. Immunology: in press.
- and Ch. Katagiri 1975. Complete abrogation of immune response to skin allografts and rabbit erythrocytes in the early thymectomized *Xenopus*. *Develop., Growth & Differ.* **17**: 383-394.
- Tournefier, A. 1973. Développement des organes lymphoïdes chez l'Amphibien Urodèle *Triturus alpestris* Laur.; tolérance des allogreffes après la thymectomie larvaire. *J. Embryol. exp. Morph.* **29**: 383-396.
- Turner, R.J. and M.J. Manning 1974. Thymic dependence of amphibian antibody responses. *Eur. J. Immunol.* **4**: 343-346.

### Explanation of Plates IX-X

- Figs. 1 and 2. Second VCBs of non-thymectomized (Fig. 1) and thymectomized (Fig. 2) stage 56 larvae, showing the difference in lymphoid populations.  $\times 200$ .
- Figs. 3 and 4. Posterior DCBs of non-thymectomized (Fig. 3) and thymectomized (Fig. 4) stage 56 larvae. A small lymphoid aggregation is discernible in Fig. 4.  $\times 200$ .
- Figs. 5 and 6. LET bodies found in the small intestine of non-thymectomized (Fig. 5) and thymectomized (Fig. 6) stage 56 larvae. The degree of lymphoid invasion into the gut epithelium is extremely weak in Fig. 6.  $\times 200$ .
- Figs. 7 and 8. LET bodies in the small intestine of non-thymectomized (Fig. 7) and thymectomized (Fig. 8) toads, showing a similar degree of lymphoid accumulation.  $\times 200$ .
- Figs. 9 and 10. Sections through a part of the spleen from non-thymectomized (Fig. 9) and early-thymectomized (Fig. 10) toads 4 weeks after the last injection of RRBC, showing a difference in the lymphoid aggregations of the white pulp and the area surrounding it.  $\times 150$ .
- Figs. 11 and 12. Sections through a part of the spleen from non-thymectomized (Fig. 11) and early-thymectomized (Fig. 12) toads 4 weeks after the last injection of PVP, showing similar lymphoid aggregations in the white-pulp area, as contrasted with those in the red pulp which are developed only in Fig. 11.  $\times 150$ .
- Fig. 13. Liver from an early-thymectomized toad which died of a particular syndrome. The necrotic focus (NF) is filled with a large number of melanin granules and cellular debris. HC, normal hepatic cells.  $\times 200$ .
- Fig. 14. Lung from an early thymectomized and infected toad, showing alveoli (A) filled with blood. A lymphoid aggregation (arrow) is seen in the septum.  $\times 100$ .
-



*S. Tochinai: Lymphoid Tissues in Thymectomized Xenopus*



*S. Tochinai: Lymphoid Tissues in Thymectomized Xenopus*