



HOKKAIDO UNIVERSITY

Title	Immunohistochemical demonstration of chromogranin A in endocrine organs of the rat and horse by use of region-specific antibodies
Author(s)	HASHIMOTO, Yoshiharu; OHKI, Hiroyuki; SATO, Fumio et al.
Citation	Japanese Journal of Veterinary Research, 49(1), 3-17
Issue Date	2001-05-31
DOI	https://doi.org/10.14943/jjvr.49.1.3
Doc URL	https://hdl.handle.net/2115/2862
Type	departmental bulletin paper
File Information	KJ00002400324.pdf



Immunohistochemical demonstration of chromogranin A in endocrine organs of the rat and horse by use of region-specific antibodies

Yoshiharu Hashimoto¹, Hiroyuki Ohki¹, Fumio Sato²,
Noboru Yanaihara³ and Toshihiko Iwanaga^{1*}

(Accepted for publication : May 5, 2001)

Abstract

Chromogranin A (CgA) is an acidic glycoprotein that is co-stored with hormones or neurotransmitters in granular components of endocrine cells and neurons, and released together with them in response to adequate stimulation. In addition to acting as a packaging protein, CgA functions as a precursor molecule that yields several bioactive peptides by proteolytic cleavage. The purpose of this study is to elucidate how different the processing of CgA is among endocrine tissues by immunostaining using multiple region-specific antisera, and to evaluate the availability of region-specific antisera. When various endocrine organs of rats were immunostained with four region-specific antisera against rat CgA (CgA 1-28, 94-130, 296-314, and 359-389), all amine/peptide-secreting endocrine tissues except the pineal body were stained positively. The adrenal medulla and gastric endocrine cells were equally intensely immunoreactive to all four antisera, while the other endocrine tissues, represented by pancreatic islets, showed different staining patterns depending on the antiserum. These results suggest that the processing of CgA differs from tissue to tissue. An antiserum against horse CgA 335-365, corresponding to rat CgA 359-389 which shows the highest concentration in the plasma and urine of the rat, again stained all endocrine tissues of the horse except the pineal body. Therefore, the anti-horse CgA 335-365 serum is useful for immunohistochemical survey of horse CgA, and may make possible the establishment of a CgA assay system for the measurement of CgA in the plasma, urine and saliva.

¹Laboratory of Anatomy, Department of Biomedical Sciences, Graduate School of Veterinary Medicine, Hokkaido University, Sapporo 060-0818

²Laboratory of Molecular and Cellular Biology, Equine Research Institute, Japan Racing Association, Utsunomiya 320-0856

³Yanaihara Institute, Fujinomiya 418-0011, Japan

*Corresponding author

Fax : +81-11-706-5189

E-mail : tiwanaga@vetmed.hokudai.ac.jp

Key words : chromogranin A, immunohistochemistry, rat, region-specific antisera

Introduction

Chromogranin A (CgA) is a 48-kDa acidic and hydrophilic protein that was originally isolated from chromaffin granules of the bovine adrenal medulla^{3,43}. Subsequent immunohistochemical studies revealed its ubiquitous distribution in amine/peptide-secreting endocrine cells, including the adenohypophysis, thyroid calcitonin cells, parathyroid gland, gastro-entero-pancreatic endocrine cells, pulmonary and cutaneous paraneurons, and atrial myoendocrine cells^{36,47,56}. Thus, CgA is generally recognized as a useful marker of these endocrine cells in histological analysis. Functionally it has often been thought that CgA might act as a packaging protein within the core of secretory granules^{14,39}. Neurons in the central and peripheral nervous systems also contain CgA molecules, possibly in large-cored vesicles^{29,37}. Although early studies insisted on the selective localization of CgA in sympathetic nerves^{33,37}, a broader distribution in the nervous systems has also been proposed^{29,36,44,46,55,57}. Interestingly, recent radioimmunoassay (RIA) studies have revealed the existence of CgA-like substances in saliva. Immunohistochemically, the CgA-like immunoreactivity of the salivary glands is localized mainly in the ducts of the submandibular gland^{23,24,36}. Its concentration in the saliva as well as blood is sharply elevated in stress conditions, due to stimulated sympathetic activity, suggesting that CgA in the saliva becomes a reliable marker of stress conditions³².

The cloning and sequencing of CgA cDNA from bovine^{2,20}, porcine²¹, human²⁶, mouse⁵⁸, rat²² and equine⁴¹ libraries provided complete deduced amino acid sequences. CgA consists of 448 amino acid residues in the rat^{19,22}, with

8-10 sites of pairs of basic amino acids (Lys or Arg) that may act as proteolytic processing sites³⁰. Thus, there is a possibility that CgA is processed within cells to yield several bioactive peptides such as vasostatins, chromostatin, pancreastatin, and parastatin¹⁶. However, the modes and mechanisms of the CgA processing in cells remain unclear and complicated.

The present immunohistochemical study using four region-specific antisera against rat CgA demonstrates different staining patterns for CgA in various endocrine organs. Moreover, an antiserum against horse CgA was examined with regard to usefulness for immunostaining and establishment of a highly sensitive immunoassay system in the horse. Immunohistochemical data on the rat were partially described in our previous report³⁴.

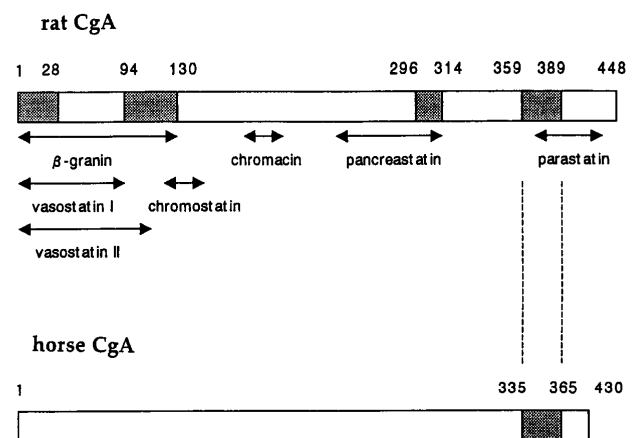


Fig. 1 A diagram showing sequences used for production of antisera. Four antisera for rat CgA and one antiserum for horse CgA were raised against shadow regions in the columns.

Materials and Methods

Animals

Twelve male Wistar rats, weighing about 200g, and seven female thoroughbred horses, weighing 400-550kg, were used in this study. Rats and horses were anesthetized by intravenous injection of pentobarbital and pentobarbital/thiopental sodium, respectively, and were sacrificed by bloodletting from the cervical artery. The adrenal gland, pituitary gland, pineal body, thyroid gland, parathyroid gland, pancreas, gastric body, ileum and colon were removed and immersed in Bouin's fluid for 12 hr. All experiments were performed under protocols following the Guidelines for Animal Experimentation, Graduate School of Veterinary Medicine, Hokkaido University.

Immunohistochemistry

The Bouin-fixed tissues were embedded in paraffin according to a conventional method, and cut serially at 4 μ m in thickness. Immunostaining of CgA was carried out according to the avidin-biotin complex (ABC) method. Four antisera raised against different regions of rat CgA and one antiserum against horse CgA 335-365 were used (Table 1) (Fig. 1). Since previous studies showed that, in the rat and human, rat CgA 359-389 (homologous to the human CgA 344-374) is highly stable in the plasma and urine^{34,35,59}, horse CgA 335-365 corresponding to these regions of rat and human CgA was selected for production of antisera against the horse CgA. All antisera were supplied by the Yanaihara Institute (Fujinomiya, Japan).

After treatment with a blocking serum for 30min, dewaxed sections were incubated with one of the rabbit polyclonal antisera against rat and horse CgA, listed in Table 1, overnight at room temperature. The sections were then incubated with biotinylated goat anti-rabbit immunoglobulins and avidin-

Table 1. List of antisera used

Antiserum	Code No.	dilution
Rat CgA 1-28	R0791	1 : 2,000
Rat CgA 94-130	Y291	1 : 10,000
Rat CgA 296-316	Y090	1 : 32,000
Rat CgA 359-389	Y290	1 : 4,000
Horse CgA 335-365	RY472	1 : 3,000

peroxidase complex (Histofine kit; Nichirei, Tokyo, Japan). The antigen-antibody reactions were visualized by incubation in 0.05M Tris-HCl buffer (pH 7.6) containing 0.01% 3,3'-diaminobenzidine and 0.002% H₂O₂. The specificity of the immunoreactions was checked by preincubation of the antiserum with the corresponding antigen (10 μ g/ml diluted antisera).

Results

Rat

When the adrenal glands of rats were immunostained using rat CgA 1-28, 94-130, 296-314 and 359-389 antisera, the medullary chromaffin cells were intensely immunolabeled with all four antisera, showing the same intensity of reaction (Fig. 2). Similarly, the four antisera intensely stained endocrine cells, predominantly enterochromaffin-like (ECL) cells, dispersed in the mucosa of the gastric body (Fig. 3a). A major population of endocrine cells in the adenohypophysis (anterior pituitary) had positive reactions with all antisera, but cells immunoreactive to individual antisera varied in intensity and intermingled with immunonegative cells (Fig. 3b). In the adenohypophysis, the intensity of immunoreactions with antisera against CgA 1-28 and 359-389 was weaker than that with the other antisera. The same tendency of immunoreaction observed in the adenohypophysis was recognized in endocrine cells dispersed in the intestinal mucosa. Immunoreactive cells in

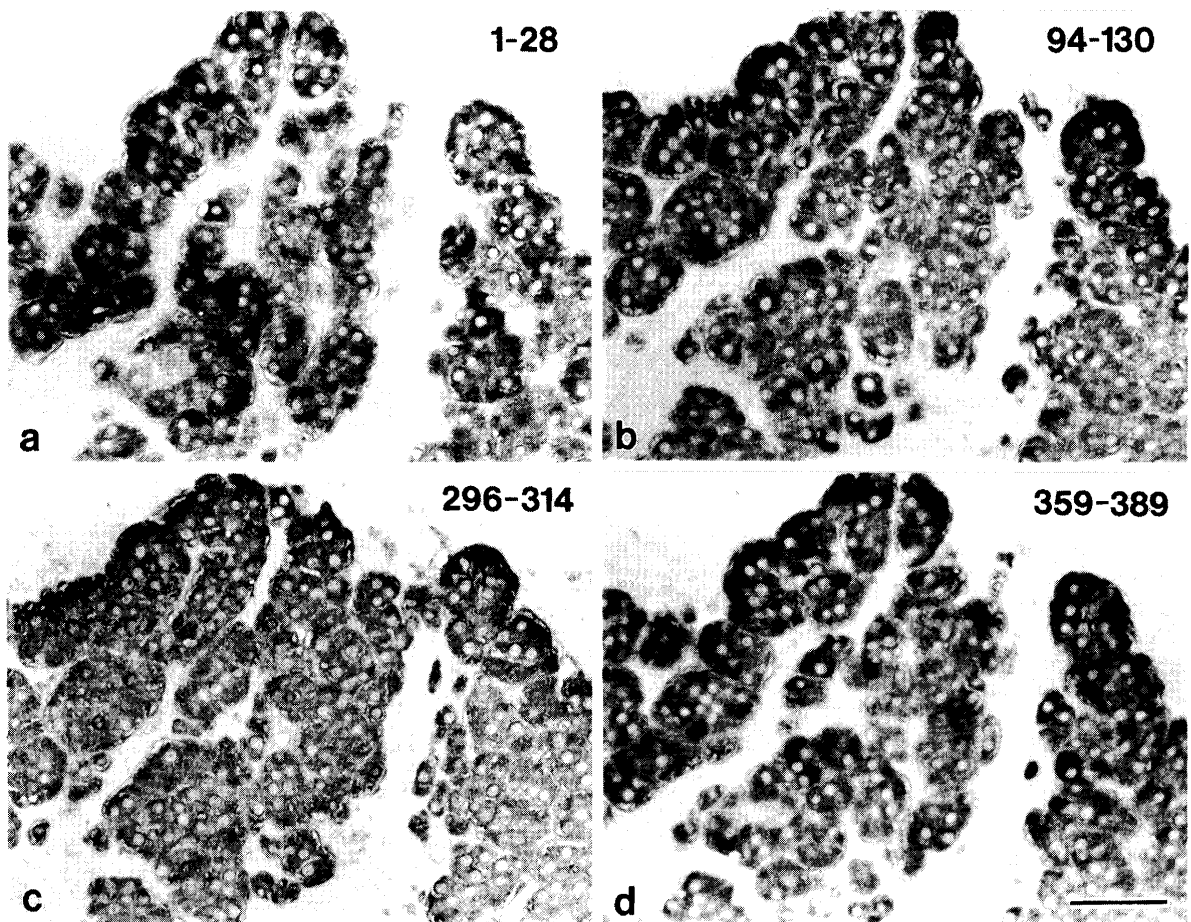


Fig. 2 CgA immunoreactivities with four region-specific antisera in the rat adrenal gland (four serial sections)
All medullary chromaffin cells are equally immunoreactive to the four antisera. Scale bar = 50 μ m

the ileum (Fig. 3 c) and colon (Fig. 3 d) were flask-shaped cells and extended a slender process to the lumen.

In the pancreas, islets of Langerhans were selectively stained, but the staining pattern quite differed depending upon the antiserum used (Fig. 4). The most intense staining was obtained with the antiserum against CgA 296-314; essentially all islet cells were evenly immunolabeled (Fig. 4 c). Less intense staining occurred with the CgA 94-130 antiserum (Fig. 4 b), weak immunoreactivity with the CgA 1-28 antiserum (Fig. 4 a), and faint reactivity with the CgA 359-389 antiserum (Fig. 4 d). The immunoreactive islet

cells, even among the same cell type, showed various intensities of immunoreaction for CgA and intermingled with immunonegative cells, as clearly shown in insulin cells occupying the central parts of islets.

In the thyroid gland, parafollicular cells (C cells), which secrete calcitonin, were stained positively, being distributed around follicles (Fig. 3 e). Immunoreactivity with CgA 296-314 antiserum was most intense, followed by that with CgA 94-130 antiserum, and then with CgA 1-28 antiserum. Antiserum against CgA 359-389 failed to stain any C cells. In the parathyroid gland, all principal cells were immunoreactive, with the same inten-

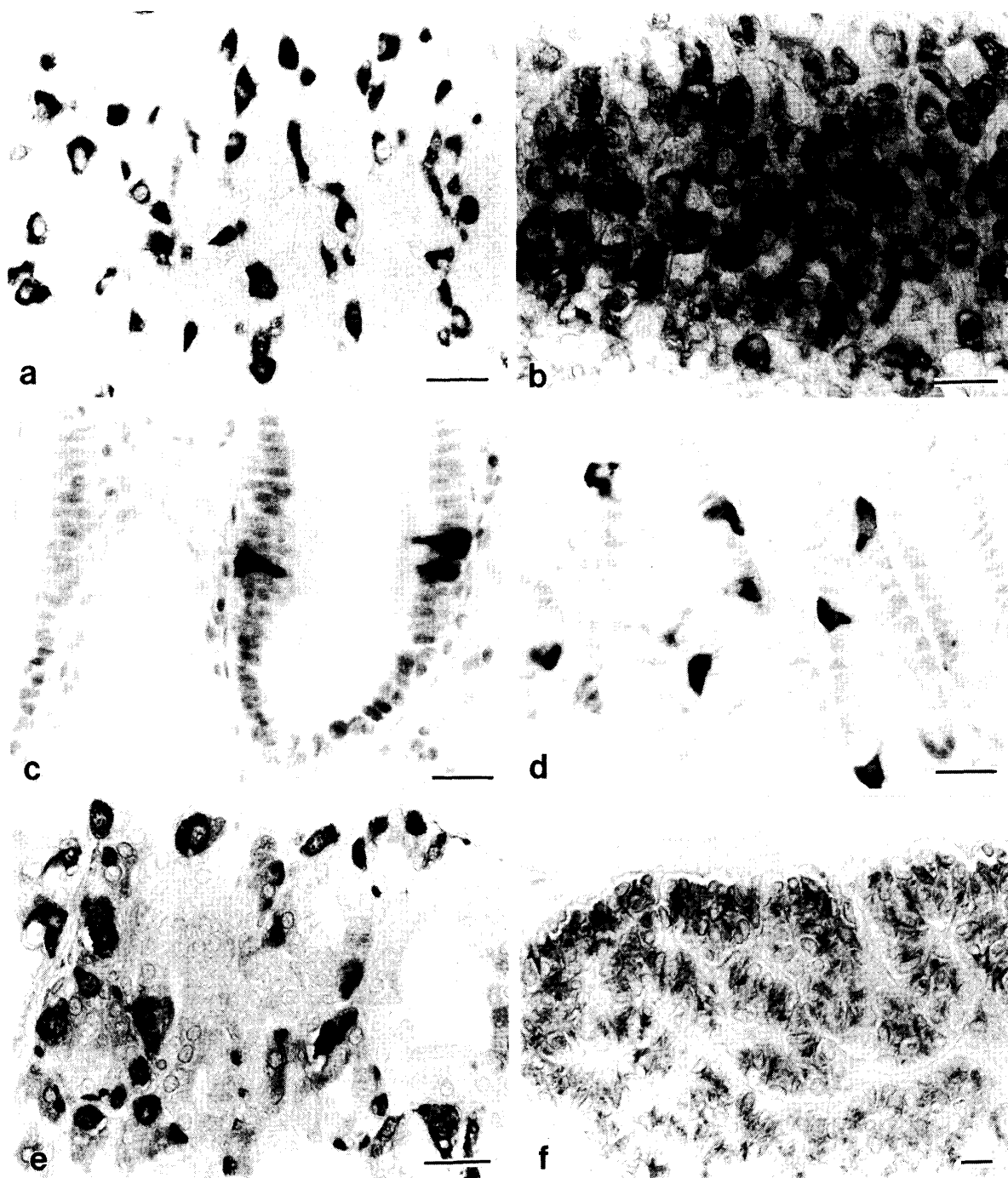


Fig. 3 Immunostaining of the gastric corpus (a), adenohypophysis (b), ileum (c), colon (d), thyroid gland (e), and parathyroid gland (f) by use of anti-rat CgA 296-314 serum in rats

In the adenohypophysis (b), immunoreactive cells showing different intensities intermingle. All endocrine cells in the parathyroid gland (f) are immunoreactive, but less intensely, possibly due to the small number of secretory granules. Scale bar = 20 μ m

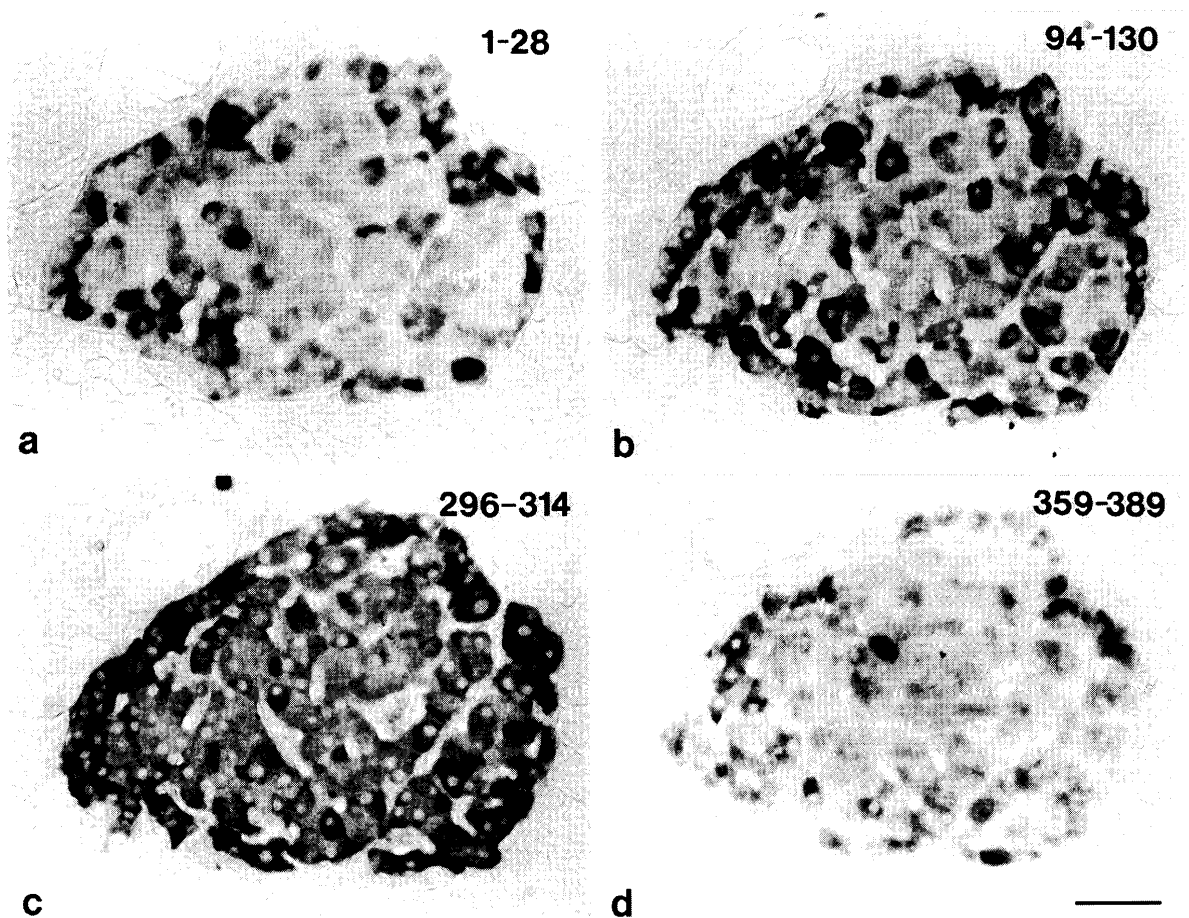


Fig. 4 CgA immunoreactivities with four region-specific antisera in the rat pancreas (four serial sections)

The antiserum against CgA 296-314 evenly stain all islet cells, but immunoreactivities with other three antisera are heterogeneous and less intense. Scale bar = 50 μ m

sity, to the antisera against CgA 94-130 and 296-314 (Fig. 3 f). Positive immunoreaction with CgA 359-389 antiserum in the parathyroid gland was slightly weak, while no immunoreactivity was recognized with the use of CgA 1-28 antiserum. In the pineal body, none of the antisera could stain any cellular elements. The staining results mentioned above are summarized in Table 2.

Horse

When the adrenal glands of horses were immunostained with the four antisera against rat CgA, chromaffin cells were reactive to only one, CgA 1-28 antiserum. The same staining

results were obtained in other endocrine cells of the horse (gastric endocrine cells, pancreatic islets, etc) except the pineal body.

The antiserum against horse CgA 335-365 detected the adrenal medulla, adenohypophysis, thyroid parafollicular cells, parathyroid gland, pancreatic islets, and endocrine cells of the gastric body and intestine (Fig. 5). In the pancreatic islets, their central region occupied by glucagon cells was stained more intensely than the peripheral region, which is dominated by insulin cells¹⁷⁾ (Fig. 5 d). In the thyroid gland, parafollicular cells were stained selectively, but the population of the

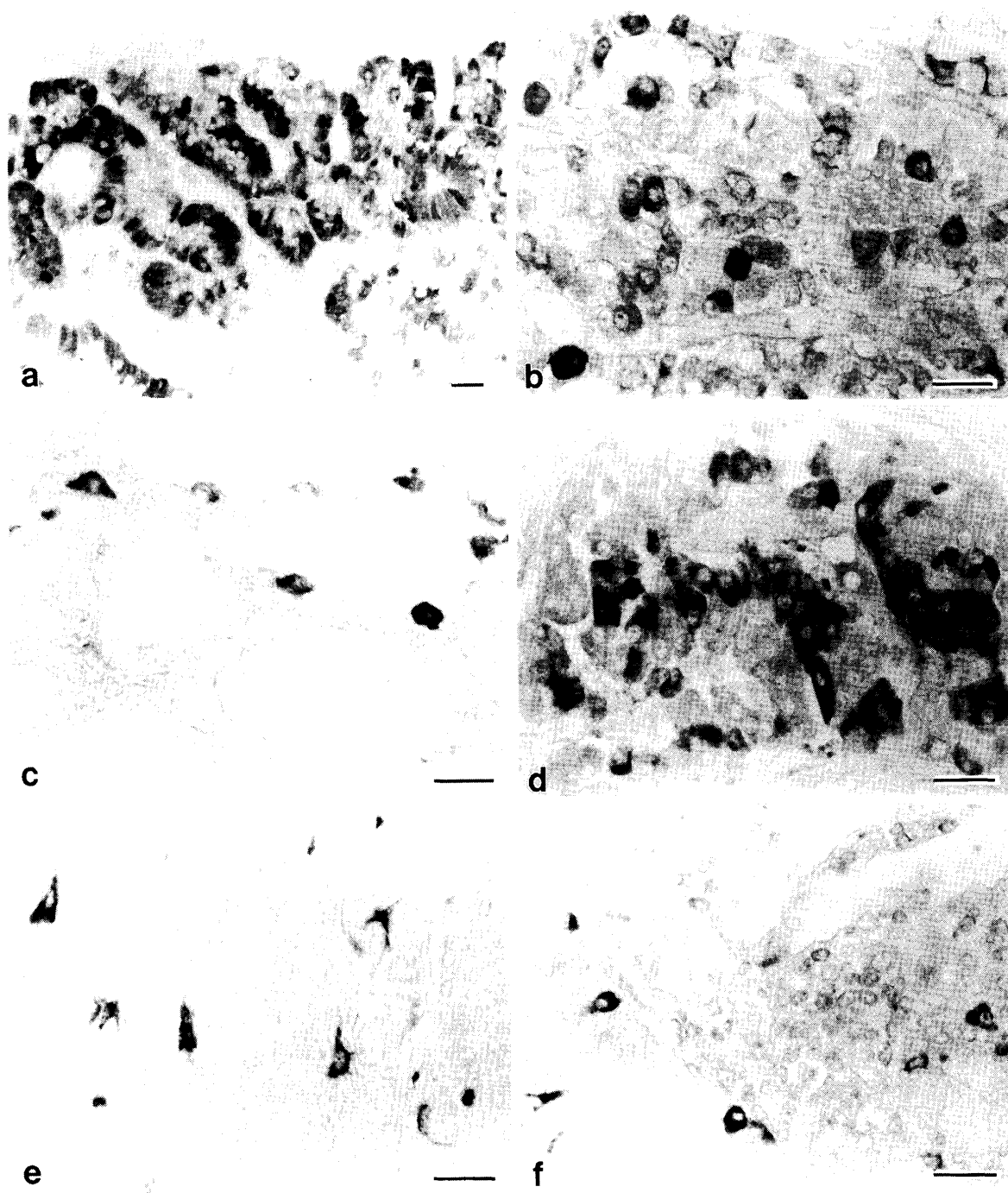


Fig. 5 Immunostaining of the adrenal gland (a), adenohypophysis (b), thyroid gland (c), pancreas (d), gastric body (e) and ileum (f) by use of anti-horse CgA 335-365 serum in horses.

In the adrenal gland (a), all medullary chromaffin cells are immunoreactive. The adenohypophysis (b) contains endocrine cells showing different intensities. CgA-immunoreactive cells in the pancreas gather in the central region of islets (d). Scale bar = 20 μ m

positive cells was smaller than in rats. Characteristic ring structures consisting of CgA-immunoreactive cells were formed around follicles throughout the thyroid gland (Fig. 5c).

Immunoreaction in the parathyroid gland was weak, but significantly positive. The pineal body did not contain any cells immunoreactive with the horse CgA 335-365 antiserum.

Table 2. Immunoreactivities of various endocrine cells to four region-specific antisera

Rat tissue	CgA 1-28	CgA94-130	CgA296-316	CgA359-389
Adrenal medulla	+++	+++	+++	+++
Gastric endocrine cells	+++	+++	+++	+++
Adenohypophysis	++	+++	+++	++
Intestinal endocrine cells	+	++	++	+
Pancreatic islets	+ / ++	++	+++	+
Thyroid C cells	+ / ++	++	+++	-
Parathyroid	-	++	++	+
Pineal body	-	-	-	-

+++ : intense, ++ : mediate, + : weak, - : negative

Discussion

The existence of many pairs of basic amino acids in the CgA molecule indicates that CgA is cleaved into biologically active peptides (Fig. 1). The N-terminal domain of CgA, called vasostatin (human CgA 1-76) or β -granin (rat CgA 1-130), has suppressive effects on vascular contractility and inhibits parathyroid hormone secretion^{1,40}. The middle part of CgA yields pancreastatin (porcine CgA 240-288, bovine CgA 248-294) and catestatin (porcine CgA 343-363, bovine CgA 344-364) or chromostatin (bovine CgA124-143), which have paracrine- or autocrine-inhibiting effects on the secretion of insulin^{10,19,52} and adrenal catecholamines^{13,28}, while another product, chromacin (bovine CgA 173-194), possesses antibacterial effects⁴⁹. The more C-terminally-derived peptide, termed parastatin (porcine CgA 347-419), inhibits parathormone secretion¹¹. The mode of the cleavage and end product are considerably different according

to the tissue, as indicated by gel permeation chromatography of CgA-like immunoreactants^{4,7,25,31,42,53,60}. It is reasonable that this different post-translational processing affects the immunohistochemical staining with antisera against intact CgA or its fragments.

Curry et al.⁸ reported inconsistent immunoreactivities in rat endocrine tissues using nine different antisera against rat CgA, supporting histochemically tissue- and cell-specific processing of CgA. The antigen peptides used for production of these nine antisera conspicuously differed in the length of sequences, from 6 to 128 in amino acid residues, and some of them overlapped. In contrast, we used four region-specific antisera raised against non-overlapping amino acid residues with a considerably consistent length of sequences, from 19-40 (Fig. 1); the N-terminal region of CgA (CgA 1-28), CgA 94-130 which is the C-terminal region of β -granin¹⁸, CgA 296-314 which corresponds to the C-terminal region of pancreastatin, and the C-terminal re-

gion of CgA (CgA 359-389). The present study confirmed the previous finding that the staining patterns with region-specific antisera differ from tissue to tissue⁸⁾. However, there are some discrepancies between our data and the study by Curry et al.⁸⁾. In their study, for example, the nine antisera for CgA showed various intensities of immunoreaction in the adrenal medulla and gastric body, whereas we obtained consistent intensity of immunoreaction with all four antisera in these two tissues. Gel permeation patterns of CgA immunoreactivity^{31,53,54)} demonstrated that the adrenal gland and gastric body, especially the former, are rich in intact CgA and large CgA-derived fragments, due to low proteolytic cleavage. This finding suggests the consistent immunoreactivities of these tissues to various region-specific antisera, in agreement with our immunohistochemical results.

In contrast to the adrenal medulla and gastric endocrine cells, other endocrine tissues, particularly pancreatic islets, showed different staining patterns to the antisera used. This was related to the fact that in the pancreas, proteolytic cleavage is the most extensive, as shown by gel permeation chromatography^{25,31,53)}. The thyroid C cells and parathyroid chief cells showed unique staining patterns for the CgA antisera: they were negative only for CgA 359-389 and CgA 1-28 antisera. Significant, possibly unique, proteolytic processing of CgA is known to occur in the thyroid gland^{4,7)}. Although no data on molecular forms of CgA in the parathyroid gland are available, production of some bioactive fragments is recognizable in parathyroid cells^{9,40)}. The weak or no immunoreaction in immunostaining seems to result either because a region recognized by the antiserum is lost by proteolytic cleavage or the antigenic determinant (epitopes of antigen) is masked by extension of amino acid sequences or by

binding of co-existing peptide hormones¹⁵⁾. In any case, the different staining patterns in each tissue indicated that the processing of CgA and following production of bioactive peptides were not identical in the tissues.

The present study further revealed that the antiserum against CgA 296-314, corresponding to the C-terminal of pancreastatin, was best for immunohistochemical investigation of rat endocrine tissues. It is worth noting that the CgA 296-314 antiserum displayed a large discrepancy between immunohistochemistry and RIA in the rat. According to RIA^{31,34,60)}, immunoreactive CgA levels detectable with this antiserum were extremely low in all endocrine tissues examined, as well as in plasma and urine, in contrast to high immunoreactivities with the other three antisera, indicating low production of pancreastatin in the endocrine tissues. However, Schmidt et al.⁴²⁾, Watkinson et al.⁵³⁾ and Bretherton-Watt et al.⁴⁾ could detect abundant pancreastatin-like immunoreactivity in the pancreas as well as the adrenal gland and pituitary in pigs and cattle. Furthermore, molecular characterization of pancreastatin-like immunoreactants showed predominant occurrence of the immunoreactants that coelute with native pancreastatin in the porcine pancreas and pituitary, bovine pancreas and pyloric antrum. Our immunohistochemical data showing abundant pancreastatin in essentially all islet cells are supported by several immunohistochemical studies that used anti-pancreastatin sera^{4,27,38,42,45)}.

CgA is stored in secretory granules and synaptic vesicles with hormones/neurotransmitters^{12,56)}, and released with them to the circulation⁵⁾. Stridsberg et al.⁴⁸⁾ reported that CgA circulates at a detectable level in the sheep, goat, horse and pig, by use of RIA for bovine CgA17-39. The concentration of circulating CgA appears to be influenced predomi-

nantly by secretion of CgA from the adrenal medulla, since secretagogue stimulation of normal human endocrine tissues other than the adrenal medulla does not perturb the plasma CgA concentration^{50,51}. This observation is consistent with the greater abundance of CgA in the adrenal gland than in other neuroendocrine tissues. Since plasma CgA is correlated with adrenal catecholamine release, plasma CgA is a valid marker of sympathochromaffin activity in humans⁶. In utilization of CgA as a marker for activated adreno-sympathetic activity, the peptide fragments used as antigens need to be stable in the blood and as detectable as possible by immunochemical methods. RIA studies with the same four antisera as those we used revealed that the anti-rat CgA 359-389 serum detect a great amount of the fragment in the plasma and urine of the rat³⁴. The same experiment in humans revealed that the corresponding fragment of human CgA (human CgA 344-374) is also detectable in the plasma, urine and saliva^{35,59}. Therefore, for investigation of horse CgA, we first tried to produce an antiserum against the corresponding sequence of the horse molecule (horse CgA 335-365). The present study with the antiserum (RY472) stained all endocrine tissues of the horse except the pineal body, indicating that this antiserum is useful in immunohistochemistry of horse CgA, and that measurement of the CgA fragments using the antiserum may be possible in the horse. Now we are developing an assay system to measure the CgA fragments in the plasma, urine and saliva in the horse using this antiserum.

Comparison of CgA sequences among various mammals shows that the structures of N- and C-terminal regions of CgA are considerably conserved^{22,41}, while the middle region possesses a lower degree of homology among species. When we immunostained the

horse adrenal gland with the four antisera against rat CgA, positive reactions were observed only with the antiserum against the N-terminal region of CgA. Positive immunoreactivity with the anti-rat CgA 1-28 serum was also observed in the adrenal medulla of the mouse, sheep and cattle (our unpublished data). These results prove, at the immunohistochemical level, that the amino acids of the N-terminal region detected by the anti-rat CgA 1-28 serum are highly conserved among mammals, in contrast to other regions of CgA.

In conclusion, the different immunostaining patterns depending upon the four antisera indicate tissue-specific processing of CgA. Immunostaining with region-specific antisera against CgA, as in this study, is important to survey CgA in various endocrine tissues, and is available to elucidate the manner of processing of CgA.

References

1. Aradal, S. and Helle, K. B. 1992. The vasoinhibitory activity of bovine chromogranin A fragment (vasostatin) and its independence of extracellular calcium in isolated segments of human blood vessels. *Regul. Pept.*, 41 : 9-18
2. Benedum, U. M., Baeuerle, P. A., Konecki, D. S., Frank, R., Powell, J., Mallet, J. and Huttner, W. B. 1986. The primary structure of bovine chromogranin A : a representative of a class of acidic secretory proteins common to a variety of peptidergic cells. *EMBO J.*, 5 : 1495-1502
3. Blaschke, E., Comline, R. S., Schneider, F.H., Silver, M. and Smith, A. D. 1967. Secretion of a chromaffin granule protein, chromogranin, from the adrenal gland after splanchnic stimulation. *Nature*, 215 : 58-59
4. Bretherton-Watt, D., Ghatei, M. A.,

- Bishop, A. E., Facer, P., Fahey, M., Hedges, M., Williams, G., Valentino, K. L., Tatemoto, K., Roth, K., Polak, J. M. and Bloom, S. R. 1988. Pancreastatin distribution and plasma levels in the pig. *Peptides*, 9 : 1005-1014
5. Carmichael, S.W., Stoddard, S.L., O'Connor, D. T., Yaksh, T. L. and Tyce, G. M. 1990. The secretion of catecholamines, chromogranin A and neuropeptide Y from the adrenal medulla of cat via the adrenolumbar vein and thoracic duct: different anatomic routes based on size. *Neuroscience*, 34 : 433-440
 6. Cryer, P. E., Wortsman, J., Shah, S. D., Nowak, R. M. and Deftos, L. J. 1991. Plasma chromogranin A as a marker of sympathochromaffin activity in humans. *Am. J. Physiol.*, 260 : E243-E246
 7. Curry, W. J., Johnston, C. F., Shaw, C., Buchanan, K. D. 1990. Distribution and partial characterisation of immunoreactivity to the putative C-terminus of rat pancreastatin. *Regul. Pep.*, 30 : 207-219
 8. Curry, W. J., Johnston, C. F., Hutton, J. C., Arden, S. D., Rutherford, N. G., Shaw, C. and Buchanan, K. D. 1991. The tissue distribution of rat chromogranin A-derived peptides: evidence for differential tissue processing from sequence specific antisera. *Histochemistry*, 96 : 531-538
 9. Drees, B. M., Rouse, J., Johnson, J. and Hamilton, J. W. 1991. Bovine parathyroid glands secrete a 26-kDa N-terminal fragment of chromogranin-A which inhibits parathyroid cell secretion. *Endocrinology*, 129 : 3381-3387
 10. Eiden, L. E. 1987. Is chromogranin a prohormone? *Nature*, 325 : 301
 11. Fasciotto, B. H., Trauss, C. A., Greeley, G. H. and Cohn, D. V. 1993. Parastatin (porcine chromogranin A 347-419), a novel chromogranin A-derived peptide, inhibits parathyroid cell secretion. *Endocrinology*, 133 : 461-466
 12. Fischer-Colbrie, R., Lassmann, H., Hang, C. and Winkler, H. 1985. Immunological studies on the distribution of chromogranin A and B in endocrine and nerve tissues. *Neuroscience*, 16 : 547-555
 13. Galindo, E., Rill, A., Bader, M. F. and Aunis, D. 1991. Chromostatin, a 20-amino acid peptide derived from chromogranin A, inhibits chromaffin cell secretion. *Proc. Natl. Acad. Sci. USA*, 88 : 1426-1430
 14. Gorr, S.-U., Shioi, J. and Cohn, D. V. 1989. Interaction of calcium with porcine adrenal chromogranin A (secretory protein-I) and chromogranin B (secretogranin I). *Am. J. Physiol.*, 257 : E247-E254
 15. Grube, D., Aunis, D., Bader, F., Cetin, Y., Jörns, A. and Yoshie, S. 1986. Chromogranin A (CGA) in the gastro-entero-pancreatic (GEP) endocrine system. I. CGA in the mammalian endocrine pancreas. *Histochemistry*, 85 : 441-452, 1986
 16. Helle, K. B. and Angeletti, R. H. 1994. Chromogranin A: a multipurpose prohormone? *Acta Physiol. Scand.*, 152 : 1-10
 17. Helmstaedter, V., Feurle, G. E. and Forssmann, W. G. 1976. Insulin-, glucagon-, and somatostatin-immunoreactive endocrine cells in the equine pancreas. *Cell Tissue Res.*, 172 : 447-454
 18. Hutton, J. C., Hansen, F. and Peshavaria, M. 1985. β -granins: 21kDa cosecreted peptides of the insulin gran-

- ules closely related to adrenal medullary chromogranin A. *FEBS Lett.*, 188 : 336-340.
19. Hutton, J. C., Nielsen, E. and Kastern, W. 1988. The molecular cloning of the chromogranin A-like precursor of β -granin and pancreastatin from the endocrine pancreas. *FEBS Lett.*, 236 : 269-274
 20. Iacangelo, A., Affolter, H. U., Eiden, L. E., Herbert, E. and Grimes, M. 1986. Bovine chromogranin A sequence and distribution of its messenger RNA in endocrine tissues. *Nature*, 323 : 82-86
 21. Iacangelo, A., Fischer-Colbrie, R., Koller, K. J., Brownstein, M. J. and Eiden, L. E. 1988. The sequence of porcine chromogranin A messenger RNA demonstrates chromogranin A can serve as the precursor for the biologically active hormone, pancreastatin. *Endocrinology*, 122 : 2339-2341
 22. Iacangelo, A., Okayama, H. and Eiden, L. E. 1988. Primary structure of rat chromogranin A and distribution of its mRNA. *FEBS Lett.*, 227 : 115-121
 23. Kanno, T., Asada, N., Yanase, H., Iwanaga, T., Nishikawa, Y., Hoshino, M. and Yanaihara, N. 1998. Autonomic control of submandibular chromogranin A secretion in the anaesthetized rat. *Biomed. Res.*, 19 : 411-414
 24. Kanno, T., Asada, N., Yanase, H., Iwanaga, T., Ozaki, T., Nishikawa, Y., Iguchi, K., Mochizuki, T., Hoshino, M. and Yanaihara, N. 1999. Salivary secretion of highly concentrated chromogranin A in response to noradrenaline and acetylcholine in isolated and perfused rat submandibular glands. *Exp. Physiol.* 84 : 1073-1083
 25. Kirchmair, R., Leitner, B., Fischer-Colbrie, R., Marksteiner, J., Hogue-Angeletti, R. and Winkler, H. 1995. Large variations in the proteolytic formation of a chromogranin A-derived peptide (GE-25) in neuroendocrine tissues. *Biochem. J.* 310 : 331-336
 26. Konecki, D.S., Benedum, U.M., Gerdes, H.H. and Huttner, W. B. 1987. The primary structure of human chromogranin A and pancreastatin. *J. Biol. Chem.*, 262 : 17026-17030
 27. Lamberts, R., Schmidt, W. E. and Creutzfeldt, W. 1990. Light and electron microscopical immunocytochemical localization of pancreastatin-like immunoreactivity in porcine tissues. *Histochemistry*, 93 : 369-380
 28. Mahata, S.K., O'Connor, D. T., Mahata, M., Yoo, S. H., Taupenot, L., Wu, H., Gill, B. M. and Parmer, R. J. 1997. Novel autocrine feedback control of catecholamine release. A discrete chromogranin A fragment is a noncompetitive nicotinic cholinergic antagonist. *J. Clin. Invest.*, 100 : 1623-1633
 29. Majdoubi, M. L., Metz-Boutigue, M. -H., Garcia-Sablone, P., Theodosis, D. T. and Aunis, D. 1996. Immunocytochemical localization of chromogranin A in the normal and stimulated hypothalamo-neurohypophysial system of the rat. *J. Neurocytol.*, 25 : 405-416
 30. Metz-Boutigue, M.-H., Garcia-Sablone, P., Hogue-Angeletti, R. and Aunis, D. 1993. Intracellular and extracellular processing of chromogranin A. Determination of cleavage sites. *Eur. J. Biochem.*, 217 : 247-257
 31. Nagasawa, S., Nishikawa, Y., Ohshima, K., Iguchi, K., Mochizuki, T., Greeley, G. H. and Yanaihara, N. 1995. Distribution of chromogranin A-like peptides in the rat. *Biomed. Res.*, 16 : 83-90
 32. Nakane, H., Asami, O., Yamada, Y., Ha-

- rada, T., Matsui, N., Kanno, T. and Yanaihara, N. 1998. Salivary chromogranin A as an index of psychosomatic stress response. *Biomed. Res.*, 19 : 401-406
33. Neuman, B., Wiedermann, C.J., Fischer-Colbrie, R., Schober, M., Sperk, G. and Winkler, H. 1982. Biochemical and functional properties of large and small dense-core vesicles in sympathetic nerves of rat and ox vas deferens. *Neuroscience*, 13 : 921-931
34. Nishikawa, Y., Nagasawa, S., Yanaihara, N., Iguchi, K., Mochizuki, T., Hoshino, M., Iwanaga, T. and Yanaihara, C. 1998. Immunoreactive chromogranin A in rat plasma and urine measured by region-specific radioimmunoassay. *Biomed. Res.*, 19 : 237-244
35. Nishikawa, Y., Jun, L., Futai, Y., Yanaihara, N., Iguchi, K., Mochizuki, T., Hoshino, M. and Yanaihara, C. 1998. Region-specific radioimmunoassay for human chromogranin A. *Biomed. Res.*, 19 : 245-251
36. Nolan, J. A., Trojanowski, J. Q., Hogue-Angeletti, R. 1985. Neurons and neuroendocrine cells contain chromogranin. *J. Histochem. Cytochem.*, 33 : 791-798
37. O'Connor, D. T., Klein, R. L., Thureson-Klein, A. K. and Barbosa, J. A. 1991. Chromogranin A : localization and stoichiometry in large dense core catecholamine storage vesicles from sympathetic nerve. *Brain Res.*, 567 : 188-196
38. Ravazzola, M., Efendic, S., Ostenson, C. G., Tatemoto, K., Hutton, J. C. and Orci, L. 1988. Localization of pancreastatin immunoreactivity in porcine endocrine cells. *Endocrinology*, 123 : 227-229
39. Reiffer, F. U. and Gratzl, M. 1986. Ca^{2+} binding to chromaffin vesicle matrix proteins : effect of pH, Mg^{2+} , and ionic strength. *Biochemistry*, 25 : 4402-4406
40. Russell, J., Gee, P., Liu, S.M. and Angeletti, R. H. 1994. Inhibition of parathyroid hormone secretion by aminoterminal chromogranin peptides. *Endocrinology*, 135 : 337-342
41. Sato, F., Hasegawa, T., Katayama, Y., Iwanaga, T., Yanaihara, N., Kanno, T. and Ishida, N. 2000. Molecular cloning of equine chromogranin A and its expression in endocrine and exocrine tissues. *J. Vet. Med. Sci.*, 62 : 953-959
42. Schmidt, W.E., Siegel, E. G., Lamberts, R., Gallwitz, B. and Creutzfeldt, W. 1988. Pancreastatin : molecular and immunocytochemical characterization of a novel peptide in porcine and human tissues. *Endocrinology*, 123 : 1395-1404
43. Schneider, F. H., Smith, A. D. and Winkler, H. 1967. Secretion from the adrenal medulla : biochemical evidence for exocytosis. *Br. J. Pharmacol. Chemother.*, 31 : 94-104
44. Shen, Z., Ekelund, M. and Sundler, F. 1994. Immunocytochemical evidence for chromogranin A and B in neuronal elements in human gut. *Regul. Pep.*, 51 : 229-236
45. Shimizu, F., Ikei, N., Iwanaga, T. and Fujita, T. 1987. An immunochemical and immunohistochemical study on pancreastatin-like immunoreactivity using synthetic peptides. *Biomed. Res.*, 8 : 457-462
46. Somogyi, P., Hodgson, A. J., DePotter, R. W., Fischer-Colbrie, R., Schober, M., Winkler, H. and Chubb, I. W. 1984. Chromogranin immunoreactivity in the central nervous system. Immunocytochemical characterization, distribution,

- and relationship to catecholaminergic and enkephalin pathways. *Br. Res. Rev.*, 8 : 193-230
47. Steiner, H.-J., Weiler, R., Ludescher, C., Schmidt, K. W. and Winkler, H. 1990. Chromogranins A and B are colocalized with atrial natriuretic peptides in secretory granules of rat heart. *J. Histochem. Cytochem.*, 38 : 845-850
 48. Stridsberg, M., Angeletti, R. H. and Helle, K. B. 2000. Characterization of N-terminal chromogranin A and chromogranin B in mammals by region-specific radioimmunoassays and chromatographic separation methods. *J. Endocrinol.*, 165 : 703-714
 49. Sturb, J. M., Goumon, Y., Lugardon, K., Capon, C., Lopez, M., Moniatte, M., Dorselaer, V. A., Aunis, D. and Metz-Boutigue, M. H. 1996. Antibacterial activity of glycosylated and phosphorylated chromogranin A-derived peptide 173-194 from bovine adrenal medullary chromaffin granules. *J. Biol. Chem.*, 271 : 28533-28540
 50. Takiyyuddin, M.A., Cervenka, J.H., Pandian, M.R., Stuenkel, C.A., Neumann, H.P.H. and O'Connor, D. T. 1990. Neuroendocrine sources of chromogranin-A in normal man: clues from selective stimulation of endocrine glands. *J. Clin. Endocr. Metab.*, 71 : 360-369
 51. Takiyyuddin, M.A., Baron, A.D., Cervenka, J.H., Barbosa, J. A., Neumann, H. P. H., Parmer, R.J., Sullivan, P. A. and O'Connor, D. T. 1991. Suppression of chromogranin A release from neuroendocrine sources in man: pharmacological studies. *J. Clin. Endocr. Metab.*, 72 : 616-622
 52. Tatemoto, K., Efendic, S., Mutt, V., Makk, G., Feistner, G. J. and Barchas, J. D. 1986. Pancreastatin, a novel pancreatic peptide that inhibits insulin secretion. *Nature*, 324 : 476-478
 53. Watkinson, A., Jonsson, A.-C., Davison, M., Young, J., Lee, C. M., Moore, S. and Dockray, G. J. 1991. Heterogeneity of chromogranin A-derived peptides in bovine gut, pancreas and adrenal medulla. *Biochem. J.*, 276 : 471-479
 54. Watkinson, A. and Dockray, G. J. 1992. Functional control of chromogranin A and B concentrations in the body of the rat stomach. *Regul. Pep.*, 40 : 51-61
 55. Wiedenmann, B. and Huttner, W. B. 1989. Synaptophysin and chromogranins / secretogranins — widespread constituents of distinct types of neuroendocrine vesicles and new tools in tumor diagnosis. *Virchows Arch B*, 58 : 95-121
 56. Winkler, H. and Fischer-Colbrie, R. 1992. The chromogranin A and B: the first 25 years and future perspectives. *Neuroscience*, 49 : 497-528
 57. Woulfe, J., Deng, D. and Munoz, D. 1999. Chromogranin A in the central nervous system of the rat: pan-neuronal expression of its mRNA and selective expression of the protein. *Neuropeptides*, 33 : 285-300
 58. Wu, H. J., Rozansky, D. J., Parmer, R. J., Gill, B.M. and O'Connor, D. T. 1991. Structure and function of chromogranin A gene. Clues to evolution and tissue-specific expression. *J. Biol. Chem.*, 266 : 13130-13134
 59. Yanaihara, H., Hata, M., Nishikawa, Y., Hoshino, M., Yanaihara, N. and Murai, M. 1999. Application of region-specific immunoassay for human chromogranin A: substantial clue for detection and measurement of chromogranin A in human plasma. *Regul. Pept.*, 80 : 83-90

60. Yanaihara, N., Nishikawa, Y., Hoshino, M., Mochizuki, T., Iguchi, K., Nagasawa, S., Jun, L., Futai, Y., Kanno, T., Yanaihara, H., Murai, M. and Yanaihara, C. 1998. Evaluation of region-specific radioimmunoassays for rat and human chromogranin A : measurement of immunoreactivity in plasm, urine and saliva. In : *The Adrenal Chromaffin Cell*. pp. 305-312, Kanno, T., Nakazato, Y. and Kumakura, K. eds., Hokkaido Univ. Press, Sapporo.