



HOKKAIDO UNIVERSITY

Title	Chronic cadmium treatment induces islet B cell injury in ovariectomized cynomolgus monkeys
Author(s)	Kurata, Yoshimasa; Katsuta, Osamu; Doi, Takuya et al.
Citation	Japanese Journal of Veterinary Research, 50(4), 175-183
Issue Date	2003-02-28
DOI	https://doi.org/10.14943/jjvr.50.4.175
Doc URL	https://hdl.handle.net/2115/2965
Type	departmental bulletin paper
File Information	KJ00000699558.pdf



Chronic cadmium treatment induces islet B cell injury in ovariectomized cynomolgus monkeys

Yoshimasa Kurata^{1,2)}, Osamu Katsuta²⁾, Takuya Doi²⁾, Takeshi Kawasuso²⁾,
Hideaki Hiratsuka²⁾, Minoru Tsuchitani²⁾ and Takashi Umemura^{1)*}

(Accepted for publication : January 9, 2003)

Abstract

In an attempt to establish a primate model of chronic cadmium (Cd) toxicosis, we ovariectomized cynomolgus monkeys and treated with CdCl₂ by repeated intravenous injections for 13 to 15 months. The animals showed an increase in blood glucose from Month 10 and a decrease in blood insulin at Month 11 of the Cd-treatment. Histopathological examination of the Cd-treated animals revealed islet atrophy with reduction in islet number and vacuolation of the islet cells, whereas there was no remarkable change in the acinar cells of the exocrine pancreas. In histomorphometrical examination, insulin-positive areas in the islets were significantly decreased, accompanying a relative increase of glucagon-positive areas. Large amounts of Cd accumulated in the pancreas, and metallothionein (MT), a Cd binding protein, was localized in the islets of Cd-treated animals. The present study demonstrated that the chronic intravenous injection of Cd to cynomolgus monkeys induced the accumulation of the metal in the pancreas, degeneration of islet B cells and the diabetic clinical signs. Therefore the islet B cell is one of the major targets of the chronic Cd poisoning in monkeys.

Key words : chronic cadmium toxicosis ; cynomolgus monkey ; diabetes ; islet B cell ; pancreas

¹⁾Laboratory of Comparative Pathology, Department of Veterinary Clinical Sciences, Graduate School of Veterinary Medicine, Hokkaido University, Sapporo 060-0818, Japan

²⁾Kashima Laboratory of Mitsubishi Chemical Safety Institute Ltd., Hasaki-machi, Ibaraki 314-0255, Japan

*Corresponding author :

Takashi Umemura, Laboratory of Comparative Pathology, Department of Veterinary Clinical Sciences, Graduate School of Veterinary Medicine, Hokkaido University, Sapporo 060-0818, Japan

TEL : +81-11-706-5191

FAX : +81-11-706-5194

E-mail : umemura@vetmed.hokudai.ac.jp

Introduction

Cadmium (Cd) is a ubiquitous environmental pollutant and toxic to the kidney and bone^{1,4)}. Itai-itai disease (IID, "Ouch-ouch disease" in English) is the most morbid example of chronic Cd intoxication. IID is characterized with clinical disorders such as renal anemia, tubular nephropathy and osteomalacic osteopenia^{11,18,19)}. Recently, we conducted long-term repeated-dose toxicity studies of Cd to reproduce experimental models of IID and succeeded in developing murine and primate (cynomolgus monkeys) models^{2,3,7,8,9,17)}. In these studies, we noticed that the Cd-treated monkeys occasionally showed the increases of blood glucose and glycosuria. IID patients have been reported to reveal glycosuria⁶⁾ and the pancreas is one of the accumulation sites of Cd in humans in Cd-polluted area¹⁰⁾. These findings prompted us to investigate the effects of Cd intoxication on the pancreas and carbohydrate metabolism of the primate model. The pathological findings of the bone and kidney in the primate model will be published elsewhere.

Materials and Methods

Animals and treatment

Nine female cynomolgus monkeys (Indonesian origin, more than 5 years old) were purchased from CLEA Japan (Kanagawa, Japan). The animals were quarantined and acclimated for about 6 months, and showed no abnormalities in their general health conditions during the quarantine and acclimation period. Thus, these animals were subjected to bilateral ovariectomy (OVX) under pentobarbital anesthesia.

The OVX animals were individually housed in cages throughout the experimental period. The environmental conditions of the animal room were maintained as follows :

temperature at 24-28°C, relative humidity at 40%-70% and lighting for 12 hr. Animals were provided every day with 100 g of normal primate diet (CMK-1, CLEA Japan) and additives such as banana, and were also allowed free access to drinking water. For drinking water, tap water was used after it was passed through a 5- μ m filter and irradiated with UV. All animal care was performed in compliance with the Guidelines for Animal Test established at Mitsubishi Chemical Safety Institute Ltd.

Experimental design

One month after OVX, animals were randomly assigned to the following three groups to give practically equal mean body weights of the allocated animals in the groups : the control group (n = 4), CdCl₂ 1.0-mg/kg group (n = 3) and CdCl₂ 2.5-mg/kg group (n = 2). At the initiation of the Cd treatment, the body weights ranged from 3.14 to 3.70 kg. CdCl₂ (Purity : >95%, Wako Pure Chemical Industries Ltd., Osaka, Japan) was dissolved in saline and intravenously administered in a constant dosing volume of 0.1 ml/kg through the tail vein 3 times a week for 13 to 15 months. Animals in the control group were treated with vehicle. The actual dosing volumes for individual animals were calculated from their body weights determined on a weekly basis. The animals of the 2.5-mg/kg group, however, showed severe anemia in Month 9. Therefore, the dosing frequency was reduced to twice weekly for the rest of the treatment period.

Blood chemical examination and urinalysis

Blood samples for the examination of blood glucose and insulin levels were collected in the morning from the femoral vein before treatment and at 1-month intervals during the Cd treatment period. Animals were fasted

from 17 : 00 on the day before every blood sampling. Blood glucose was analyzed by GlcK-G 6 PDH method on an auto-analyzer (736-10, HITACHI Ltd., Tokyo, Japan) by using plasma samples obtained on centrifugation of heparin-treated blood samples. A blood insulin level of the serum samples obtained at Month 11 of the Cd-treatment was analyzed by radioimmunoassay method at Mitsubishi Chemical BCL Co., Ltd. (Tokyo, Japan). Fresh urine samples were also obtained before treatment and at 1-month intervals in the morning, and urine glucose levels were measured by a paper-test (Multistix[®], Bayer Medical, Ltd., Tokyo, Japan).

Histopathological examination on the pancreas

At necropsy, tissue samples of the pancreas were collected and fixed in 10% neutral buffered formalin solution, and routinely processed for histopathological sections of hematoxylin and eosin stain. The successive sections of the pancreas were immunostained with ABC methods using anti-human metallothionein (MT) antibody (DAKO Japan, Kyoto, Japan), anti-swine insulin antibody (DAKO Japan) and anti-human glucagon antibody (DAKO Japan). Islet areas and numbers in the pancreas were estimated at hematoxylin and eosin sections using an image analyzer (IPAP, Sumika-Technos Inc., Osaka, Japan), and the ratios of islet areas and islet numbers per pancreatic tissue area were calculated. The ratios of insulin- and glucagon-positive areas per pancreatic tissue area were also measured using the same instrument on the immunostained sections.

Analysis of tissue Cd and MT contents in the liver, kidney and pancreas

Small portions of the livers, kidneys and pancreas collected at necropsy were dissolved

in 14-N nitric acid. Cd contents in these tissues were measured on an atomic absorption spectrophotometer (AA-680, Shimadzu Co., Kyoto, Japan). MT contents in the liver and kidney were analyzed by a Cd saturation-hemolysate method¹³⁾. The MT concentrations were calculated, on the basis of nanomoles of MT per gram wet tissue, by assuming that 7 Cd atoms bind to 1 MT molecule.

Results

Body weight change

Animals treated with Cd at 2.5 mg/kg showed gradual reduction in body weight from Month 6, while animals treated with Cd at 1.0 mg/kg as well as those treated with vehicle alone (control group) showed no significant changes in body weight throughout the treatment period. None of the animals of all the groups showed the loss of appetite during the treatment period.

Findings of blood chemistry and urinalysis

Two animals in the 2.5-mg/kg group and one animal in the 1.0-mg/kg group showed an increase in blood glucose at Month 10 (Fig. 1 a). These animals also showed low blood insulin levels at Month 11 (Fig. 1 b). All animals treated with Cd discharged glucose positive urine from Month 5 or after.

Histopathological findings and histomorphometry of pancreatic islet

On necropsy, the pancreas of all monkeys showed no remarkable change. Histological examination revealed Cd-treatment caused atrophy of the islet and vacuolation of the islet cell (Figs. 2 a, b and c). On the other hand, no histological abnormalities were found in the exocrine acinar cells. Histomorphometrical examination revealed significant decreases in relative number, mean and relative areas of the islets to pancreatic tissue in Cd-

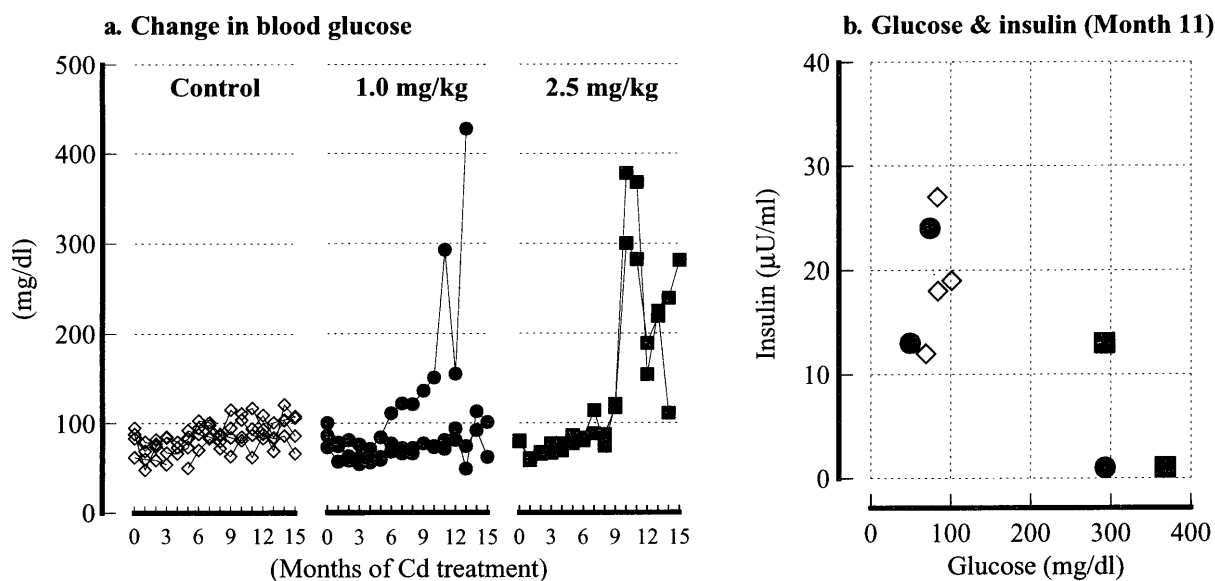


Fig. 1 Changes in plasma glucose and a relationship between glucose and insulin levels at Month 11 in ovariectomized cynomolgus monkeys treated with Cd. Panel a: plasma glucose level. Panel b: relationship between plasma glucose and insulin levels. \diamond : control group ($n=4$), \bullet : 1.0-mg/kg group ($n=3$), \blacksquare : 2.5-mg/kg group ($n=2$).




Fig. 2 Histopathological changes in the pancreas of the ovariectomized cynomolgus monkeys treated with Cd for 13 to 15 months. Panels a, b and c: hematoxylin and eosin staining of the pancreas from control (a), 1.0-mg/kg (b) and 2.5-mg/kg (c) groups. Islets in the Cd-treated groups are atrophic and vacuolation of the islets is illustrated at (c). Scale bar = 100 μm

treated animals (Figs. 3 a, b and c). In the microscopic and histomorphometrical examination on the immunostained sections for insulin and glucagon, insulin positive areas decreased significantly or disappeared (Figs. 4 a, b and c and Fig. 6 a), whereas there was no

obvious change in glucagon positive areas (Figs. 5 a, b and c and Fig. 6 b). The pancreatic tissues of Cd-treated animals were strongly positive for MT in immunostaining. The positive reaction for the MT was more remarkable in the islet areas, where the cyto-

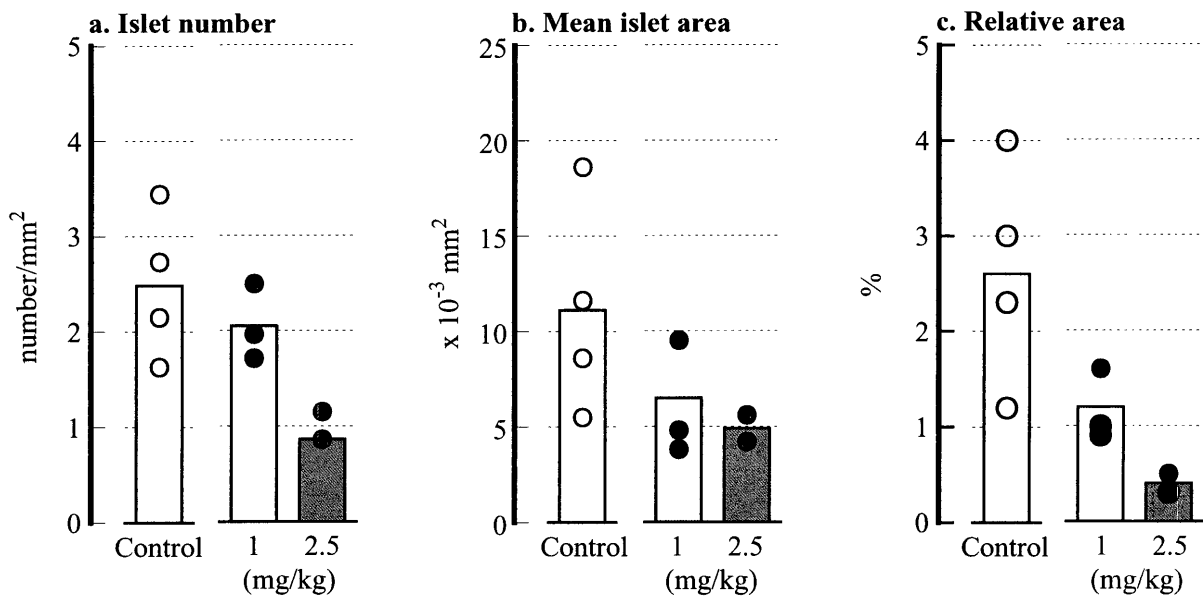


Fig. 3 Number and area of islets in ovariectomized cynomolgus monkeys treated with Cd for 13 to 15 months. Panel a : number of islets /mm² of pancreatic tissue. Panel b : mean area of islets. Panel c : relative area of islet to pancreatic tissue. Columns indicate the means in the control (n= 4), 1.0-mg/kg (n= 3) and 2.5-mg/kg (n= 2) groups, and symbols indicate the values in individual monkeys.

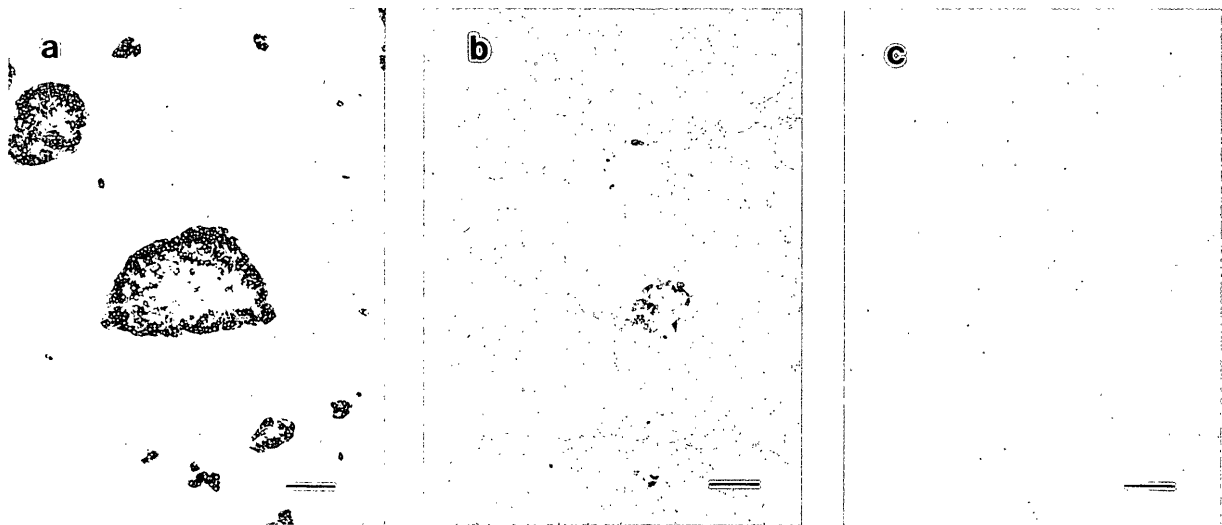


Fig. 4 Insulin-immunostaining of the pancreas in the ovariectomized cynomolgus monkeys treated with Cd for 13 to 15 months. Panels a, b and c : the pancreatic islets from control (a), 1.0-mg/kg (b) and 2.5-mg/kg (c) groups. Insulin-positive cells decreased in number at the islets of the Cd-treated groups. Scale bar=100 μm

plasma was also strongly positive as well as nucleus. On the other hand, cytoplasmic reaction in acinar area was less remarkable than that of the nucleus (Figs. 7 a, b and c).

Tissue concentrations of Cd and MT

In all Cd-treated animals, large amounts of Cd accumulated in the liver, kidney and pancreas (Figs. 8 a, b and c). The concentration of Cd in the pancreas was about 650 and

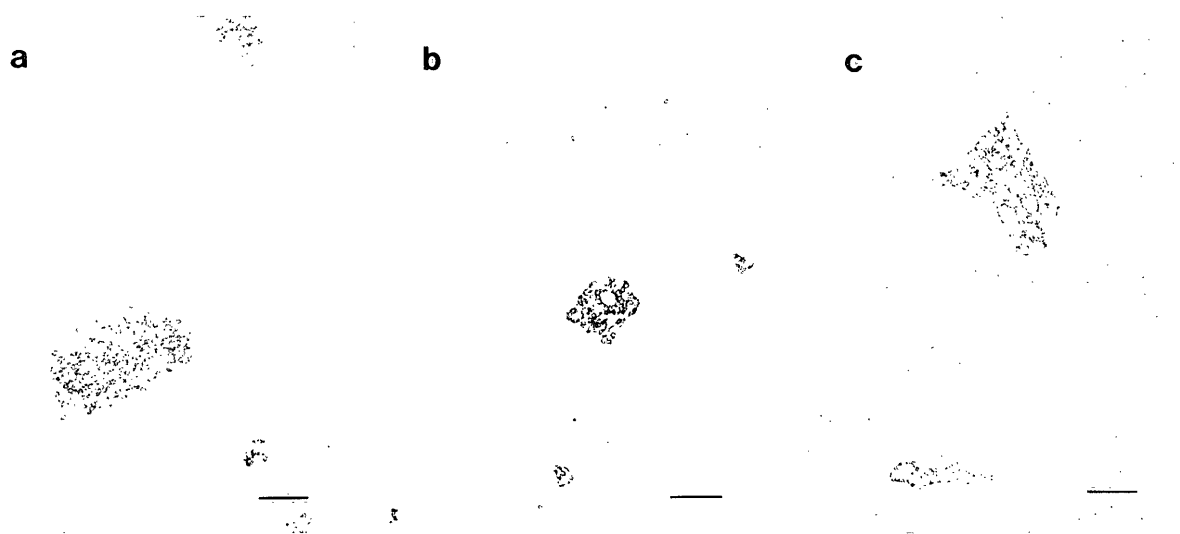


Fig. 5 Glucagon-immunostaining of the pancreas in the ovariectomized cynomolgus monkeys treated with Cd for 13 to 15 months. Panels a, b and c : the pancreatic islets from control (a), 1.0-mg/kg (b) and 2.5-mg/kg (c) groups. Glucagon-positive cells are preserved in the Cd-treated groups. Scale bar = 100 μ m

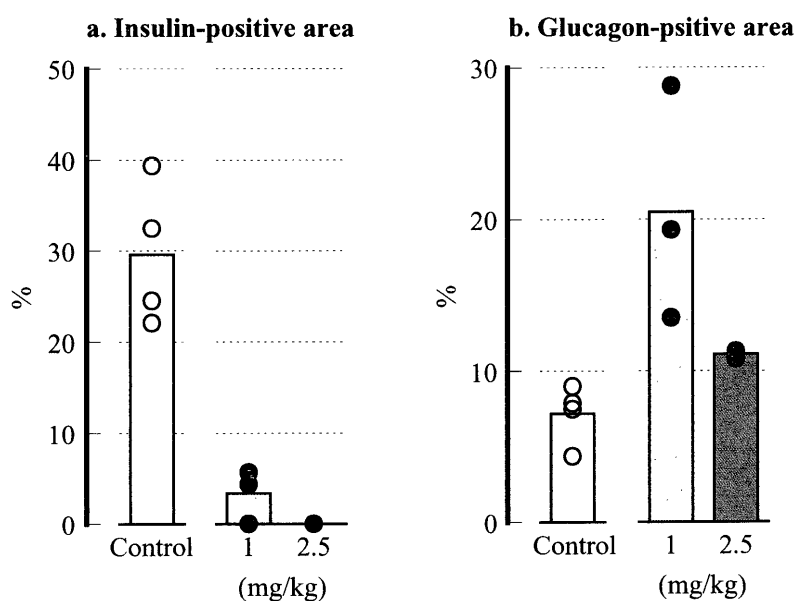


Fig. 6 Positive areas to insulin- and glucagon-immunostaining in ovariectomized cynomolgus monkeys treated with Cd for 13 to 15 months. Panel a : relative insulin-positive area to islet area. Panel b : relative glucagon-positive area to islet area. Columns indicate the means in the control (n = 4), 1.0-mg/kg (n = 3) and 2.5-mg/kg (n = 2) groups, and symbols indicate the values in individual monkeys.

900 μ g/g wet tissue for the 1.0- and 2.5-mg/kg groups, respectively, which were rather higher than those in the kidney. MT concentrations

in the above organs were remarkably elevated in a proportion to a rise of Cd concentrations in those organs (Figs. 9 a, b and c).

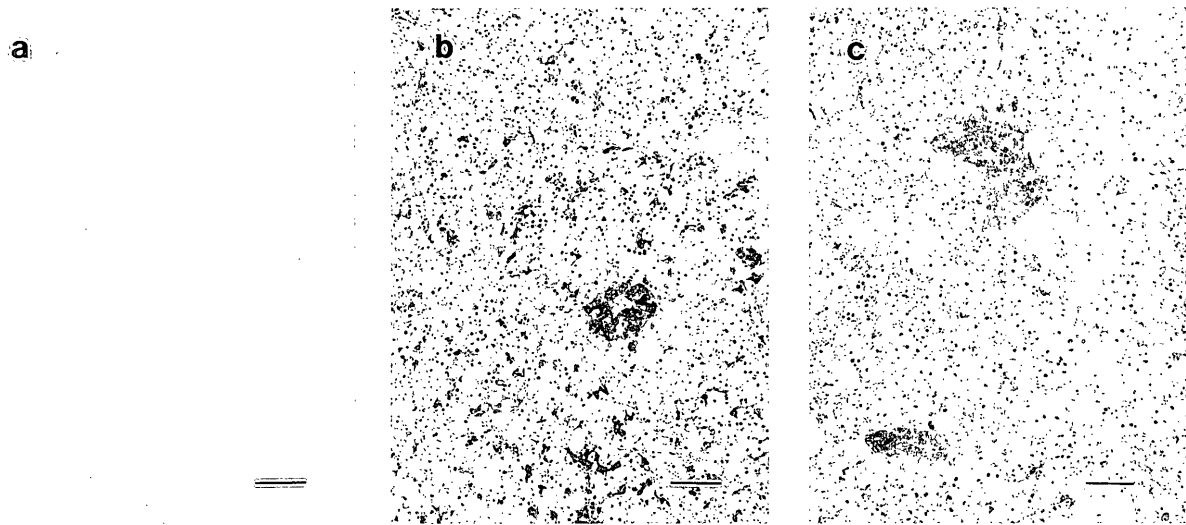


Fig. 7 MT-immunostaining of the pancreas in the ovariectomized cynomolgus monkeys treated with Cd for 13 to 15 months. Panels a, b and c : the pancreatic islets from control (a), 1.0-mg/kg (b) and 2.5-mg/kg (c) groups. MT-positive cells are localized in the islets of Cd-treated monkeys. Scale bar = 100 μ m

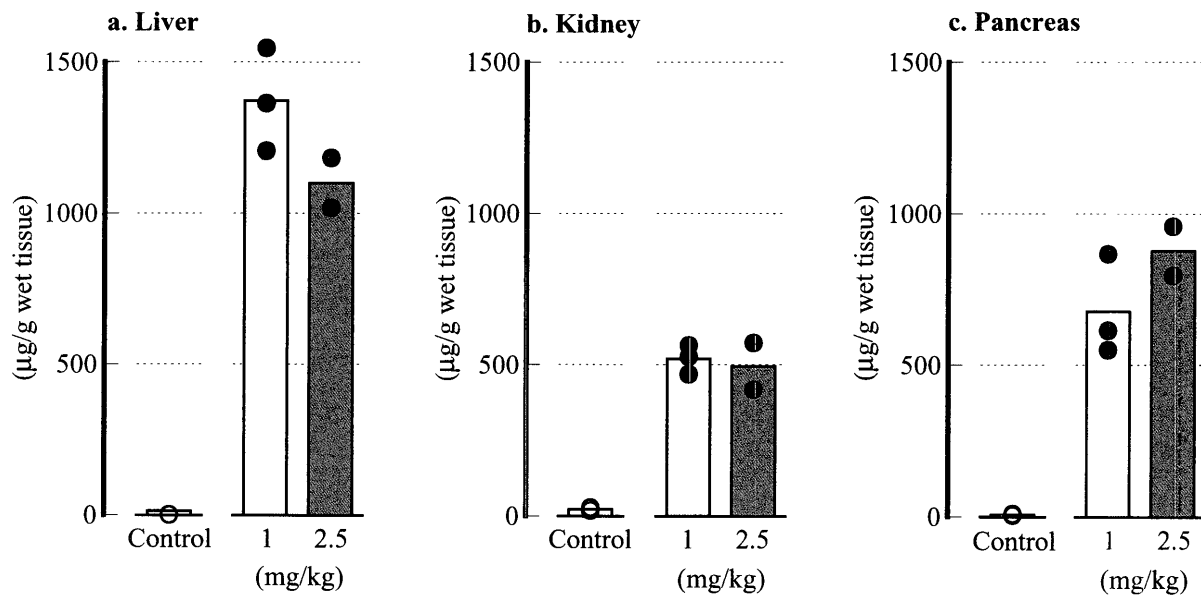


Fig. 8 Tissue concentrations of Cd in ovariectomized cynomolgus monkeys treated with cadmium for 13 to 15 months. Panels a, b and c : Cd concentrations in the liver (a), kidney (b) and pancreas (c). Columns indicate the means in the control (n = 4), 1.0-mg/kg (n = 3) and 2.5-mg/kg (n = 2) groups, and symbols indicate the values in individual monkeys.

Discussion

In the present study, we ovariectomized female monkeys before Cd treatment to put their Cd metabolisms in a postmenopausal-like condition, since 90% of IID patients are

post-menopausal women⁵⁾. Furthermore, we injected Cd intravenously, since the intestinal absorption rates of Cd in animals and human are low : 5 to 7 % for humans¹⁵⁾, and 0.36 to 0.54% for rats¹²⁾. Cadmium administered perorally or intravenously deposits in various

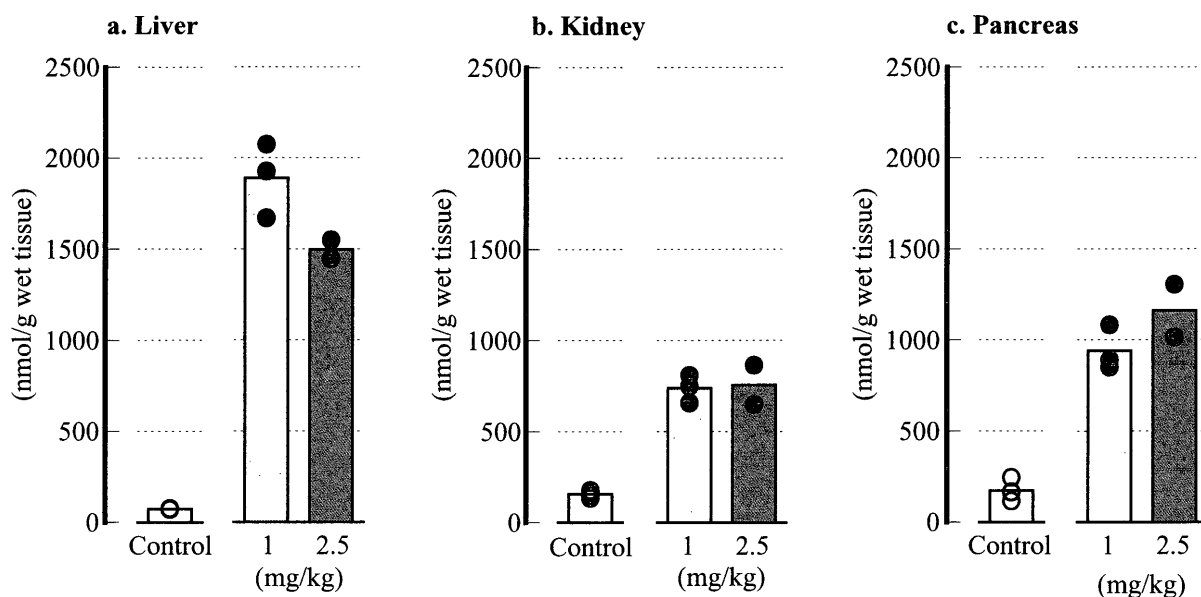


Fig. 9 Tissue concentrations of MT in ovariectomized cynomolgus monkeys treated with Cd for 13 to 15 months. Panels a, b and c: MT concentrations in the liver (a), kidney (b) and pancreas (c). Columns indicate the means in the control ($n = 4$), 1.0-mg/kg ($n = 3$) and 2.5-mg/kg ($n = 2$) groups, and symbols indicate the values in individual monkeys.

organs such as the kidney and liver¹⁵. The pancreas is one of the major accumulation sites of Cd^{10, 14, 16}, however the effects of Cd on the pancreas have not been examined extensively. Some IID patients show glycosuria⁶, however neither the functional and histological changes of the pancreas of the patients nor the relationship of those changes with Cd deposited in the organ has been elucidated.

Large amounts of Cd deposited in the pancreas of the monkeys after long-term and repeated injections of CdCl₂ in the present study. Those pancreas showed atrophy, reduction in islet number and vacuolation of the islet cells. Cadmium in the organs is bound with MT¹⁵. Immuno-histochemistry demonstrated the marked positive reaction of MT at the islets, thus indicated the accumulation of Cd in the islets. Furthermore, histochemical staining for insulin and glucagon revealed a specific damage on the insulin-positive cells (B cells). These results indicate that Cd accumulated in the pancreas damaged islet cells,

especially B cells of monkeys and induced diabetic clinical signs such as hyperglycemia and glycosuria.

In conclusion, chronic intravenous injection of Cd to cynomolgus monkeys induced the accumulation of the metal in the pancreas, degeneration of B cells of pancreatic islets and diabetic clinical signs. These results suggest that the pancreas is one of the major target organs of the chronic Cd poisoning and the pancreatic endocrine functions should be assessed in evaluating the health effects of chronic Cd-exposure in humans.

References

- 1) Elinder, C. G. 1992. Cadmium as an environmental hazard. *IARC Sci. Publ.*, 118: 123-132.
- 2) Hiratsuka, H., Katsuta, O., Toyota, N., Tsuchitani, M., Umemura, T. and Marumo, F. 1996. Chronic cadmium exposure-induced renal anemia in ovariectomized rats. *Toxicol. Appl. Pharmacol.*, 137: 28-

- 236.
- 3) Hiratsuka, H., Katsuta, O., Toyota, N., Tsuchitani, M., Akiba, T., Marumo, F. and Umemura, T. 1997. Iron deposition at mineralization fronts and osteoid formation following chronic cadmium exposure in OVX rats. *Toxicol. Appl. Pharmacol.*, 143 : 348-356.
 - 4) Hu, H. 2000. Exposure to metals. *Prim. Care*, 27 : 983-996.
 - 5) Kajikawa, K., Kitagawa, M., Nakanishi, I., Ueshima, H., Katsuda, S. and Kuroda, K. 1974. A pathological study of "Itai-itai disease". *J. Juzen Med. Soc.*, 93 : 309-347. (in Japanese)
 - 6) Kasuya, M., Aoshima, K., Teranishi, H., Katoh, T., Fan, J. and Hagino, S. 1997. II-4. Urinalysis and Hematology in Itai-itai Disease. *Kankyo-Hoken Report*, 61 : 187-193. (in Japanese)
 - 7) Katsuta, O., Hiratsuka, H., Matsumoto, J., Tsuchitani, M., Umemura, T. and Marumo, F. 1993. Ovariectomy enhances cadmium-induced nephrotoxicity and hepatotoxicity in rats. *Toxicol. Appl. Pharmacol.*, 119 : 267-274.
 - 8) Katsuta, O., Hiratsuka, H., Matsumoto, J., Iwata, H., Toyota, N., Tsuchitani, M., Umemura, T. and Marumo, F. 1994. Cadmium-induced osteomalacic and osteopetrotic lesions in the OVX rats. *Toxicol. Appl. Pharmacol.*, 126 : 58-68.
 - 9) Kurata, Y., Katsuta, O., Hiratsuka, H., Tsuchitani, M. and Umemura, T. 2001. Intravenous $1\alpha, 25(\text{OH})_2$ vitamin D_3 (calcitriol) pulse therapy for bone lesions in a murine model of chronic cadmium toxicosis. *Int. J. Exp. Path.*, 82 : 43-53.
 - 10) Kuzuhara, Y., Furusho, Y., Sumino, K. and Hayashi, C. 1997. II-15 Tissue Metal Concentrations in Autopsy Case. *Kankyo-Hoken Report*, 61 : 243-262. (in Japanese)
 - 11) Noda, M. and Kitagawa, M. 1990. A quantitative study of iliac bone histopathology on 62 cases with itai-itai disease. *Calcif. Tissue Int.*, 47 : 66-74.
 - 12) Ohta, H., Yamauchi, Y., Nakakita, M., Tanaka, H., Asami, S., Seki, Y. and Yoshikawa, H. 2000. Relationship between renal dysfunction and bone metabolism disorder in male rats after long-term oral quantitative cadmium administration. *Ind. Health.*, 38 : 339-355.
 - 13) Onosaka, S., Tanaka, K., Doi, M. and Okahara, K. 1978. A simplified procedure for determination of metallothionein in animal tissues. *Eisei Kagaku*, 24 : 128-133. (in Japanese)
 - 14) Onosaka, S. and Cherian, M. G. 1981. The induced synthesis of metallothionein in various tissues of rat in response to metals. I. Effect of repeated injection of cadmium salts. *Toxicology*, 22 : 91-101.
 - 15) Robert, A. G. and Thomas, W. C. Toxic Effects of Metals. In : *Casarett & Doull's TOXICOLOGY*, 6th ed., pp. 822-826, Curid DK ed., McGraw-Hill, New York.
 - 16) Sato, M. and Takizawa, Y. 1982. Cadmium-binding proteins in human organs. *Toxicol. Lett.*, 11 : 269-273.
 - 17) Umemura, T. 2000. Experimental reproduction of itai-itai disease, a chronic cadmium poisoning of humans, in rats and monkeys. *Jpn. J. Vet. Res.*, 48 : 15-28.
 - 18) Yamashita, H. and Kitagawa, M. 1996. Histomorphometric study of ribs with looser zones in Itai-itai disease. *Calcif. Tissue Int.*, 58 : 170-176.
 - 19) Yasuda, M., Miwa, A. and Kitagawa, M. 1995. Morphometric studies of renal lesions in itai-itai disease : chronic cadmium nephropathy. *Nephron*, 69 : 14-19.