HOKKAIDO UNIVERSITY

Title	Alveolar echinococcosis of the liver in children
Author(s)	Yoshida, Tadashi; Kamiyama, Toshiya; Okada, Tadao et al.
Citation	Journal of Hepato-Biliary-Pancreatic Sciences, 17(2), 152-157 https://doi.org/10.1007/s00534-009-0114-6
Issue Date	2010-03
Doc URL	https://hdl.handle.net/2115/43105
Rights	The original publication is available at www.springerlink.com
Type	journal article
File Information	JHBPS17-2_152-157.pdf

Hokkaido University Collection of Scholarly and Academic Papers : HUSCAP

Alveolar Echinococcosis of the Liver in Children

[1] Department of Digestive and General Surgery, Hokkaido University Graduate School of Medicine, Kita-ku, North 15, West 7, Sapporo 060-8638, Japan

[2] Department of Pediatric Surgery, Hokkaido University Graduate School of Medicine, Sapporo, Japan

Tadashi Yoshida[1], Toshiya Kamiyama[1], Tadao Okada[2], Kazuaki Nakanishi[1], Hideki Yokoo[1], Hirofumi Kamachi[1], Michiaki Matsushita[1], Naoki Sato[1], Fumiaki Sasaki[2], and Satoru Todo[1]

Address reprint requests to: Tadashi Yoshida, MD; Department of Digestive and General Surgery, Hokkaido University Graduate School of Medicine, Kita-ku, Kita 15, Nishi 7, Sapporo 060-8638, Japan

TEL: +81-11-706-5927 FAX: +81-11-717-7515

E-mail: ytadashi324@yahoo.co.jp

Short title: Alveolar Echinococcosis.

Running title: Alveolar Echinococcosis of the Liver in Children.

Keywords: child, alveolar echinococcosis, liver

Abstract

Background/Purpose. Alveolar echinococcosis of the liver (AEL) is a zoonosis that is distributed in cold regions of the northern hemisphere. The disease is mostly found in adults and rarely in pediatric patients because it tends to be slow growing.

Patients and Methods. Ten Japanese pediatric patients with AEL (under fifteen-year-old) have been operated on in Hokkaido University Hospital from January 1936 to June 2008. We examined these children and revealed the characteristics of AEL.

Results. The patients included three males and seven females whose mean age was 10.9 years old, ranging from 7 to 15. The length of follow-up was from 3 months to 33 years (median: 19 years). Six cases were picked up by mass screening and nine cases who underwent hepatectomy are still alive and one case whose tumors were unresectable died of liver failure.

Conclusion. Our cases indicate that some AEL pediatric patients advanced rapidly, so early detection is imperative. Thus, screening examinations are essential for children in contaminated areas, and complete radical resection should be performed if a liver tumor is found on a screening examination and diagnosed as AEL.

Introduction

Echinococcosis of the liver is a zoonosis caused by tape worms belonging to the genus Echinococcus (family Taeniidae). Echinococcus is mainly classified into two groups, *Echinococcus granulosus* and *Echinococcus multilocularis*, which cause cystic echinococcosis and alveolar echinococcosis, respectively. While Echinococcus granulosus is distributed widely throughout the world, Echinococcus multilocularis is distributed in cold regions of the northern hemisphere such as Europe, Russia, North America, and Japan.[1,2] Alveolar echinococcosis is found in the majority of echinococcosis cases in Japan, which is found almost only in Hokkaido in northern Japan.[2,3] Because alveolor echinococcosis of the liver (AEL) tends to be slow growing, the disease is mostly found in adults and rarely in pediatric patients. It has been reported that patients should receive early treatment because AEL often invades or metastasizes to other organs like a malignant neoplasm.[4] As far as we know, only two case reports of AEL in children have been published in Japan, except for our cases, and there have been no other summary reports of AEL in children.[2,5] We report ten cases of AEL in Japanese children in our hospital.

Patients and Methods

1. Patients

Ten pediatric Japanese patients with AEL (under fifteen years old) have been operated on in Hokkaido University Hospital from January 1936 to June 2008.

2. Methods

We performed checkups and revealed the epidemiological characteristics, clinicopathological findings, treatments and clinical courses of pediatric patients with AEL. Mass screening for AEL have been performed in Hokkaido, Japan. The previous mass screening method utilized serological tests in the first step, which were complement fixation test (CF), indirect hemagglutination (IHA) and immunoelectrophoresis (IE) until 1983. Physical examination for hepatomegaly and examination for calcification by X-ray were performed in the second step. From 1984, enzyme-linked immunosorbent assay (ELISA) was introduced as the primary serological screening test and ultrasonography (US) has been adopted for those patients who give positive results by ELISA as the second step examination.[6] AEL was diagnosed by serological tests such as ELISA and Western-blotting (WB) and imaging methods such as X-ray, US, computed tomography (CT) and magnetic resonance imaging (MRI).

Results

Ten patients were pathologically confirmed as AEL. These

included three males and seven females whose mean age was 10.9 years old, ranging from 7 to 15. This makes up 3.8% of all operated AEL patients (263 cases) in our hospital.

The habitation areas of the patients were spread widely throughout Hokkaido, Japan. Six patients lived in Nemuro and Kushiro sub-prefectures (eastern Hokkaido), two in Oshima (southern Hokkaido), and two in Ishikari and Kamikawa (central Hokkaido).

Eight AEL patients were asymptomatic and their method of diagnosis were mass screening (six cases) and close examinations for enuresis (two cases). Only two patients were symptomatic with symptoms such as fever, abdominal pain, and general fatigue. No patients had any past or family histories of AEL.

While three patients considered drinking spring water or well water as the transmission route, the other seven patients had not drank spring water and it was unknown how they had been infected.

At the time of diagnosis, the staging system proposed by Nakajima et al was used.[7] There were 2, 4, 0, 2, and 2 cases in stages Ⅰ, Ⅱ, Ⅲa, Ⅲb, and Ⅳ, respectively (Table 1).

We utilized serological tests and imaging methods as a means of diagnosing AEL. CF, IHA, and IE were performed for 6, 6, and 5 patients, including 6, 2, and 2 positive, respectively. ELISA was performed for six patients, including two positive and four

suspected positive cases. WB was performed for four patients and all of them were positive. All of the patients had abdominal X-ray examinations and abnormal calcifications of the right upper abdomen were detected in six patients. Abdominal US and CT were performed for seven patients and cystic lesions and/or calcifications of the liver were detected in the seven patients, respectively. The US and CT findings of AEL are categorized into four patterns, respectively, by Sasaki et al.[8] One patient underwent MRI and small round cysts with a weakly enhanced solid component were detected (Table 2) .[9]

The operative procedures were hepatectomy in eight patients, including two cases with hepatectomy with resection of other organs, exploratory laparotomy in one, and marsupialization in one (Table 3).

The length of follow-up was from 3 months to 33 years (median: 19 years). All of the ten patients, except for case 1, are still alive (Table 4). Case 1 had diffuse unresectable foci of AEL at the time of diagnosis and exploratory laparotomy was done. In spite of chemotherapy by thymol ester of palmitic acid after surgery, she died of liver failure combined with progression of AEL three years later. Case 3 underwent marsupialization for drainage because of a large tumor that occupied almost the entire left lobe of the liver, and extended left lobectomy was performed as a two-staged operation. Case 4 underwent partial hepatectomy (S5, S6, S8). She needed partial hepatectomy again

because of stump recurrence after a four-year interval from the first operation. Case 7 underwent extended left lobectomy and para-aorta lymph node dissection. She was not treated with chemotherapy after surgery despite residual para-aorta lymph node metastasis because the safety of albendazole for pediatric patients was not confirmed at the time. Case 9 underwent partial hepatectomy and resection of the diaphragm and abdominal wall. She was treated with albendazole after surgery, taking care with strict examinations, because of the infiltration of the abdominal wall and uncertainty of dissemination. She is alive and free from relapse. Case 10 was ten-year-old boy and examinations for enuresis were performed. Abdominal CT showed the calcifications on the S8 of the liver (two lesions). ELISA, WB test, US, and MRI were performed and he was diagnosed as AEL (Figure 1). He underwent partial hepatectomy (S8) (Figure 2, 3).

Discussion

AEL is often called lethal parasitosis because it can lead to death if left untreated and the progression of the disease is classified as follows: incubative, advanced, and end period. The length of the incubative period is considered to be five to fifteen years. As patients were likely to be asymptomatic

during the incubative period, the disease was often discovered in more advanced periods in the past. The progression of AEL was considered to be slow, but AEL in pediatric patients can advance rapidly according to our cases, especially as seen in case 1.

Although, CF, IHA, and IE had been used for mass screening, they were not appropriate for mass screening because they could often give false-negative for some patients in early stage.[3,6] Since the primary medical examination by ELISA and the secondary by US were introduced in 1984 in Hokkaido, Japan, AEL is now sometimes found in early stages.[10] The absorbance of antibody to multilocular echinococcus antigen (ELISA value) was detected on ELISA and the criteria of ELISA values are as follows: positive ≥ 1.00, negative ≤ 0.50 and suspected positive 0.51< 0.99.[10,11] The antibodies to multilocular echinococcus antigen such as C antigen are detected in WB.[10] The calcifications and cysts of the liver on US and CT have been widely used as characteristic findings and now MRI is considered to be useful for diagnosis.[8,9] It is reported that the MRI findings of AEL are small round cysts with a weakly enhanced solid component and the cystic component can be a large and/or irregular lesion, and such lesions are depicted clearly on T2-weighted MRI by Kodama et al.[9] Thus, it is hoped that MRI plays an important role in non invasive examinations. In Hokkaido, the primary medical examination by ELISA is done for applicants older than

the third-year student and candidates who are classified into positive or suspected positive should undergo a secondary medical examination. In our case, a seven-year-old girl died of liver failure because the foci of AEL occupied the entire liver and was unresectable at diagnosis. This indicates that screening examination is essential even for children in contaminated areas and complete examination for AEL should be done if a liver tumor is found on a screening examination and diagnosed as AEL.

The only treatment for pediatric and adult AEL cases is radical resection, and nine cases whose primary lesions were completely resected were alive at the most recent follow up. In surgery, the ideal surgical margin is at least 1 cm in our hospital because the foci of AEL do not have any capsules and the borders of the foci are discontinuous and irregular.[12] Case 4 had a stump recurrence after four years from the first operation and re-resection was performed. She is still alive and free from relapse twenty-four years after the second surgery. This indicates that complete resection is very important. Despite the fact that para-aortic lymph node metastasis was unresectable during the primary operation in case 7, she has not progressed over the twenty-eight years after the surgery. It is noteworthy that radical resection of the primary lesion can offer long-term survival even if metastatic foci are residual.

Albendazole, one of the benzimidazole carbamates, is often administrated to adult patients with invasion to other organs, dissemination, and non curative resection or palliative operation. It was found that albendazole reduced the foci of AEL in six of fourteen cases with non curative resections and two of five palliative operations, respectively, by Ishizu et al.[13] It is reported that adverse effects were mild and included one case each of mild elevation of serum transaminase level and alopecia in adult patients. However, there has not been extensive experience of albendazole in pediatric patients.[13,14] In case 9, the AEL tumor ruptured and peritoneal dissemination was suspected before the operation. She was prescribed albendazole and has taken it for two and half years after surgery without any adverse effects or recurrences. It remains possible that albendazole could prevent relapse for pediatric patients in cases of non curative resection or palliative operation. Actually, we have not laid down the strict indication of the drug therapy for pediatric patients of AEL. Because there have been no reports of the effect of thymol ester of palmitic acid for AEL patients since 1965, the effect has been uncertain over the last few decades and we have not prescribed it after case 2.[15] We prescribe albendazole for pediatric patients of AEL only in cases of non curative resection or palliative operation under the strict monitoring of adverse effects (general condition and laboratory data) after the report on albendazole by Ishizu et

al in 1997.[13]

We report ten cases of AEL in pediatric patients. Although it was thought that the foci of AEL tended to grow slowly, our cases indicate that some cases of AEL in pediatric patients can advance rapidly. In summary, a screening examination is essential for children in contaminated areas, and complete radical resection should be performed if a liver tumor is found on a screening examination and diagnosed as AEL.

References

1) Rausch RL. On the ecology and distribution of Echinococcus spp. (Cestoda Taeniidae) and characteristics of their development in the intermediate host. Ann Parasitol Hum Comp 1967; 42: 19-63.

2) Sugai M, Kimura N, Ishido K, Munakata H, Hakamada K, Hiroshi Satoh, et al. A case report of Alveolar Echinococcus with pulmonary lesions in a child (in Japanese with English abstract). Nihon Shoni-Geka Gakkai Zasshi (Jpn J Pediatr Surg) 2005; 41(2): 237-242.

3) Sasaki F, Hata Y, Sato N, Sato Y, Igarashi M, Kameda H, et al. Alveolar hydatid disease of the liver in children (in Japanese with English abstract). Nihon Shoni-Geka Gakkai Zasshi (Jpn J Pediatr Surg) 1989; 25(1): 47-52.

4) Sasaki F, Hata Y, Sato N, Hamada H, Uchino J. Alveolar Echinococcosis of the liver in children. Hokkaido University Medical Library Series 1993; 30: 131-136.

5) Mizumoto M, Ishikawa N. A seven-year-old boy with Echinococcosis found by scattered calcification in the liver (in Japanese with English abstract). Nihon Shonikagaku Zasshi (Jpn J Pediatr) 1997; 101(6): 1071-1075.

6) Sato N, Uchino J, Suzuki K, Kamiyama T, Takahashi M, Shimamura T, et al. Mass screening. Hokkaido University Medical Library Series 1993; 30: 121-129.

7) Nakajima Y, Sato N, Uchino J. Stage of the disease. Hokkaido University Medical Library Series 1993; 30: 115-119

8) Sasaki F, Ohkawa Y, Sato N, Uchino J, Hata Y. Imaging diagnosis of alveolar echinococcosis in young patients. Pediatr Radiol 1997; 27: 63-66.

9) Kodama Y, Fujita N, Shimizu T, Endo H, Nambu T, Sato N, et al. Alveolar echinococcosis: MR findings in the liver. Radiology 2003; 228: 172-177.

10) Furuya K, Sato N, Uchino J. Enzyme-linked immunosorbent assay (ELISA) and Western blotting (WB) test. Hokkaido University Medical Library Series 1993; 83: 75-91.

11) Sato H, Mitamura H, Arai J, Kumagai M. Serological diagnosis of human hydatid diseases by enzyme-linked immunosorbent assay (Part 1) Enzyme-linked immunosorbent assay by multilocular Echinococcus antigen (in Japanese with English abstract). Report of the Hokkaido Institute of Public Health 1983; 33: 8-15.

12) Uchino J, Sato N, Nakajima Y, Matsushita M, Takahashi M, Une Y. Treatment. Hokkaido University Medical Library Series 1993; 30: 137-149.

13) Ishizu H, Uchino J, Sato N, Aoki S, Suzuki K, Kuribayashi H. Effect of albendazole on recurrent and residual alveolar echinococcosis of the liver after surgery. Hepatology 1997; 25(3): 528-531.

14) Sato N, Ishizu H, Aoki S, Akabane H, Watanabe I, Takahashi

M, et al. Effectiveness of albendazole therapy for alveolar echinococcosis of the liver patients (in Japanese with English abstract). Shinryo to Shinyaku 1995; 32: 135-145.

15) Plotnikov NN, Ozeretskovskaia NN, Alekseeva MI, Turchins ME, Vitebskii laD, Diakin VM et al. Use of tepal (thymol ester of palmitic acid) in human echinococcosis (in Russian). Sov Med 1965; 28: 129-136.

Figure Legends

Figure 1. MRI shows two lesions of AEL. (a)T1-weighted image obtained with small round cysts in the S8 of the liver (arrow).(b) Half-Fourier acquisition single-shot turbo spin echo (HASTE) image obtained with small high intensity lesions in the S8 of the liver (arrow).

Figure 2. The aggregated small calcifications were found on the surface of the liver (S8) during the operation (arrows).

Figure 3. The resected specimen shows solid components with micro cysts.

9

=523
TR:
TE

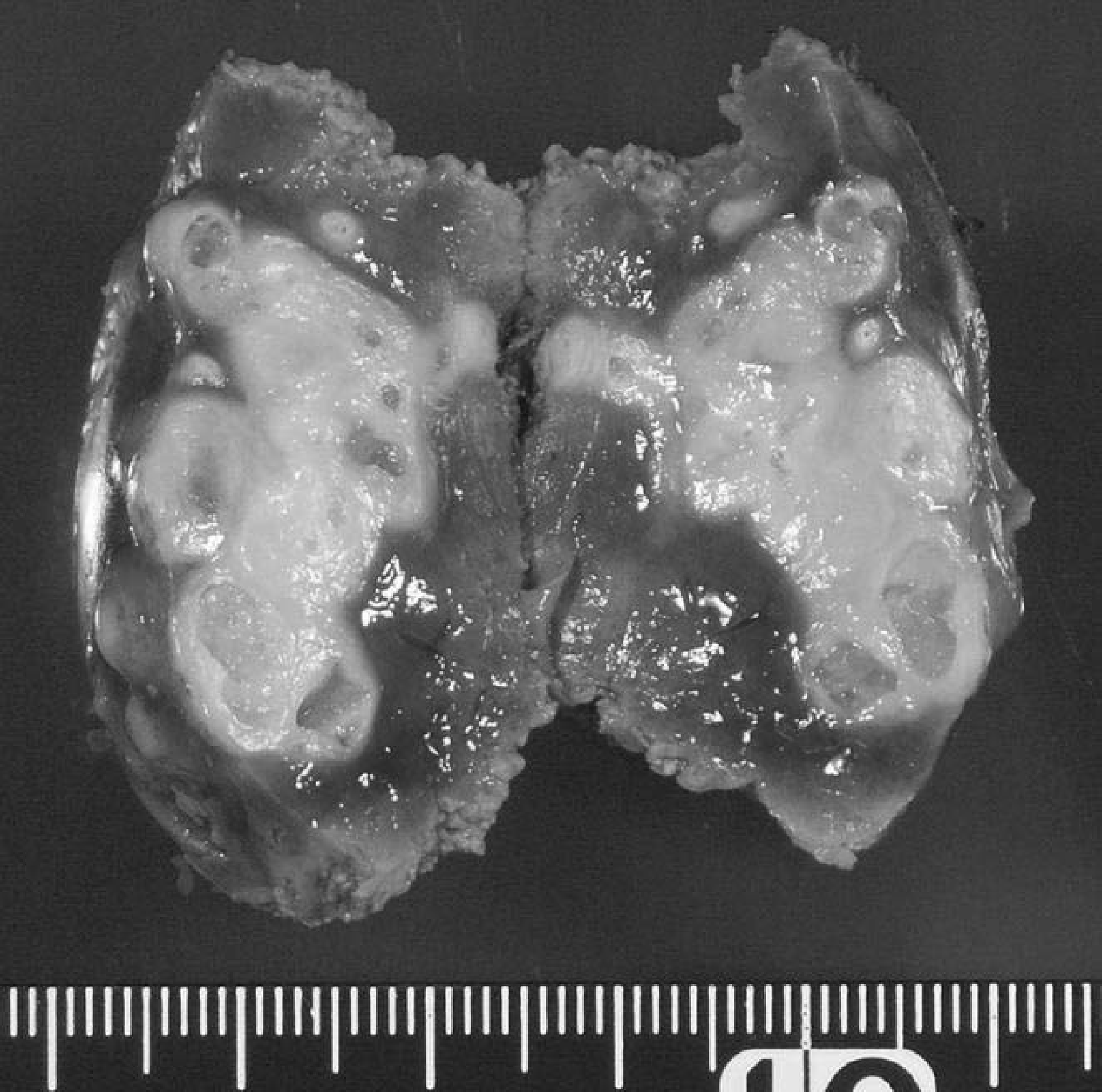
10

Table 1　Condition at the time of diagnosis

Case	Year	Age	Sex	Habitation area	Chief complaint	Initial opportunity for diagnosis	Past history	Family history	Spring water	Stage*
1	1966	7	F	Nemuro	fever, abdominal pain	examination for hepatomegaly	morbilli, scarlatina	−	unknown	Ⅳ
2	1975	15	M	Nemuro	none	mass screening	−	Father: tuberculosis	+	Ⅰ
3	1977	13	M	Nemuro	none	mass screening	−	−	+	Ⅲb
4	1980	15	F	Nemuro	none	mass screening	unknown	unknown	unknown	Ⅱ
5	1987	8	F	Oshima	none	mass screening	unknown	unknown	unknown	Ⅱ
6	1988	12	F	Kushiro	none	mass screening	unknown	unknown	unknown	Ⅱ
7	1990	10	F	Oshima	none (enuresis)	examination for enuresis	−	−	−	Ⅳ
8	1997	10	F	Nemuro	none	mass screening	−	−	+	Ⅱ
9	2005	9	F	Ishikari	fever, fatigue	examination for fever and fatigue	−	−	−	Ⅲb
10	2008	10	M	Kamikawa	none (enuresis)	examination for enuresis	−	−	−	Ⅰ

* Staging system proposed by Nakajima

Table 2　Diagnostic method

Case	CF	IHA	IE	ELISA	ELISA value	WB	X-ray	US	CT	MRI
1	+	N.D.	N.D.	N.D.	−	N.D.	*	N.D.	N.D.	N.D.
2	+	+	+	N.D.	−	N.D.	*	N.D.	N.D.	N.D.
3	+	+	+	N.D.	−	N.D.	*	N.D.	N.D.	N.D.
4	+	−	−	N.D.	−	N.D.	*	†1	‡1	N.D.
5	+	−	−	±	0.74	N.D.	−	†1	‡1	N.D.
6	+	−	−	+	unknown	N.D.	*	†1	‡1	N.D.
7	N.D.	N.D.	N.D.	+	1	+	*	†4	‡1	N.D.
8	N.D.	N.D.	N.D.	±	0.82	+	−	†2	‡2	N.D.
9	N.D.	N.D.	N.D.	±	0.896	+	−	†4	‡4	N.D.
10	N.D.	N.D.	N.D.	±	0.643	+	−	†1	‡1	§

CF; complement fixation test,　IHA; indirect hemagglutination, IE; immunoelectrophoresis

ELISA; enzyme-linked immunosorbent assay, WB; Western-Blotting

US; ultrasonography, CT; computed tomography

MRI; magnetic resonance imaging,　N.D. ; not done

* Calcification on abdominal X-ray

†1 Granular hyperechoic foci with or without acoustic shadow

†2 Irregular echogenic stroma, i.e., inflammatory or necotic changes are more echogenic than normal liver parenchyma and less echogenic than calcified parenchyma

†3 Small clustered vesicles called metacestodes detected as small hypoechoic areas with irregular margins

†4 Large anechoic or hypoechoic areas of liquefaction necrosis and/or cysts which are occasionally accompanied by an irregular internal echo

(†1 to †4: US finding categories proposed by Sasaki)

‡1 Focal high attenuation areas of calcification

‡2 Irregular low attenuation areas

‡3 Small, low attenuation cysts less than 2 cm in diameter

‡4 Large, low attenuation cysts more than 2cm in diameter

(‡1 to ‡4: CT finding categories proposed by Sasaki)

§　Small round cysts with a weakly enhanced solid component

Table 3 Operation

Case	Location*	Invasion / metastasis	Operative procedure
1	APML	–	Simple laparotomy
2	L	–	Lateral segmentectomy
3	AML	Stomach, diaphragm	Marsupialization + extended left lobectomy
4	PA	–	Partial hepatectomy x 2
5	PA	–	Right lobectomy
6	PA	–	Right lobectomy
7	PAM	Para-Aorta lymph node	Extended right lobectomy + lymph node dissection
8	PA	–	Right lobectomy
9	AP	Diaphragm, abdominal wall	Partial hepatectomy + Diaphragm and abdominal wall resection
10	A	–	Partial hepatectomy

* A; anterior segment of the liver, P; posterior, M; middle, L; lateral

Table 4　Post operative therapy and outcome

Case	Residual lesion	Post operative therapy	Years since operation/outcome
1	primary lesion	thymol ester of palmitic acid	3/Died
2	–	–	33/Alive
3	–	–	31/Alive
4	–	–	28/Alive
5	–	–	21/Alive
6	–	–	20/Alive
7	Para-Aorta Lymph node	–	18/Alive
8	–	–	11/Alive
9	suspect of peritoneal dissemination	albendazole	2/Alive
10	–	–	3months/Alive