



HOKKAIDO UNIVERSITY

Title	Autologous Osteochondral Mosaicplasty for Osteochondritis Dissecans of the Elbow in Teenage Athletes : Surgical Technique
Author(s)	Iwasaki, Norimasa; Kato, Hiroyuki; Ishikawa, Jyunichi et al.
Citation	Journal of Bone and Joint Surgery : American Volume, 92-A(Suppl. 1, pt. 2), 208-216 https://doi.org/10.2106/JBJS.J.00214
Issue Date	2010-09-01
Doc URL	https://hdl.handle.net/2115/43945
Rights	Copyright © 2010 by The Journal of Bone and Joint Surgery, Incorporated
Type	journal article
File Information	JBJS92_208-216.pdf



THE JOURNAL OF BONE & JOINT SURGERY

JB&JS

This is an enhanced PDF from The Journal of Bone and Joint Surgery

The PDF of the article you requested follows this cover page.

Autologous Osteochondral Mosaicplasty for Osteochondritis Dissecans of the Elbow in Teenage Athletes: Surgical Technique

Norimasa Iwasaki, Hiroyuki Kato, Jyunichi Ishikawa, Tatsuya Masuko, Tadanao Funakoshi and Akio Minami

J Bone Joint Surg Am. 2010;92:208-216. doi:10.2106/JBJS.J.00214

This information is current as of October 3, 2010

Reprints and Permissions

Click here to [order reprints or request permission](#) to use material from this article, or locate the article citation on jbjs.org and click on the [Reprints and Permissions] link.

Publisher Information

The Journal of Bone and Joint Surgery
20 Pickering Street, Needham, MA 02492-3157
www.jbjs.org

Autologous Osteochondral Mosaicplasty for Osteochondritis Dissecans of the Elbow in Teenage Athletes

Surgical Technique

By Norimasa Iwasaki, MD, PhD, Hiroyuki Kato, MD, PhD, Jyunichi Ishikawa, MD, PhD, Tatsuya Masuko, MD, PhD, Tadao Funakoshi, MD, PhD, and Akio Minami, MD, PhD

Investigation performed at the Department of Orthopaedic Surgery, Hokkaido University School of Medicine, Sapporo, and the Department of Orthopaedic Surgery, Shinshu University School of Medicine, Matsumoto, Japan

The original scientific article in which the surgical technique was presented was published in JBJS Vol. 91-A, pp. 2359-66, October 2009

ABSTRACT FROM THE ORIGINAL ARTICLE

BACKGROUND: Although autologous osteochondral mosaicplasty is widely used as a procedure for osteochondritis dissecans lesions, the effectiveness of this procedure in elbow lesions remains unclear. Our aim was to clarify the surgical efficacy of mosaicplasty for teenage athletes with advanced lesions of capitellar osteochondritis dissecans.

METHODS: From 2001 to 2006, nineteen teenage male patients who were competitive athletes and had advanced lesions of capitellar osteochondritis dissecans underwent mosaicplasties. The mean age of the patients was 14.2 years. The surgical technique involved obtaining small-sized cylindrical osteochondral grafts with a mean diameter of 3.5 mm from the lateral periphery of the femoral condyle at the level of the patellofemoral joint and transplanting the grafts (mean, 3.3 grafts) to prepared osteochondral defects. The patients were evaluated clinically and radiographically at a mean of forty-five months after surgery.

RESULTS: Eighteen patients were free from elbow pain, and one had mild pain occasionally. The mean total arc of elbow motion and standard deviation increased significantly from $112^{\circ} \pm 17^{\circ}$ preoperatively to $128^{\circ} \pm 12^{\circ}$ postoperatively ($p < 0.005$). The mean clinical score described by Timmerman and Andrews (with a maximum of 200 points) improved significantly from 131 ± 23 points preoperatively to 191 ± 15 points postoperatively ($p < 0.0001$). All patients except one had an excellent or good clinical result. All donor knees were graded as excellent on the basis of the Lysholm knee scoring system. All patients except two returned to a competitive level of the sport they had previously played. Neither loose-body formation nor secondary osteoarthritic changes were found in any patient.

CONCLUSIONS: The current midterm results indicate that mosaicplasty can provide satisfactory clinical outcomes for teenage athletes with advanced capitellar osteochondritis dissecans lesions.

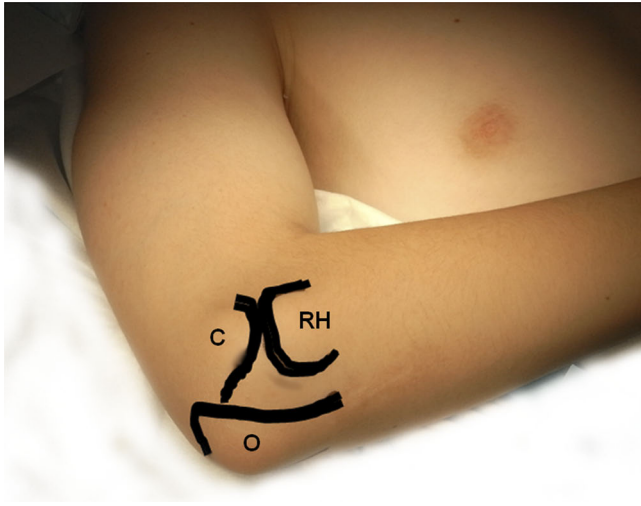
LEVEL OF EVIDENCE: Therapeutic Level IV. See Instructions to Authors for a complete description of levels of evidence.

ORIGINAL ABSTRACT CITATION: "Autologous Osteochondral Mosaicplasty for Osteochondritis Dissecans of the Elbow in Teenage Athletes" (2009;91:2359-66).

DISCLOSURE: The authors did not receive any outside funding or grants in support of their research for or preparation of this work. Neither they nor a member of their immediate families received payments or other benefits or a commitment or agreement to provide such benefits from a commercial entity.



A video supplement to this article will be available from the *Video Journal of Orthopaedics*. A video clip will be available at the JBJS web site, www.jbjs.org. The *Video Journal of Orthopaedics* can be contacted at (805) 962-3410, web site: www.vjortho.com.

**FIG. 1**

The patient is placed supine on the operating table. The affected arm is brought over a bolster. RH = radial head, C = capitellum, and O = olecranon.

INTRODUCTION

Because of the limited potential of articular cartilage for self-repair, the treatment of advanced osteochondritis dissecans of the humeral capitellum (capitellar osteochondritis dissecans) remains a challenge. Although various surgical options have been advocated to treat advanced capitellar osteochondritis dissecans lesions, these procedures have been shown to provide only temporary relief of symptoms, and osteoarthritis can still result¹⁻⁵. One way to achieve satisfactory long-term outcomes may be to resurface these lesions with hyaline cartilage. Because autologous osteochondral mosaicplasty (mosaicplasty) provides hyaline repair of articular cartilage defects⁶⁻⁸, this procedure may be a good option for treating advanced capitellar osteochondritis dissecans lesions⁹⁻¹³.

SURGICAL TECHNIQUE

Under general anesthesia, the patient is placed supine with the

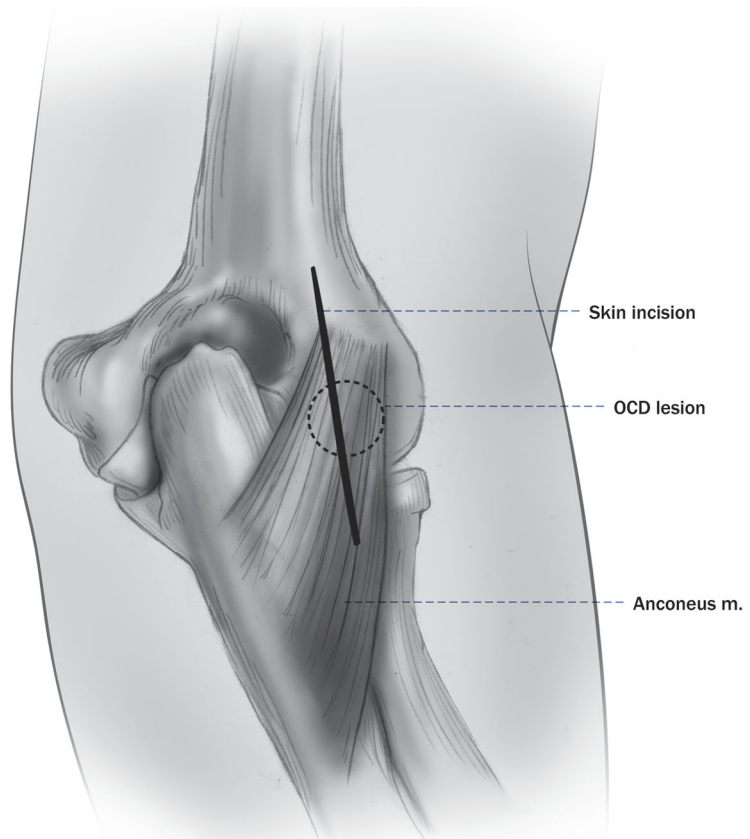
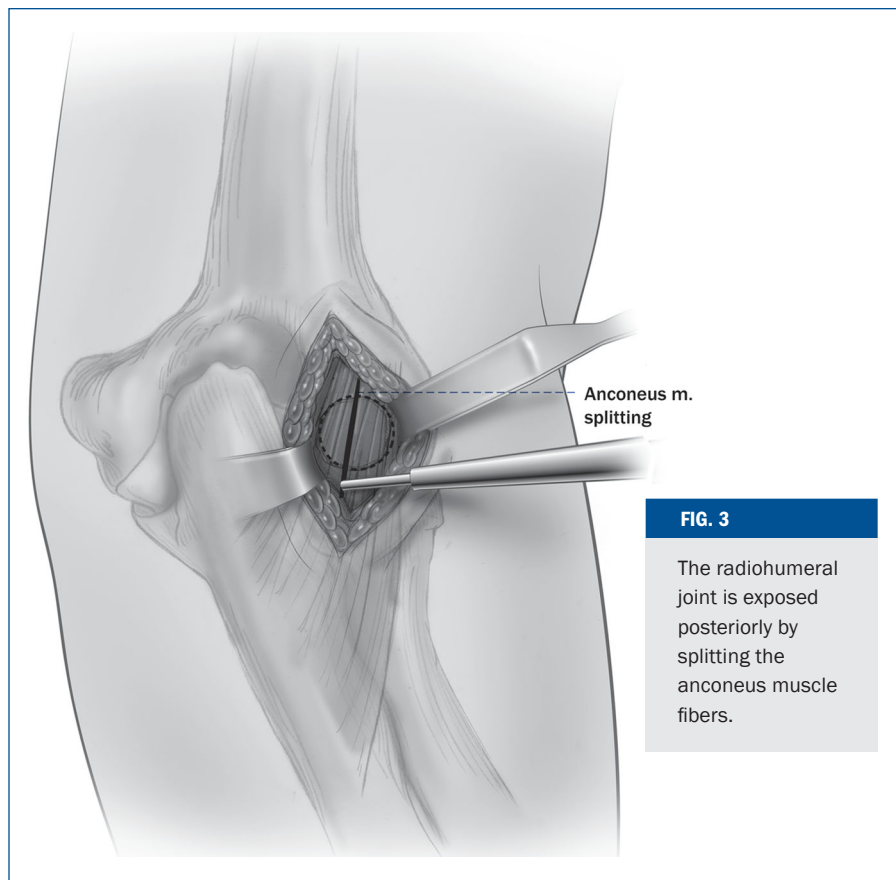
**FIG. 2**

Fig. 2 A 4 to 6-cm longitudinal posterior skin incision is made just ulnar to the proximal radioulnar joint. OCD = osteochondritis dissecans.



affected arm draped free over a bolster (Fig. 1). The ipsilateral lower extremity is prepared free from the proximal aspect of the thigh distally. Pneumatic tourniquets are placed on both the upper and lower extremities.

An Esmarch bandage is used to exsanguinate the upper extremity, and the tourniquet is inflated. A 4 to 6-cm longitudinal skin incision is made just ulnar to the posterior aspect of the proximal radioulnar joint (Fig. 2). Then, the fascia over the anconeus muscle is incised. The radiohumeral joint is exposed posteriorly by splitting the anconeus muscle fibers (Fig. 3). The capsule is incised just over the capitellar lesion from the posterior edge of the lateral epicondyle to the proximal

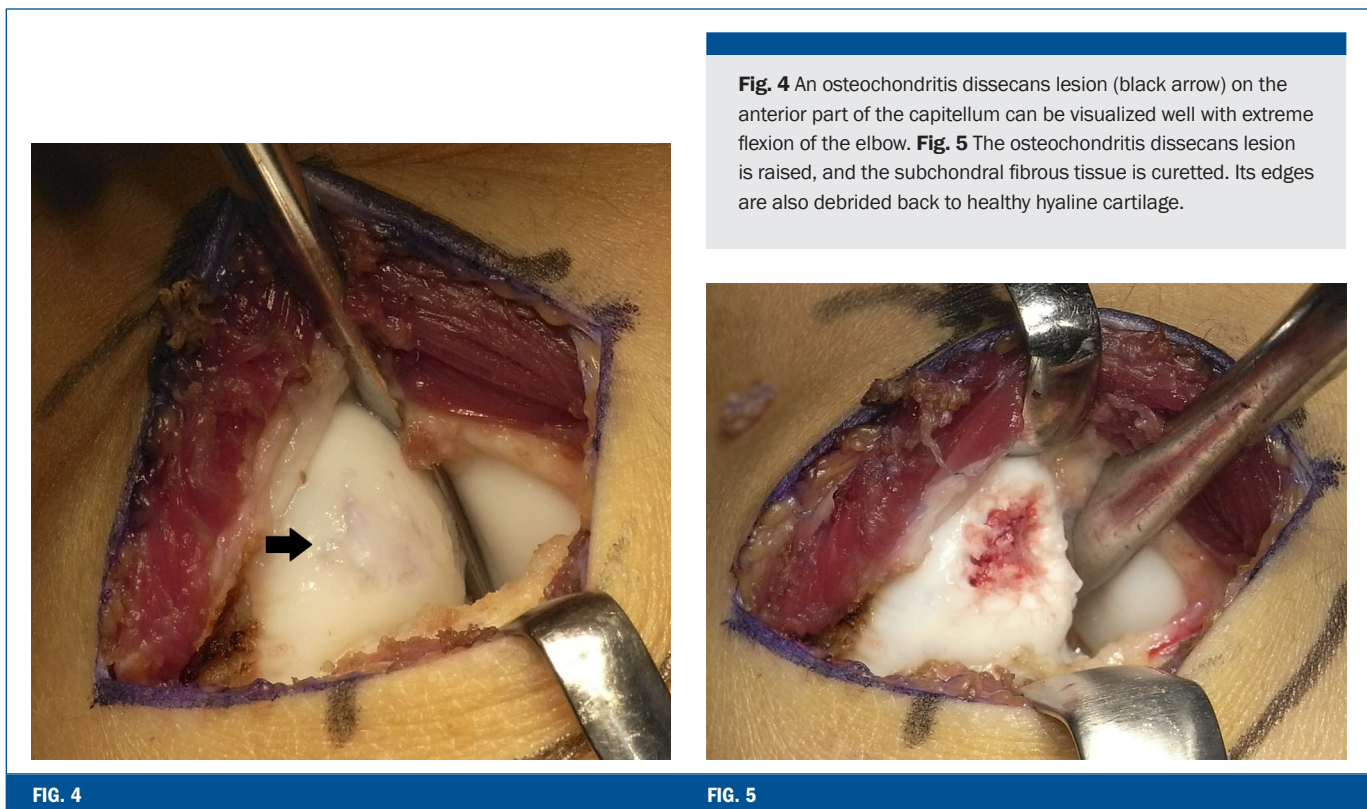


FIG. 4

FIG. 5

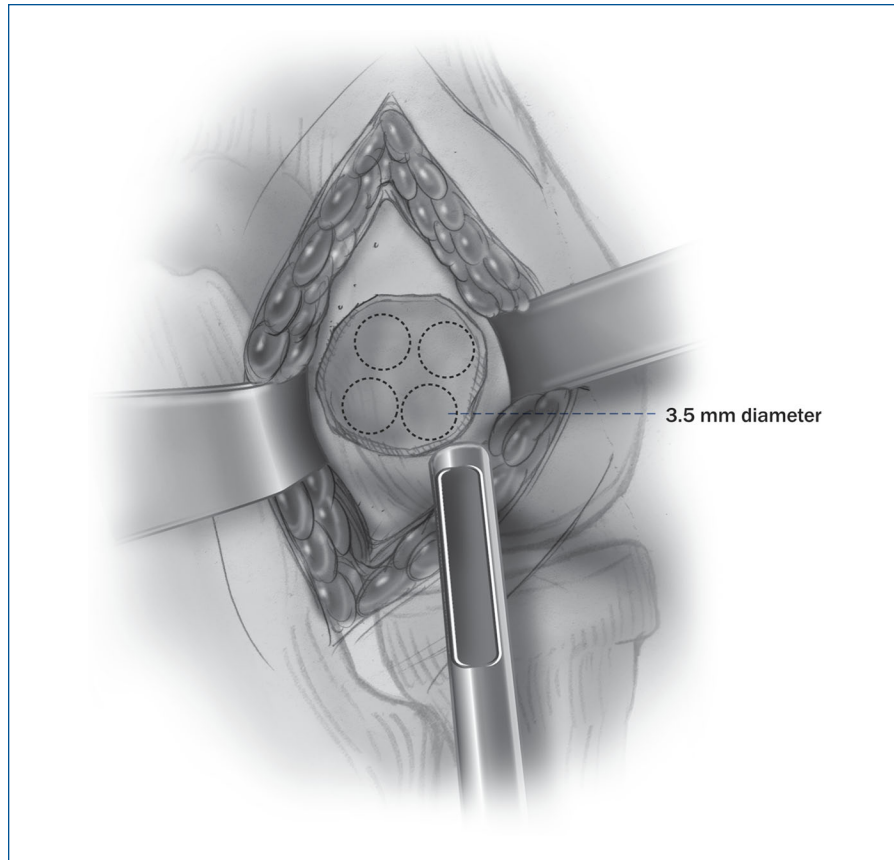


FIG. 6

3.5-mm drill guide is used to determine the number of grafts that will be needed. By tapping the drill guide down to subchondral bone, the optimal depth for filling the defect can be projected.

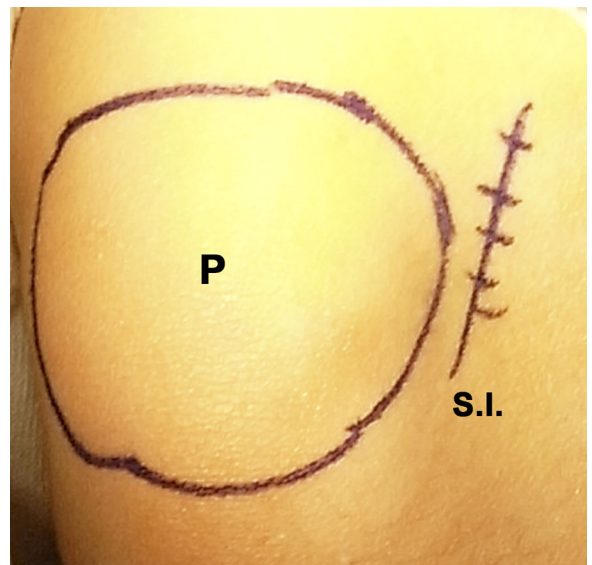
First, the osteochondritis dissecans lesion is assessed directly. The detached or dislocated fragment is raised with use of a chisel, and the subchondral fibrous tissue is curetted. Its edges are debrided back to healthy hyaline cartilage (Fig. 5). Then, a 3.5-mm drill guide is used to determine the number of grafts that will be needed. By tapping the drill guide down to viable subchondral bone, the optimal depth for filling the defect can be projected (Fig. 6). The wound is then irrigated with saline solution and packed with wet gauze.

Next, the grafts are harvested from the knee. Under tourniquet control, a 4 to 5-cm longitudinal skin incision is made just lateral to the patella (Fig. 7). The extensor retinaculum and the capsule are incised in line with the skin incision. A cuff of capsular tissue lateral to the patella is left to facilitate

edge of the annular ligament. A limited local synovectomy is performed, if necessary. Even if the osteochondritis dissecans lesion exists in the anterior part of the capitellum, it can be visualized well with extreme flexion of the elbow (Fig. 4). Through this approach, damage to the lateral collateral ligament can be avoided. In patients with severe restriction of elbow flexion, the anterior part of the osteochondritis dissecans lesion cannot be visualized with use of this approach and the Kocher lateral approach should be used.

FIG. 7

A 4 to 5-cm longitudinal skin incision is made just lateral to the patella. P = patella, and S.I. = skin incision.



With use of an appropriately sized tubular chisel (Fig. 8-A), small (3.5-mm-diameter and 10 to 15-mm-long) cylindrical osteochondral grafts (Fig. 8-B) are obtained from the lateral periphery of the condyle at the level of the patellofemoral joint (Figs. 8-C and 8-D).



FIG. 8-A

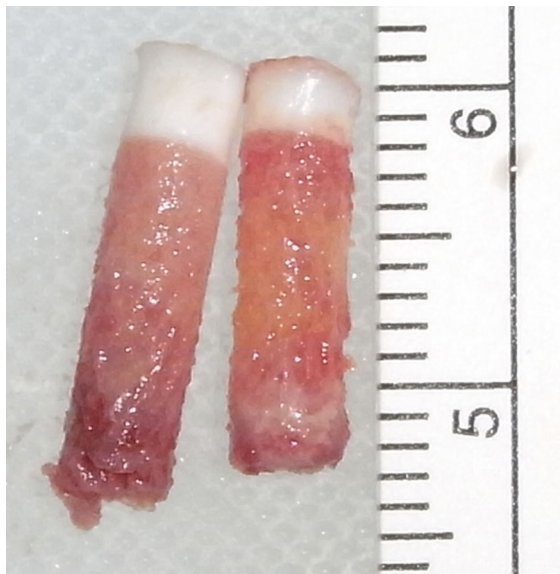


FIG. 8-B

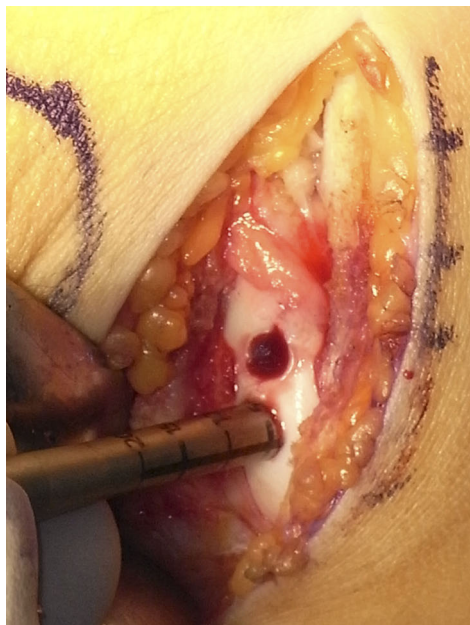

FIG. 8-C

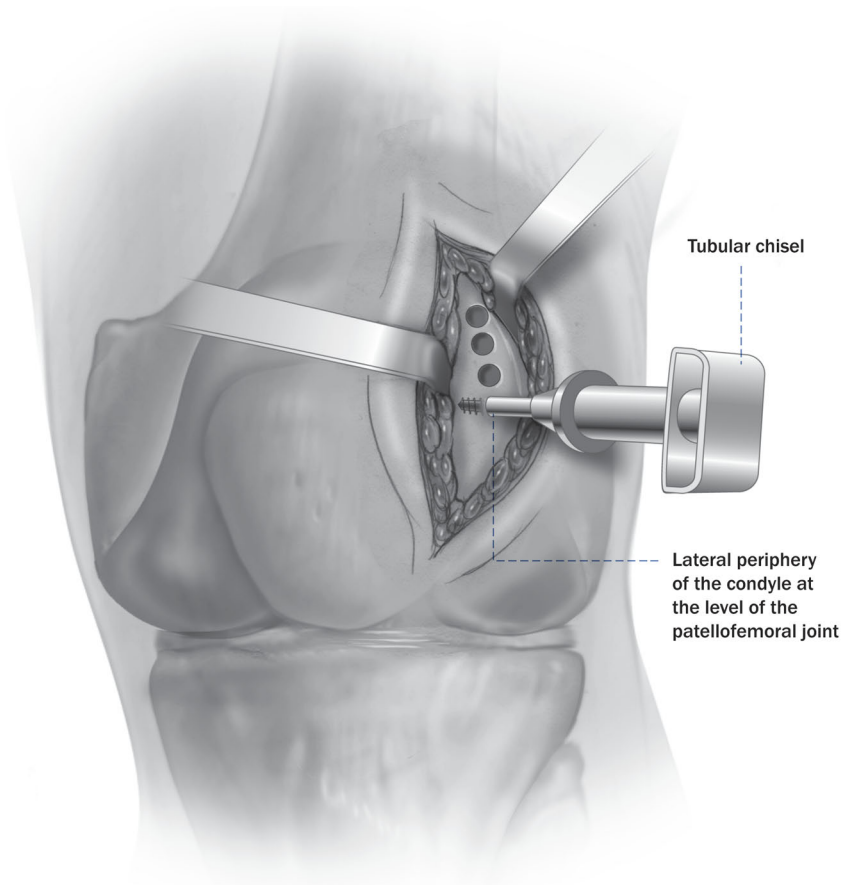


FIG. 8-D

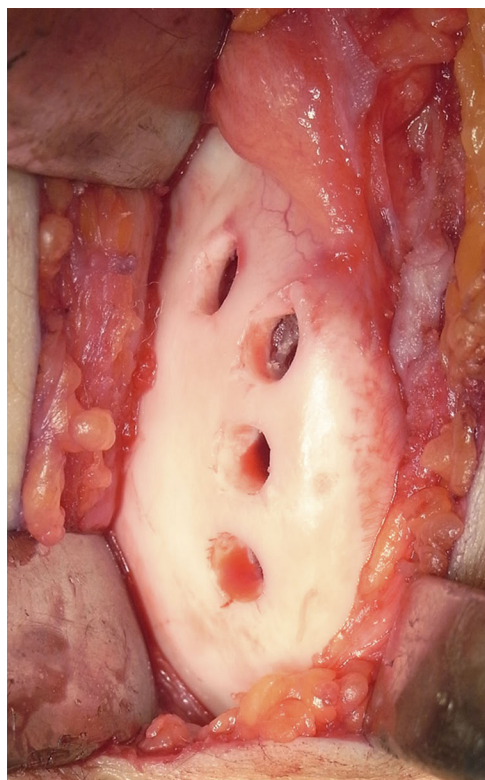

FIG. 9

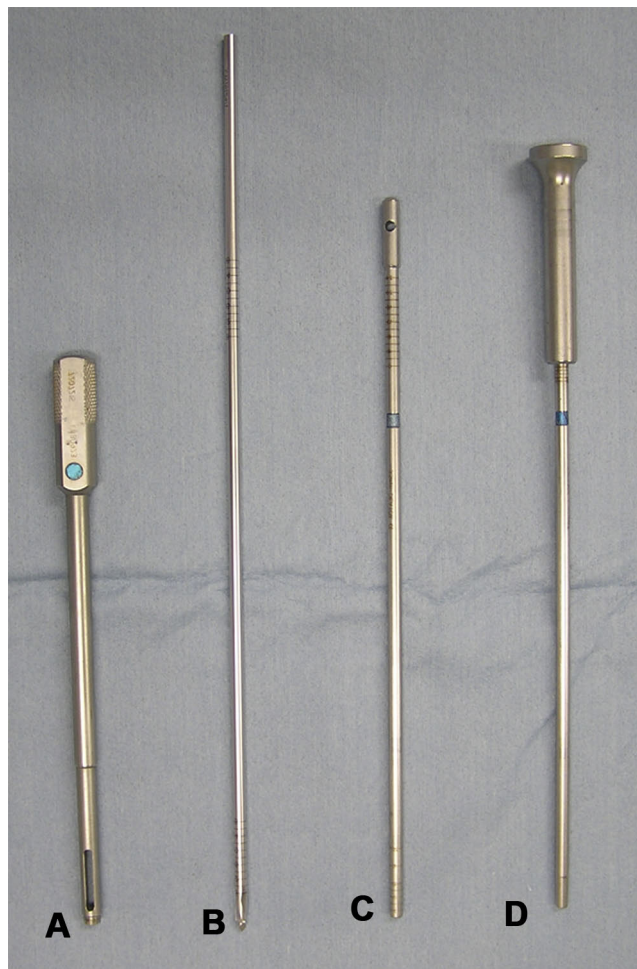

FIG. 10

Fig. 9 A distance between each harvest site of ≥ 5 mm is achieved to avoid fracture of the articular surface of the donor site. **Fig. 10** Acufex Mosaicplasty instrumentation used for graft implantation. A: drill guide; B: drill; C: dilator; and D: graft delivery tamper.

closure. By retracting the patella medially, the lateral aspect of the femoral condyle is exposed to harvest the grafts. With use of an appropriately sized tubular chisel and a special harvesting device (Acufex Mosaicplasty DP; Smith and Nephew, Andover, Massachusetts) (Fig. 8-A), small (mainly, 3.5-mm-diameter and 10 to 15-mm-long) cylindrical osteochondral grafts (Fig. 8-B) are obtained from the lateral periphery of the condyle at the

level of the patellofemoral joint (Figs. 8-C and 8-D). After tapping and then toggling without rotation, the tubular chisel is gently removed from the harvest sites. The graft is delivered from the harvester with use of a chisel guard. To prevent osteochondral fracture at the articular surface of the donor site, a distance of at least 5 mm should be maintained between each harvest site (Fig. 9). For patients with an open distal femoral physis,

shorter grafts are harvested to avoid damage to it. Each donor site is packed with bone wax to prevent postoperative bleeding.

With use of a universal guide, the harvested grafts are transplanted to the prepared osteochondral defect in the capitulum. Figure 10 shows the Acufex Mosaicplasty instrumentation for graft implantation. First, the drill guide is tapped into the osseous base of the prepared defect. With the assistance of

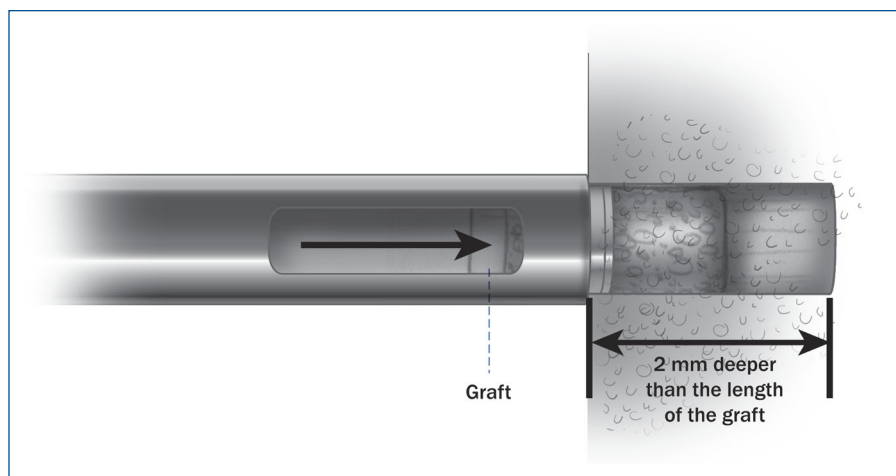


FIG. 11

With the assistance of a universal guide, a tubular tunnel is created with an appropriately sized drill-bit. The tunnel is 2.0 mm deeper than the length of the graft. Each graft is transplanted into the prepared tunnel with use of an adjustable plunger.

should protrude slightly, and centrally they should be flush with the surrounding articular surface (Fig. 11). This step-by-step sequence is repeated to insert all of the grafts (Fig. 12). The smoothness of the resurfaced area is confirmed through a range of elbow extension-flexion motion.

The tourniquets of both the upper and lower extremities are released, and hemostasis is achieved. Drains are left in both the elbow and knee joints. After irrigation of the wounds, the incised capsule of both joints is tightly sutured and the subcutaneous tissues and skin are closed in layers. The drains are removed between twenty-four and forty-eight hours after surgery.

POSTOPERATIVE CARE

Postoperatively, the patient's elbow is immobilized in 90° of flexion with the forearm in a neutral position for two weeks to promote soft-tissue healing. Regarding the knee, the patient is instructed to begin partial weight-bearing at two days and is allowed to walk freely at seven days postoperatively. Specific rehabilitation for the knee is not prescribed. The patient begins active and assisted passive motion exercises of the elbow and forearm immediately after removal of the splint. Strengthening exercises of the elbow and forearm are allowed at three months postoperatively. If patients do not have any symptoms in the elbow, we allow them to begin throwing activity at six

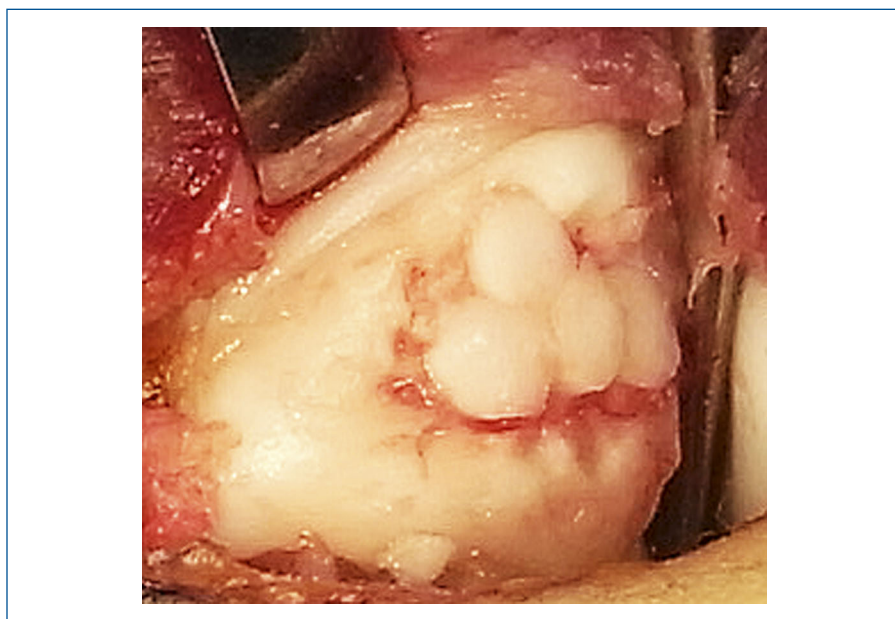


FIG. 12

The grafts have been press-fit flush into the prepared osteochondral defect.

this guide, a tubular tunnel is created with an appropriately sized drill-bit, typically 3.5 mm in diameter. The created tunnel should be 2.0 mm deeper than the length of the graft. Then, a dilator is inserted to create a

conical shaped recipient tunnel for insertion of the graft. Finally, the grafts are transplanted perpendicularly into the prepared tunnels with use of the adjustable plunger. The grafts in the periphery of the lesion

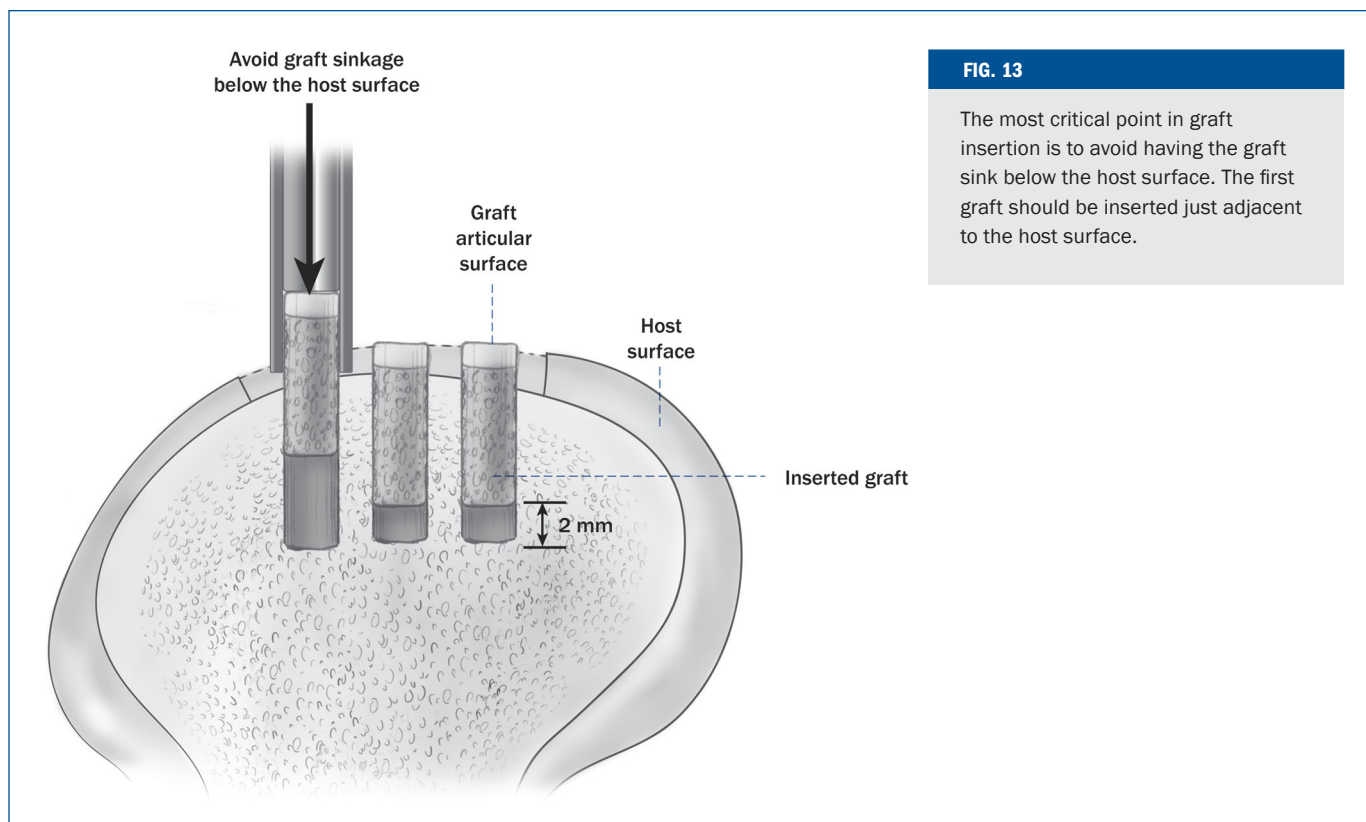


FIG. 13

The most critical point in graft insertion is to avoid having the graft sink below the host surface. The first graft should be inserted just adjacent to the host surface.

months after surgery, and they are permitted to return to their previous level of throwing activ-

ity by eight to twelve months postoperatively. Specifically, we instruct baseball players to

return to their previous level at eight months for fielders and at twelve months for pitchers.

CRITICAL CONCEPTS

INDICATIONS:

- Evidence of focal unstable lesions, including displaced and detached fragment(s), on plain radiographs and magnetic resonance imaging scans
- Failure of more than six months of conservative treatment
- A lesion of ≥ 5 mm in diameter

CONTRAINDICATIONS:

- A patient with an open growth plate of the capitellum
- A lesion of < 5 mm in diameter
- Existence of osteoarthritic changes

PITFALLS:

- The lateral (radial) wall of the defect should be preserved, except for any lateral lesions.
- Perpendicular graft harvest and implantation is crucial to reconstruct an even surface on the host area.
- The grafts should protrude slightly from the periphery of the lesion and fit flush with the surrounding articular surface centrally.

continued

CRITICAL CONCEPTS

PITFALLS (CONTINUED):

- To avoid graft sinkage below the host surface, the first graft inserted should be the one just adjacent to the host surface. Do not insert the graft into the center of the defect first (Fig. 13).
- A 3.5-mm-diameter graft is strongly recommended to prevent donor-site morbidity.
- An important technical consideration in harvesting osteochondral plugs is to prevent excessive bleeding from the donor site as it can complicate the postoperative course⁷. Therefore, adequate hemostasis should be achieved after release of the tourniquet. Additionally, we pack each donor tunnel carefully with bone wax to prevent postoperative bleeding¹⁴.
- Sequential magnetic resonance imaging indicates that graft incorporation into the surrounding tissues seems to occur in 40% of the patients by six months postoperatively¹⁵. Therefore, rehabilitation precautions should be taken for up to six months following mosaicplasty in all patients. Teenage baseball players treated with mosaicplasty are allowed to return to previous throwing activities only after at least six months.

AUTHOR UPDATE:

There have not been any important changes in surgical technique since the publication of the original article.

Norimasa Iwasaki, MD, PhD
Jyunichi Ishikawa, MD, PhD
Tatsuya Masuko, MD, PhD
Tadanao Funakoshi, MD, PhD
Akio Minami, MD, PhD

Department of Orthopaedic Surgery, Hokkaido University School of Medicine, Kita 15, Nishi 7, Sapporo 060-8638, Japan. E-mail address for N. Iwasaki: niwasaki@med.hokudai.ac.jp

Hiroyuki Kato, MD, PhD
Department of Orthopaedic Surgery, Shinshu University School of Medicine, Asahi 3-1-1, Matsumoto 390-8621, Japan

The line drawings in this article are the work of Jennifer Fairman (jfairman@fairmanstudios.com).

REFERENCES

1. Bauer M, Jonsson K, Josefsson PO, Lindén B. Osteochondritis dissecans of the elbow. A long-term follow-up study. *Clin Orthop Relat Res.* 1992;284:156-60.
2. McManama GB Jr, Micheli LJ, Berry MV, Sohn RS. The surgical treatment of osteochondritis of the capitellum. *Am J Sports Med.* 1985;13:11-21.
3. Takahara M, Ogino T, Sasaki I, Kato H, Minami A, Kaneda K. Long term outcome of osteochondritis dissecans of the humeral capitellum. *Clin Orthop Relat Res.* 1999;363:108-15.
4. Takahara M, Mura N, Sasaki J, Harada M, Ogino T. Classification, treatment, and outcome of osteochondritis dissecans of the humeral capitellum. *J Bone Joint Surg Am.* 2007;89:1205-14.
5. Tivnon MC, Anzel SH, Waugh TR. Surgical management of osteochondritis dissecans of the capitellum. *Am J Sports Med.* 1976;4:121-8.
6. Hangody L, Feczkó P, Bartha L, Bodó G, Kish G. Mosaicplasty for the treatment of articular defects of the knee and ankle. *Clin Orthop Relat Res.* 2001;391 Suppl:S328-36.
7. Hangody L, Füles P. Autologous osteochondral mosaicplasty for the treatment of full-thickness defects of weight-bearing joints: ten years of experimental and clinical experience. *J Bone Joint Surg Am.* 2003;85 Suppl 2:25-32.
8. Hangody L, Ráthonyi GK, Duska Z, Vászárhegyi G, Füles P, Módis L. Autologous osteochondral mosaicplasty. Surgical technique. *J Bone Joint Surg Am.* 2004;86 Suppl 1:65-72.
9. Ansah P, Vogt S, Ueblacker P, Martinek V, Woertler K, Imhoff AB. Osteochondral transplantation to treat osteochondral lesions in the elbow. *J Bone Joint Surg Am.* 2007;89:5188-94.
10. Iwasaki N, Kato H, Ishikawa J, Saitoh S, Minami A. Autologous osteochondral mosaicplasty for capitellar osteochondritis dissecans in teenaged patients. *Am J Sports Med.* 2006;34:1233-9.
11. Shimada K, Yoshida T, Nakata K, Hamada M, Akita S. Reconstruction with an osteochondral autograft for advanced osteochondritis dissecans of the elbow. *Clin Orthop Relat Res.* 2005;435:140-7.
12. Tsuda E, Ishibashi Y, Sato H, Yamamoto Y, Toh S. Osteochondral autograft transplantation for osteochondritis dissecans of the capitellum in nonthrowing athletes. *Arthroscopy.* 2005;21:1270.
13. Yamamoto Y, Ishibashi Y, Tsuda E, Sato H, Toh S. Osteochondral autograft transplantation for osteochondritis dissecans of the elbow in juvenile baseball players: minimum 2-year follow-up. *Am J Sports Med.* 2006;34:714-20.
14. Iwasaki N, Kato H, Kamishima T, Suenaga N, Minami A. Donor site evaluation after autologous osteochondral mosaicplasty for cartilaginous lesions of the elbow joint. *Am J Sports Med.* 2007;35:2096-100.
15. Iwasaki N, Kato H, Kamishima T, Minami A. Sequential alterations in magnetic resonance imaging findings after autologous osteochondral mosaicplasty for young athletes with osteochondritis dissecans of the humeral capitellum. *Am J Sports Med.* 2009;37:2349-54.