HOKKAIDO UNIVERSITY

Title	The Effects of a Vitamin D-deficient Diet on Chronic Cadmium Exposure in Rats
Author(s)	Uchida, Hideomi; Kurata, Yoshimasa; Hiratsuka, Hideaki et al.
Citation	Toxicologic Pathology, 38(5), 730-737 https://doi.org/10.1177/0192623310374328
Issue Date	2010-08
Doc URL	https://hdl.handle.net/2115/46872
Rights	The final, definitive version of this article has been published in the Journal, Toxicologic Pathology, 38(5), 2010 of publication, (c) Society of Toxicologic Pathology, 2010 by SAGE Publications Ltd at the Toxicologic Pathology page: http://tpx.sagepub.com/ on SAGE Journals Online: http://online.sagepub.com/
Type	journal article
File Information	TP38-5_730-737.pdf

Hokkaido University Collection of Scholarly and Academic Papers : HUSCAP

The Effects of a Vitamin D Deficient Diet on Chronic Cadmium Exposure in Rats

HIDEOMI UCHIDA, [1, 3] YOSHIMASA KURATA, [2] HIDEAKI HIRATSUKA, [2] AND TAKASHI UMEMURA [3]

[1]*Kumamoto Laboratory, Toxicological Science Division, Medi-Chem Business Segment, Mitsubishi Chemical Medience Corporation, 1285 Kurisaki, Uto, Kumamoto 869-0425, Japan*

[2]*Kashima Laboratory, Toxicological Science Division, Medi-Chem Business Segment, Mitsubishi Chemical Medience Corporation, 14 Sunayama, Kamisu, Ibaraki 314-0255, Japan*

[3]*Laboratory of Comparative Pathology, Graduate School of Veterinary Medicine, Hokkaido University, Sapporo 060-0818, Japan*

Address correspondence to: Takashi Umemura, D.V.M., Ph. D., Laboratory of Comparative Pathology, Graduate School of Veterinary Medicine, Hokkaido University, Sapporo 060-0818, Japan; e-mail: umemura@vetmed.hokudai.ac.jp; Tel.: (+81-11) 706-5191; Fax: (+81-11) 706-5194

Keywords. Cadmium toxicosis; hypovitaminosis D; itai-itai disease; osteomalacia.

Abbreviations: IID, itai-itai disease; Cd, cadmium; OX, ovariectomized; Saline + Vit. D, saline injection + normal diet; Saline - Vit. D, saline injection + vitamin D deficient diet; Cd + Vit. D, $CdCl_2$ injection + normal diet; Cd - Vit. D, $CdCl_2$ injection + vitamin D deficient diet; SD, Sprague-Dawley; $1,25(OH)_2D_3$, 1,25-dihydoroxycholecalciferol; 25(OH)D, 25- hydoroxycholecalciferol; Ca, calcium; IP, inorganic phosphorus; NAG, *N*-acetyl-*β*-D-glucosaminidase; Pyd, pyridinoline; Dpd, deoxypyridinoline; RBC, erythrocyte; Ht., hematocrit; HB conc., hemoglobin concentration; MCV, mean corpuscular volume; MCH, mean corpuscular hemoglobin; MCHC, mean corpuscular hemoglobin concentration; AST, asparate aminotransferase; ALT, alanine aminotransferase; γ-GT, gamma glutamyltranspeptidase; ALP, alkaline phosphatase; BUN, blood urea nitrogen; Fe, iron; UIBC, unsaturated iron binding capacity; TIBC, total iron-binding capacity; PTH, parathyroid hormone; BGP, bone glaprotein; HE, hematoxylin and eosin; BMD, bone mineral density.

ABSTRACT

Itai-itai disease (IID) of humans is one of the most severe forms of chronic Cadmium (Cd) intoxication occurring mainly in post-menopausal women and is characterized by osteoporosis with osteomalacia, renal tubular disorder, and renal anemia. Some researchers insist the major cause of IID is not Cd but malnutrition, especially hypovitaminosis D. We administrated a low concentration of Cd chloride intravenously to OX female rats that were fed a vitamin D deficient diet or a normal diet for 50 weeks. The vitamin D deficient diet decreased serum concentration of vitamin D, but did not affect the metabolism of the kidney or bone. Cd treatment alone induced a decrease in serum concentration of vitamin D as well as renal dysfunction, renal anemia and abnormal bone metabolism. Osteoporosis with osteomalacia, tubular nephropathy, fibrous osteodystrophy and bone marrow hyperplasia occurred following Cd treatment. In rats treated with Cd and administered a vitamin D deficient diet, the toxic effects of Cd on kidney, bone and hematopoiesis were enhanced in comparison to rats treated with the Cd and a normal diet. The present experiment demonstrated that hypovitaminosis D did not evoke morphologic features of IID in humans but did enhance the Cd-induced toxicity in the rat model of this disease.

INTRODUCTION

Cadmium (Cd) is one of the most toxic heavy metals that coexists ubiquitously with zinc, copper and lead in the environment (WHO/IPCS, 1992). Environmental and occupational exposure to this metal caused renal and bone toxicity as well as respiratory difficulty and some types of cancer (Järup et al., 1998b). For many years, Cd has been thought to affect the body at high-level exposure only in Cd-polluted areas (Kawamura et al., 1978; Kjellström, 1992). However, recent surveillance has shown that low to moderate exposure to Cd can cause renal damage or bone disease in polluted areas of many countries including Japan, Sweden, Belgium, Poland and China (Hu, 2000; Buchet et al., 1990; Nordberg et al., 1997; Cai et al., 1998; Järup et al., 1998a and 1998b; Alfven et al., 2000; Berglund et al., 2000; Ikeda et al., 2000).

IID (‘Ouch-ouch disease’ in English) of humans is one of the most severe forms of chronic Cd intoxication. The disease occurs mainly in post-menopausal women and is characterized by osteoporosis with osteomalacia, renal tubular disorder, and renal anemia (Blainey et al., 1980; Nogawa et al., 1987; Kazantzis, 2004). Some researchers insist that the major cause of IID is not Cd but malnutrition, especially hypovitaminosis D (Takeuchi, 1973). Then many researchers have tried to reproduce histopathological features characteristic of IID in various animals by chronic Cd exposure (Itokawa et al., 1974; Furuta, 1978; Kajikawa et al., 1981; Kawashima et al., 1988; Ogoshi et al., 1989; Hamada et al., 1991), but few of them were successful in reproducing osteoporosis with osteomalacia characteristic to IID. In our previous report (Hiratsuka et al., 1996), osteoporosis with osteomalacia, tubular nephropathy and renal anemia was induced in ovariectomized (OX) female rats by intravenous injections of Cd for 50 weeks without the involvement of malnutrition. In the present study, the effects of hypovitaminosis D on the rat model was examined to determine whether hypovitaminosis D could be the major cause of IID in humans or one of the enhancing factors of Cd toxicity.

MATERIALS AND METHODS

Experimental Animals and Treatment

A total of 80 female Sprague-Dawley rats (Crj: CD (SD) IGS, Charles River Japan, Kanagawa, Japan) were obtained at 6 weeks of age, and the ovaries were completely excised bilaterally under anesthesia with sodium pentobarbital (50 mg/kg ip). At ovariectomy, the body weights ranged from 164.9 to 199.1 g. Complete disappearance of the estrus cycle was confirmed by vaginal smear testing in all animals. Three weeks later, the rats were randomly assigned to four groups, and the administration began at 10 weeks of age. Group composition was as follows: 1) saline injection + normal diet (Saline + Vit. D), 2) saline injection + vitamin D deficient diet (Saline - Vit. D), 3) $CdCl_2$ injection + normal diet (Cd + Vit. D), and 4) $CdCl_2$ injection + vitamin D deficient diet (Cd - Vit. D). The saline and $CdCl_2$ injection group consisted of 18 and 20 rats, respectively, and the + Vit. D groups were given the diet (Oriental Yeast Co., Tokyo, Japan) containing 3 IU/g vitamin D (cholecalciferol) and - Vit. D groups were given the diet (Oriental Yeast Co., Tokyo, Japan) containing <0.3 IU/g vitamin D. All the animals were allowed to drink well-water admixed with NaClO (about 2 ppm) from automatic dispensers *ad libitum*. The body weights at the initiation of administration ranged from 297.0 to 360.2 g. The animals were individually housed in stainless steel wire cages (W × H × D: 260 × 200 × 380 mm) in a barrier system area. The animal rooms were thermostatically controlled at 21-27°C and maintained at a relative humidity of 35-75%, with a 12-hour light/dark cycle (lighting from 7:00 AM to 7:00 PM). The rooms were ventilated 13-15 times/hour. This study was conducted in accordance with all relevant guidelines concerning experimental animals and animal welfare set by Japanese government and the testing facility.

Experimental Design

The rats were injected into the tail vein with saline (1.0 ml/kg) or $CdCl_2$ dissolved in saline (0.5 mg/kg) 5 days a week for up to 50 weeks. The dose of Cd (as $CdCl_2$) was decided by referring to the results of previous

13- and 50-week administration experiments (Katsuta et al., 1994; Hiratsuka et al., 1996). Individual dose level was adjusted weekly based on the most recently recorded individual body weights. Prior to the necropsy at 24 and 50 weeks, all surviving rats (3-6 rats/group) were deeply anesthetized with sodium pentobarbital and exsanguinated from the posterior vena cava.

Assays for Serum Vitamin D

At necropsy, a blood sample was obtained from the posterior vena cava for hematology, blood chemistry, and assays for serum vitamin D and/or bone metabolic markers. At week 50, serum concentrations of 1,25-dihydoroxycholecalciferol ($1,25(OH)_2D_3$) and 25- hydoroxycholecalciferol (25(OH)D) were determined using commercially available ELISA kits (Immundiagnostik AG., Germany) and a microplatereader (SPECTRA FLOUR; TECAN, Austria).

Urinalysis

At 16, 24 and 50 weeks, four to six rats in each group were housed in individual metabolism cages for about 16 hours and urine was collected. Total urine volume was recorded and aliquots of urine were frozen for determination of calcium (Ca; Methylxylenol blue method, Wako Pure Chemical Industries, Ltd. Osaka, Japan), inorganic phosphorus (IP; Purine-nucleoside phosphorylase·xanthine oxidase method, Wako Pure Chemical Industries, Ltd.), *N*-acetyl-*β*-D-glucosaminidase (NAG; enzyme method, Kyowa Medics Co., Ltd., Tokyo, Japan), β_2-microglobulin (ELISA method, Panapharm Laboratories Co., Ltd., Japan), pyridinoline (Pyd; Sumitomo Seiyaku Biomedical Co., Ltd., Japan), and deoxypyridinoline (Dpd; Sumitomo Seiyaku Biomedical Co., Ltd.). β_2-microglobulin, Pyd and Dpd were assayed by a microplatereader (SPECTRA FLOUR; TECAN). Ca, IP and NAG were assayed by an auto analyzer (7170; Hitachi Ltd., Japan).

Hematology and Blood Chemistry

The parameters evaluated in the hematology were erythrocyte count (RBC; laser optical method), hematocrit (Ht; (RBC×MCV)/10^3), hemoglobin concentration (HB conc.; cyanic methemoglobin method), mean corpuscular volume (MCV; laser optical method), mean corpuscular hemoglobin (MCH; calculated from HB conc. and RBC), mean corpuscular hemoglobin concentration (MCHC; calculated from HB conc., RBC and MCV), and reticulocyte count (RNA staining laser optical method) by a hematology system (ADVIA 120; Bayer Medical Ltd., Germany). The parameters evaluated in the blood chemistry were asparate aminotransferase (AST; UV-kinetic method), alanine aminotransferase (ALT; UV-kinetic method), gamma glutamyltranspeptidase (γ-GT; L-γ-glutamyl-3-hydroxymethyl-4-nitroanilide reaction), alkaline phosphatase (ALP; p-nitrophenylphosphate reaction), blood urea nitrogen (BUN; urease-GlDH method), creatinine (Jaffé method), IP (PNP·XOD method), Ca (MXB method), iron (Fe; bathophenanthroline direct method), unsaturated iron binding capacity (UIBC; bathophenanthroline direct method), and total iron-binding capacity (TIBC; calculated from Fe and UIBC) by an auto analyzer (7170; Hitachi Ltd.).

Assays for Bone MetabolicMarkers

Serum concentrations of parathyroid hormone (PTH), calcitonin, and osteocalcin (bone glaprotein, BGP) were determined using commercially available kits (Immutopics, Inc., U.S.A), the immunoradiometric (IRMA) assay method, and a Gamma counter (COBRA Quantum 5005; PerkinElmer, Inc., U.S.A.).

Histopathology

The liver, kidneys and parathyroid glands were collected at necropsy from all surviving animals. These organs and tissues were fixed in 10% neutral-buffered formalin, embedded in paraffin wax, sectioned, and stained with hematoxylin and eosin (HE). In addition, the right femurs and thoracic vertebrae of the animals

were fixed for 2 days in 0.5% cyanuric chloride in methanol containing 1% (0.1 M) N-methylmorpholine (Yoshiki, 1973), decalcified in 10% formic acid formalin, and were processed routinely for HE staining.

Bone Mineral Density (BMD)

BMD of the left femur (proximal, middle and distal portions) was measured by dual energy X-ray absorptiometry (DCS-600; ALOKA CO., Ltd., Tokyo, Japan).

Statistical Analysis

Values obtained from rats in the Saline - Vit. D group and Cd treatment groups were compared with those from the Saline + Vit. D group. Bartlett's test was used to compare the variances among the groups. If the groups were accepted to be homogeneous, Dunnett's multiple comparison test was used for comparison of the groups. If the data of each group were heterogeneous in Bartlett's test, Steel's multiple comparison test was used. The Wilcoxon test was used for the comparison of semi quantitated histopathological findings.

RESULTS

Body Weight

Body weight gain depressed in the Cd-treated groups from 5 to 50 weeks consistently, and the body weight of the Cd-treated rats was significantly low from 13 weeks (Fig. 1). There were no clear effects of Vitamin D deficiency on the body weight change throughout the administration period.

Concentration of SerumVvitamin D

In the Saline - Vit. D group, serum levels of $1,25(OH)_2D_3$ and 25(OH)D were significantly decreased, and a decrease of 25(OH)D was more remarkable (Table 1). In contrast, Cd treatment alone induced the decreases of $1,25(OH)_2D_3$ to the same extent. The decrease of the Vitamin D in the Cd - Vit. D group was the sum of the effects of Cd treatment and vitamin D deficiency, and the serum concentration of $1,25(OH)_2D_3$ was higher than that of 25(OH)D.

Urinalysis

β_2-microglobulin significantly increased in the Cd-treated groups from 16 to 50 weeks. Although an elevation of NAG was observed from 16 weeks in the groups, the change disappeared at week 50. Urinary excretion of Ca in Cd-treated rats tended to decrease or significantly decreased at weeks 16 and 24, respectively, and then changed to an increase at week 50. Excretions of the bone metabolic markers, such as Pyd and Dpd, slightly increased at week 16 in the Cd-treated groups, and the excretion of Pyd continuously increased at weeks 24 and 50. The Saline - Vit. D group showed no urinary changes throughout the administration period.

Hematology

The Cd-treated groups revealed significant decreases in HB conc., Ht, MCV, MCH and MCHC, and an increase in reticulocyte count (Table 2). At week 50, these changes became more prominent, except for MCV, MCH and MCHC. The degree of the anemia at week 50 was most severe in the Cd - Vit. D group than in the Cd + Vit. D group. None of these changes appeared in the Saline - Vit. D group during the administration period.

Blood Chemistry

Serum concentrations of BUN, creatinine and IP were significantly higher in the Cd-treated groups at week 24 and 50. There were significant increases or a tendency to increase in serum AST, γ-GT and ALP activities in

the Cd-treated groups at weeks 24 and 50. In addition, Cd-treatment resulted in significant increases of UIBC and TIBC concentrations which were accompanied by a decrease in the Fe concentration at weeks 24 and 50. There were no clear influences of vitamin D deficiency in these parameters.

Bone Metabolic Markers

No treatment-related changes were observed in the Saline - Vit. D group. As for the Cd-treated groups, serum levels of PTH and BGP were significantly high.

Gross Findings

A total of 9 and 11 out of 20 rats died in the Cd + Vit. D and Cd - Vit. D groups, respectively, between the weeks 40 to 50. The livers and kidneys of the deceased animals were slightly atrophic and indented on their surfaces. There was no clear effect of vitamin D deficiency on the liver or kidney. The animals that survived Cd treatment also exhibited similar hepatic and renal changes, but to a milder degree, to the rats that died of Cd treatment at week 24, and these changes became severer at week 50.

Histopathology

The hepatocytes of Cd-treated rats showed an increase in individual cell necrosis and/or focal necrosis, enlargement of the cytoplasm and nuclei with prominent nucleoi, irrespective of dietary vitamin D concentrations (Table 3). Mitosis and binucleated hepatocytes were also occasionally seen in the livers of Cd-treated rats at week 50. Cd-treated rats showed tubular nephropathy with interstitial fibrosis at weeks 24 and 50 (Figs. 2a and b). The renal change was more severe at week 50 than at week 24 (Table 3).

At week 24, 9 of 12 femurs in Cd-treated groups showed mild fibrous osteodystrophy. Bone marrow hyperplasia was observed in the femur of one rat from the Cd - Vit. D group. At week 50, the femurs and

thoracic vertebrae in Cd-treated groups showed prominent fibrous osteodystrophy, osteoporosis with osteomalacia, and bone marrow hyperplasia (Figs. 3a and b). The extent of the former two osseous changes was more severe in the Cd- Vit. D group than in the Cd + Vit. D group, and more prominent in the femur than in the vertebrae (Table 3). Cortical and cancellous bones were remarkably porotic or atrophic with the formation of osteoid seams at the inner surface of Haversian canals and endosteum. Fibrotic tissues proliferated within the pores, at the inner surface of the endosteum (Fig. 4), and around the bone spicules of the trabecular bone at metaphysis. Microfractures of cancellous bone accompanying collagenous callus were sometimes observed at epiphysis of the femur in the Cd - Vit. D group. Bone marrow hyperplasia was prominent in all three rats of the Cd - Vit. D group and in two of the five rats in the Cd + Vit. D group. The femurs and thoracic vertebrae of non-Cd-treated groups were unremarkable at weeks 24 and 50.

The parathyroid glands of all the rats necropsied at week 24 were unremarkable. In contrast, the glands of the Cd-treated rats were slightly or moderately enlarged in comparison with those of the non-Cd treated rats at week 50. In the enlarged glands, each lobule was enlarged due to hypertrophy and hyperplasia of the chief cells with pale and granular cytoplasm. Mitotic figures of chief cells were occasionally observed in the enlarged parathyroid glands.

Bone Mineral Density (BMD)

At week 24, the BMDs of all treatment groups were not significantly different from Saline + Vit. D group. At week 50, the BMDs of the femur were significantly or insignificantly low in the Cd-treated groups (Fig. 5). The osteoporosis at middle and distal portions of the femur was slightly more severe in the Cd - Vit. D group than in the Cd + Vit. D group.

DISCUSSION

By repeated intravenous injection of Cd to OX female rats over 50 weeks, osteoporosis with osteomalacia, renal tubular nephropathy and renal anemia, which were the main pathological changes of IID, could be reproduced in the present study. These results confirm our previous reports in which the characteristic pathologies of human IID, were reproduced by Cd treatment for 13 weeks (Katsuta et al., 1994) and 50 to 70 weeks (Hiratsuka et al., 1996) in OX rats. In the present study, fibrous oteodystrophy was also observed in the Cd-treated rats. Fibrous osteodystrophy is one of the osseous changes distinctive to hyperparathyroidism (Rude, 1996; Lotinun et al., 2006) and may occur secondary to renal dysfunction (Jablonski et al., 1993; Amann et al., 1994).

The rats fed a vitamin D deficient diet showed a significant decrease of active and inactive forms of serum vitamin D [1,25$(OH)_2D_3$ and 25(OH)D]. Vitamin D is an important hormone regulating homeostasis of Ca and P, and severe vitamin D deficiency is known to increase the risk of rickets (Hirota et al., 2006; Lips, 2006). However, in the present study, the rats given a diet deficient in vitamin D did not show biochemical abnormality in blood or urine suggesting metabolic disorders of the bone and kidneys. Vitamin D is produced in the skin through ultraviolet irradiation or obtained from food. The inactive form of vitamin D undergoes its first step of activation, namely 25-hydroxylation in the liver followed by 1α-hydroxylation in the kidneys, to make the biologically active compound 1,25$(OH)_2D_3$. The active metabolite has many functions related to Ca regulation and bone metabolism, including intestinal Ca and P absorption, Ca mobilization in the bone, and resorption of P and Ca in the renal tubular cells (Jones et al., 1998; Deluca, 2004; Lips, 2006). Although vitamin D interacts with PTH (Jones et al., 1998; Deluca., 2004), hypovitaminosis D does not influence PTH under sufficient serum levels of Ca (Kollenkirchen et al., 1991; Dabbagh et al., 1989), and many researchers (Fox, 1992; Lee et al., 1991; Masuyama et al., 2003) have reported a vitamin D-independent Ca homeostasis system. Therefore,

hypovitaminosis D alone might not affect Ca homeostasis and bone remodeling due to the vitamin D-independent system in the present experiment.

The mechanisms of Cd-induced osteoporosis with osteomalacia, which is the main pathological finding of IID, are not fully understood. The inactive form of vitamin D is activated at the proximal tubules of the kidneys, and dysfunction of the tubules occurs in the early phase of chronic Cd toxicosis (Kjellström, 1992; Kazantzis, 2004) and IID (Shigematsu, 1984; Takebayashi et al., 2000). Thus, the disorder of vitamin D hydroxylation in the kidneys is regarded as one of the important mechanisms of bone pathology in IID patients (Aoshima and Kasuya, 1991; Tsuritani et al., 1992; Kido, 1995). The rats treated with Cd showed a decreased serum $1,25(OH)_2D_3$ concentration due to renal tubular nephropathy which was accompanied by a remarkable elevation of serum PTH; thus the indirect action of Cd on bone via renal damage was demonstrated in the present experiment. Histological and roentgenological examinations of the bone showed that the fibrous osteodystrophy, osteoporosis with osteomalacia, and reduction of BMD detected in the femur were more severe in Cd - Vit. D rats than in Cd + Vit. D rats. These results suggested that dietary hypovitaminosis D enhanced Cd toxicity on the bone. Similar findings were reported by Kobayashi et al. (1979), in which osteomalacic changes were prominent in the rats subjected to long-term feeding of the diet containing Cd and low concentrations of Ca and vitamin D.

Severe anemia appeared in the Cd treatment groups after 24 and 50 weeks in the present experiment. The anemia at week 24 accompanied decreases of MCV and MCH, whereas the anemia at week 50 was normocytic and normochromic. These differences indicate the shift from iron-deficiency anemia at week 24 to renal anemia at week 50 due to the advance of renal tubular destruction resulting in a poor erythropoietin response by Cd treatment (Hiratsuka et al., 1996). A diet deficient in protein, calcium, phosphorus and fiber enhances Cd accumulation in the kidney in rats under Cd toxication (Muto and Omori, 1977), and malnutrition plays an important role in the early development of Cd toxicosis, in particular for the development of renal damage. The present experiment demonstrated the aggravation of Cd-induced renal dysfunctions and renal anemia following

feeding of a vitamin D deficient diet. In conclusion, malnutrition (based on a vitamin D deficient diet) alone does not evoke histopathological features of IID in the rodent model but enhances the Cd-related toxicity characterized by osteoporosis with osteomalacia, renal tubular nephropathy and renal anemia.

ACKNOWLEDGEMENTS

The present study was supported in part by the Japanese Environmental Agency. The authors wish to thank Mr. Masahiro Nasu and Ms. Miwako Ishii for their excellent technical assistance.

REFERENCES

Alfvén, T., Elinder, C. G., Carlsson, M. D., Grubb, A., Hellström, L., Persson, B., Pettersson, C., Spang, G., Schütz, A., and Järup, L. (2000). Low-level cadmium exposure and osteoporosis. *J Bone Miner Res* **15**, 1579-1586.

Amann, K., Ritz, E., Wiest, G., Klaus, G., and Mall, G. (1994). A role of parathyroid hormone for the activation of cardiac fibroblasts in uremia. *J Am Soc Nephrol* **4**, 1814-1819.

Aoshima, K., Kasuya, M. (1991). Preliminary study on serum levels of 1,25-dihydroxyvitamin D and 25-hydroxyvitamin D in cadmium-induced renal tubular dysfunction. *Toxicol Lett* **57**, 91-99.

Berglund, M., Åkesson, A., Bjellerup, P., and Vahler, M. (2000). Metal-bone interactions. *Toxicol Lett* **15**, 112-113: 219-225.

Blainey, J. D., Adams, R. G., Brewer, D. B., and Harvey, T. C. (1980). Cadmium-induced osteomalacia. *Br J Ind Med* **37**, 278-284.

Buchet, J. P., Lauwerys, R., Roels, H., Bernard, A., Bruaux, P., Claeys, F., Ducoffre, G., de Plaen, P., Staessen, J., and Amery, A. (1990). Renal effects of cadmium body burden of the general population. *Lancet* **336**, 699-702.

Cai, S., Yue, L., Jin, T., and Nordberg, G. (1998). Renal dysfunction from cadmium contamination of irrigation water: dose-response analysis in a Chinese population. *Bull World Health Organ* **76**, 153-159.

Dabbagh, S., Epley, M., Diven, W., Chen, T., Virji, M., and Ellis, D. (1989). Effect of vitamin D deficiency on amino acid excretion in the phosphate-depleted rat. *Miner Electrolyte Metab* **15**, 283-290.

DeLuca, H. F. (2004). Overview of general physiologic features and functions of vitamin D. *Am J Clin Nutr* **80**, 1689S-1696S.

Fox, J. (1992). Hypocalcemia, but not PTH or hypophosphatemia, induces a rapid increase in $1,25(OH)_2D_3$ levels in rats. *Am J Physiol* **262**, 211-215.

Furuta, H. (1978). Cadmium effects on bone and dental tissues of rats in acute and subacute poisoning. *Experientia* **34**, 1317-1318.

Hamada, T., Nakano, S., Iwai, S., Tanimoto, A., Ariyoshi, K., and Koide, O. (1991). Pathological study on beagles after long-term oral administration of cadmium. *Toxicol Pathol* **19**, 138-147.

Hiratsuka, H., Katsuta, O., Toyota, N., Tsuchitani, M., Umemura, T., and Marumo, F. (1996). Chronic cadmium exposure-induced renal anemia in ovariectomized rats. *Toxicol Appl Pharmacol* **137**, 228-236.

Hirota, K., and Hirota, T. (2006). Nutrition-related bone disease [in Japanese]. *Nippon Rinsho* **64**, 1707-1711.

Hu, H. (2000). Exposure to metals. *Prim Care* **27**, 983-996.

Ikeda, M., Zhang, Z. W., Moon, C. S., Shimbo, S., Watanabe, T., Nakatsuka, H., Matsuda-Inoguchi, N., and Higashikawa, K. (2000). Possible effects of environmental cadmium exposure on kidney function in the Japanese general population. *Int Arch Occup Environ Health* **73**, 15-25.

Itokawa, Y., Abe, T., Tabei, R., and Tanaka, S. (1974). Renal and skeletal lesions in experimental cadmium poisoning: histological and biochemical approaches. *Arch Environ Health* **28**, 149-154.

Jablonski, G., Klem, K. H., Attramadal, A., Dahl, E., Ronningen, H., Gautvik, K. M., Haug, E., and Gordeladze, J. O. (1993). Surgically induced uremia in rats. I: effect on bone strength and metabolism. *Biosci Rep* **13**, 275-287.

Järup, L., Alfvén, T., Persson, B., Toss, G., and Elinder, C. G. (1998a). Cadmium may be a risk factor for osteoporosis. *Occup Environ Med* **55**, 435-439.

Järup, L., Berglund, M., Elinder, C. G., Nordberg, G., and Vahter, M. (1998b). Health effects of cadmium exposure – a review of the literature and a risk estimate. *Scand J Work Environ Health* **24**, 1-51.

Jones, G., Strugnell, S. A., and Deluca, H. F. (1998). Current understanding of the molecular actions of vitamin D. *Physiol Rev* **78**, 1193-1231.

Kajikawa, K., Nakanishi, I., and Kuroda, K. (1981). Morphological changes of the kidney and bone of rats in chronic cadmium poisoning. *Exp Mol Patho* **34**, 9-24.

Katsuta, O., Hiratsuka, H., Matsumoto, J., Iwata, H., Toyota, N., Tsuchitani, M., Umemura, T., and Marumo, F. (1994). Cadmium-induced osteomalacic and oeteopetrotic lesions in ovariectomized rats. *Toxicol Appl Pharmacol* **126**, 58-68.

Kawamura, J., Yoshida, O., Nishino, K., and Itokawa, I. (1978). Disturbances in kidney functions and calcium and phosphate metabolism in cadmium-poisoned rats. *Nephron* **20**, 101-110.

Kawashima, H., Nomiyama, H., and Nomiyama, K. (1988). Chronic exposure to cadmium did not impair vitamin D metabolism in monkeys. *Environ Res* **46**, 48-58.

Kazantzis, G. (2004). Cadmium, osteoporosis and calcium metabolism. *Biometals* **17**, 493-498.

Kido, T. (1995). Studies on health effects of cadmium exposure in the general environment [in Japanese]. *Nippon Eiseigaku Zasshi* **49**, 960-72.

Kjellström, T. (1992). Mechanism and epidemiology of bone effects of cadmium. In Cadmium in the Human Environment: Toxicity and Carcinogenicity (G. F. Nordberg, R. F. M. Herber, and L. Alessio, eds.), pp. 301-310. IARC Scientific Publications, Lyon, France.

Kobayashi, E., Nogawa, K., and Ishizaki, A. (1979). Comparison of bone lesions in chronic cadmium poisoning and vitamin D-deficiency [in Japanese]. *Kankyo Hoken Rep* **45**, 131-137.

Kollenkirchen, U., Walters, M. R., and Fox, J. (1991). Plasma Ca influences vitamin D metabolite levels as rats develop vitamin D deficiency. *Am J Physiol* **260**, 447-452.

Lee, D. B., Hu, M. S., Kayne, L. H., Nakhoul, F., and Jamgotchian, N. (1991). The importance of non-vitamin D-mediated calcium absorption. *Contrib Nephrol* **91**, 14-20.

Lotinum, S., Sibonga, J. D., and Turner, R. T. (2006). Evidence that the cells responsible for marrow fibrosis in a rat model for hyperparathyroidism are preosteoblasts. *Endocrinology* **146**, 4074-4081.

Lips, P. (2006). Vitamin D physiology. *Prog Biophys Mol Biol* **92**, 4-8.

Masuyama, R., Nakaya, Y., Katsumata, S., Kajita, Y., Uehara, M., Tanaka, S., Sakai, A., Kato, S., Nakamura, T., and Suzuki, K. (2003). Dietary calcium and phosphorus ratio regulates bone mineralization and turnover in vitamin D receptor knockout mice by affecting intestinal calcium and phosphorus absorption. *J Bone Miner Res* **18**, 1217-1226.

Muto, Y. and Omori, M. (1977). Nutritional influence on the onset of renal damage due to long-term administration of cadmium in young adult rats. *J Nutr Sci Vitaminol* **23**, 349-360.

Nogawa, K., Tsuritani, I., Kido, T., Honda, R., Yamada, Y., and Ishizaki, M. (1987). Mechanism for bone disease found in inhabitants environmentally exposed to cadmium: decreased serum 1 α, 25-dihydroxyvitamin D level. *Int Arch Occup Environ Health* **59**, 21-30.

Nordberg, G. F., Jin, T., Kong, Q., Ye, T., Cai, S., Wang, Z., Zhuang, F., and Wu, X. (1997). Biological monitoring of cadmium exposure and renal effects in a population group residing in a polluted area in China. *Sci Total Environ* **199**, 111-114.

Ogoshi, K., Moriyama, T., and Nanzai, Y. (1989). Decrease in the mechanical strength of bones of rats administered cadmium. *Arch Toxicol* **63**, 320-324.

Rude, R. K. (1996). Hyperparathyroidism. *Otolaryngol Clin North Am* **29**, 663-679.

Shigematsu, I. (1984). The epidemiological approach to cadmium pollution in Japan. *Ann Acad Med Singapore* **13**, 231-236.

Takebayashi, S., Jimi, S., Segawa, M., and Kiyoshi, Y. (2000). Cadmium induces osteomalacia mediated by proximal tubular atrophy and disturbances of phosphate reabsorption. A study of 11 autopsies. *Pathol Res Pract* **196**, 653-663.

Takeuchi, J. (1973). Etiology of Itai-itai disease: criticism on the theory of cadmium source [in Japanese].

Nippon Rinsho **31**, 2048-2057.

Tsuritani, I., Honda, R., Ishizaki, M., Yamada, Y., Kido, T., and Nogawa, K. (1992). Impairment of vitamin D metabolism due to environmental cadmium exposure, and possible relevance to sex-related differences in vulnerability to the bone damage. *J Toxicol Environ Health* **37**, 519-33.

WHO/IPCS (1992). Environmental health criteria 134, Cadmium. World Health Organization, Geneva.

Yoshiki, S. (1973). A simple histological method for identification of osteoid matrix in decalcified bone. *Stain Technol* **48**, 223-238.

FIGURE 1.—Body weight changes of the rats treated with cadmium and/or vitamin D deficiency. Each point represents the mean ± SD (n = 12 at weeks 1 to 23, n = 3, 5 or 6 at weeks 25 to 50). Asterisk (*) indicates significant difference from the saline + Vit. D group (p<0.01).

FIGURE 2.—The kidney of the rats in Saline - Vit. D group (A) and Cd - Vit. D group (B) at 50 weeks of treatment. Interstitial fibrous tissues accompanying inflammatory cell infiltration fill the gaps among small diameter tubules (b) and the epithelial cells of the tubules are regenerative (B). H.E. stain. ×200 (A, B).

FIGURE 3.—Diaphysis of the femurs of the rats in Saline - Vit. D group (A) and Cd - Vit. D group (B) at 50 weeks of treatment. Bone marrow hyperplasia, osteoporosis and fibrous osteitis (b). H.E. stain. ×40 (a, b).

FIGURE 4.—Diaphysis of the femur of the rat in Cd - Vit. D group at 50 weeks of treatment. Fibrous osteitis of cortical bone. H.E. stain. ×100.

FIGURE 5.—Bone mineral density of the rats treated with cadmium and/or vitamin D deficiency. Asterisk (*) indicates significant difference from the saline + Vit. D group ($p<0.01$). Site A: 1/4 part from proximal metaphysis of the femur. Site B: Diaphysis (central part of the femur). Site C: 1/4 part from distal metaphysis of the femur.

TABLE 1.—Serum vitamin D concentrations of the rats treated with cadmium and/or vitamin D deficiency for 50 weeks.

Group		$1,25(OH)_2D_3$ (pg/mL)	25(OH)D (ng/mL)
Saline+Vit. D	*n*	6	6
	Mean[a]	68.5	37.5
	SD	23.5	13.8
Saline-Vit. D	*n*	6	6
	Mean	34.1 **	2.7 **
	SD	12.1	1.1
Cd+Vit. D	*n*	5	5
	Mean	41.9 *	18.1 *
	SD	19.4	8.5
Cd-Vit. D	*n*	3	3
	Mean	8.5 **	0 **
	SD	2.4	0

*: Significantly different from saline +Vit. D value, $p < 0.05$.

**: Significantly different from saline +Vit. D value, $p < 0.01$.

TABLE 2.—Hematology data of the rats treated with cadmium and/or vitamin D deficiency for 24 and 50 weeks.

Week	Group		Erythrocytes ($10^4/\mu L$)	Hemoglobin (g/dL)	Hematocrit (%)	MCV (fL)	MCH (pg)	MCHC (g/dL)	Reticulocyte (%)
24	Saline+Vit. D	*n*	6	6	6	6	6	6	6
		Mean	806	15.2	43.9	54.6	18.9	34.6	2.1
		SD	29	0.6	1.2	1.7	0.6	0.4	0.5
	Saline-Vit. D	*n*	6	6	6	6	6	6	6
		Mean	823	15.5	44.2	53.8	18.9	35.1	1.8
		SD	57	0.8	2.6	1.4	0.7	0.5	0.3
	Cd+Vit. D	*n*	6	6	6	6	6	6	6
		Mean	739	10.2 *	31.8 *	43.1 **	13.9 **	32.1 *	4.1 *
		SD	55	0.5	1.6	3.5	1.3	0.6	0.8
	Cd-Vit. D	*n*	6	6	6	6	6	6	6
		Mean	650 **	8.9 *	27.4 *	41.9 **	13.6 **	32.3 *	4.1 *
		SD	107	2.0	5.5	2.2	1.3	1.9	1.6
50	Saline+Vit. D	*n*	6	6	6	6	6	6	6
		Mean	797	15.0	43.9	55.2	18.9	34.2	2.4
		SD	47	0.4	1.3	2.7	0.9	0.5	0.6
	Saline-Vit. D	*n*	6	6	6	6	6	6	6
		Mean	797	14.4	42.3	53.0	17.9	33.8	2.5
		SD	79	2.2	5.5	4.7	2.1	1.4	1.2
	Cd+Vit. D	*n*	5	5	5	5	5	5	5
		Mean	417 **	6.8 **	20.6 **	49.7 *	16.4 **	32.9	3.9
		SD	120	1.8	5.3	2.7	1.2	1.2	1.6
	Cd-Vit. D	*n*	3	3	3	3	3	3	3
		Mean	216 **	3.9 *	12.5 *	58.2	18.1	31.2	11.8 *
		SD	40	0.7	1.2	4.9	0.2	2.4	6.4

*: Significantly different from saline +Vit. D value, $p < 0.05$.

**: Significantly different from saline +Vit. D value, $p < 0.01$.

TABLE 3.—Histopathologic findings of the rats treated with cadmium and/or vitamin D deficiency for 24 and 50 weeks.

Week 24

Organ	Group	Saline+Vit. D				Saline-Vit. D				Cd+Vit. D					Cd-Vit. D				
Findigs	Grade	-	+	++	+++	-	+	++	+++	-	+	++	+++		-	+	++	+++	
Liver																			
Solitary necrosis		5				6					5	1		**		6			**
Enlargement of hepatocytes		5				6				1	5			**		6			**
Kidney																			
Tubular nephropathy		5				6						6		**			5	1	**
Parathyroid gland																			
Enlargement		5				6				6					6				
Femur																			
Fibrous osteitis		5				6				2	4			*	1	5			**
Bone marrow hyperplasia		5				6				6					5	1			

Grade: -, no lesion; +, slight; ++, moderate; +++, severe.

Week 50

Organ	Group	Saline+Vit. D				Saline-Vit. D				Cd+Vit. D					Cd-Vit. D				
Findigs	Grade	-	+	++	+++	-	+	++	+++	-	+	++	+++		-	+	++	+++	
Liver																			
Solitary necrosis		6				6					5			**		3			**
Enlargement of hepatocytes		6				6					5			**		3			**
Kidney																			
Tubular nephropathy		6				6						2	3	**				3	**
Parathyroid gland																			
Enlargement		6				6					2	3		**			3		**
Femur																			
Osteoporosis with osteomalacia		6				6					2	1	2	**				3	**
Fibrous osteitis		6				6				2	1		2	**				3	**
Bone marrow hyperplasia		6				6				3		2				1	2		*
Thoracic vertebrae																			
Osteoporosis with osteomalacia		6				6					3	2		**			3		
Fibrous osteitis		6				6				3		2					3		**
Bone marrow hyperplasia		6				6				3		2					3		**

Grade: -, no lesion; +, slight; ++, moderate; +++, severe.

*: Significantly different from saline +Vit. D value, $p < 0.05$.

**: Significantly different from saline +Vit. D value, $p < 0.01$.

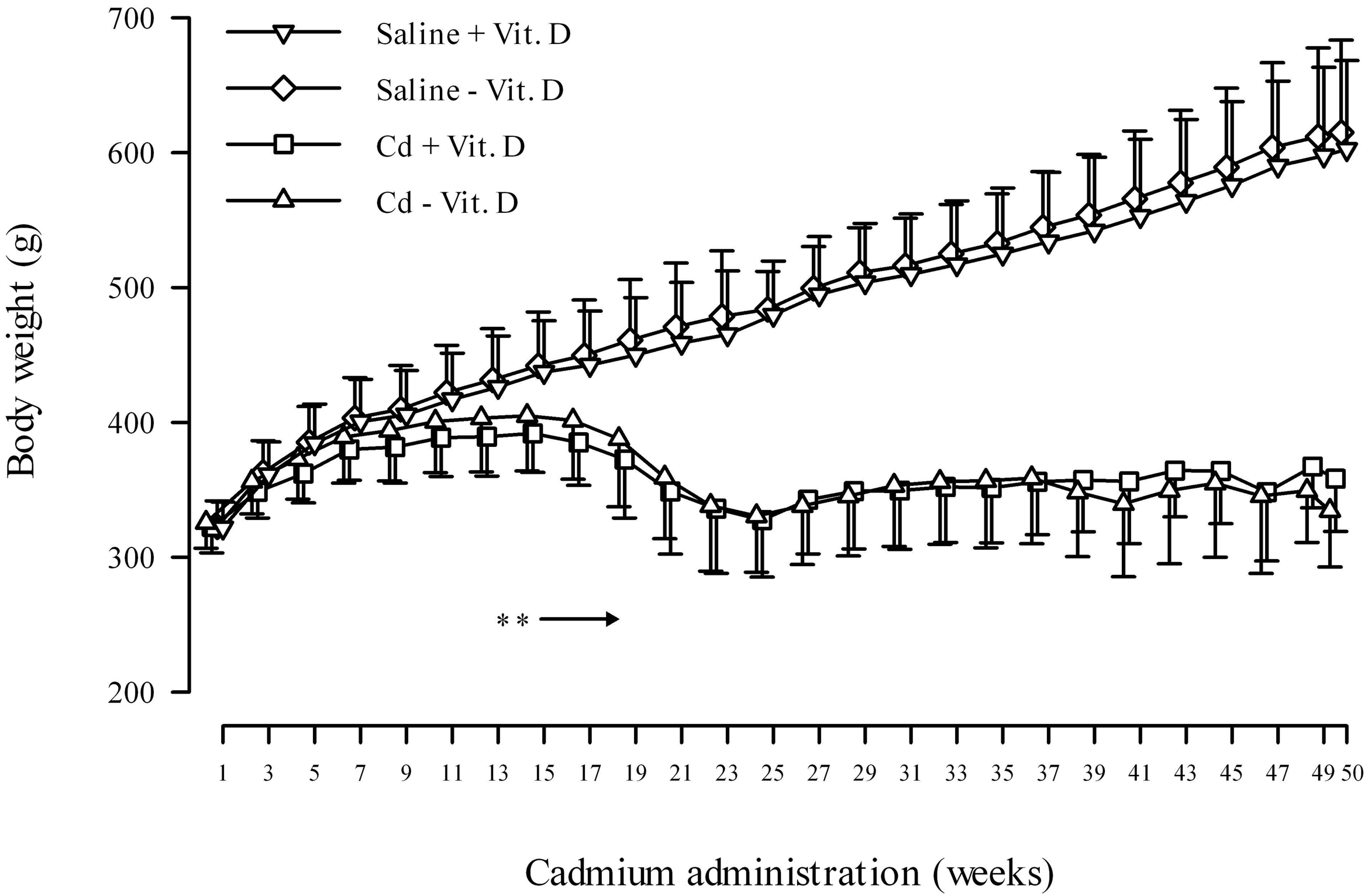
Saline + Vit. D
Saline - Vit. D
Cd + Vit. D
Cd - Vit. D
Body weight (g)
700
600
500
400
300
200
* *
1 3 5 7 9 11 13 15 17 19 21 23 25 27 29 31 33 35 37 39 41 43 45 47 49 50
Cadmium administration (weeks)

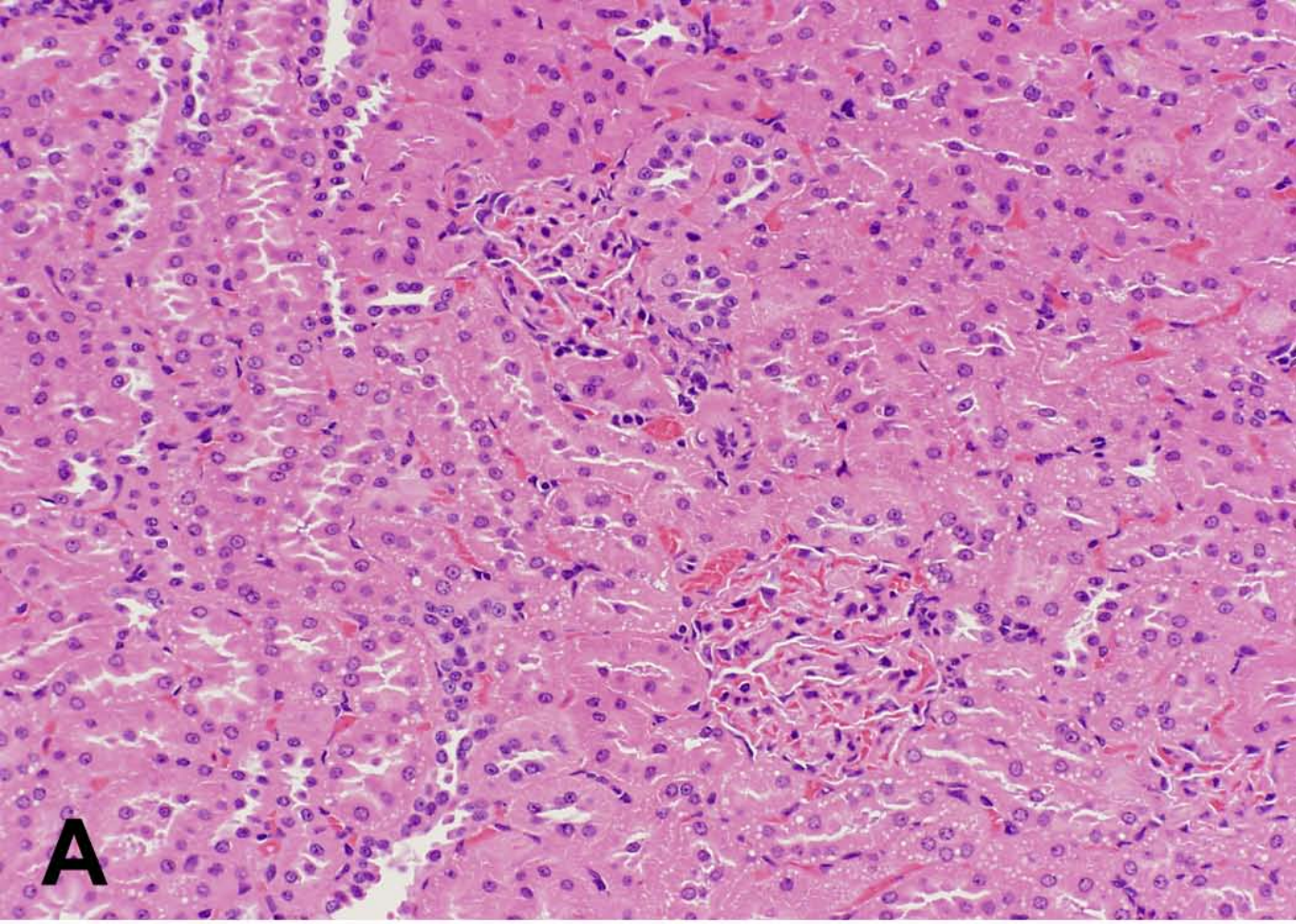
A

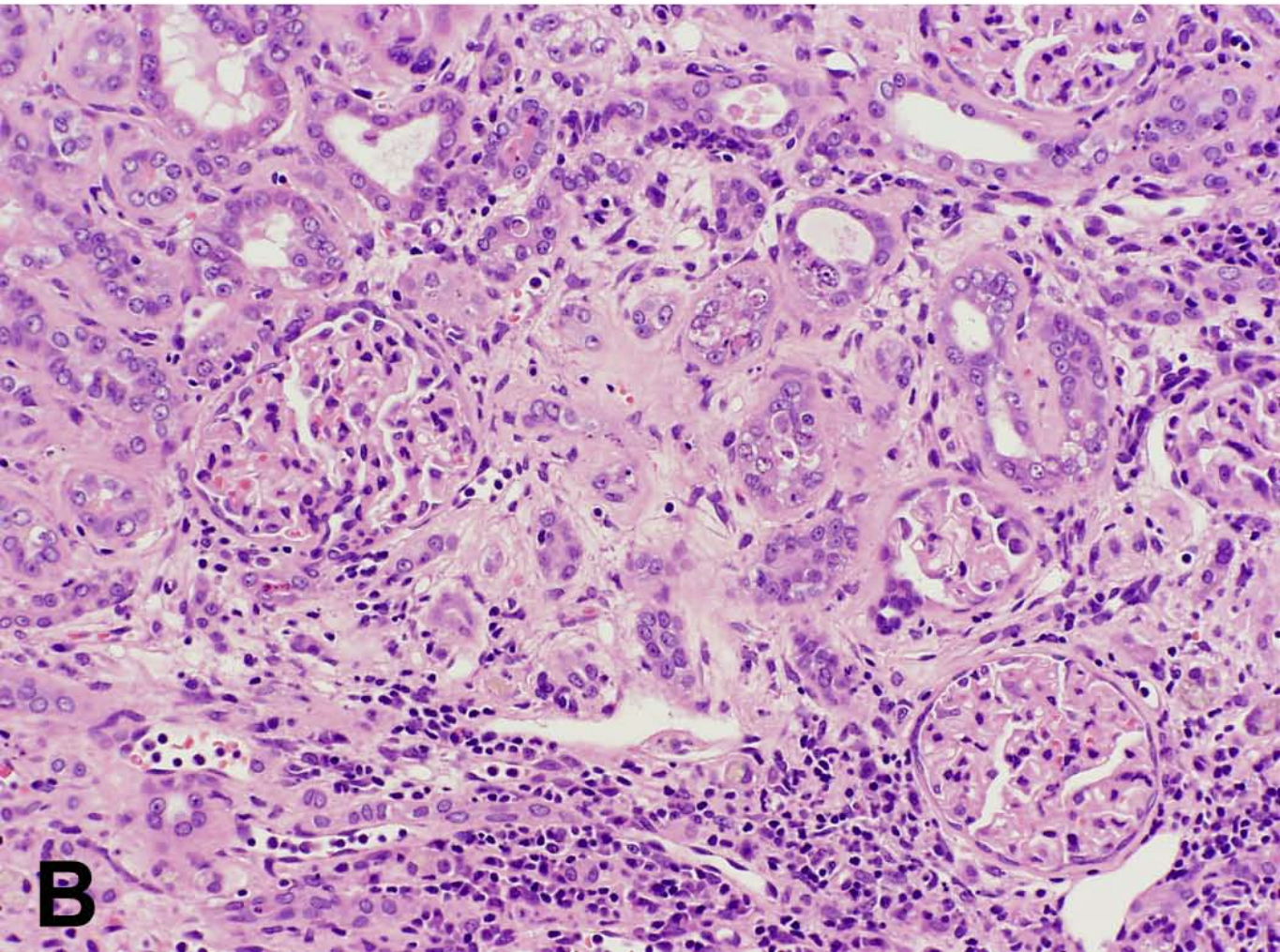
B

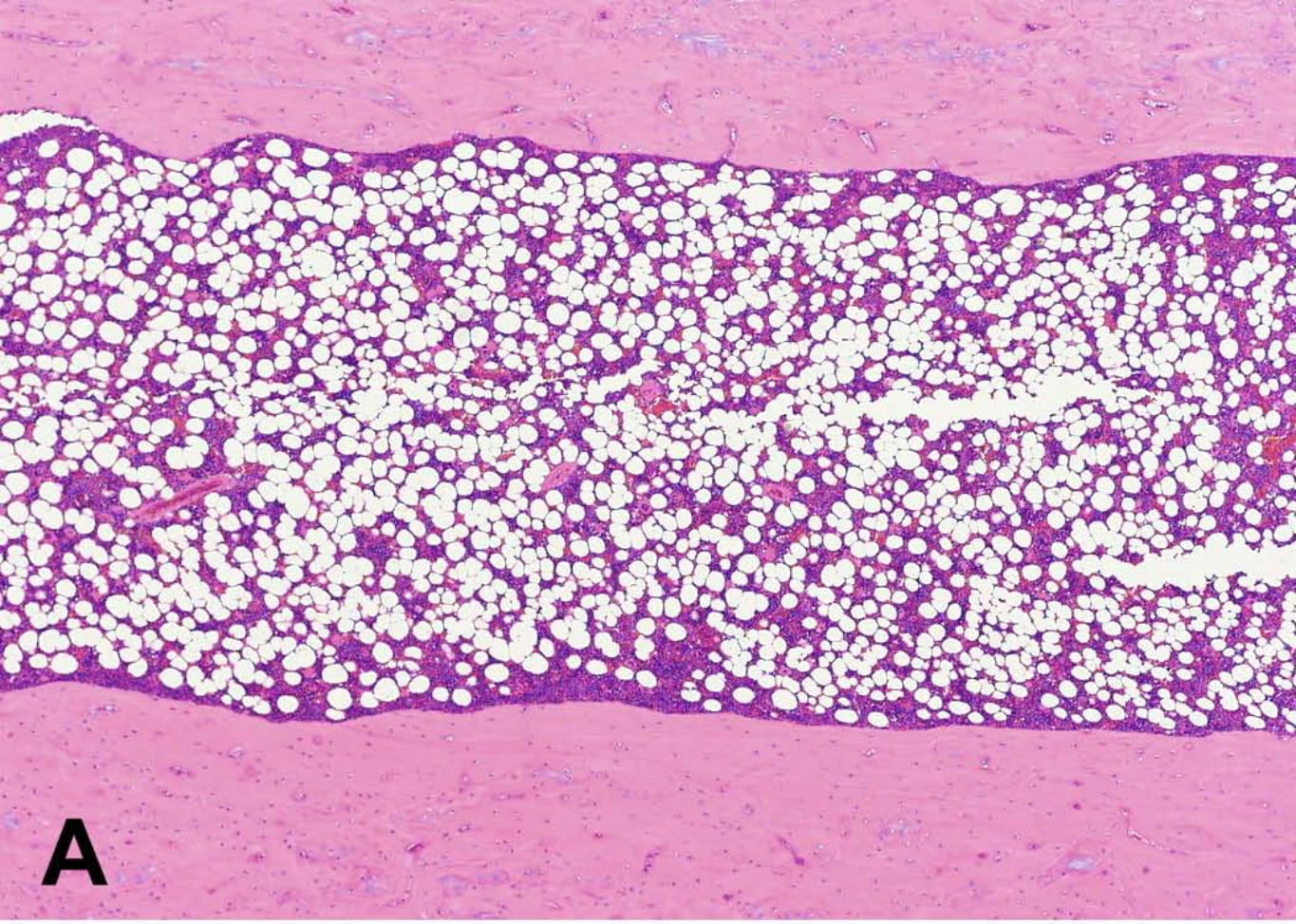
A

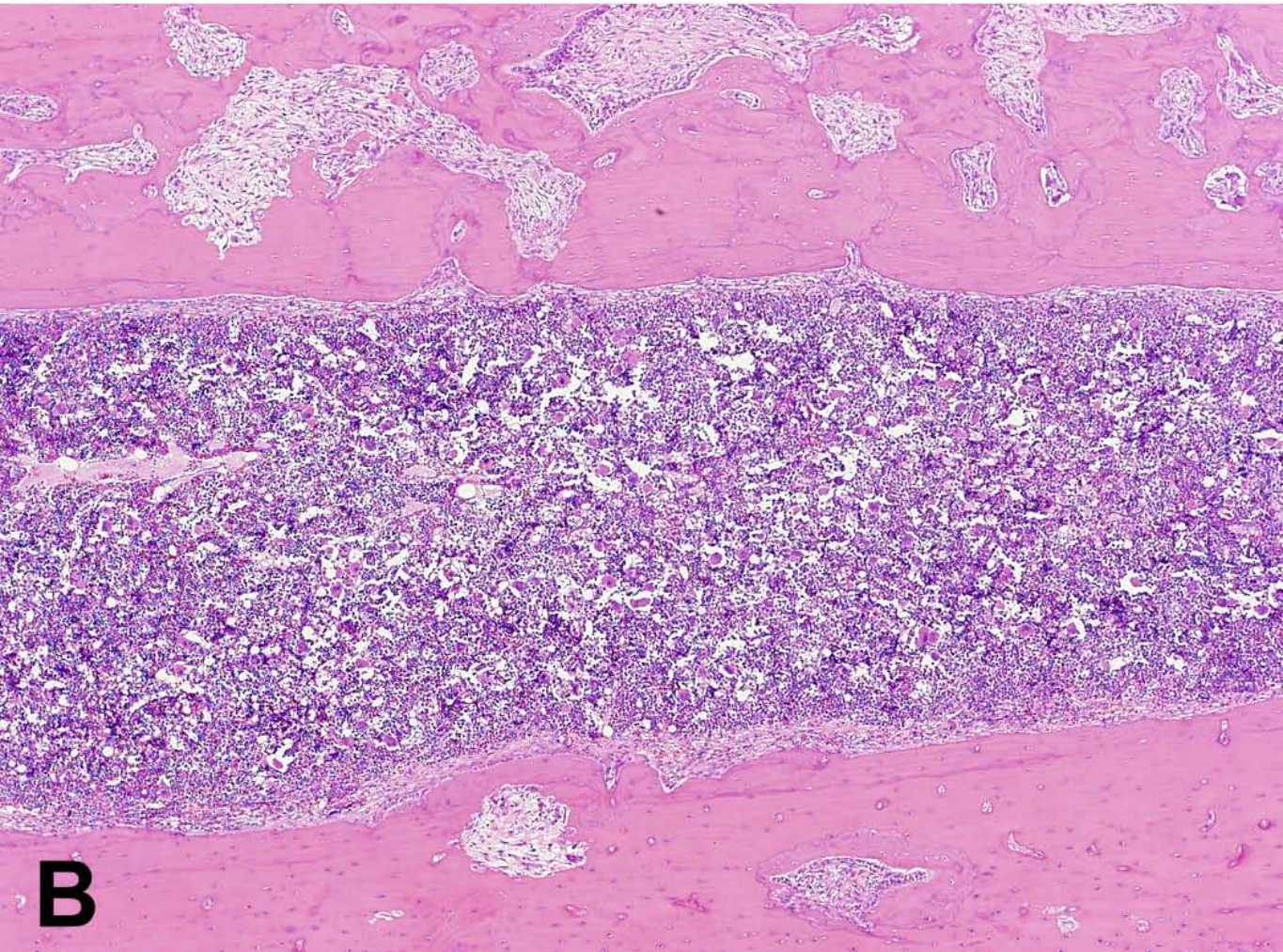
B

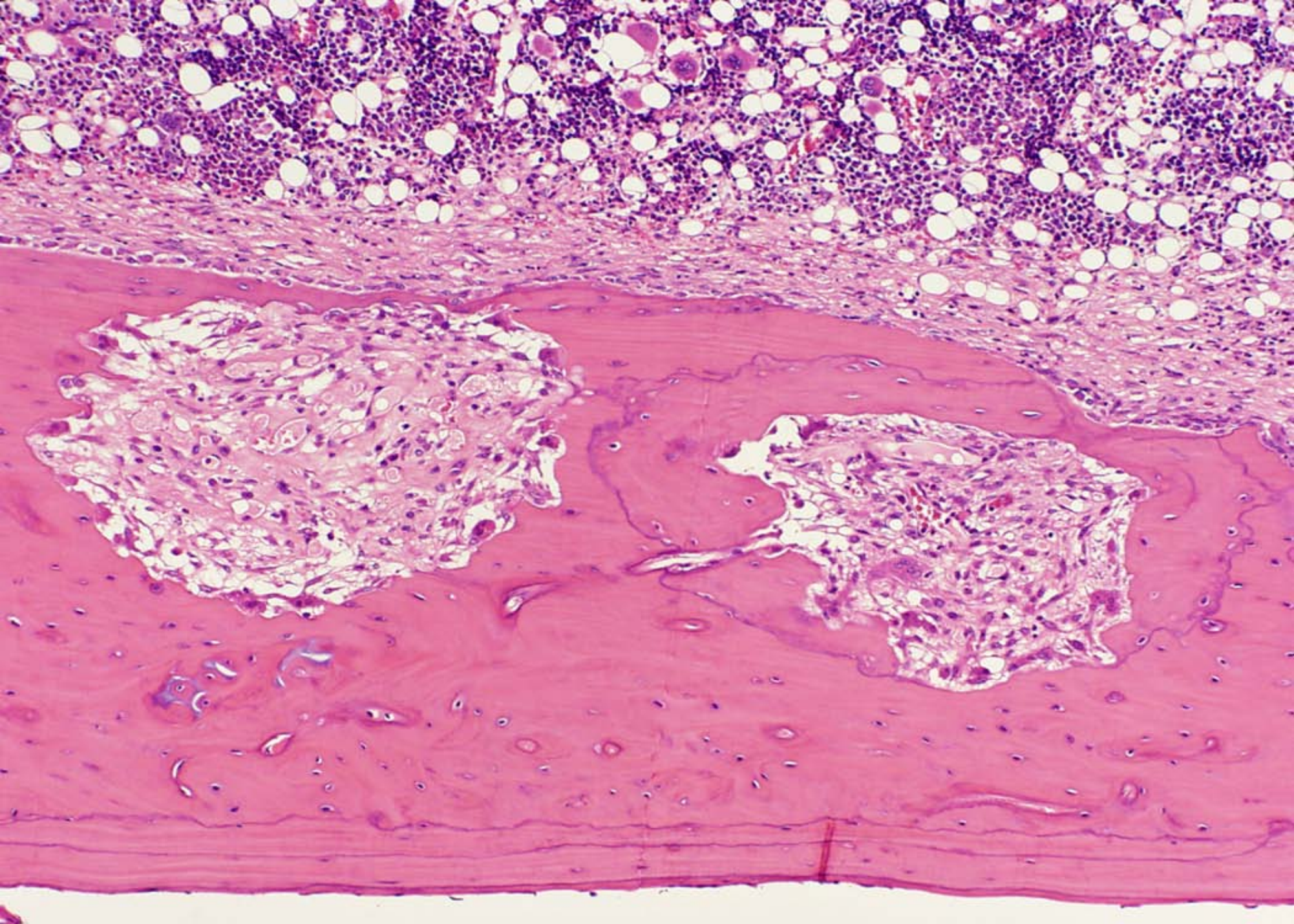

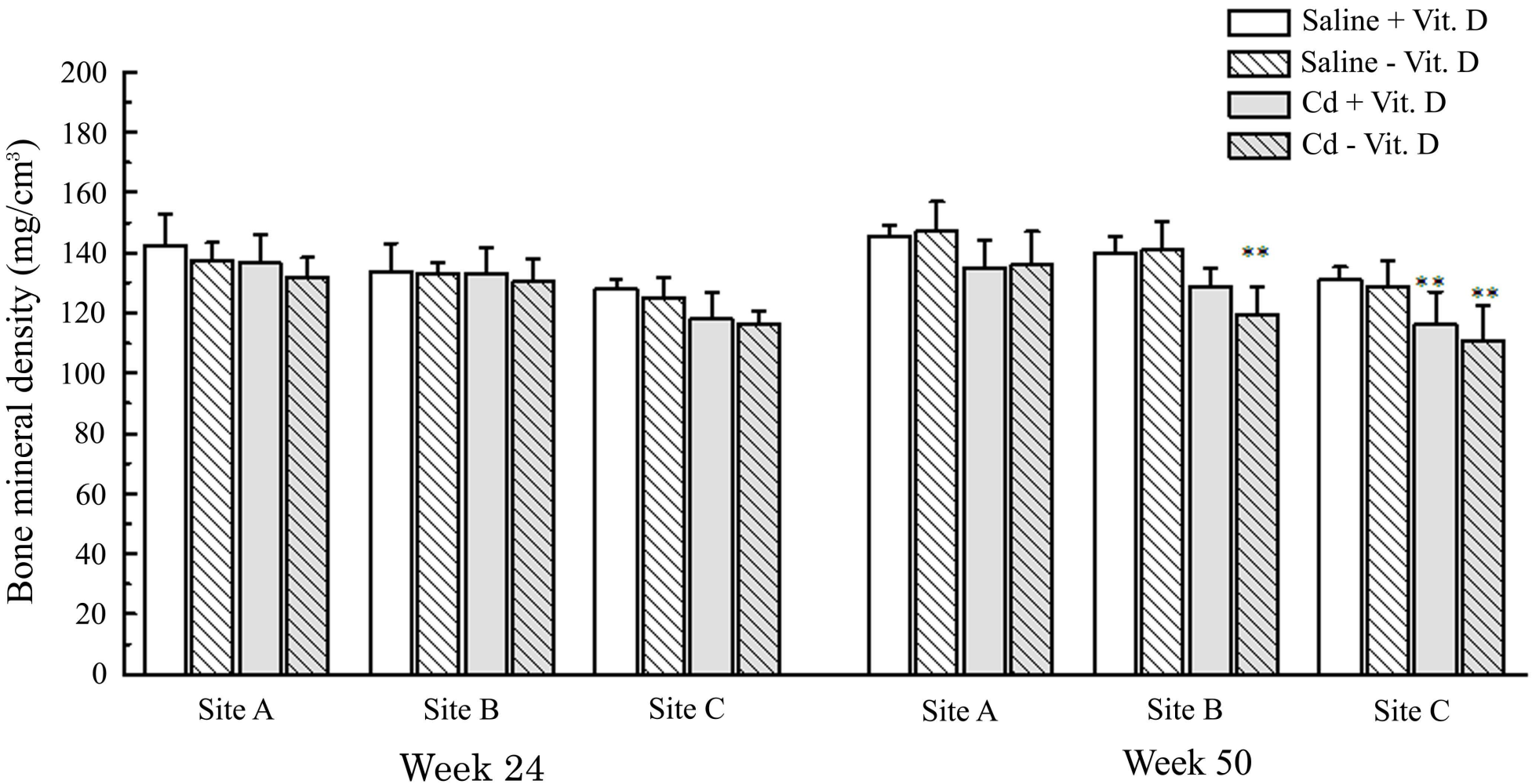
Saline + Vit. D
Saline - Vit. D
Cd + Vit. D
Cd - Vit. D
Bone mineral density (mg/cm³)
200
180
160
140
120
100
80
60
40
20
0
**
**
**
Site A
Site B
Site C
Site A
Site B
Site C
Week 24
Week 50