HOKKAIDO UNIVERSITY

Title	Anti-laminin-gamma 1 Pemphigoid with Generalized Pustular Psoriasis and Psoriasis Vulgaris
Author(s)	Fujimura, Yu; Natsuga, Ken; Hamade, Yohei et al.
Citation	Acta dermato-venereologica, 96(1), 120-121 https://doi.org/10.2340/00015555-2168
Issue Date	2016-01
Doc URL	https://hdl.handle.net/2115/60856
Type	journal article
File Information	4463.pdf

Hokkaido University Collection of Scholarly and Academic Papers : HUSCAP

Acta Derm Venereol 2016; 96: 120–121

SHORT COMMUNICATION

Anti-laminin-gamma 1 Pemphigoid with Generalized Pustular Psoriasis and Psoriasis Vulgaris

Yu Fujimura[1], Ken Natsuga[1]*, Yohei Hamade[1], Yukiko Nomura[1], Yo Kaku[2], Ryuichi Muramatsu[3] and Hiroshi Shimizu[1]
*Departments of Dermatology, [1]Hokkaido University Graduate School of Medicine, N15 W7, Sapporo 060-8638, [2]Kuriyama Red Cross Hospital, Kuriyama, and [3]Iwamizawa City Hospital, Iwamizawa, Japan. *E-mail: natsuga@med.hokudai.ac.jp*
Accepted Jun 11, 2015; Epub ahead of print Jun 15, 2015

Anti-p200 pemphigoid was first described in 1996 (1, 2) as a subepidermal blistering disorder characterized by auto-antibodies against a 200-kDa protein (p200) of the basement membrane zone (BMZ). In 2009, 90% of anti-p200 pemphigoid sera were reported to react with laminin γ1 (3). Approximately 30% of published cases of anti-laminin γ1 pemphigoid are associated with psoriasis vulgaris (PV) (4, 5), although the coexistence of anti-laminin γ1 pemphigoid and generalized pustular psoriasis (GPP) is rare. We describe here a rare case of anti-laminin γ1 pemphigoid with GPP plus PV in which no *IL36RN* or *CARD14* mutations were identified.

CASE REPORT

A 73-year-old Japanese woman with a 9-year history of PV was referred to our hospital due to erythema with pustules over her whole body and blisters on her trunk and extremities. Six months prior to referral, she had had the same symptoms and had been treated with etretinate, 40 mg/day, and topical corticosteroid for 2 months. The erythema with pustules had healed, but erosions remained, despite the etretinate treatment. Therefore, etretinate was stopped and oral prednisolone, 20 mg/day (0.33 mg/kg/day), was started, which ameliorated the erosions. When the prednisolone was tapered to 11 mg/day, pustules and blisters flared up. Physical examination revealed itchy erythema with tiny pustules over the whole body, and several tense blisters on her trunk and extremities (Fig. 1). Laboratory studies revealed elevated white blood cell count (18,100/µl) and C-reactive protein (2.25 mg/dl). Enzyme-linked immunosorbent assay showed that the indices of antibodies against BP180NC16A, desmoglein 1 and 3 were all within normal limits (MBL, Nagoya, Japan). Histological skin examination showed a spongiform pustule of Kogoj (Fig. 2a) and a subepidermal blister with infiltration of neutrophils (Fig. 2b). Direct immunofluorescence showed linear deposits of IgG and C3 around the BMZ (data not shown). Indirect immunofluorescence (IIF) detected serum IgG antibodies against BMZ at a titre of 1:80. IIF using 1 M NaCl-split human skin showed IgG antibodies binding to the dermal side of the split skin (Fig. 2c). Immunoblotting (IB) with dermal extracts identified a 200-kDa protein (Fig. 2d). Mutation analysis for genes associated with GPP revealed that the patient did not have *CARD14* p.Asp176His or mutations in *IL36RN*. From these findings, a diagnosis of anti-laminin γ1 pemphigoid and GPP/PV was made. The pustules and blisters disappeared after treatment with prednisolone at 40 mg/day (0.67 mg/kg/day) and etretinate at 30 mg/day. The blisters recurred when the prednisolone was tapered. The addition of dapsone at 50 mg/day abolished the blister formation.

Fig. 1. Clinical presentation at patient's first presentation to our hospital. (a) Erythema with small pustules on the whole body, and blisters on the trunk and extremities. (b) Erythema with small pustules on the trunk. (c) Blisters on the forearm.

DISCUSSION

The mechanism of development of anti-laminin γ1 pemphigoid in psoriatic skin has not been fully elucidated, but it has been hypothesized that matrix metalloproteinase-9 released from neutrophils in psoriatic skin degrades matrix proteins including laminins and that the degraded laminins are recognized by autoantibodies due to aberrant immune tolerance (5). An alternative possible reason for the high

© 2016 The Authors. doi: 10.2340/00015555-2168
Journal Compilation © 2016 Acta Dermato-Venereologica. ISSN 0001-5555

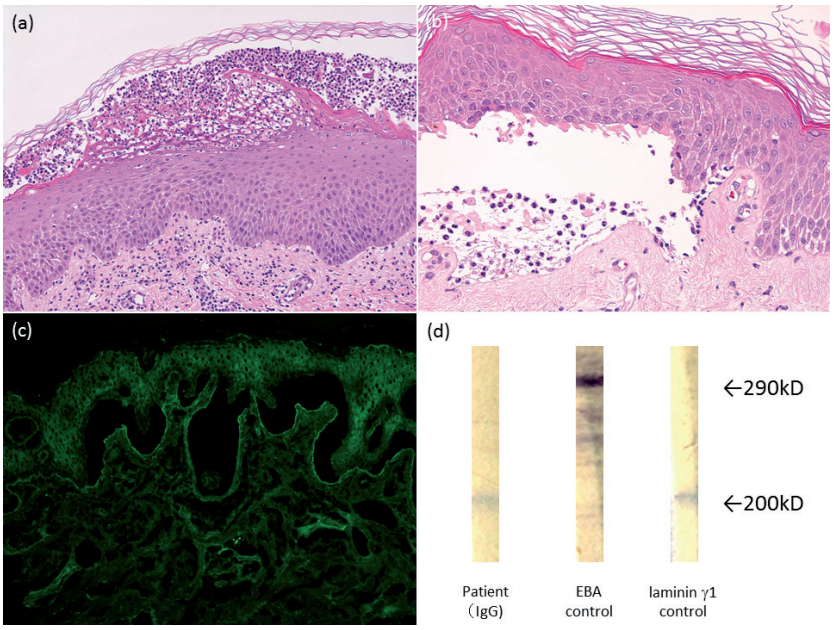

Fig 2. Histological and immunological findings. (a) Skin biopsy from erythema with pustule show a spongiform pustule of Kogoj (haematoxylin and eosin (H&E), original magnification × 100). (b) Skin biopsy from a blister shows a subepidermal blister with infiltration of mainly neutrophils along with a few eosinophils (H&E, original magnification × 200). (c) Indirect immunofluorescence (IIF) using 1M NaCl-split human skin shows immunoglobulin G (IgG) antibodies binding to the dermal side of the split skin (original magnification × 100). (d) Results of immunoblotting (IB) with dermal extracts. IgG from the patient reacts with the 200-kDa protein.

prevalence of psoriasis in patients with anti-laminin γ1 pemphigoid is that disruption of the basement membrane laminins is a key aspect in the pathogenesis of psoriasis (6).

Treatments for anti-laminin γ1 pemphigoid include oral and topical corticosteroid, minocycline and cyclosporine. Dapsone has also been shown to achieve favourable responses in some cases (7).

So far, only 3 cases of anti-laminin γ1 pemphigoid associated with GPP have been reported (8). Of these, 2 were diagnosed as having GPP with PV. Recent advances in skin disease genetics have led to the identification of a *CARD14* mutation (p.Asp176His) as a significant risk factor for GPP preceded or accompanied by PV (9), whereas *IL36RN* mutations are typically seen in GPP patients without PV (10). Our case harboured neither *CARD14* p.Asp176His nor *IL36RN* mutation. As GPP is thought to be a heterogeneous group of disorders that show extensive pustular formation on the body, it is possible that anti-laminin γ1 pemphigoid plus GPP with PV is based on unknown genetic abnormalities other than *CARD14* or *IL36RN* mutations. Further case reports and mutation analysis are needed to clarify this question.

The authors declare no conflicts of interest.

REFERENCES

1. Chen KR, Shimizu S, Miyakawa S, Ishiko A, Shimizu H, Hashimoto T. Coexistence of psoriasis and an unusual IgG-mediated subepidermal bullous dermatosis: identification of a novel 200-kDa lower lamina lucida target antigen. Br J Dermatol 1996; 134: 340–346.
2. Zillikens D, Kawahara Y, Ishiko A, Shimizu H, Mayer J, Rank CV, et al. A novel subepidermal blistering disease with autoantibodies to a 200-kDa antigen of the basement membrane zone. J Invest Dermatol 1996; 106: 1333–1338.
3. Dainichi T, Kurono S, Ohyama B, Ishii N, Sanzen N, Hayashi M, et al. Anti-laminin gamma-1 pemphigoid. Proc Natl Acad Sci U S A 2009; 106: 2800–2805.
4. Dilling A, Rose C, Hashimoto T, Zillikens D, Shimanovich I. Anti-p200 pemphigoid: a novel autoimmune subepidermal blistering disease. J Dermatol 2007; 34: 1–8.
5. Dainichi T, Koga H, Tsuji T, Ishii N, Ohyama B, Ueda A, et al. From anti-p200 pemphigoid to anti-laminin gamma1 pemphigoid. J Dermatol 2010; 37: 231–238.
6. McFadden JP, Powles A, Kimber I, Fry L. Psoriasis and basement-membrane laminin. Br J Dermatol 2013; 169: 718–719.
7. Yamane N, Sawamura D, Nishie W, Abe M, Kodama K, Adachi K, et al. Anti-p200 pemphigoid in a 17-year-old girl successfully treated with systemic corticosteroid and dapsone. Br J Dermatol 2007; 156: 1075–1078.
8. Igarashi M, Tsunemi Y, Koga H, Hashimoto T, Tateishi C, Tsuruta D, et al. Anti-laminin γ1 pemphigoid associated with pustular psoriasis. Eur J Dermatol 2014; 24: 629–630.
9. Sugiura K, Muto M, Akiyama M. CARD14 c.526G>C (p.Asp176His) is a significant risk factor for generalized pustular psoriasis with psoriasis vulgaris in the Japanese cohort. J Invest Dermatol 2014; 134: 1755–1757.
10. Sugiura K, Takemoto A, Yamaguchi M, Takahashi H, Shoda Y, Mitsuma T, et al. The majority of generalized pustular psoriasis without psoriasis vulgaris is caused by deficiency of interleukin-36 receptor antagonist. J Invest Dermatol 2013; 133: 2514–2521.