HOKKAIDO UNIVERSITY

Title	Recovery of Impaired Somatosensory Evoked Fields after Improvement of Tongue Sensory Deficits with Neurosurgical Reconstruction
Author(s)	Maezawa, Hitoshi; Tojyo, Itaru; Yoshida, Kazuya et al.
Citation	Journal of Oral and Maxillofacial Surgery, 74(7), 1473-1482 https://doi.org/10.1016/j.joms.2016.01.011
Issue Date	2016-01-08
Doc URL	https://hdl.handle.net/2115/64029
Rights	© 2016. This manuscript version is made available under the CC-BY-NC-ND 4.0 license http://creativecommons.org/licenses/by-nc-nd/4.0/
Rights(URL)	https://creativecommons.org/licenses/by-nc-nd/4.0/
Type	journal article
File Information	manuscript.pdf

Hokkaido University Collection of Scholarly and Academic Papers : HUSCAP

Recovery of Impaired Somatosensory Evoked Fields after Improvement of Tongue Sensory Deficits with Neurosurgical Reconstruction

Hitoshi Maezawa [1, 2, *], Itaru Tojyo [3], Kazuya Yoshida [4], Shigeyuki Fujita [3]

[1]Human Brain Research Center, Graduate School of Medicine, Kyoto University, Sakyo-ku, Kyoto, Japan
[2]Department of Oral Physiology, Graduate School of Dental Medicine, Hokkaido University, Kita-ku, Sapporo, Japan
[3]Department of Oral and Maxillofacial Surgery, School of Medicine, Wakayama Medical University, Kimiidera, Wakayama, Japan
[4]Department of Oral and Maxillofacial Surgery, National Hospital Organization, Kyoto Medical Center, Fushimi-ku, Kyoto, Japan

*Corresponding author: Hitoshi Maezawa, DDS, PhD, Assistant professor
Address: Department of Oral Physiology, Graduate School of Dental Medicine, Hokkaido University, Kita-ku, Sapporo, Hokkaido 060-8586, Japan
TEL: 81-11-706-4229; FAX: 81-11-706-4229
E-mail: maezawa@den.hokudai.ac.jp

Keywords: magnetoencephalography, lingual nerve, sensory deficit, nerve injury, MEG, neurosurgical reconstruction

Abstract

Somatosensory evoked fields (SEFs) induced by tongue stimulation can be useful as an objective parameter to assess sensory disturbances in the tongue. However, whether tongue SEFs can be useful as a clinical, objective follow-up assessment method of tongue sensation following oral surgery is unknown. Here we describe two cases in which tongue SEFs were successfully used in a clinical assessment. Two patients with unilateral tongue sensory deficits caused by lingual nerve injury during lower third molar extraction were recruited. Both patients underwent oral surgery to repair the damaged nerve, and all tongue sensory evaluations were made once before and once after surgery. SEFs were recorded by stimulating the affected and unaffected sides of the tongue separately, and cortical activity was evaluated over the contralateral hemisphere. The unilaterality of the deficit was also assessed. In both patients, stimulation of the unaffected side evoked reproducible cortical responses pre- and post-surgery. Both patients also recovered some sensation following surgery, as pre-surgery stimulation of the affected side failed to evoke cortical activity, whereas post-surgery stimulation evoked cortical activity on both sides. Sensation was initially highly lateralized in both patients, but was restored to approximately normal in the post-surgery evaluation. Finally, both patients' rated their subjective tongue sensations on the affected side over 50% better after the surgical intervention. These cases indicate that tongue SEFs may have a clinical use as an objective parameter for assessing the course of tongue sensory recovery.

Introduction

Sensory disturbance of the tongue caused by lingual nerve injury can sometimes lead to speech and eating difficulties, and can affect the patient's quality of life significantly. Several recent papers have reported that oral surgeries for the impaired lingual nerve, such as microneurosurgical reconstruction, are useful for recovering sensation and reducing the sensory disturbance.[1-8] In clinical situations, several sensibility tests, such as the two-point discrimination (TPD) test, are often used to assess the course of symptomatic sensory recovery of the tongue. However, the reproducibility of these tests is not high, since they depend on subjective self-assessments. Therefore, assessment methods that are objective, more reliable, and reproducible are required for following the sensory recovery of the tongue.[9,10]

Recently, we demonstrated that the evoked cortical response following tongue stimulation as measured by magnetoencephalography (MEG) can serve as an objective parameter for detecting sensory disturbances of the tongue caused by unilateral lingual nerve damage.[11,12] In these studies, we found high intra-subject similarity of somatosensory evoked field (SEF) waveforms between the right and left sides of the tongue, which suggested that the unaffected (control) side of the tongue could serve as a reference for the affected (damaged) side in patients with unilateral lingual nerve injury. To evaluate cortical activity, we employed the activated root-mean-square (aRMS) parameter (see the Materials and Methods section for details), which utilizes the time average of the 18-channel RMS obtained from tongue SEFs. We successfully estimated the unilateral sensory disturbance of the tongue in each patient using a laterality index derived from the aRMS. However, it is not known if the objective assessment of tongue sensory disturbance using MEG can be useful as a follow-up assessment method in the clinical course of tongue sensory recovery.

Here we report two cases in which we successfully evaluated sensory recovery in the tongue by measuring tongue SEFs both before and after sensory recovery related to oral surgical intervention. A portion of this study has been reported previously.[11]

Case Reports

We recruited two right-handed patients (one male, one female, both aged 21 years) with sensory disturbance of the tongue (Table 1). Both of the patients met the following five criteria: (1) The sensory defect was caused by unilateral lingual nerve injury during third molar extraction; (2) Initial rating of the subjective sensation of the affected area was less than half of that of the unaffected area; (3) TPD of the affected area exceeded 5 mm; (4) Rating of the subjective sensation recovered to greater than half after oral surgery (details of surgical procedures are described below); (5) No pain sensation. The study was run in accordance with the Helsinki Declaration. Written informed consent was obtained from both participants, in accordance with the study protocol approved by the Ethics Committee, Kyoto University Graduate School of Medicine and Wakayama Medical University.

In the surgical intervention, the injured lingual nerve was exposed through an intraoral mucosal incision and lingual flap reflection by the same operator (SF). External neurolysis was performed in both patients. Optical magnifying glasses (250 mm) and an operating microscope (Superlux 301, Zeiss, Germany) were available during surgery.

In the case of Patient 1, almost all of the lingual nerves in the surgical site for the lower third molar extraction were intact under microscopic view. However, the part of the lingual nerve adjacent to the second molar had a sharp crescent-like fragment of the

extracted third molar crown inserted within it, creating a delicate and small wound (Fig 1). Therefore, we removed the fragment and sutured the small torn epineurium with 9-0 nylon.

In Patient 2, the lingual nerves adhered to the periosteum adjacent to the extracted lower second molar region and were disrupted in the form of a spiral groove about 8-mm long, which was a delicate and shallow wound within the depth of the epineurium, but not deep into the perineurium (Fig 2). We removed the scars in these wounds and sutured them with 9-0 nylon using the microscope.

Sensibility Tests, Sensory Evaluation, and Nerve Condition Assessment

The patients' TPD, tactile sensation, and gustatory sensation of the affected side and its bilaterally symmetric healthy side were evaluated in a quiet room. Subjects were requested to close their eyes. TPD was evaluated by 5 grades: ≤5, >5, 10, 15, and 20 mm using the Disk-Criminator (Kono Seisakusyo, Chiba, Japan) with four stepwise spaces between 5 to 20 mm. Subjects were instructed to indicate with their fingers whether they felt one or two-points during the application of the Disk-Criminator (Kono Seisakusyo, Chiba, Japan). Tactile sensation was also classified into five grades using Semmes-Weinstein monofilaments (Kono Seisakusyo, Chiba, Japan).[13] The perception tester is composed of four discrete monofilaments that have different diameters and produce four steps of stimulus magnitude: 2.83, 3.61, 4.31, and 6.65. The monofilament was applied to the same point as the electrical stimulation (2 cm lateral to the midline of the lower lip crust) with sufficient force until it bent, and held for 2 s. Subjects were required to gesture "yes" each time they sensed the application of the monofilaments. Gustatory sensation was assessed with localized testing disks (Sanwa Kagaku

Kenkyusho, Nagoya, Japan; salt, 1 M sodium chloride; sweet, 1 M sucrose; sour, 0.4 M acetic acid; bitter, 0.1 M quinine).

Sensory evaluations of the tongue were assessed using the British Medical Research Council (BMRC) Criteria.[14,15] The condition of the injured lingual nerve was assessed by Sunderland[16] and Seddon[17] classification during the surgical procedures.

Tongue Stimulation

The affected and unaffected sides of the tongue were stimulated separately using an electrical stimulator (SEN7203, Nihon Kohden, Tokyo, Japan) through a pair of pin electrodes, as we reported previously.[12,18] Biphasic constant current square electric pulses (0.5 ms for one phase) were applied at 1 Hz. The stimulus intensity of four times the sensory threshold in the unaffected area was used for both sides in each patient. The average number of stimuli applied was 600 for each side, and two sessions separated by a rest period were held in each stimulus point. The group-averaged data of two sessions were used for further analysis. The unaffected side was stimulated first in both patients.

Magnetoencephalographic Recordings

SEFs were recorded with a whole-head neuromagnetometer (Vectorview, Elekta Neuromag, Helsinki, Finland) equipped with 102 sensor units consisting of two planar gradiometers and one magnetometer by the same experimenter (HM). Data from 204 planar gradiometers were used for analysis since the planar gradiometers detect the largest signal just above the corresponding source.[19] The recording bandpass was 0.1 to 990 Hz, and the sampling rate was 2997 Hz. The analysis window for averaging was 100 ms before to 500 ms after each trigger signal, and epochs with signal variation

greater than 1500 fT/cm were excluded automatically from averaging. The baseline was calculated from -50 to -5 ms before stimulus onset.

Data Analysis

To estimate the evoked cortical activation for tongue stimulation, we used the aRMS as described in our previous studies.[11,12] First, we calculated the spatial summation of the RMS from the contralateral 18-channel waveforms including the maximum amplitude channel. In one patient (Patient 2), no reliable response was detected following affected side stimulation. In this case, we selected 18 channels homologous to those channels analyzed for unaffected side stimulation to obtain the aRMS for affected side stimulation. Second, we calculated the temporal average of the RMS for the 10–150 ms period (RMS[10,150]) and subtracted the mean amplitude of the baseline RMS (RMS[-50,-5]) to obtain the aRMS.

Moreover, to assess the unilateral sensory disturbance of the tongue in each participant, the laterality index of the aRMS, expressed as (left − right)/(left + right), was compared to the normal range. The normal range was -0.287 to 0.337, which was set to the average ± 3 standard deviations (SD) of the laterality index obtained from 10 healthy volunteers, as described in our previous report.[10]

Results

Case 1

Sensibility Tests and Sensory Evaluations

The results of the sensibility tests and sensory evaluations are described in Table 2. The sensory evaluation scores showed that the sensory function improved by 2 levels of

the BMRC score. Patient 1 had first degree injury by Sunderland classification, and neurapraxia by Seddon classification. The unaffected side showed that the Semmes-Weinstein test score was 2.83 and Disk-Criminator score was <5 mm in both recordings.

SEFs and aRMS

Sensory threshold and stimulus intensity are described in Table 3. A traceable response was observed over the contralateral hemisphere following affected side (right side) stimulation in one patient (Patient 1) in the first recording (Fig 3). In contrast, a clear response was observed after sensory recovery in the second measurement in this patient (Patient 1) (Fig 4, Fig 5). Reproducible clear responses were detected during unaffected side stimulation both before and after sensory recovery (Fig 5).

In the first recording, the aRMS for affected side stimulation was 2.4 fT/cm, and it recovered to 4.4 fT/cm in the second recording (Table 2). The aRMS for unaffected side stimulation was 8.4 fT/cm in the first recording, and was 7.7 fT/cm in the second recording (Table 2).

Case 2

Sensibility Tests and Sensory Evaluations

The sensory evaluation scores showed that the sensory function of Patient 2 improved by 3 levels by the BMRC score (Table 2). Patient 2 had second or third degree injury by Sunderland classification, and axonotmesis by Seddon classification. As described above for Case 1, the unaffected side showed a Semmes-Weinstein score of 2.83 and Disk-Criminator score of <5 mm in both recordings.

SEFs and aRMS

Sensory threshold and stimulus intensity are described in Table 3. No reliable response was detected following stimulation of the affected side (left side) in the first recording (Fig 6). In contrast, a clear response was observed in the second recording following stimulation of the affected side (left side). Clear activity was detected over the contralateral hemisphere during unaffected side (right side) stimulation, which was reproducible between the first and second recordings (Fig 6).

In the first recording, the aRMS for affected side stimulation was 0.4 fT/cm, and it recovered to 1.9 fT/cm in the second recording (Table 2). The aRMS for unaffected side stimulation was 2.5 fT/cm in the first recording, and was 3.1 fT/cm in the second recording (Table 2).

Laterality index of aRMS for both patients

The laterality index was out of the normal range in both patients in the first recording (0.556 [Patient 1] and -0.724 [Patient 2]) (Table 2, Fig 7). However, in the second recording, the laterality index was within the normal range in both patients (0.273 [Patient 1] and -0.240 [Patient 2]).

Discussion

In this study, we analyzed two cases in which we tried to assess the clinical course of tongue sensory recovery. In both patients, the laterality index was out of the pre-determined normal range before sensory recovery, but was within the normal range

after sensory recovery. In addition, both objective and subjective markers of nerve-damage-related deficits in tongue sensation were improved following surgery.

Previous studies have reported that evoked cortical responses following lingual nerve stimulation are useful for detecting sensory disturbances of the tongue using electroencephalography or MEG recordings.[12,20] However, there have been no reports examining the usefulness of cortical responses as a follow-up assessment method for tongue sensory recovery after oral surgery.

In the present study, we adopted an objective assessment for patients using the quantitative parameter aRMS, which represented cortical activation.[11] This method is advantageous because an objective parameter can be calculated easily, without having to identify individual components visually. In fact, in our previous study on tongue SEF in ten healthy volunteers, three or four components were identified. However, because none of those components was consistently detected in all healthy subjects, neither the latency nor amplitude of the components could be considered a reliable parameter (Maezawa et al., 2008). This is especially important since the existence of the response was based on an estimator's subjective impression, and was sometimes difficult to judge.

We found that in both patients, stimulation of the affected side induced RMS waveforms with obviously larger amplitudes in the second recording (after sensory recovery) than in the first recording (before sensory recovery). In contrast, a reproducible response was observed following unaffected side stimulation between the first and second recordings. Judging the sensory disturbance objectively at each measurement time (before and after sensory recovery) using the laterality index, the value, which was above the normal range before sensory recovery, was within the

normal range along with the improvement of subjective symptoms in both patients. These results suggest that the laterality index parameter might be effective as an objective follow-up parameter for assessing tongue sensory recovery. Clinically, the commonly used diagnostic approaches of TPD and tactile sensation are subjective measures that do not always provide enough reliability and reproducibility. Quantitative assessment using the laterality index parameter aRMS is advantageous since it provides objective evidence of the disabled condition of the tongue at a given measurement time in the course of sensory recovery.

The intraoperative findings indicated that the lingual nerves were not seriously damaged in either patient. However, the severity of the lingual nerve injuries was different in each patient based on the Sunderland and Seddon classifications. Patient 1 had mild injury of the lingual nerve (first degree injury by Sunderland classification and neurapraxia by Seddon classification), whereas Patient 2 had an injury that was more severe (second or third degree injury by Sunderland classification and axonotmesis by Seddon classification). This is interesting given the different tongue SEFs between patients. In Patient 1, who had mild lingual nerve injury, a small response was detected with affected side stimulation in the first recording. In contrast, Patient 2, who had a more severe nerve injury, showed no response in the first recording. In future studies, we hope to increase the number of patients whose impaired nerve conditions can be visually assessed, and examine the relationship between the severity of the nerve condition and tongue SEFs. We hypothesize that it may be possible to predict the severity of lingual nerve injury non-invasively, by measuring tongue SEFs.

In conclusion, our study demonstrated the possibility that the laterality index, measured using the aRMS obtained from tongue SEFs, may serve as an objective

parameter for evaluating unilateral tongue sensory recovery. It could be possible to follow the sensory recovery of the tongue by analyzing the laterality of the cortical activity in response to tongue stimulation using MEG.

Acknowledgements

This work was supported by Grants-in-Aid for Young Scientists (B)25862071 (HM) from the Japan Society for the Promotion of Science. The authors thank Mr. Jun Matsubayashi, Masao Matsuhashi, Tatsuya Mima, and Hidenao Fukuyama (Kyoto university), and Takashi Nagamine (Sapporo medical university) for their advice on data analysis. None of the authors have potential conflicts of interest to be disclosed.

References

1. Miloro M: Peterson's principles of oral and maxillofacial surgery. Ontario, BC Decker Inc., 2004, pp 819

2. Ziccardi VB, Rivera L, Gomes J: Comparison of lingual and inferior alveolar nerve microsurgery outcomes. Quintessence Int 40:295, 2009

3. Smith KG, Robinson PP: An experimental study of lingual nerve repair using epineurial sutures or entubulation. Br J Oral Maxillofac Surg 33:211, 1995

4. Pogrel MA: The results of microneurosurgery of the alveolar and lingual nerve. J Oral Maxillofac Surg 60:485, 2002

5. Bagheri SC, Meyer RA, Khan HA, et al: Retrospective review of microsurgical repair of 222 lingual nerve injuries. J Oral Maxillofac Surg 68:715, 2010

6. Susarla SM, Kaban LB, Donoff RB, et al: Does early repair of lingual nerve injuries improve functional sensory recovery? J Oral Maxillofac Surg 65:1070, 2007

7. Fagin AP, Susarla SM, Donoff RB, et al: What factors are associated with functional sensory recovery following lingual nerve repair? J Oral Maxillofac Surg 70:2907, 2012

8. Fujita S, Tojyo I, Yamada M, et al:. Outcome following lingual nerve repair with vein graft cuff: a preliminary report. J Oral Maxillofac Surg 72:1433, 2014

9. Renton T, Thexton A, Crean SJ, et al: Simplifying the assessment of the recovery from surgical injury to the lingual nerve. Brit Dent J 200:569, 2006

10. Vriens JP, van der Glas HW: Extension of normal values on sensory function for facial areas using clinical tests on touch and two-point discrimination. Int J Oral Maxillofac Surg 38:1154, 2009

11. Maezawa H, Yoshida K, Nagamine T, et al: Somatosensory evoked magnetic fields following electric tongue stimulation using pin electrodes. Neurosci Res 62:131, 2008

12. Maezawa H, Yoshida K, Matsuhashi M, et al: Evaluation of tongue sensory disturbance by Somatosensory evoked magnetic fields following electric tongue stimulation. Neurosci Res 71:244, 2011

13. Weinstein S: Fifty years of somatosensory research: from the Semmes-Weinstein monofilaments to the Weinstein Enhanced Sensory Test. J Hand Ther 6:11, 1993

14. Mackinnon SE, Dellon AL: Surgery of the Peripheral Nerve. New York, NY, Thieme Medical Publishers, 1988

15. Mackinnon SE: Surgical management of the peripheral nerve gap. Clini Plast Surg 16:587, 1989

16. Sunderland S: The anatomy and physiology of nerve injury. Muscle Nerve 13:771, 1990

17. Seddon H: Three types of nerve injury. Brain 66:237, 1943

18. Maezawa H, Matsuhashi M, Yoshida K, et al: Evaluation of lip sensory disturbance using somatosensory evoked magnetic fields. Clin Neurophysiol 125:363, 2014

19. Hämäläinen M, Hari R, Ilmoniemi RJ, et al: Magnetoencephalography-theory, instrumentation, and applications to noninvasive studies of the working human brain. Rev Mod Phys 65:413, 1993

20. Altenmüller E, Cornelius CP, Buettner UW: Somatosensory evoked potentials following tongue stimulation in normal subjects and patients with lesions of afferent trigeminal system. Electroencephalogr Clin Neurophysiol 77:403, 1990

Table 1. PATIENT PROFILES

Pt	Sex	Age (years)	Lesion side	First oral surgery[*1]	Second oral surgery[*2]	Period 1[*3] (month)	Period 2[*4] (month)	Period 3[*5] (month)	Subjective sensation[*6]	
									F	S
1	Male	21	Right	Third molar extraction	Neurorrhaphy, Removal of fractured tooth	5	3	6	3	7–8
2	Female	21	Left	Third molar extraction	Neurorrhaphy	6	19	7	2	5

Abbreviations: Pt, Patient number; F, First measure; S, Second measure.

[*1]The surgery that caused lingual nerve injury.

[*2]The second surgery for the treatment of lingual nerve injury.

[*3]The period between the first oral surgery and the initial signs of sensory recovery.

[*4]The period between the first oral surgery and the second oral surgery.

[*5]The period between the first magnetoencephalography measure and the second magnetoencephalography measure.

[*6]Tongue sensation in the affected side was assessed on a subjective scale from 0–10.

Table 2. SENSORY FUNCTION OF THE TONGUE AND LINGUAL NERVE CONDITION

Pt	Sensibility tests				Gustatory sensation		Sensory evaluation *[1]		Nerve condition *[2]	
	1		2							
	TPD (mm)	TS	TPD (mm)	TS	1	2	1	2	Sunderland	Seddon
1	>20	4.31	>5	3.61	×	○	S2	S4	First degree	Neurapraxia
2	>20	4.31	>10	4.31	×	○	S0	S3	Second or third degree	Axonotmesis

Abbreviations: Pt, Patient number; 1, First measure; 2, Second measure; TPD, Two-point discrimination; TS, Tactile sensation; ×, absent; ○, present.

*[1]Sensory evaluations were assessed using the British Medical Research Council Criteria.[18,19]

*[2]Nerve condition was assessed by Sunderland and Seddon classification.[16,17]

Table 3. ELECTROPHYSIOLOGICAL FINDINGS

Pt	Sensory threshold (mA)				Intensity* (mA)		aRMS (fT/cm)				Laterality index	
	1		2		1	2	1		2		1	2
	U	A	U	A			U	A	U	A		
1	0.25	2.3	0.23	0.40	1.00	0.92	8.4	2.4	7.7	4.4	0.556	0.273
2	0.25	1.6	0.22	0.62	1.00	0.88	2.5	0.4	3.1	1.9	-0.724	-0.240

Abbreviations: Pt, Patient number; 1, First measure; 2, Second measure; U, Unaffected side; A, Affected side.

*The stimulus intensity was four times the sensory threshold of the unaffected side in each recording.

Figure legends

FIGURE 1. Intraoperative photographs used for assessing the nerve conditions in Patients 1. The lingual nerve was damaged by the tooth fragment of the extracted third molar crown.

FIGURE 2. Intraoperative photographs used for assessing the nerve conditions in Patient 2. An 8-mm long segment of the lingual nerve epineurium was spirally damaged (indicated by the arrowheads).

FIGURE 3. The magnetic waveforms of somatosensory evoked fields (SEFs) following affected side (right side) stimulation for the first measurement in Patient 1 (before sensory recovery). Whole-head magnetic waveforms of SEFs for the first measurement. The top view of the SEFs recorded by the planar 204-channel recording shows traceable responses over the contralateral area. Each trace started 50 ms before to 300 ms after stimulus onset. As shown in the expanded waveforms, a traceable response (indicated by the black circle) was identified over the contralateral hemisphere. The root-mean-square (RMS) waveforms over the contralateral hemisphere were calculated from 18-channel waveforms including the channel with local maximum amplitude (traces within dashed outlines). The vertical scale was 35 fT/cm. The two dashed lines in the graph show the time points of 10 ms and 150 ms, respectively.

FIGURE 4. The magnetic waveforms of somatosensory evoked fields (SEFs) following affected side (right side) stimulation for the second measurement in Patient 1 (after

sensory recovery). Whole-head magnetic SEF waveforms for the second measurement. Each trace started 50 ms before to 300 ms after stimulus onset. As shown in the expanded waveforms, clear responses (indicated by the arrow head) were detected over the contralateral area. The RMS waveforms were calculated from 18-channel waveforms over the contralateral hemisphere (traces within dashed outlines). The vertical scale was 35 fT/cm. The two dashed lines in the graph show the time points of 10 ms and 150 ms, respectively.

FIGURE 5. The RMS waveforms calculated from the 18-channels over the contralateral hemisphere in Patient 1 for the first (before sensory recovery) and second (after sensory recovery) recordings. The vertical scale was 35 fT/cm. The two dashed lines in each graph show the time points of 10 and 150 ms, respectively. The RMS amplitude in the first recording for the affected side was significantly smaller than that in the second recording. In the unaffected side, we observed highly similar shapes and amplitudes between the first and second recordings. Abbreviations: lt-side, Left side; rt-side, Right side; RMS, Root-mean-square; stim, Stimulation.

FIGURE 6. The RMS waveforms calculated from the 18-channels over the contralateral hemisphere in Patient 2 in the first (before sensory recovery) and second (after sensory recovery) recordings. The vertical scale was 25 fT/cm. The two dashed lines in each graph show the time points of 10 and 150 ms, respectively. The RMS amplitude in the first recording of the affected side was significantly smaller than that in the second recording. In the unaffected side, we observed highly similar shapes and

amplitudes between the first and second recordings. Abbreviations: lt-side, Left side; rt-side, Right side; RMS, Root-mean-square; stim, Stimulation.

FIGURE 7. The laterality index of aRMS for both patients in the first (before sensory recovery) and second (after sensory recovery) recordings. The area between the two dashed lines indicates the predetermined normal range. The normal range was -0.287 to 0.337, which was set to the average ± 3 SD of the laterality index obtained from 10 healthy volunteers. The laterality index was out of the normal range in both patients before sensory recovery, but was within the normal range in both patients after sensory recovery. Abbreviations: aRMS, Activated root-mean-square; Pt, Patient number.

Patient 1

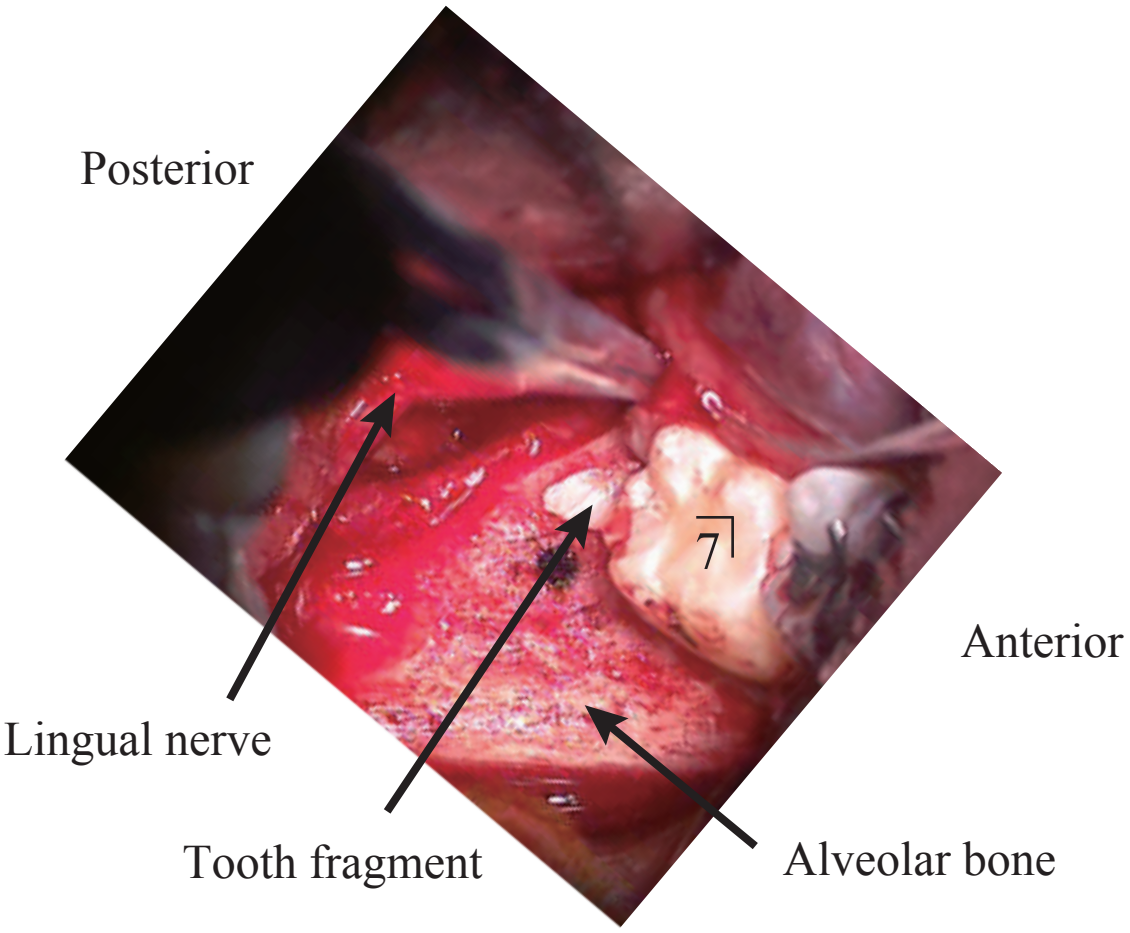
Posterior
7
Anterior
Lingual nerve
Tooth fragment
Alveolar bone

Patient 2

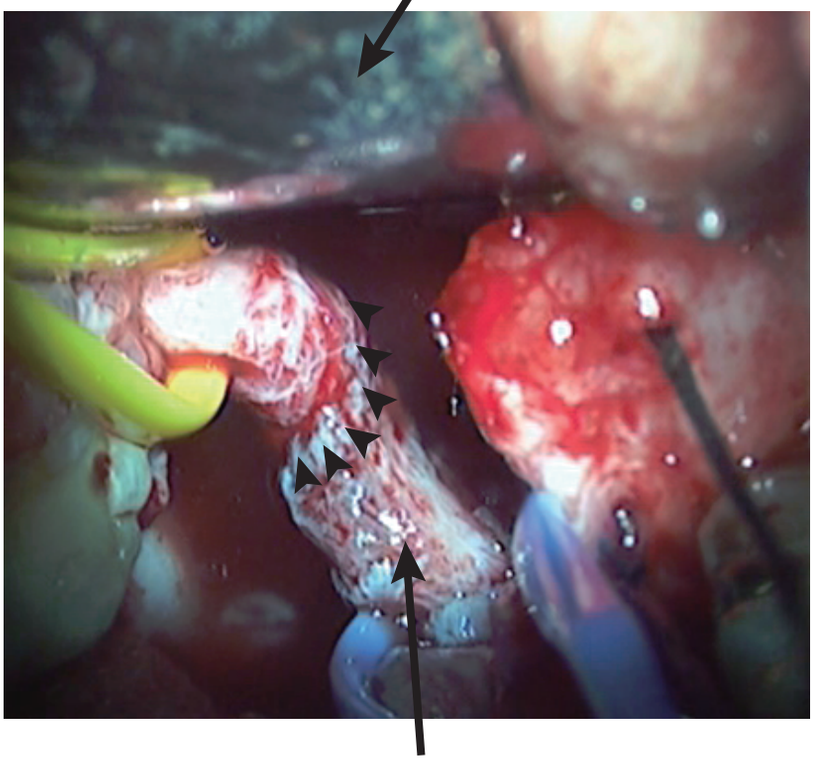

First measure of SEF waveforms following affected-side (right-side) stimulation in Patient 1

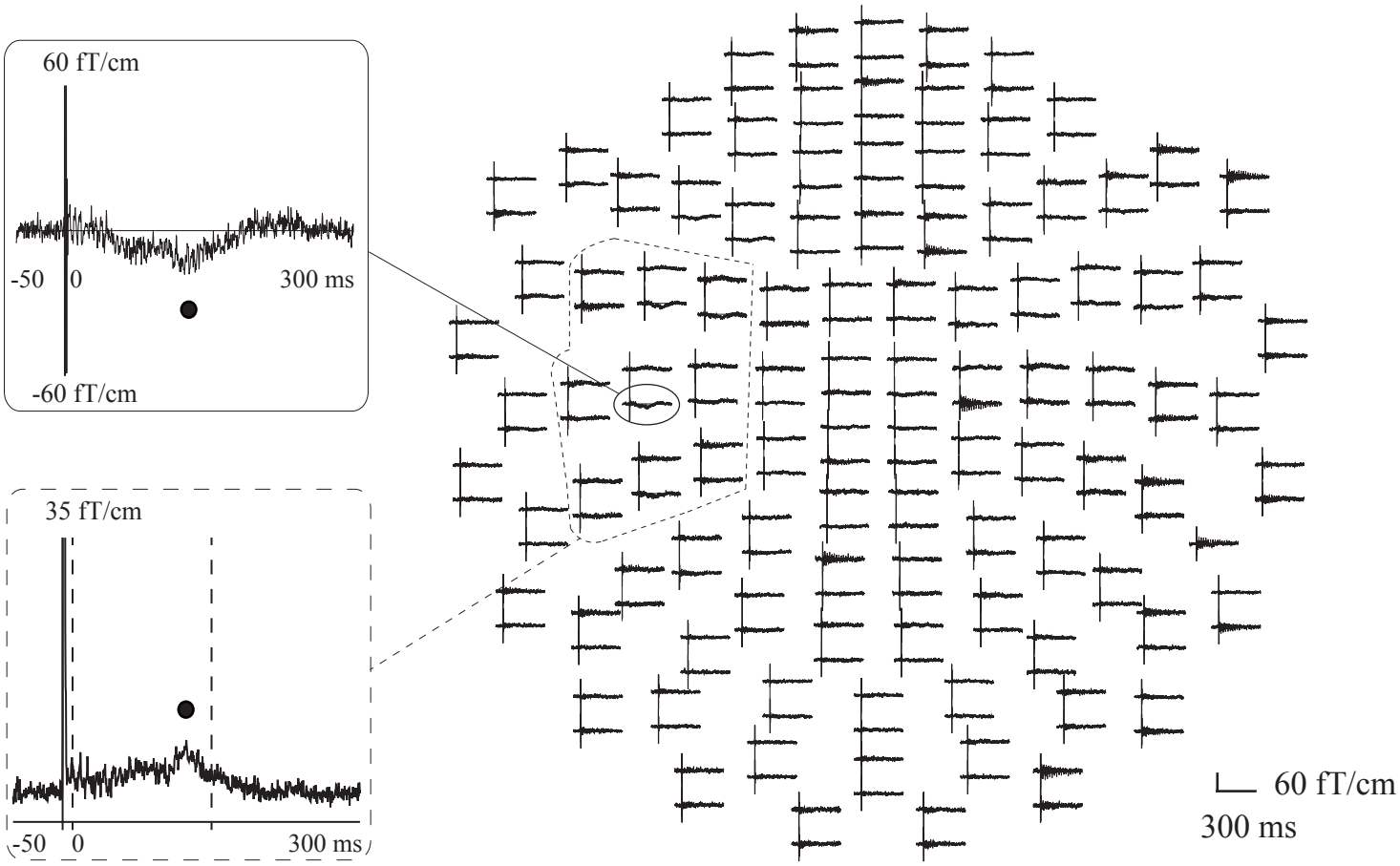

Second measure of SEF waveforms following affected-side (right-side) stimulation in Patient 1

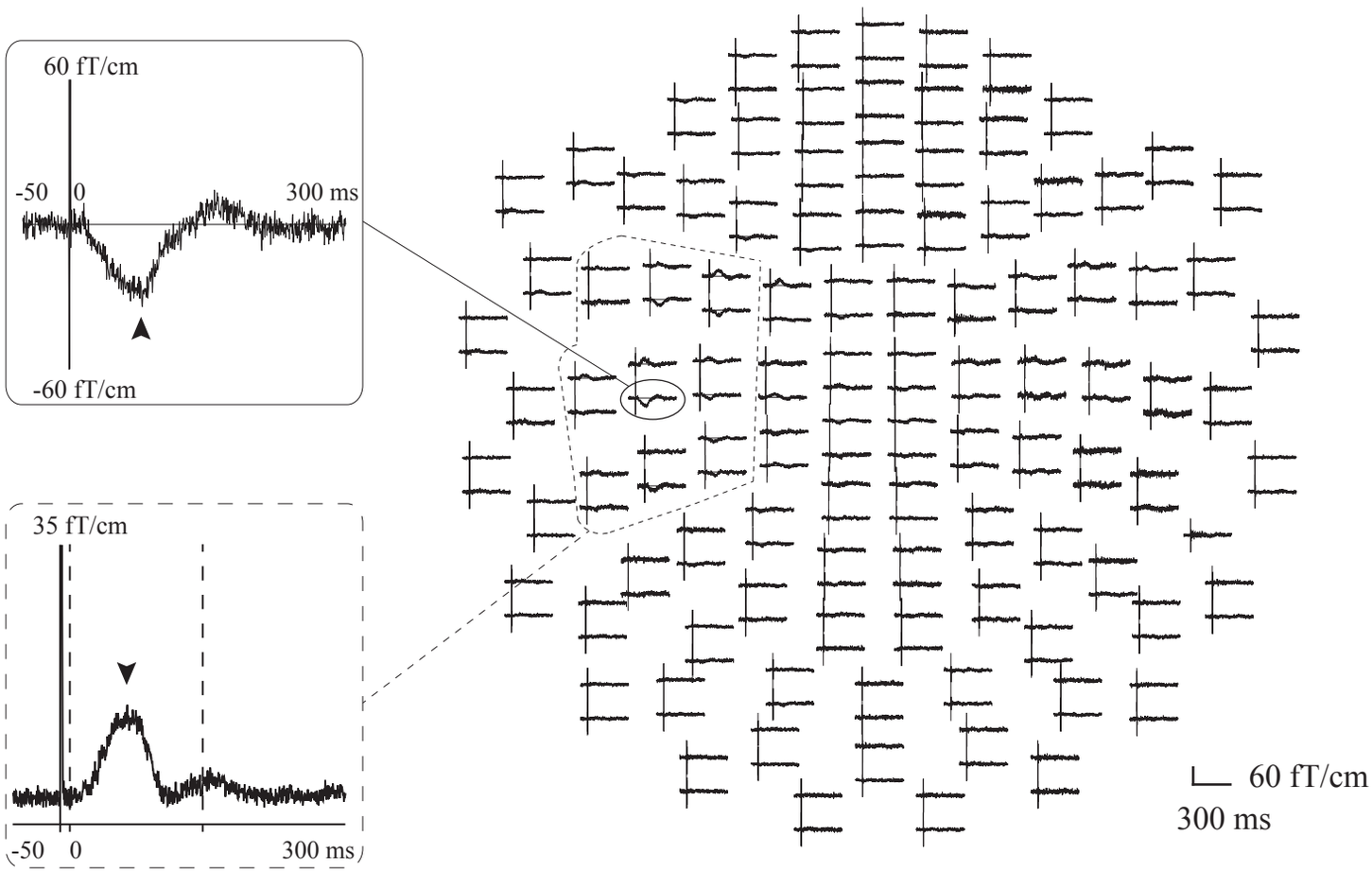

First measure

Affected-side (rt-side) stim.

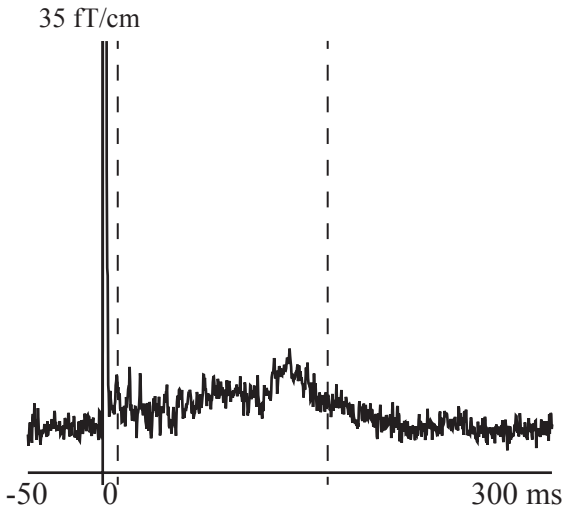

Unaffected-side (lt-side) stim.

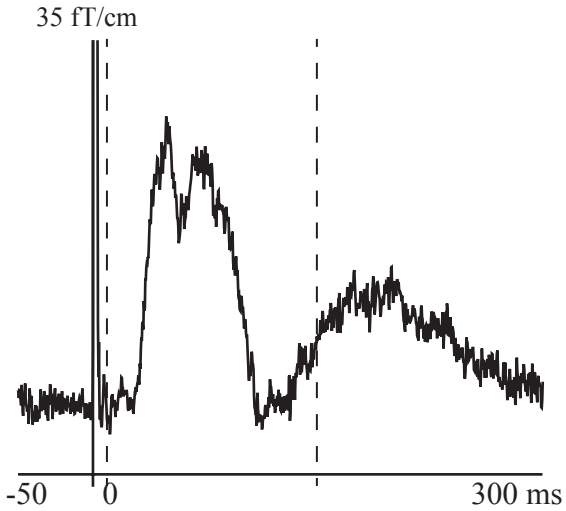

Second measure

Affected-side (rt-side) stim.

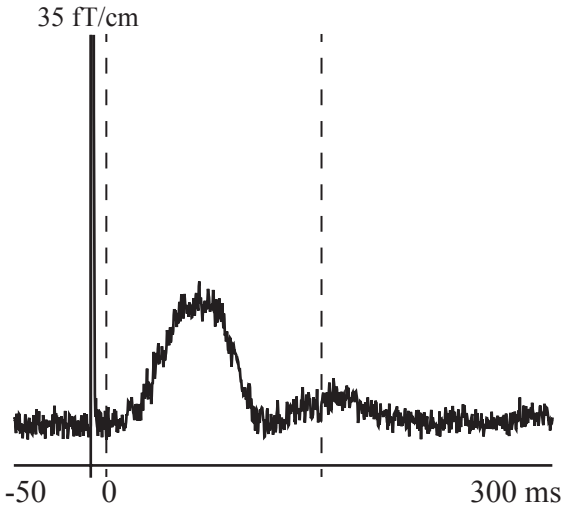

Unaffected-side (lt-side) stim.

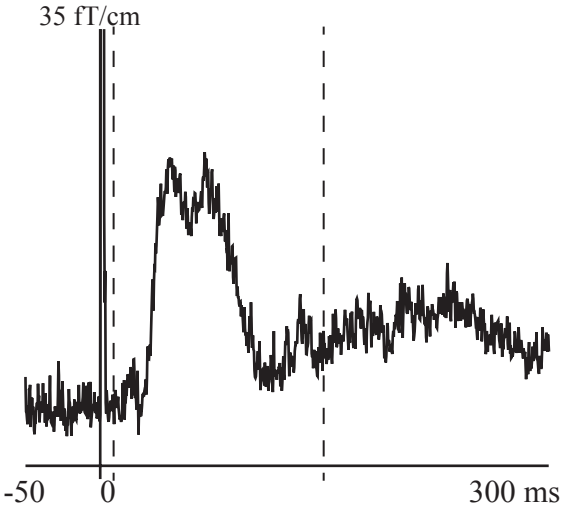

First measure

Affected-side (lt-side) stim.

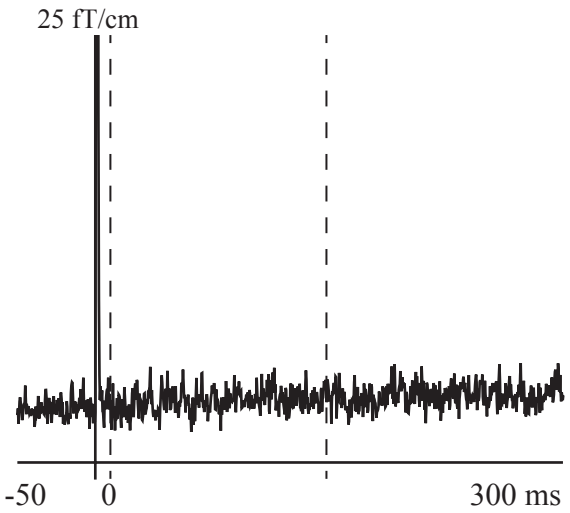

Unaffected-side (rt-side) stim.

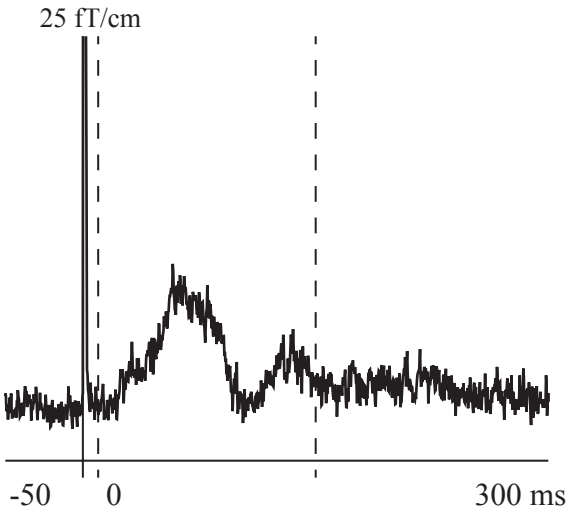

Second measure

Affected-side (lt-side) stim.

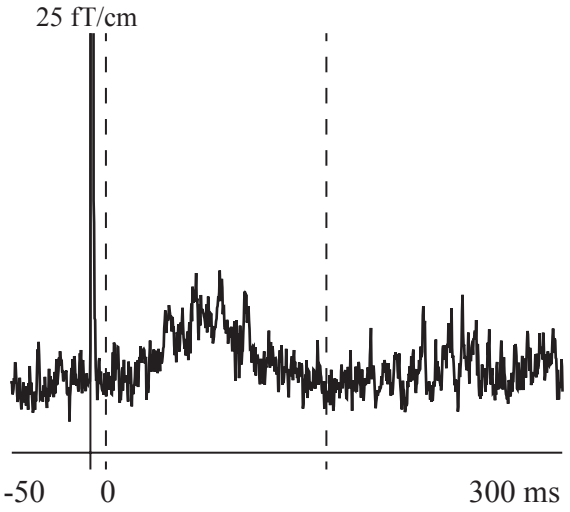

Unaffected-side (rt-side) stim.

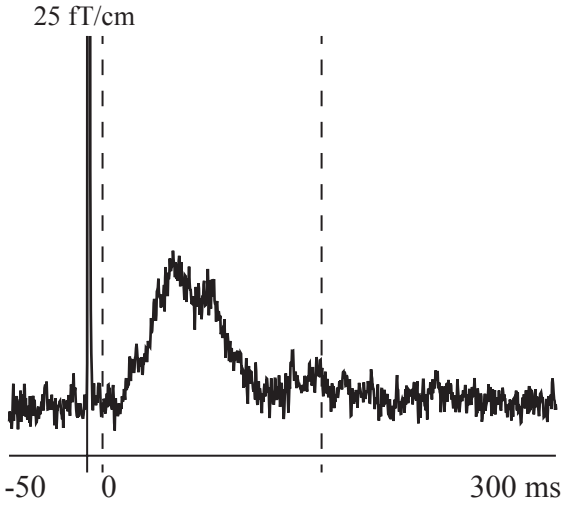
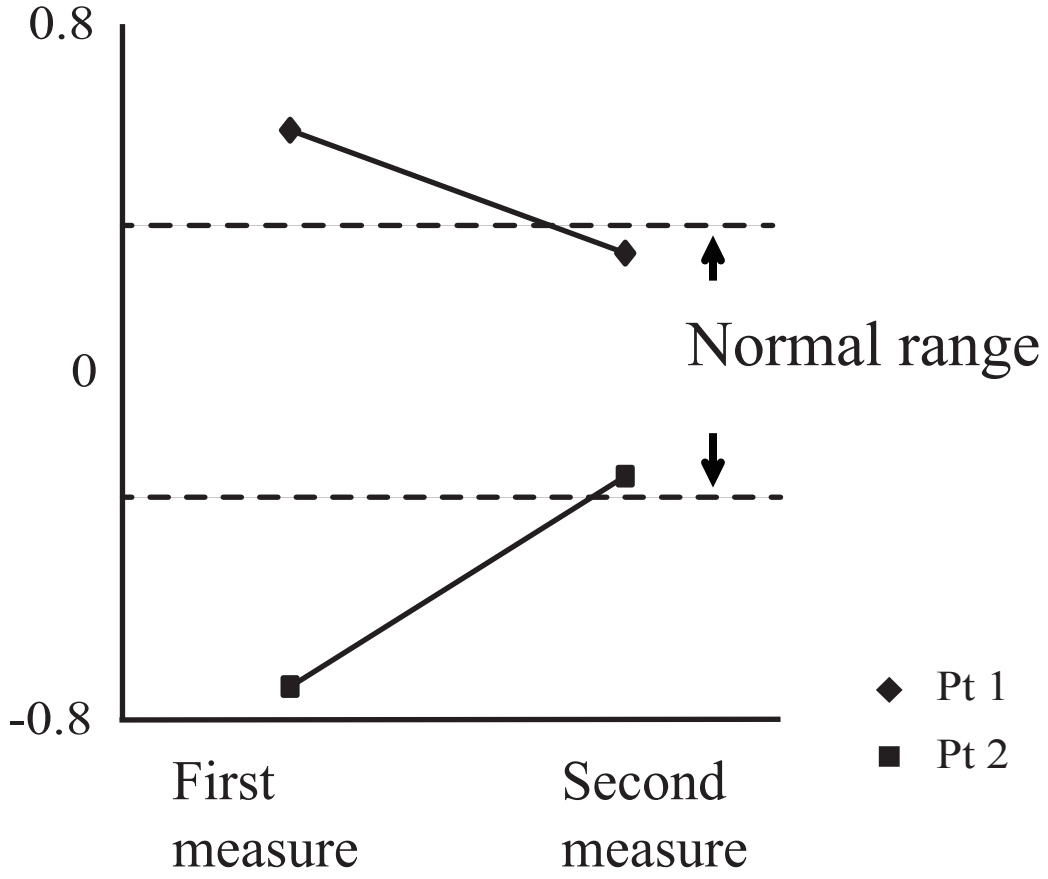
The laterality index of aRMS