



HOKKAIDO UNIVERSITY

Title	Modified 360-degree suture trabeculotomy combined with phacoemulsification and intraocular lens implantation for glaucoma and coexisting cataract
Author(s)	Shinmei, Yasuhiro; Kijima, Riki; Nitta, Takuya et al.
Citation	Journal of Cataract & Refractive Surgery, 42(11), 1634-1641 https://doi.org/10.1016/j.jcrs.2016.08.016
Issue Date	2016-11
Doc URL	https://hdl.handle.net/2115/67489
Rights	© 2016. This manuscript version is made available under the CC-BY-NC-ND 4.0 license http://creativecommons.org/licenses/by-nc-nd/4.0/
Rights(URL)	https://creativecommons.org/licenses/by-nc-nd/4.0/
Type	journal article
File Information	JCataractRefractSurg42_1634.pdf



Title: Modified 360-Degree Suture Trabeculotomy Combined with Phacoemulsification and Intraocular Lens Implantation for Glaucoma and Coexisting Cataract

Short Title: Suture Trabeculotomy Combined with Phacoemulsification

First Author: Yasuhiro Shinmei, M.D., Ph.D.

Order of Authors: Riki Kijima, M.D.¹⁾; Takuya Nitta, M.D., Ph.D.²⁾; Kan Ishijima, M.D.¹⁾; Takeshi Ohguchi, M.D., Ph.D.¹⁾; Shinki Chin, M.D., Ph.D.¹⁾; Susumu Ishida, M.D., Ph.D.¹⁾

Affiliation: 1) Department of Ophthalmology, Hokkaido University Graduate School of Medicine 2) Kaimeido Eye and Dental Clinic

Corresponding Author: Yasuhiro Shinmei, M.D., Ph.D.

Department of Ophthalmology

Hokkaido University Graduate School of Medicine

North 15, West 7, Kita-ku, Sapporo 060-8638, Japan

Tel.: +81-11-706-5944; Fax: +81-11-706-5948

E-mail: yshinmei@med.hokudai.ac.jp

Financial Disclosure: No author has a financial or proprietary interest in any material or method mentioned.

ABSTRACT

Purpose: To investigate the efficacy and safety of a modified 360-degree suture trabeculotomy combined with cataract surgery (ST-CS) technique in patients with glaucoma and coexisting cataract.

Setting: Hokkaido University Hospital, Sapporo, Japan.

Design: Retrospective case series.

Methods: Review of medical records of 46 patients with glaucoma receiving the ST-CS procedure. Another 46 age-matched patients with glaucoma who underwent the modified 360-degree suture trabeculotomy (ST) alone served as controls with the type of glaucoma adjusted.

Results: In either group, eyes were diagnosed with primary angle-closure glaucoma in 2 eyes, primary open-angle glaucoma in 24 eyes, exfoliation glaucoma in 4 eyes, uveitic glaucoma in 15 eyes, and steroid glaucoma in 1 eye. The mean preoperative IOP values were 27.2 ± 7.3 mmHg on 3.0 ± 0.5 medications in the ST-CS group and 27.7 ± 10.7 mmHg on 2.9 ± 0.6 medications in the ST group. Twelve months after surgery, the mean IOPs were 13.4 ± 3.7 mmHg on 0.8 ± 1.1 medications in the ST-CS group and 13.9 ± 4.1 mmHg on 0.6 ± 0.9 medications in the ST group. The success rates (<18 mmHg) of the ST-CS and ST groups were 89.1% and 93.5% at 12 months, respectively. The major complications included

transient IOP spikes (30.4% and 37.0%) and prolonged hyphema (10.9% and 6.5%) in the ST-CS and ST groups, respectively.

Conclusions: Our present data showed the equivalent effects of the ST-CS procedure compared with the ST surgery on postoperative safety and efficacy, suggesting this combined procedure as a valuable option for the initial surgical treatment of glaucoma with coexisting cataract.

INTRODUCTION

The purpose of trabeculotomy is to reduce the resistance of aqueous outflow via mechanical cleavage of the trabecular meshwork and the inner layer of Schlemm's canal. Trabeculotomy effectively reduces intraocular pressure (IOP) in adult patients with primary open-angle glaucoma (POAG),¹⁻⁴ and is associated with a lower rate of postoperative complications (corneal epithelial damage, bleb leaks, hypotony, flat anterior chambers, serous choroidal detachment, etc.) than trabeculectomy.^{1,4} Trabeculotomy alone largely fails to maintain the "adequately low" postoperative IOP (i.e., below 15 mmHg),⁴ whereas it can sufficiently lower IOP when combined with cataract surgery.⁵⁻⁸

Conventional trabeculotomy with metal trabeculotomes applies to a 120-degree incision of Schlemm's canal, whereas a 360-degree suture trabeculotomy technique opens the entire circumference of Schlemm's canal in a single surgical procedure.^{9,10} In terms of controlling IOP, the success rate of this procedure in primary congenital glaucoma was equivalent to that of standard trabeculotomy with metal trabeculotomes⁹ and superior to that of goniotomy¹⁰; however, the mean postoperative IOP was not described in these studies.^{9,10} Given that the inner wall of Schlemm's canal and the juxtacanalicular trabeculum are incised circumferentially up to 360 degrees, the resistance between the anterior chamber and Schlemm's canal is theorized to be negligible. Reasonably, the 360-degree suture

trabeculotomy would reduce IOP to a level close to the episcleral venous pressure in healthy eyes (i.e., 8-11 mmHg).¹¹

In our previous study, we investigated the effects of a modified 360-degree suture trabeculotomy technique (not combined with cataract surgery) on POAG and secondary open-angle glaucoma (SOAG) in adult patients.¹² After the modified 360-degree suture trabeculotomy, both the postoperative IOP and the number of anti-glaucoma medications were lower than that observed after trabeculotomy with metal trabeculotomes.¹² In addition, the success rate of the modified 360-degree suture trabeculotomy was higher than that of trabeculotomy with metal trabeculotomes.

Cataract and glaucoma are both primarily aging diseases that frequently coexist. Combining an anti-glaucoma procedure with cataract extraction is widely accepted as an appropriate surgical intervention for coexisting uncontrolled glaucoma and visually significant cataract.¹³⁻¹⁴ The IOP-lowering potency of trabeculotomy combined with phacoemulsification and intraocular lens (IOL) implantation has been substantiated by several studies.⁵⁻⁸ Moreover, the triple procedure surgery would be advantageous to patients with glaucoma and coexisting cataract in terms that it produces a better quality of vision than trabeculotomy alone. In this study, we evaluated the efficacy and safety of the modified 360-degree suture trabeculotomy combined with phacoemulsification and IOL implantation for the treatment of glaucoma with coexisting cataract.

PATIENTS AND METHODS

This study was a retrospective case series. A consecutive series of 49 patients underwent the modified 360-degree suture trabeculotomy¹² combined with phacoemulsification and IOL implantation for glaucoma with coexisting cataract at Hokkaido University Hospital from June 2007 to November 2014. One eye was randomly selected from each patient by the randomization tool (Microsoft Excel 2010), if both eyes met the inclusion criteria. In 46 of the 49 eyes (93.9%), we could successfully thread the suture around the entire circumference of Schlemm's canal. Three patients whom we failed to give a complete 360-degree cannulation (stopped at 180, 210, and 240 degrees) were excluded from this study to prevent any bias. These 46 eyes successfully receiving the modified 360-degree suture trabeculotomy (ST) combined with cataract surgery (CS) were enrolled as the ST-CS group. Another group of 46 eyes of 46 age-matched patients who underwent the 360-degree suture trabeculotomy alone during the same period were selected with the type of glaucoma being adjusted, and served as controls (i.e., the ST group) comprising 31 phakic and 15 pseudophakic eyes. In all the pseudophakic eyes, cataract surgery had been performed over 12 months before the 360-degree suture trabeculotomy. No patient had undergone any glaucoma surgery or laser treatment prior to either of the surgical interventions. In eyes with uveitic glaucoma (UG), inflammation was under control prior to either surgery. Eyes with neovascular glaucoma

were not included in each group. We excluded patients with a severely affected visual field defined as Stage 5 or 6 on the modified Aulhorn-Greve classification¹⁵ because the visual field could have led to loss of fixation due to postoperative transient IOP elevation.¹⁶ Written informed consent was obtained from all patients enrolled in this study. The institutional review board of Hokkaido University Hospital for clinical research approved this study.

Within 60 days prior to surgery, all enrollees completed baseline ophthalmic examinations as follows: history of glaucoma and medication use; best-corrected visual acuity, IOP and visual field measurements (30-2 Humphrey field analyzer; Humphrey Instruments, Munich, Germany); and slit-lamp biomicroscopic, gonioscopic and funduscopy observations. IOP was measured using an applanation tonometer. The preoperative IOP was measured with no use of systemic anti-glaucoma drugs such as hypertonic solutions or carbonic anhydrase inhibitors. Postoperative examinations were performed on a daily basis for 1 week. Further examinations were then performed during the follow-up visits at 1, 3, 6, 9, 12, 18, 24, 30 and 36 months after surgery.

Surgeries were performed under local peribulbar anesthesia in all cases. In the ST-CS group, phacoemulsification was performed and a foldable 6.0-mm AcrySof[®] IQ IOL (SN60WF; Alcon Laboratories, Fort Worth, TX) was implanted (Figure 1A) through a 2.4-mm clear corneal incision, followed by the modified 360-degree suture trabeculotomy procedure. In the ST group, only the modified 360-degree suture trabeculotomy was

performed as described in our previous paper.¹² In brief, we dissected a fornix-based conjunctival flap at the inferior-temporal position in order to create a double scleral flap. After the circumference of Schlemm's canal was cannulated with a 5-0 nylon suture (Figure 1B), both ends of the 5-0 nylon suture were pulled out from a clear corneal incision through anterior chamber (Figure 1C), resulting in a 360-degree incision of Schlemm's canal.

The surgery was considered a success if: (1) IOP was below 18 mmHg and (2) IOP was below 15 mmHg, both with similar or less dosage of anti-glaucoma medications. Transient elevations in IOP levels within the first postoperative month were excluded from the final determination of success or failure. A Kaplan–Meier life-table was used for calculation of the success rate of postoperative IOP control. Statistical comparisons of the success rate between two groups were made with the log-rank test. Values are expressed as the mean \pm standard deviation. Differences were considered statistically significant at $P < 0.05$.

RESULTS

The circumference of Schlemm's canal was incised without resistance in the 46 eyes of the ST-CS group. The mean follow-up periods were 30.1 ± 8.5 months (from 12 months to 36 months) in the ST-CS group and 32.1 ± 8.3 months in the ST group. Table 1 shows the preoperative characteristics of the patients enrolled in this study. The mean ages of

patients in ST-CS and ST groups were 68.7 ± 7.1 years and 65.6 ± 8.4 years, respectively. There was no significant difference in the rate of males to females, the age, the preoperative IOP levels, or the number of topical medications (Welsh's t test or the chi-square test, $P > 0.05$). The ratios of type of glaucoma were matched between the two groups. Two patients with primary angle-closure glaucoma (PACG) in the ST group had undergone phacoemulsification and IOL implantation more than a year prior to the ST surgery. Fifteen pseudophakic eyes were enrolled in the ST group. Postoperative ocular inflammation was under control in all cases with UG. The type of uveitis underlying the development of UG, though not matched between the ST-CS and ST groups due to the small sample size (15 eyes for both), was as follows: sarcoidosis in 8 eyes, Vogt-Koyanagi-Harada (VKH) disease, ulcerative colitis and scleritis in 1 eye for each, with the remaining 4 eyes from unknown causes in the ST-CS group; sarcoidosis in 3 eyes, varicella zoster virus-associated uveitis in 2 eyes, VKH disease, Behçet's disease, human T-cell lymphotropic virus-1-associated uveitis and Posner-Schlossman syndrome in 1 eye for each, with the remaining 6 eyes from unknown causes in the ST group.

Both of the ST-CS and ST surgeries effectively lowered mean IOP throughout the follow-up periods (Table 2). Twelve months after surgery, the mean postoperative IOPs in the ST-CS and ST groups were 13.4 ± 3.7 mmHg and 13.9 ± 4.1 mmHg, respectively. The IOP reduction rates in the ST-CS and ST groups were $52.7 \pm 24.3\%$ and $52.9 \pm 18.0\%$,

respectively, as compared with preoperative IOPs. The mean anti-glaucoma medications in the ST-CS and ST groups were 0.8 ± 1.1 and 0.6 ± 0.9 , respectively, at 12 months after surgery. The mean IOPs in the ST-CS and ST groups were 13.2 ± 3.7 mmHg with an average of 1.1 ± 1.1 medications and 13.3 ± 2.7 mmHg with an average of 0.9 ± 1.2 medications, respectively, at 24 months after surgery, and were 12.8 ± 2.8 mmHg with an average of 0.8 ± 1.0 medications and 13.1 ± 3.1 mmHg with an average of 1.2 ± 1.3 medications, respectively at 36 months after surgery (Table 2). There was no significant difference between the ST-CS and ST groups in either IOP changes or the number of medications during our observation period (Welch's t test, $P > 0.05$).

On the basis of the classification outlined in the Methods, the Kaplan-Meier life-table analysis showed that the success probabilities (<18 mmHg) after the ST-CS and ST surgeries were 89.1% and 93.5% at 12 to 24 months, and 82.0% and 83.0% at 36 months, respectively (Figure 2A). The success probabilities (<15 mmHg) after the ST-CS and ST surgeries were 63.0% and 67.4% at 12 months, 57.6% and 62.2% at 24 months, and 57.6% and 50.9% at 36 months, respectively (Figure 2B). These findings did not show any significant difference between the ST-CS and ST groups ($P = 0.781$ for <18 mmHg and $P = 0.867$ for <15 mmHg, log-rank test).

Next, in order to examine the potential impact of the type of glaucoma on the IOP outcome, we extracted and compared POAG eyes ($n = 24$) and UG eyes ($n = 15$) from

the total of 46 eyes in each of the ST-CS and ST groups (Figure 3). The remaining 3 types, i.e., PACG, exfoliation glaucoma (XG) and steroid glaucoma (SG) were not analyzed separately due to the limited number of eyes ($n = 2, 4$ and 1 , respectively). Importantly, no significant difference was found among the 4 groups (Figure 3A-D) in the postoperative IOP changes during our observation period ($P > 0.05$, ANOVA). With regard to the preoperative IOP values, there was a significant difference among the 4 groups ($P = 2.7E-05$, ANOVA); however, no significant difference between the ST-CS and ST groups was found in POAG eyes (25.6 ± 12.5 mmHg vs. 22.5 ± 5.4 mmHg) or UG eyes (32.4 ± 9.4 mmHg vs. 34.2 ± 12.6 mmHg) ($P > 0.05$ for both, Tukey-Kramer multiple comparison test). Differences were detected only between POAG and UG eyes, showing the significantly higher preoperative IOP values of UG eyes than POAG eyes independently of the surgical procedures ($P = 0.0353$ and 0.0020 for ST-CS in UG vs. ST-CS and ST in POAG, $P = 0.0050$ and 0.0002 for ST in UG vs. ST-CS and ST in POAG, respectively; Tukey-Kramer multiple comparison test).

Kaplan-Meier life-table analyses separately for POAG and UG eyes were shown in Figure 4. As is the case with Figure 2 containing all the enrolled eyes, there were no significant differences between the ST-CS and ST surgeries in POAG (Figure 4A) as well as in UG (Figure 4B) ($P = 0.994$ and 0.475 , respectively; log-rank test), given that the surgery

was considered a success if IOP was below 18 mmHg. Similarly, there was no significant difference if the other definition of success (<15mmHg) was applied (data not shown).

The complications related to the ST-CS and ST surgeries that were observed in this study are listed in Table 3. Eyes undergoing the ST-CS and ST procedures showed early perforation into the anterior chamber in 1 eye (2.2%) and no eye (0%), prolonged hyphema requiring surgical removal in 5 eyes (10.9%) and 3 eyes (6.5%), transient IOP spikes (>30mmHg) in 14 eyes (30.4%) and 17 eyes (37%), and fibrin exudation in 3 eyes (6.5%) and 2 eyes (4.3%), respectively. When IOPs were elevated above 30 mmHg, patients were treated with oral acetazolamide or systemic mannitol. In most of the cases, their IOPs reduced within a week. If hyphema was prolonged over two weeks, we surgically washed it out of the anterior chamber. After the removal of blood from the anterior chamber of eyes with hyphema-related IOP spikes, the IOP levels decreased under control. There was no significant difference in the incidence of these complications between ST-CS and ST groups (Chi-square test).

There was one case complicated by vitreous hemorrhage in the ST group (2.2%), which was thought to stem from hyphema and disappeared within a month. In 2 cases (4.3%) receiving the ST-CS surgery, hyphema invaded into the space between the IOL and the posterior capsule (Figure 5), requiring YAG laser capsulotomy. In none of the eyes did we encounter Descemet's membrane detachment, shallow anterior chamber, choroidal

detachment, malignant glaucoma, or CS-related complications (posterior capsule rupture, vitreous loss, etc.). None of the eyes developed a conjunctival bleb.

DISCUSSION

Non-filtering anti-glaucoma procedures such as trabeculotomy⁸ and canaloplasty,¹⁷ in which a bleb is not produced, could be more effective when combined with cataract surgery than those done alone. The original version of the 360-degree suture trabeculotomy is an advanced technique that opens the entire circumference of Schlemm's canal during a single surgical procedure,⁹ unlike a trabeculotomy with metal trabeculotomes where the incision of Schlemm's canal is only 120 degrees. Our modified version of the 360-degree suture trabeculotomy, after which the mean postoperative IOP value was 13.1 ± 2.9 mmHg at 12 months, was more effective than trabeculotomy with metal trabeculotomes for adult patients with POAG and SOAG.¹² Recently, Hepşen et al. reported that the modified 360-degree suture trabeculotomy was also effective for XG eyes, and the mean postoperative IOP value was 12.9 ± 2.7 mmHg at 6 months after surgery.¹⁸ They performed the ST-CS technique in 6 patients with XG, achieving favorable outcomes similar or equivalent to the ST surgery alone in 15 patients with exfoliation glaucoma, in accordance with our present data.

In the current study enrolling 92 patients with various types of glaucoma (PACG, POAG, XG, UG and SG), we retrospectively evaluated our surgical results in

comparison between the combined ST-CS and the single ST procedures by matching patients' age and the type of glaucoma, and revealed that the ST-CS procedure reduced IOP as efficiently as the ST surgery alone. Throughout our observation period up to 36 months, postoperative IOP changes and the number of anti-glaucoma medications were not found to be significantly lower in the ST-CS procedure than in the ST technique. The success rate (89.1%) of the combined ST-CS procedure was also similar to that of the single ST procedure (93.5%) according to the definition of success ($<18\text{mmHg}$). Based on the other criterion of success ($<15\text{mmHg}$), however, the success rates decreased to 63.0% and 67.4% in the combined and single procedures, respectively, suggesting that ST-CS technique may not be suitable for patients with end-stage optic disc cupping who are in need of much lower IOP.

To investigate whether the type of glaucoma could affect the IOP outcomes, we extracted the major two subgroups, POAG and UG eyes, for comparison between the ST-CS and ST procedures. Although the preoperative IOP values were significantly higher in UG eyes than in POAG eyes, the postoperative IOP values were equivalent between the two diseases independently of the surgical procedures. Moreover, Kaplan-Meier life-table analysis demonstrated no significant difference in the success rate between the ST-CS and ST surgeries in either POAG or UG cases, as similarly shown in all the enrolled cases with different etiologies. These results suggest the efficacy of the ST-CS technique for UG patients as well as in POAG patients, when uveitis is fairly controlled.

In this study, there were no serious complications such as shallow anterior chamber, choroidal detachment, aqueous misdirection, infection, or wound leaks, as seen after trabeculectomy with mitomycin C. There was no case of local descemetolysis in our present study or in our previous study with the ST technique alone. Since the suture's force is focused only on the cutting edge, our modified technique would make it possible to correctly incise the Schlemm's canal without any resistance.

By contrast, hyphema occurred in all eyes and transient IOP elevations above 30 mmHg were seen in 14 eyes (30.4%) and in 17 eyes (37.4%) in the ST-CS and ST groups, respectively. The complete incision of Schlemm's canal up to 360 degrees may induce more massive and persisting hyphema than conventional trabeculectomy with a 120-degree incision. We successfully treated such cases with IOP spikes due to massive hyphema, in consistence with a previous report showing the effectiveness of washing out prolonged hyphema to lower the related IOP spikes¹⁹. Captured hemorrhage between the IOL and the posterior capsule, observed in 2 cases receiving the ST-CS surgery is not a frequent complication, but a potential problem mostly specific to the procedure. In order to reduce this risk, we should create an anterior capsulotomy large enough to drain the captured hemorrhage. Since the prolonged massive hyphema, including the clot stuck inside the bag, causes temporary visual loss, patients with poor vision in the fellow eye should be carefully selected for this surgery.

Our results revealed the efficacy and safety of the ST-CS procedure equivalent to those of the ST technique for the treatment of glaucoma. This combined procedure provides a practicable choice in cases of glaucoma with coexisting cataract. Inherent limitations of the present study include its retrospective data collection from small sample population followed up with the short period. The results of this study warrant future randomized trials with a larger sample size to further explore the long-term effects of this surgical intervention on various kinds of glaucoma.

WHAT WAS KNOWN

The modified 360-degree trabeculotomy was shown to be safe and effective in both POAG and SOAG patients. The mean postoperative IOP was significantly lower than that found after trabeculotomy with metal trabeculotomes.

WHAT THIS PAPER ADDS

Our results revealed the efficacy and safety of the modified 360-degree trabeculotomy combined with phacoemulsification and IOL implantation equivalent to those of the modified 360-degree trabeculotomy alone for the treatment of glaucoma. This combined procedure was feasible for cases of glaucoma with coexisting cataract.

REFERENCES

1. Chihara E, Nishida A, Kodo M, et al., Trabeculotomy ab externo: an alternative treatment in adult patients with primary open-angle glaucoma, *Ophthalmic Surg*, 1993; 24: 735-739
2. Tanihara H, Negi A, Akimoto M and Nagata M, Long-term surgical results of combined trabeculotomy ab externo and cataract extraction, *Ophthalmic Surg*, 1995; 26: 316-324
3. Tanihara H, Negi A, Akimoto M, et al., Surgical effects of trabeculotomy ab externo on adult eyes with primary open angle glaucoma and pseudoexfoliation syndrome, *Arch Ophthalmol*, 1993; 111: 1653-1661
4. Wada Y, Nakatsu A and Kondo T, Long-term results of trabeculotomy ab externo, *Ophthalmic Surg*, 1994; 25: 317-320
5. Gimbel HV and Meyer D, Small incision trabeculotomy combined with phacoemulsification and intraocular lens implantation, *J Cataract Refract Surg*, 1993, 19, 92-96
6. Hoffmann E, Schwenn O, Karallus M, Krummenauer F, Grehn F and Pfeiffer N, Long-term results of cataract surgery combined with trabeculotomy, *Graefes Arch Clin Exp Ophthalmol*, 2002, 240, 2-6

7. Schwenn O and Grehn F, Cataract extraction combined with trabeculotomy, *Ger J Ophthalmol*, 1995; 4: 16-20
8. Mizoguchi T, Kuroda S, Terauchi H and Nagata M, Trabeculotomy combined with phacoemulsification and implantation of intraocular lens for primary open-angle glaucoma, *Semin Ophthalmol*, 2001; 16: 162-167
9. Beck AD and Lynch MG, 360 degrees trabeculotomy for primary congenital glaucoma, *Arch Ophthalmol*, 1995; 113: 1200-1202
10. Mendicino ME, Lynch MG, Drack A, et al., Long-term surgical and visual outcomes in primary congenital glaucoma: 360 degrees trabeculotomy versus goniotomy, *J Aapos*, 2000; 4: 205-210
11. Sit AJ, McLaren JW. Measurement of episcleral venous pressure. *Exp Eye Res*. 2011; 93:291-298
12. Chin S, Nitta T, Shinmei Y, Aoyagi M, Nitta A, Ohno S, Ishida S, Yoshida K. Reduction of Intraocular Pressure Using a Modified 360-degree Suture Trabeculotomy Technique in Primary and Secondary Open-Angle Glaucoma: A Pilot Study. *J Glaucoma*. 2012 Aug;21(6):401-407
13. Casson RJ, Salmon JF. Combined surgery in the treatment of patients with cataract and primary open-angle glaucoma. *J Cataract Refract Surg*. 2001; 27: 1854-1863

14. Augustinus CJ, Zeyen T. The effect of phacoemulsification and combined phaco/glaucoma procedures on the intraocular pressure in open-angle glaucoma. A review of the literature. *Bull Soc Belge Ophtalmol.* 2012; 320:51-66
15. Greve EL, Langerhost CT, Van den Berg TJ. Perimetry and other visual function tests in glaucoma. In: Cairns JE, ed. *Glaucoma 1* London, England Grune & Stratton; 1986
16. Mizoguchi T, Nagata M, Matsumura M, Kuroda S, Terauchi H and Tanihara H, Surgical effects of combined trabeculotomy and sinusotomy compared to trabeculotomy alone, *Acta Ophthalmol Scand*, 2000; 78: 191-195
17. Bull H, von Wolff K, Körber N, Tetz M. Three-year canaloplasty outcomes for the treatment of open-angle glaucoma: European study results. *Graefes Arch Clin Exp Ophthalmol.* 2011; 249:1537-1545
18. Hepşen İF, Güler E, Kumova D, Tenlik A, Kulak AE, Hülya Yazıcı E, Dişli G. Efficacy of Modified 360-degree Suture Trabeculotomy for Pseudoexfoliation Glaucoma. *J Glaucoma.* 2016;25:e29-34
19. Inatani M, Tanihara H, Muto T, Honjo M, Okazaki K, Kido N, Honda Y. Transient intraocular pressure elevation after trabeculotomy and its occurrence with phacoemulsification and intraocular lens implantation. *Jpn J Ophthalmol.* 2001; 45: 288-292

FIGURE LEGENDS

Figure 1. The procedure of the modified 360-degree suture trabeculotomy with cataract surgery.

A. Phacoemulsification was performed through a 2.4 mm clear corneal incision at an 11 o'clock position, followed by IOL implantation.

B. After a conjunctival flap and a 4×4-mm scleral double flap were made, the Schlemm's canal was identified and cannulated with a 5-0 nylon suture. Arrows indicate the tip of a 5-0 nylon suture that just passed through the whole circumference of Schlemm's canal clockwise.

C. A 5-0 nylon suture incised the two-thirds of Schlemm's canal. Arrows indicates cutting points made by the suture. When the suture was pulled out from the anterior chamber, Schlemm's canal was completely opened.

Figure 2. Kaplan-Meier survival curve of the ST-CS and ST surgeries.

A. Survival criterion: <18mmHg. **B.** Survival criterion: <15mmHg.

The solid and dashed lines show the success rates of the ST-CS and ST procedures, respectively. *P*-values by the log-rank test.

ST-CS: the modified 360-degree suture trabeculotomy with cataract surgery. ST: the modified 360-degree suture trabeculotomy alone.

Figure 3. Time course of postoperative IOP changes in POAG (**A, B**) and UG (**C, D**) eyes after the ST-CS (**A, C**) and ST (**B, D**) surgeries.

IOP is presented as the mean (○) with SD (vertical bars).

ST-CS: the modified 360-degree suture trabeculotomy with cataract surgery. ST: the modified 360-degree suture trabeculotomy alone. POAG: primary open-angle glaucoma. UG: uveitic glaucoma.

Figure 4. Kaplan-Meier survival curve of the ST-CS and ST surgeries for POAG (**A**) and UG (**B**) eyes.

The solid and dashed lines show the success rates of the ST-CS and ST procedures, respectively. Survival criterion: <18mmHg. *P*-values by the log-rank test.

ST-CS: the modified 360-degree suture trabeculotomy with cataract surgery. ST: the modified 360-degree suture trabeculotomy alone. POAG: primary open-angle glaucoma. UG: uveitic glaucoma.

Figure 5. Massive hemorrhage captured between the IOL and the posterior capsule of the lens. Arrows indicate a niveau formation behind the IOL in the bag.

Table1. Baseline characteristics of enrolled patients

Characteristics	ST-CS group (46 eyes)	ST group (46 eyes)	<i>P-value</i>
Sex (males/females)	21/25	22/24	0.834
Age (years) at the time of surgery	68.7 ± 7.1	65.6 ± 8.4	0.060
Preoperative intraocular pressure (mmHg)	27.2 ± 7.3	27.7 ± 10.7	0.813
Preoperative antiglaucoma medications (drugs)	3.0 ± 0.5	2.9 ± 0.6	0.280
Lens status (phakic/pseudophakic eyes)	46/0*	31/15	2.3E-05
Type of glaucoma (eyes)			
PACG: Primary angle-closure glaucoma	2	2	
POAG: Primary open-angle glaucoma	24	24	
XG: Exfoliation glaucoma	4	4	
UG: Uveitic glaucoma	15	15	
SG: Steroid glaucoma	1	1	

ST-CS: modified 360-degree suture trabeculotomy with cataract surgery. ST: modified 360-degree suture trabeculotomy alone.

*P-value (Welch's t-test, Chi-square test), * P < 0.05.*

Table 2. Postoperative IOP in the ST-CS and ST groups

Follow-up (months)	ST-CS group			ST group		
	IOP (mmHg)	No. of eyes	Medications	IOP (mmHg)	No. of eyes	Medications
1	12.7 ± 4.0	46	0.4 ± 0.7	14.2 ± 3.7	46	0.7 ± 1.1
3	13.5 ± 3.4	44	0.4 ± 0.8	13.8 ± 4.4	45	0.5 ± 0.8
6	13.3 ± 3.4	46	0.5 ± 1.0	13.0 ± 3.6	46	0.5 ± 0.9
9	13.9 ± 3.5	45	0.5 ± 0.9	13.2 ± 3.4	45	0.5 ± 0.9
12	13.4 ± 3.7	46	0.8 ± 1.1	13.9 ± 4.1	46	0.6 ± 0.9
18	13.2 ± 3.6	42	0.8 ± 1.1	12.2 ± 3.9	40	0.6 ± 1.0
24	13.2 ± 3.7	37	1.1 ± 1.1	13.3 ± 2.7	39	0.9 ± 1.2
30	13.4 ± 3.1	31	0.8 ± 1.0	12.3 ± 3.1	39	1.0 ± 1.2
36	12.8 ± 2.8	29	0.8 ± 1.0	13.1 ± 3.1	36	1.2 ± 1.3

ST-CS: modified 360-degree suture trabeculectomy with cataract surgery. ST: modified 360-degree suture trabeculectomy alone.

IOP: intraocular pressure.

Medications: the number of different anti-glaucoma drugs applied regardless of their concentration and frequency.

Table 3. Incidence of potential complications

Complications	ST-CS group	ST group	<i>P-value</i>
	eyes (%) N=46	eyes (%) N=46	
Early perforation	1 (2.2%)	0	0.315
Descemet's membrane detachment	0	0	
Prolonged hyphema	5 (10.9%)	3 (6.5%)	0.479
IOP spikes (>30mmHg)	14 (30.4%)	17 (37.0%)	0.508
Fibrin exudation	3 (6.5%)	2 (4.3%)	0.646
Vitreous hemorrhage	0	1 (2.2%)	0.315
Captured hemorrhage between posterior capsule and IOL	2 (4.3%)	0	0.153
Shallow anterior chamber	0	0	
Choroidal detachment	0	0	
Malignant glaucoma	0	0	

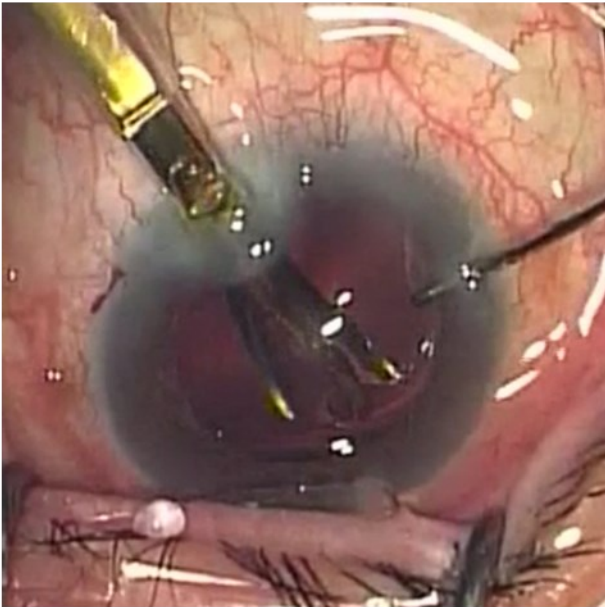
ST-CS: modified 360-degree suture trabeculectomy with cataract surgery. ST: modified 360-degree suture trabeculectomy alone.

IOP: intraocular pressure. IOL: intraocular lens.

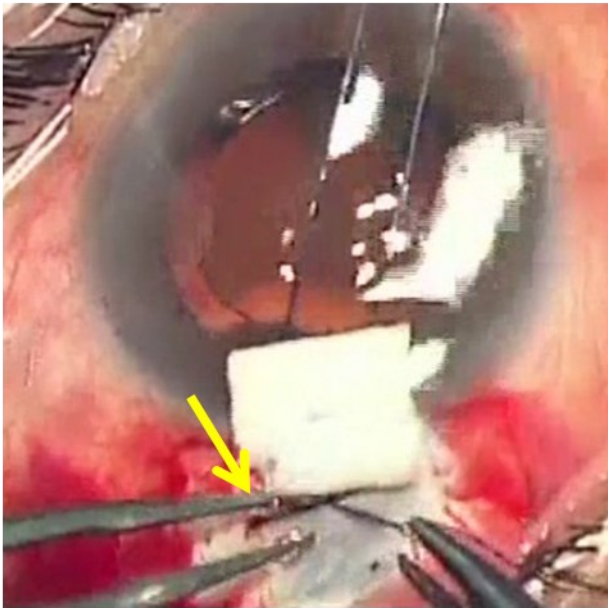
P-value (Chi-square test).

Figure 1.

A.



B.



C.

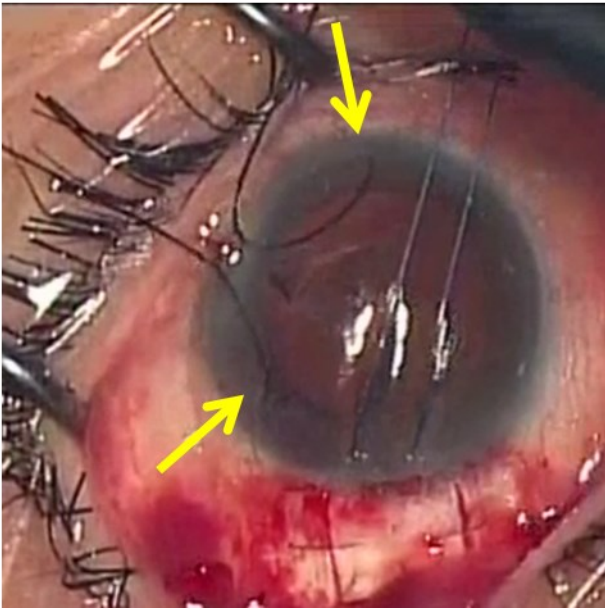
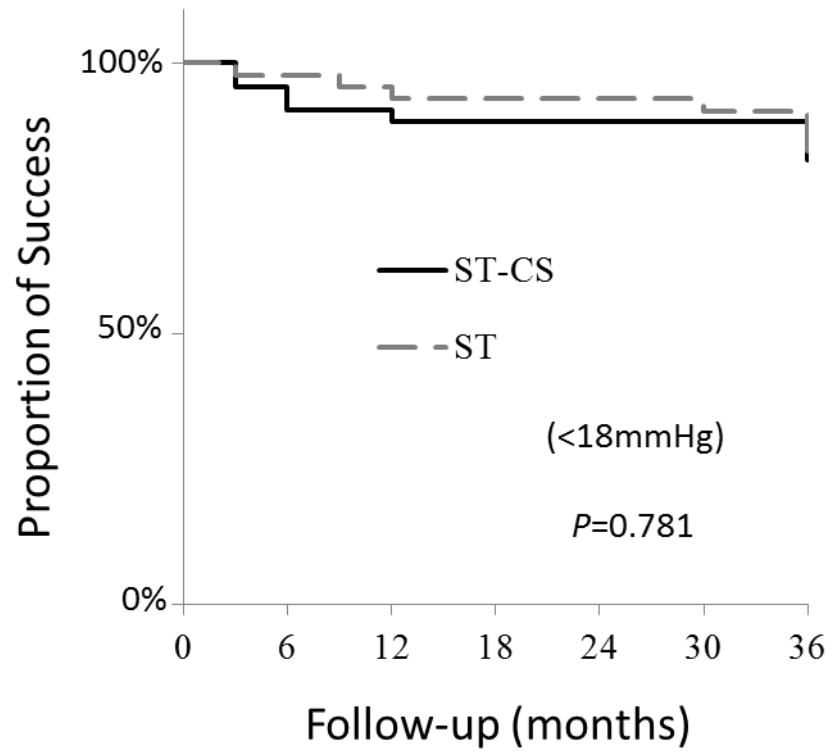


Figure 2.

A.



B.

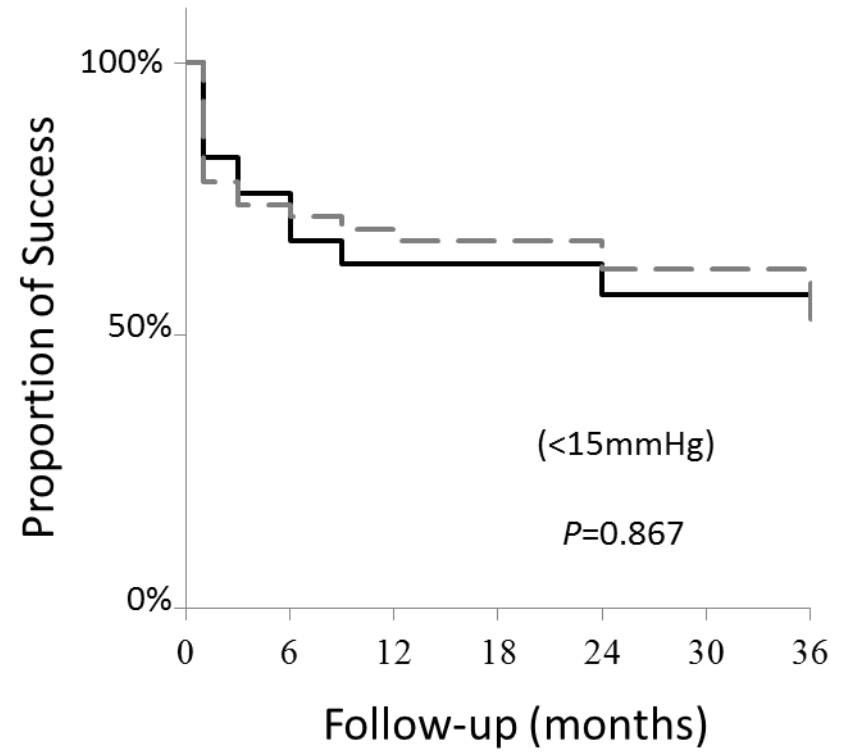
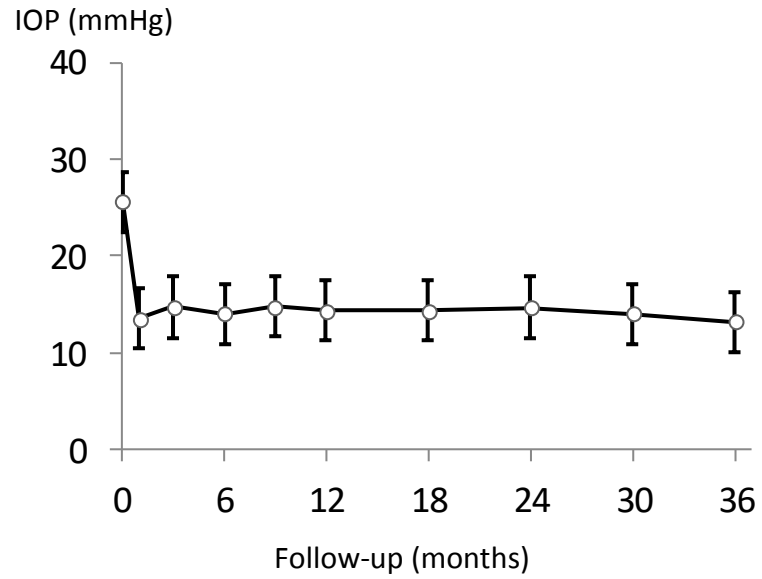
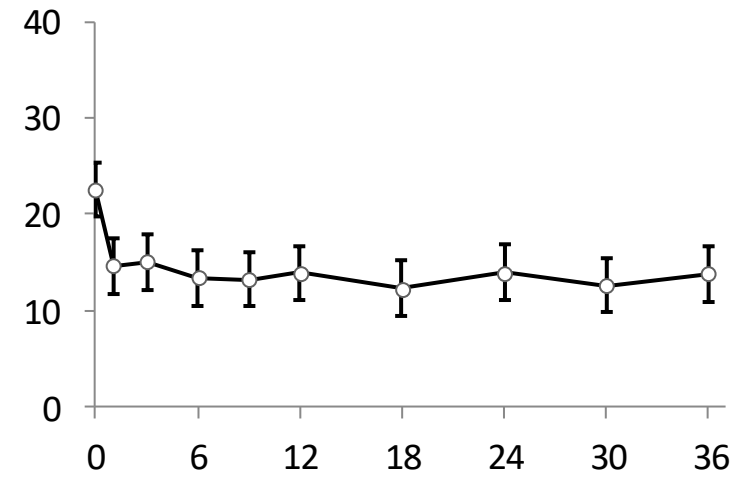


Figure 3.

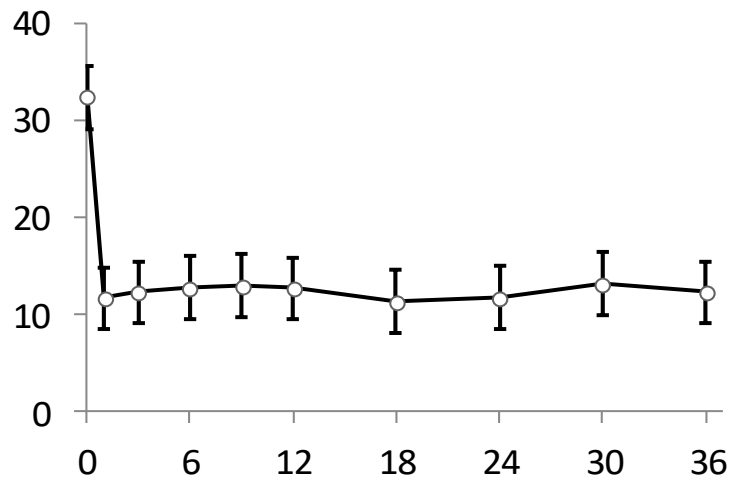
A. ST-CS in POAG (n=24)



B. ST in POAG (n=24)



C. ST-CS in UG (n=15)



D. ST in UG (n=15)

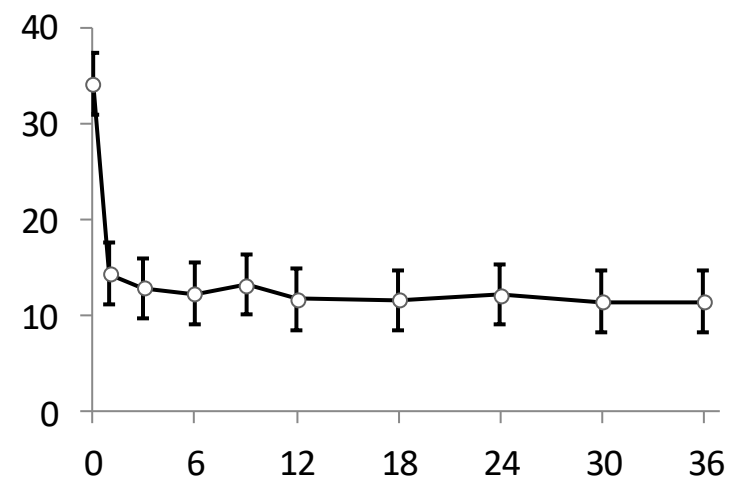
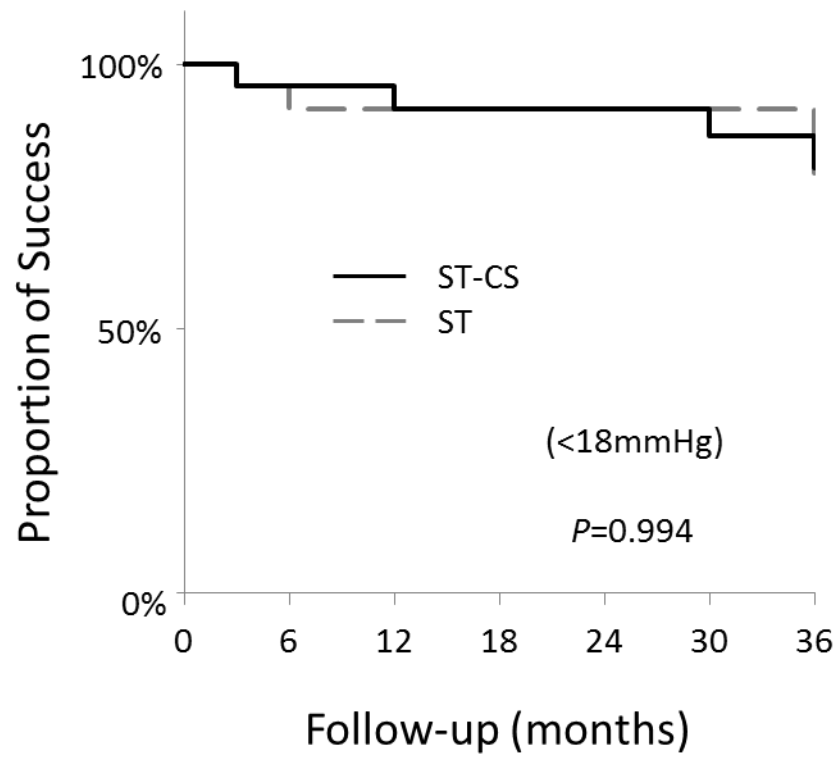


Figure 4.

A. POAG



B. UG

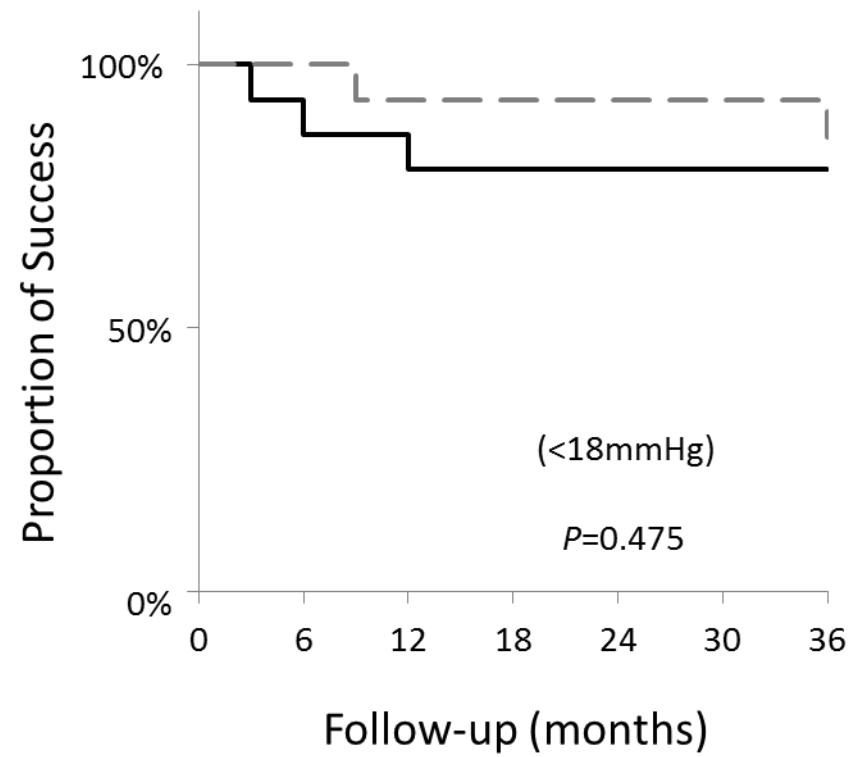


Figure 5.

