HOKKAIDO UNIVERSITY

Title	Usefulness of the octreotide test in Japanese patients for predicting the presence/absence of somatostatin receptor 2 expression in insulinomas
Author(s)	Nakamura, Akinobu; Mitsuhashi, Tomoko; Takano, Yoshinari et al.
Citation	Endocrine Journal, 63(2), 135-142 https://doi.org/10.1507/endocrj.EJ15-0371
Issue Date	2016-02
Doc URL	https://hdl.handle.net/2115/68409
Type	journal article
File Information	63_EJ15-0371.pdf

Hokkaido University Collection of Scholarly and Academic Papers : HUSCAP

Endocrine Journal 2016, **63** (2), 135-142

ORIGINAL

Usefulness of the octreotide test in Japanese patients for predicting the presence/absence of somatostatin receptor 2 expression in insulinomas

Akinobu Nakamura[1)], Tomoko Mitsuhashi[2)], Yoshinari Takano[1)], Hideaki Miyoshi[1)], Hiraku Kameda[1)], Hiroshi Nomoto[1)], So Nagai[1)], Yutaka Hatanaka[2)], Chikara Shimizu[3)], Yasuo Terauchi[4)] and Tatsuya Atsumi[1)]

[1)] *Division of Rheumatology, Endocrinology and Nephrology, Hokkaido University Graduate School of Medicine, Sapporo, Japan*
[2)] *Department of Surgical Pathology, Hokkaido University Hospital, Sapporo, Japan*
[3)] *Division of Laboratory and Transfusion Medicine, Hokkaido University Hospital, Sapporo, Japan*
[4)] *Department of Endocrinology and Metabolism, Graduate School of Medicine, Yokohama City University, Yokohama, Japan*

Abstract. We investigated the relationship between the results of the octreotide test and somatostatin receptor (SSTR) 2 expression in insulinoma patients, to evaluate the usefulness of this test for predicting SSTR2 expression in insulinomas in Japanese patients. Five females and one male were included in the study. All patients underwent the octreotide test before the surgery carried out to resect the tumor, and histopathological examination of the resected tumor was performed by a single experienced pathologist. SSTR2 expression was evaluated by the SSTR2 immunohistochemistry scoring system. Insulinoma was clinically diagnosed and surgically resected in all six patients. In the octreotide test, suppression of insulin secretion was sufficient after loading in patients 1-4 and 6. In patient 5, however, the suppression of insulin secretion was insufficient, which resulted in severe hypoglycemia with endogenous relative hyperinsulinemia after the octreotide loading. The histopathological findings revealed SSTR2 expression in the insulinomas of patients 1-4 and 6, but not in the insulinoma of patient 5. In conclusion, improvement of hyperinsulinemic hypoglycemia by octreotide in Japanese insulinoma patients was associated with SSTR2 expression in the tumor. Our results suggest that the octreotide test could be useful for predicting SSTR2 expression in the tumor.

Key words: Insulinoma, Octreotide, Somatostatin receptor

INSULINOMAS occur in approximately 0.7-4 individuals per million population per year, making it the most commonly occurring functional pancreatic neuroendocrine tumor [1]. Patients with insulinomas suffer from severe hypoglycemia episodes due to the inappropriately increased circulating serum insulin levels. Insulinomas are usually single, small, well- circumscribed, benign, sporadic, and intrapancreatic tumors [2]. Surgical removal is the ideal treatment, however, medical treatment to normalize the blood glucose levels is useful in patients with symptomatic hypoglycemia before surgery, and in patients in whom surgical removal is not possible due to the inaccessible location of the tumor in the pancreas. In addition, some patients are too old and/or debilitated at presentation to be suitable candidates for major surgery.

The somatostatin analogue, octreotide, is known to suppress the secretion of various hormones from endocrine tissues or tumors, including insulin secretion from the pancreatic beta cells, *via* the somatostatin receptor [3]. Although five somatostatin receptor (SSTR) subtypes (SSTR1-5) have been identified in insulinoma cells, octreotide binds with high affinity to SSTR2 and SSTR5 [4-7]. Vezzosi *et al*. showed that positive SSTR2A, but not SSTR5, receptor immunostaining could be associated with the efficacy of octreotide treatment [8].

The octreotide test has been reported to be useful for predicting the efficacy of treatment in patients with benign insulinomas [8-10]. However, reports describ-

Submitted Jul. 1, 2015; Accepted Oct. 19, 2015 as EJ15-0371
Released online in J-STAGE as advance publication Nov. 14, 2015
Correspondence to: Hideaki Miyoshi, M.D., Ph.D., Division of Rheumatology, Endocrinology and Nephrology, Hokkaido University Graduate School of Medicine, N-15, W-7, Kita-ku, Sapporo 060-8638, Japan. E-mail: hmiyoshi@med.hokudai.ac.jp

©The Japan Endocrine Society

ing the possible relationship between the results of the octreotide test and the presence/absence of SSTR2 expression in insulinoma patients are still scarce. In the present study, therefore, we investigated the relationships of the octreotide test results with the presence/absence of SSTR2 expression in insulinoma patients, in order to evaluate the usefulness of the octreotide test for predicting the presence/absence of SSTR2 expression in insulinomas.

Patients and Methods

Patients

This study included six Japanese patients (five females and one male) with hypoglycemia associated with endogenous hyperinsulinemia who were referred to Hokkaido University Hospital, Sapporo, Japan. A detailed history was obtained from each patient, and a physical examination was performed. The diagnosis of insulinoma was made as described below. Also, all patients underwent the octreotide test as described below before the surgery. Partial pancreatectomy was performed for all the patients enrolled in this study and histopathological examination of the tumor was performed by a single experienced pathologist (T.M.). The study was conducted with the approval of the Institutional Review Boards of the Hokkaido University Hospital.

Diagnosis of insulinoma

A biochemical diagnosis of insulinoma was made when the following criteria were satisfied: fasting plasma glucose concentration <3 mmol/L, plasma insulin concentration ≥3 μU/mL, and no circulating antibodies to insulin. All the six patients fulfilled the criteria for Whipple's triad – hypoglycemic symptoms in the presence of low plasma glucose with relief of symptoms on administration of glucose – during the episodes of hypoglycemia. Blood samples taken during fasting showed low plasma glucose levels of 2.1-2.9 mmol/L and relatively elevated serum insulin levels of 9.1-20.3 μU/mL. Adrenal insufficiency, hypopituitarism, hepatic failure, insulin autoimmune syndrome, and ingestion of alcohol or hypoglycemic agents as the cause of the hypoglycemia were excluded based on the laboratory and endocrine data and the medical history (data not shown). A 75-g oral glucose tolerance test (OGTT) was performed to confirm glucose tolerance and the existence of postprandial hypoglycemia. Glucose tolerance was classified according to the 2006 World Health Organization (WHO) criteria [11] and Glucose-stimulated insulin secretion was evaluated based on the insulinogenic index [12]. The diagnosis of insulinoma was confirmed by localizing the tumor by conventional imaging examinations, such as abdominal computed tomography scan and ultrasonography. Also, selective arterial calcium stimulation and hepatic venous sampling were performed in five of the six patients. The plasma glucose and serum insulin levels were measured by standard laboratory techniques.

Octreotide test

The octreotide test was performed in all six patients. Basal plasma glucose and serum insulin were measured at 0600 h (0 min). Then, 100 μg of octreotide was injected subcutaneously, and blood samples were collected from an antebrachial vein at 0700 h (60 min), 0800 h (120 min), 1000 h (240 min), 1200 h (360 min) and 1400 h (480 min) for measurement of the plasma glucose and serum insulin levels. If the suppression of insulin secretion is insufficient (plasma glucose concentration <3 mmol/L despite plasma insulin concentration ≥3 μU/mL [2]) after injection of octreotide, the patient is classified as a negative response in the octreotide test.

Histopathological examination

Histopathological examination was performed by hematoxylin and eosin (H&E) staining of formalin-fixed, paraffin-embedded (FFPE) tissue sections prepared from the surgically resected specimens. The tumor grade was evaluated by a combination of the mitotic counts in at least 50 high power fields (HPFs) (1 HPF = 2 mm^2) and the Ki-67 labelling index using the MIB-1 antibody as a percentage of 500-2,000 cells counted in areas showing the strongest nuclear labelling (hot spots), as recommended in the WHO classification of tumors of the digestive system, 4th edition. If the grade as assessed by the mitotic counts differed from that assessed by the Ki-67 index, the higher grade was assumed. Immunohistochemical staining was performed as follows. Sections were deparaffinized in xylene and rehydrated through a graded ethanol series. Appropriate antigen retrieval was carried out according to the manufacturer's protocol. Basically, heat-induced antigen retrieval was carried out in a high-pH antigen retrieval buffer (Dako Cytomation, Glostrup, Denmark). Endogenous peroxidase was blocked by incubation

in 3% H_2O_2 for 5 min. Primary antibodies against SSTR2 (1:100, UMB1; Abcam, Cambridge, UK), SSTR5 (1:1000, ab28618; Abcam, Cambridge, UK), chromogranin A (1:150, DAK-A3; Dako Cytomation, Glostrup, Denmark), synaptophysin (1:100, 27G12; Novocastra, Tyne, United Kingdom), CD56 (prediluted, 123C3; Zymed, San Francisco, CA, USA), insulin (1:100, 2D11-H5; Novocastra, Tyne, United Kingdom), and Ki-67 (1:20, MIB-1; Dako Cytomation, Glostrup, Denmark) were applied for 60 minutes. The sections were visualized by the HRP-labeled polymer method (EnVision FLEX system, Dako). Immunostained sections were counterstained with hematoxylin, dehydrated in ethanol, and cleared in xylene. The tumors were classified as neuroendocrine tumor grade 1 (NET G1) when the mitotic count was <2 per 10 HPFs and/or the Ki-67 index was ≤2%, as NET G2 when the mitotic count was 2-20 per 10HPF and/or the Ki-67 index was 3-20% and as neuroendocrine carcinoma (NEC) when the mitotic count was >20 per 10 HPFs and/or the Ki-67 index was >20% [13].

SSTR2 expression was evaluated by the SSTR2 immunohistochemistry (IHC) scoring system as follows: 0: absence of immunoreactivity; 1: pure cytoplasmic immunoreactivity, either focal or diffuse; 2: membranous reactivity in less than 50% of the tumor cells, irrespective of the presence of cytoplasmic staining; 3: circumferential membranous reactivity in more than 50% of the tumor cells, irrespective of the presence of cytoplasmic staining [14]. SSTR5 immunostaining in the tumors was compared with that obtained in the normal adjacent pancreatic tissue, as described elsewhere [8]. The immunostaining was described as 3+ if its intensity was greater than that observed in the normal pancreas, 2+ if it was similar, and + if it was less than that of the normal pancreas and - when no immunostaining was found in the tumor [8].

Results

Clinical features and biochemical data

Five females and one male, ranging in age from 41 years to 81 years, were included in this study (Table 1). The result of a 75-g OGTT in the six patients were shown in Table 2. Of the six patients, one (patients 1) were diagnosed as normal glucose tolerance, while the remaining 5 (patients 2-6) were diagnosed as impaired glucose tolerance. The insulinogenic indices in patients 1-6 were 0.33, 0.88, 0.28, 0.67, 0.03 and 0.62, respectively. This result indicated that glucose-stimulated insulin secretion in patient 5 was extremely lower than that in the other patients. There were no postprandial hypoglycemia during the OGTT in all these patients. Abdominal ultrasonography and computed tomography revealed the tumors in all these patients. Furthermore, selective arterial calcium stimulation and hepatic venous sampling showed a striking increase of the insulin concentration in the splenic artery supplying the pancreatic body and tail area in patients 1, 2 and 5, and in the gastroduodenal artery supplying the pancreatic head area in patients 3 and 4. A clinical diagnosis of insulinoma was made based on these results and surgical resection of the tumors was performed.

Octreotide test

The octreotide test was performed to evaluate the efficacy of octreotide in improving the hyperinsulinemic hypoglycemia in all the six patients. As shown in Table 3, suppression of insulin secretion was achieved, starting at 60 min after octreotide loading, in patients 1-4 and 6. However, in patient 5, the suppression of insulin secretion was insufficient, which resulted in severe hypoglycemia with endogenous relative hyperinsulinemia (plasma glucose concentration was 2.1 mmol/L although plasma insulin concentration was 8.5 μU/mL) starting at 120 min after octreotide loading, and then insulin secretion was rather increased after 240 min. From these results, patients 1-4 and 6 were classified as a positive response group. On the other hand, patient 5 was classified as a negative response group.

Pathological findings

Macroscopically, the tumor was located in the head (n = 2), body (n = 1) or tail (n = 3) of the pancreas. The tumors ranged in size from 4 to 67 mm (Table 4). Histopathologically, the mitotic index was <2 per 10 HPFs in patients 1-5 and 7 per 10 HPFs in patient 6. There was no definitive venous invasion in any of the cases. IHC for chromogranin A, synaptophysin and insulin revealed diffuse positive staining for all of these proteins in all the tumors. The Ki-67 labelling index was >2% in patients 3, 4 and 6. Based on these results, the tumors in these three patients (patients 1, 2, and 5) were classified as NET G1 and those in the remaining three patients (patients 3, 4 and 6) as NET G2 (Table 4). As shown in Fig. 1, SSTR2 was expressed in 5 of the insulinomas (patients 1-4 and 6), with an IHC score of 3. On the other hand, the IHC score was 0 and no

Table 1 Clinical features and glucose and insulin levels at hypoglycemia of the six patients

Patient	Gender	Age (years)	Body mass index (kg/m^2)	Manifestations	Glucose (mmol/L)	Insulin (μU/mL)
1	Female	81	24.2	Gait disorder	2.1	11.8
2	Female	68	26.1	Dizziness, loss of appetite	2.8	20.3
3	Female	76	27.0	Abnormal behavior	2.7	11.4
4	Male	71	31.1	Loss of consciousness	2.7	10.5
5	Female	69	27.4	Loss of consciousness	2.4	9.1
6	Female	41	19.6	Loss of consciousness	2.9	17.3

Table 2 Oral glucose tolerance test (75-g OGTT)

Patient		Time (minutes)					
		0	30	60	90	120	180
1	Glucose (mmol/L)	4.4	9.4	10.7	8.9	7.4	8.9
	Insulin (μU/mL)	11.2	41.0	61.0	53.7	37.3	53.8
2	Glucose (mmol/L)	2.8	6.9	8.2	ND	9.1	8.7
	Insulin (μU/mL)	20.3	86.5	96.4	ND	103.2	77.5
3	Glucose (mmol/L)	3.2	5.7	5.7	9.7	11.0	7.2
	Insulin (μU/mL)	8.5	20.7	15.9	40.9	54.4	18.7
4	Glucose (mmol/L)	3.4	5.2	7.7	7.9	7.8	6.6
	Insulin (μU/mL)	10.0	31.5	56.8	41.5	42.5	30.6
5	Glucose (mmol/L)	3.3	4.3	7.0	8.4	9.3	5.6
	Insulin (μU/mL)	5.3	5.9	21.8	27.2	22.6	5.0
6	Glucose (mmol/L)	5.8	9.2	9.1	9.3	7.9	6.3
	Insulin (μU/mL)	27.1	64.3	56.5	59.6	52.3	25.9

ND, not determined

Table 3 Octreotide test

Patient		Time (minutes)					
		0	60	120	240	360	480
1	Glucose (mmol/L)	5.8	4.0	2.9	4.8	ND	8.6
	Insulin (μU/mL)	7.3	<0.5	<0.5	<0.5	ND	1.6
2	Glucose (mmol/L)	6.6	6.8	7.3	8.3	7.1	6.4
	Insulin (μU/mL)	29.4	2.0	2.5	5.3	4.5	<0.5
3	Glucose (mmol/L)	3.3	2.8	7.7	7.3	6.8	6.4
	Insulin (μU/mL)	5.1	<0.5	<0.5	1.5	2.4	1.2
4	Glucose (mmol/L)	2.8	3.1	5.4	6.4	4.3	5.8
	Insulin (μU/mL)	8.1	2.0	3.7	4.2	3.6	6.2
5	Glucose (mmol/L)	4.2	3.0	2.1	5.7	5.4	6.0
	Insulin (μU/mL)	13.6	5.9	8.5	27.4	19.8	19.7
6	Glucose (mmol/L)	4.6	4.4	5.1	4.9	4.2	3.5
	Insulin (μU/mL)	14.1	3.2	1.5	4.7	4.1	7.2

ND, not determined

Table 4 Histopathological manifestation in the present patients

Patient	Size (mm)	Location (pancreas)	Mitotic index (/ 10HPF)	Ki-67 (%)	Chromogranin A, Synaptophysin and Insulin	Diagonosis
1	4	Body	0	2.0	All positive	NET G1
2	12	Tail	1	2.0	All positive	NET G1
3	12	Head	0	9.0	All positive	NET G2
4	11	Head	0	7.0	All positive	NET G2
5	8	Tail	1	1.9	All positive	NET G1
6	67	Tail	7	11.3	All positive	NET G2

HPF, high-power field; NET, neuroendocrine tumor; G1, grade 1; G2, grade 2

SSTR2 expression was detected in the remaining one case (patient 5). Immunohistochemical localization of SSTR5 was predominantly in cytoplasm, however; membranous accentuation was observed in one of these cases (patient 3). The heterogeneity and obscuration in the immunostaining were observed for SSTR5 in comparison with that for SSTR2, which showed sharper and more consistent membranous staining. Patient 5 also showed positivity for SSTR5 (see Supplemental Fig. 1), although SSTR2 was totally negative for this case. These results showed that improvement of hyperinsulinemic hypoglycemia by octreotide in the octreotide test was associated with the presence of SSTR2 immunoreactivity, but not with the immunoreactivity for SSTR5, although both of them were expressed in the insulinomas to a varying degree.

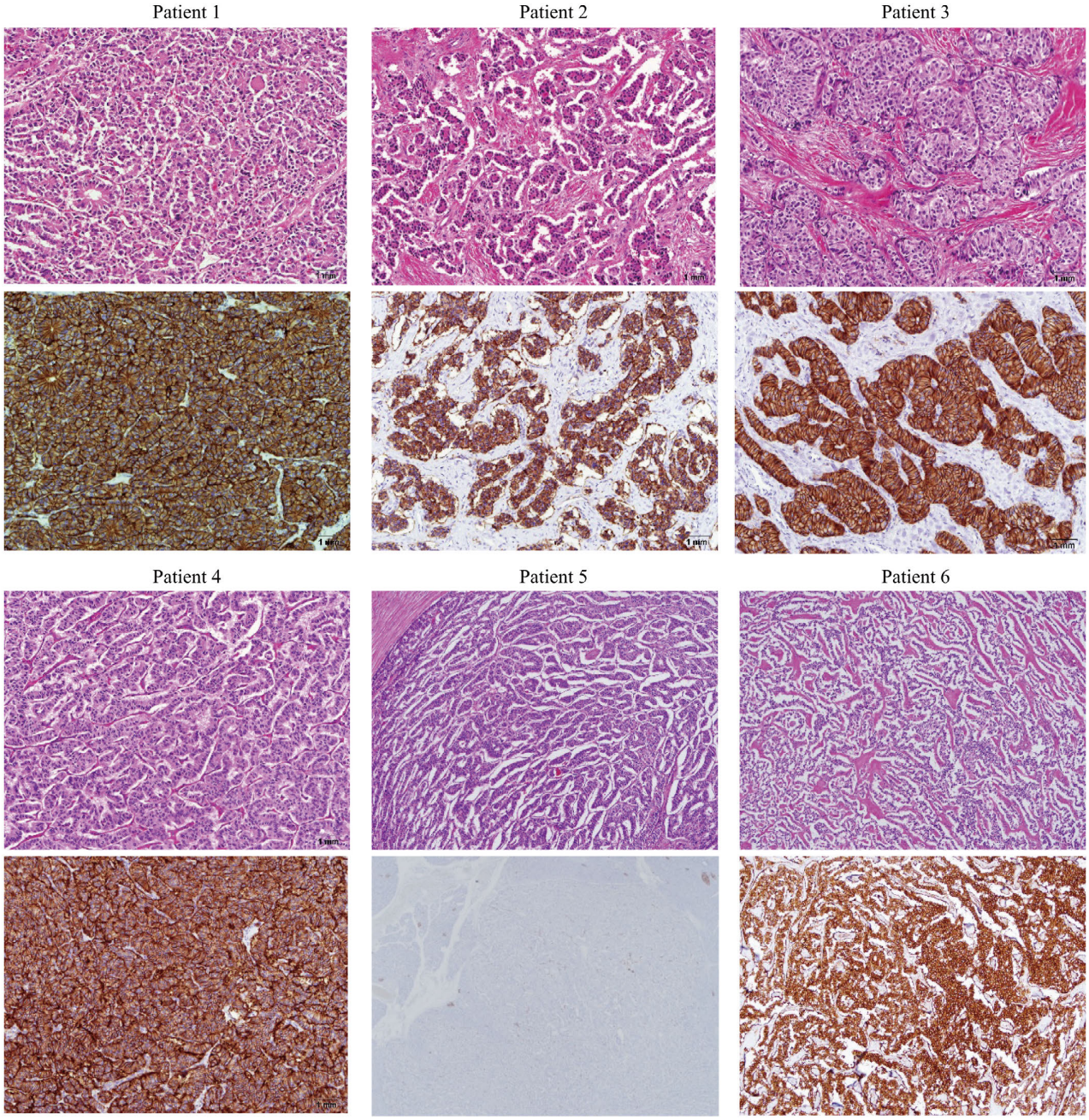

Fig. 1 Microscopic findings in the insulinomas of the six patients assessed by hematoxylin-and-eosin staining (upper slides) and immunohistochemistry for SSTR2 (lower slides).

Discussion

The somatostatin analogue, octreotide, has been shown to be useful for the control of hypoglycemia in some cases of insulinoma, and the efficacy/safety of long-term treatment with octreotide has been reported [9]. However, the response to octreotide has been reported to vary depending on the presence or absence, mainly of SSTR2A expression on the insulinoma cells [8, 9]. We used antibody against SSTR2 instead of SSTR2A, based on the results of our pilot studies on the outcomes of IHC using these antibodies. Sharper and more distinct membranous immunostaining was obtained with SSTR2 antibody as compared to that with SSTR2A antibody, although the tendency of positivity and negativity was exactly similar for both antibodies. SSTR2 is the functionally dominant somatostatin receptor in human pancreatic alpha-cells [15], and SSTR2 agonists are the most potent inhibitors of glucagon secretion from isolated human pancreatic islets [16]. Thus, in cases with insulinoma cells showing very low or absent expression of SSTR2, octreotide might lower the blood glucose level by suppressing the release of counter-regulatory factors such as glucagon [7, 17]. According to one case report, exacerbation of hypoglycemia was observed in a patient with a proinsulinoma treated with octreotide [18]. In this case, acute neuroglycopenic symptoms were present during the period of octreotide-induced hypoglycemia, which was accompanied by and probably attributable to an acute reduction of the pancreatic glucagon secretion in the presence of persistent and unsuppressed hyperproinsulinemia due to low or absent expression of SSTR2. Therefore, it is important to predict the presence or absence of SSTR2 expression at an early stage in patients with insulinoma, since it is difficult to confirm SSTR2 expression directly prior to surgical resection.

In our present study, all five patients with a positive response in the octreotide test showed positive results of IHC for SSTR2 expression, while a negative result of IHC was obtained in the one patient who showed a negative response in the octreotide test. Vezzosi's report described the association between the octreotide test results and presence/absence of SSTR2A expression in insulinoma patients [8], and our results are largely consistent with this report. Although evidence to suggest the usefulness of the octreotide test is accumulating, one problem is that the definition of a response or non-response in the octreotide test remains inconsistent. In some case reports, a positive response in the octreotide test was based on the suppression of insulin secretion [10, 19]. On the other hand, Vezzosi described that patients experiencing symptomatic hypoglycemia with a blood glucose level of <2.5 mmol/L were considered to be unresponsive [8, 9]. Essentially, the pathophysiological concept of insulinoma is hypoglycemia associated with endogenous hyperinsulinemia. Thus, ideally we should evaluate whether administration of octreotide improves the hypoglycemia associated with the endogenous hyperinsulinemia. Our study showed that in all the five insulinoma patients in whom the hypoglycemia associated with endogenous hyperinsulinemia improved with the administration of octreotide, namely, in the patients who showed a positive response in the octreotide test, SSTR2 was expressed on the insulinoma cells, and that in the one patient with persistent hypoglycemia associated with endogenous hyperinsulinemia following octreotide administration, that is, in the patient who showed a negative response in the octreotide test, the result of IHC for SSTR2 expression was negative. Our study is the first report of revealing the association between the responses in the octreotide test and SSTR2 expression by using the essential criteria for the assessment of octreotide test. Based on these perspectives, a larger prospective study with evaluation of accurate cutoff values of the plasma glucose and serum insulin levels in the octreotide test is needed.

A 75-g OGTT indicated that glucose-stimulated insulin secretion in one patient was extremely lower than that in the other patients. Considering that the suppression of insulin secretion was insufficient after the octreotide loading and no SSTR2 expression was detected in only this patient, the response of insulin to glucose could be relevant to that to octreotide and to SSTR2 expression. Although this association is interesting, it is unclear whether there is a positive correlation between SSTR2 expression and glucose-stimulated insulin secretion. Additionally, since it has been reported that octreotide was effective in elderly patients with insulinoma [10, 19, 20], the relationship between SSTR2 expression and age is interesting. However, it is also unclear whether SSTR2 expression is correlated to age in our results. Further studies are needed for elucidating these correlations.

The major limitations of our study were the retrospective study design and the small size of the sample. Another limitation was that there were no cases with an IHC score of 1 or 2. Thus, it is not clear yet whether

administration of octreotide improves the hypoglycemia associated with the endogenous hyperinsulinemia in patients with an IHC score of 1 or 2. Further large-scale studies are needed to obtain more detailed information. Since this study included six patients with low-grade insulinomas, one of the challenges for the future is to estimate the usefulness of the octreotide test for the prediction of SSTR2 expression also in high-grade insulinomas.

In conclusion, improvement of hyperinsulinemic hypoglycemia by octreotide in the octreotide test was associated with the presence of SSTR2 expression in the tumors in Japanese patients with insulinomas. Our results suggest that the octreotide test could be useful for predicting the presence/absence of SSTR2 expression at an early stage for the treatment of insulinoma, since it is difficult to confirm SSTR2 expression directly without surgical resection.

Acknowledgement

This work was supported in part by a Grant-in-Aid for Research on Specific Diseases "Hypothalamo-Pituitary Dysfunction" from the Ministry of Health, Labour and Welfare, Japan (C.S.).

Disclosure

None of the authors have any potential conflicts of interest associated with this research.

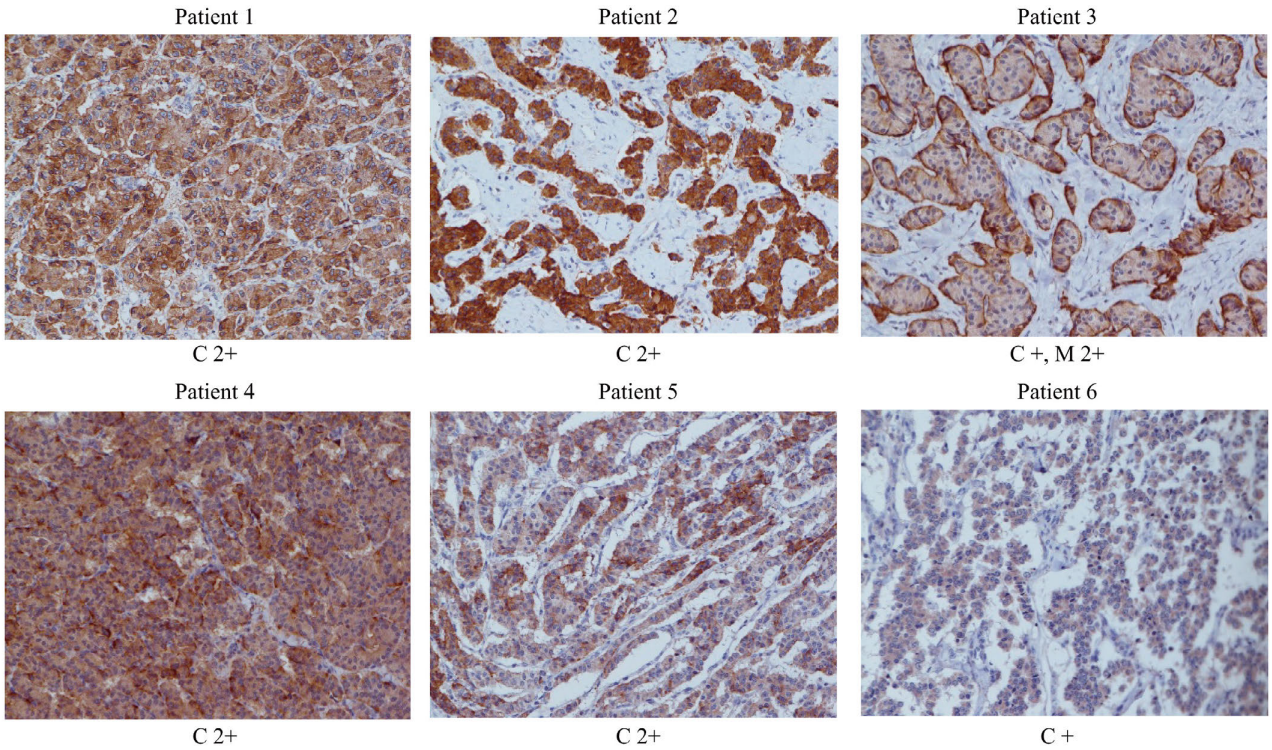

Supplemental Fig. 1 Immunohistochemical SSTR5 expression in the insulinomas of the six patients. Note that patient 5 shows cytoplasmic staining (C 2+), although SSTR2 immunostaining is not detected in the same tumor (see Fig. 1). C, cytoplasmic; M, membranous

References

1. Krampitz, GW, Norton JA (2013) Pancreatic neuroendocrine tumors. *Curr Probl Surg* 50: 509-545.
2. Iglesias P, Díez JJ (2014) Management of endocrine disease: a clinical update on tumor-induced hypoglycemia. *Eur J Endocrinol* 170: R147-R157.
3. Battershill PE, Clissold SP (1989) Octreotide. A review of its pharmacodynamic and pharmacokinetic properties, and therapeutic potential in conditions associated with excessive peptide secretion. *Drugs* 38: 658-702.
4. Bertherat J, Tenenbaum F, Perlemoine K, Videau C,

Alberini JL, et al. (2003) Somatostatin receptors 2 and 5 are the major somatostatin receptors in insulinomas: an in vivo and in vitro study. *J Clin Endocrinol Metab* 88: 5353-5360.

5. de Sá SV, Corrêa-Giannella ML, Machado MC, de Souza JJ, Pereira MA, et al. (2006) Somatostatin receptor subtype 5 (SSTR5) mRNA expression is related to histopathological features of cell proliferation in insulinomas. *Endocr Relat Cancer* 13: 69-78.
6. de Herder WW, Kwekkeboom DJ, Feelders RA, van Aken MO, Lamberts SW, et al. (2006) Somatostatin receptor imaging for neuroendocrine tumors. *Pituitary* 9: 243-248.
7. Oberg K, Kvols L, Caplin M, Delle Fave G, de Herder W, et al. (2004) Consensus report on the use of somatostatin analogs for the management of neuroendocrine tumors of the gastroenteropancreatic system. *Ann Oncol* 15: 966-973.
8. Vezzosi D, Bennet A, Rochaix P, Courbon F, Selves J, et al. (2005) Octreotide in insulinoma patients: efficacy on hypoglycemia, relationships with Octreoscan scintigraphy and immunostaining with anti-sst2A and anti-sst5 antibodies. *Eur J Endocrinol* 152: 757-767.
9. Vezzosi D, Bennet A, Courbon F, Caron P (2008) Short- and long-term somatostatin analogue treatment in patients with hypoglycaemia related to endogenous hyperinsulinism. *Clin Endocrinol (Oxf)* 68: 904-911.
10. Katabami T, Kato H, Shirai N, Naito S, Saito N (2005) Successful long-term treatment with once-daily injection of low-dose octreotide in an aged patient with insulinoma. *Endocr J* 52: 629-634.
11. World Health Organization (2006) Definition and Diagnosis of Diabetes Mellitus and Intermediate Hyperglycemia: Report of a WHO / IDF Consultation. World Hearth Org.
12. Onishi Y, Hayashi T, Sato KK, Ogihara T, Kuzuya N, et al. (2010) Fasting tests of insulin secretion and sensitivity predict future prediabetes in Japanese with normal glucose tolerance. *J Diabetes Investig* 1: 191-195.
13. Bosman FT (2010) World Health Organization classification of tumours of the digestive system. *Lyon: IARC Press*.
14. Volante M, Brizzi MP, Faggiano A, La Rosa S, Rapa I, et al. (2007) Somatostatin receptor type 2A immunohistochemistry in neuroendocrine tumors: a proposal of scoring system. *Mod Pathol* 20: 1172-1182.
15. Kailey B, van de Bunt M, Cheley S, Johnson PR, MacDonald PE, et al. (2012) SSTR2 is the functionally dominant somatostatin receptor in human pancreatic β- and α-cells. *Am J Physiol Endocrinol Metab* 303: E1107-E1116.
16. Singh V, Brendel MD, Zacharias S, Mergler S, Jahr H, et al. (2007) Characterization of somatostatin receptor subtype-specific regulation of insulin and glucagon secretion: an in vitro study on isolated human pancreatic islets. *J Clin Endocrinol Metab* 92: 673-680.
17. Healy ML, Dawson SJ, Murray RM, Zalcberg J, Jefford M (2007) Severe hypoglycaemia after long-acting octreotide in a patient with an unrecognized malignant insulinoma. *Intern Med J* 37: 406-409.
18. Gama R, Marks V, Wright J, Teale JD (1995) Octreotide exacerbated fasting hypoglycaemia in a patient with a proinsulinoma; the glucostatic importance of pancreatic glucagon. *Clin Endocrinol (Oxf)* 43: 117-120; discussion 120-122.
19. Kishikawa H, Okada Y, Hirose A, Tanikawa T, Kanda K, et al. (2006) Successful treatment of insulinoma by a single daily dose of octreotide in two elderly female patients. *Endocr J* 53: 79-85.
20. Usukura M, Yoneda T, Oda N, Yamamoto Y, Takata H, et al. (2007) Medical treatment of benign insulinoma using octreotide LAR: a case report. *Endocr J* 54: 95-101.