



Title	Surgery for Left Ventricular Outflow Tract Obstruction with a Relatively Thin Interventricular Septum
Author(s)	Shingu, Yasushige; Sugiki, Hiroshi; Ooka, Tomonori et al.
Citation	The Thoracic and cardiovascular surgeon, 66(04), 307-312 https://doi.org/10.1055/s-0035-1570748
Issue Date	2018-06
Doc URL	https://hdl.handle.net/2115/71265
Rights	This is an Accepted Manuscript of an article published by Thieme Publishing Group in Journal Title on Publication Date, available online at https://www.thieme-connect.de/products/ejournals/abstract/10.1055/s-0035-1570748
Type	journal article
File Information	ThoracCardiovascSurg66_307.pdf



Introduction

Excellent clinical results of isolated myectomy for hypertrophic obstructive cardiomyopathy (HOCM) have been reported by groups from the Cleveland Clinic and Mayo Clinic [1, 2]. On the other hand, it is remarkable that half of the patients have residual systolic anterior motion (SAM) of the mitral valve after myectomy [3]. Some surgeons insist that the mitral valve should be replaced when the ventricular septum is relatively thin (< 18 mm) or atypical septal hypertrophy exists [4, 5], but it is still controversial whether we should perform mitral valve surgery concomitant with septal myectomy [6]. There exists a report about a failure i.e. exacerbation of mitral regurgitation (MR) after isolated myectomy for SAM and LVOTO in sigmoid septum with relatively thin interventricular septum [7]. The authors speculated that abnormal papillary muscle attachment might have caused the failure. Because we believe that the effect of isolated myectomy is limited when the interventricular septum is relatively thin (< 20 mm), we have employed mitral valve repair concomitant with myectomy for HOCM cases with SAM and left ventricular outflow obstruction (LVOTO) when MR is more than mild [8]. Here we examine the surgical results of myectomy for SAM and LVOTO including HOCM and sigmoid septum as their pathology.

Material and Methods

Subjects

From 1995 to 2014, 14 patients were referred to our institution for surgical correction of SAM and LVOTO. We included 12 patients with relatively thin interventricular septum (<20 mm) who had both SAM and LVOTO. We excluded those with severe

aortic valve stenosis and LVOTO but without SAM. According to the American Heart Association guidelines, hypertrophic cardiomyopathy (HCM) was diagnosed by unexplained LV hypertrophy associated with non-dilated ventricular chambers in the absence of another cardiac or systemic disease that itself would be capable of producing the magnitude of hypertrophy [9]. Metabolic and infiltrative storage disorders were excluded by clinical and pathological analysis of the surgical specimens. HOCM was defined HCM with LVOTO. LVOTO was defined as the peak instantaneous continuous wave Doppler gradient at rest greater than 30 mmHg. In the current study, marked gradients over 50 mmHg was observed in nine in total 12 patients and three presented with marked gradients with the Valsalva maneuver.

Table 1 shows the preoperative characteristics of the patients. Eight had HOCM, three had sigmoid septum (two had also severe aortic valve stenosis), and one had an unknown etiology. The patients had symptoms of heart failure (dyspnea on exertion: n=10), syncope (n=1), and general fatigue (n=1) even with optimal medical treatments including beta blockers [10]. The preoperative maximum LVOT pressure gradients were 140 ± 18 and 56 ± 15 mmHg in the HOCM group and the group without HOCM, respectively. A DDD (dual pacing for both chambers, dual chamber activity sensing, and dual response) pacemaker had been implanted for one patient in the HOCM group. Three patients with HOCM underwent pacing studies with negative results before operation: using a pressure wire introduced from the femoral artery into the LV, LVOT pressure gradients were assessed at a series of AV intervals from 60 to 180 ms (increase by 20 ms) during temporary right atrial and ventricular apical pacing and AV interval of 100 ms during temporary right atrial and interventricular septal pacing; negative result was defined LVOT pressure gradient > 50 mmHg and $< 30\%$ reduction by any pacing

modes. The university ethics committee approved the research protocol (No. 015-0007) and waived the informed consent requirements for this retrospective study.

Assessment of cardiac function by transthoracic echocardiography

We used a Sonos 5500 ultrasound system (Philips Medical Systems, Andover, Massachusetts, USA) with a 3S transducer (3-5 MHz), a Vivid Seven system (GE/Vingmed, Milwaukee, Wis, USA) with an M3S (2.5-3.5 MHz) transducer, or an Aplio system (Toshiba Medical Systems, Tokyo, Japan) with a 2.5 MHz transducer. The following basic variables were measured from the parasternal long axis view: LV end-diastolic (LVDD) and end-systolic dimensions (LVDS) (mm), interventricular septal thickness (IVST), and LV posterior wall thickness (mm). The MR jet area was measured from the maximal MR jet by color Doppler, either in the four-chamber plane or the frontal long-axis plane. The severity of MR was analyzed off-line using color jet area mapping as follows: mild (grade 1), color jet area 2.0 to 3.9 cm²; moderate (grade 2 or 3), color jet area 4.0 to 8.0 cm²; severe (grade 4), color jet area > 8.0 cm² [11]. Moderate MR was subclassified into grade 2 when regurgitant volume assessed by the volumetric method using pulse-wave Doppler was from 30 to 44 ml and grade 3 when regurgitant volume was from 45 to 59 ml [12]. LVOT pressure gradient was measured using continuous wave Doppler by apical long axis view and Bernoulli's principle [9]. All values were averaged using three consecutive measurements. Sigmoid septum was defined when the angle between the anterior line of the ascending aorta and that of the ventricular septum was less than 120° from the parasternal long axis view. SAM was defined as the distortion of the anterior mitral valve leaflet secondary to LVOTO [9]. The jet of MR was directed laterally and posteriorly in all but three cases with

morphological changes of the mitral valve. Mitral leaflet length was also measured from the parasternal long axis view. Echocardiography was performed within one week before operation (pre-OP), from two to three weeks after operation (post-OP), and at the last follow-up (mean, 3.6 years after operation).

Surgical procedures

Table 2 shows the surgical procedures. For HOCM, isolated extended myectomy which is a modified Morrow technique releasing the communication between the aortic valve and abnormal attachment of the papillary muscles [13] was performed when MR was mild (n=1) and extended myectomy and mitral valve surgery were performed when MR was more than mild (n=4) or primary valve etiologies existed (n=3). Figure 1 shows the mitral repair techniques for posterior mitral leaflet height reduction (a) and anterior mitral leaflet augmentation and retention plication (b) [8, 14-16]. When the posterior leaflet was elongated (> 20 mm), it was excised and slid to reduce the leaflet height (Figure 2; n=3). For one case with a relatively short posterior leaflet height (< 20 mm), we employed anterior mitral leaflet augmentation and retention plication to reduce excessive mobility of the anterior mitral leaflet. A true-sized or larger total annuloplasty ring was selected according to the results of an ink test after leaflet plication. In three HOCM patients, the thickened anterior papillary muscle deviated to the septum without direct attachment. In the other five patients, there was no remarkable changes in the papillary muscles. There was no septal band across the LVOT to the anterior mitral leaflet.

In the group without HOCM, isolated myectomy was performed for the three patients with sigmoid septum (two underwent aortic valve replacement concomitantly), and

myectomy and height reduction of the posterior mitral leaflet were performed for the one patient with the unknown etiology of SAM. The resected muscle length, depth, and width were 38 ± 4 , 9 ± 1 , and 10 ± 0.4 mm in HOCM group and 28 ± 5 , 8 ± 1 , and 11 ± 1 mm in the other group, respectively.

Statistical analysis

Data are presented as mean \pm standard error of the mean. The Wilcoxon test was used to compare pre- and postoperative values. Differences were considered statistically significant if $p < 0.05$. Statistical analysis was performed with SPSS version 17.0 software (SPSS Inc. Chicago, Ill).

Results

Figure 3 shows representative pre- (a) and postoperative (b) echocardiographic images of an HOCM patient who underwent myectomy, anterior mitral leaflet augmentation, and retention plication. Moderate MR disappeared after surgery. The maximum LVOT pressure gradient decreased from 174 to 16 mmHg.

Figure 4a shows the changes of the SAM, LVOT pressure gradient, and MR grade in the HOCM group. Two patients presented with residual SAM early after surgery, but it disappeared during the follow-up. The maximum LVOT pressure gradient significantly decreased from 140 ± 18 to 16 ± 6 , and 3 ± 3 mmHg, and the MR grade significantly decreased from 2.3 ± 0.5 to 0.5 ± 0.3 , and 0.4 ± 0.2 at pre-OP, early post-OP, and the last follow-up (3 ± 1 years), respectively. The NYHA class at the last follow-up (4 ± 1 years)

was 1 for six patients and 2 for two (we lost one case to follow-up).

Figure 4b shows the changes of SAM, the LVOT pressure gradient, and MR grade in the group without HOCM. One patient presented with residual SAM early after surgery, but it disappeared during the follow-up. The maximum LVOT pressure gradient decreased from 56 ± 15 to 25 ± 15 , and 5 ± 4 mmHg, and the MR grade decreased from 2.0 ± 0.6 to 1.3 ± 0.3 , and 1.3 ± 0.8 at pre-OP, early post-OP, and the last follow-up (3 ± 2 years), respectively. One patient who underwent myectomy presented with grade 2 MR in the late period. The other one patient who had a morphological change in the mitral valve presented with grade 3 MR late after mitral valve peeling and commissurotomy. The other two patients had no MR in the late period. The NYHA class at the last follow-up (7 ± 4 years) was 1 for three patients and 2 for one patient.

Discussion

We demonstrated here that our surgical results for myectomy and mitral valve surgery for symptomatic SAM and LVOTO were acceptable. Although some reports have presented good results of isolated extended myectomy for MR in HOCM, we believe that mitral valve surgery is necessary for those with a relatively thin ventricular septum (< 20 mm) because sufficient myectomy could not be performed without the risk of interventricular septal perforation.

Is mitral valve surgery necessary for HOCM?

Excellent clinical results of isolated myectomy for HOCM have been reported by

groups at the Cleveland Clinic and Mayo Clinic [1, 2]. Cho et al. reported that the recurrence of symptomatic LVOTO was uncommon (2.5% in 2000 cases) and the most common cause of the recurrence was inadequate length of the septal incision [2]. However, it is remarkable that over half of the patients have residual SAM in the long term after myectomy [3]. Some reported that mitral valve replacement with low-profile mechanical prostheses is as effective as myectomy for SAM and LVOTO in HOCM [4, 5, 17, 18]. McIntosh et al. insisted that the mitral valve should be replaced when IVST is less than 18 mm or atypical septal hypertrophy exists [4]. More recently, various surgical techniques for mitral valve repair rather than replacement have been reported [14-16, 19, 20]. Nasser and Hetzer reported retention plasty in which the medial and lateral anterior mitral leaflet closest to the trigones are sutured to the corresponding posterior annulus to reduce excessive mobility of the anterior leaflet [14]. Swistel et al. proposed the resection, plication, and release (RPR) procedure. The resection refers to extended myectomy, plication is treatment of the anterior leaflet itself in cases where it is extremely redundant, and release refers to the dividing of any abnormal attachments that the papillary muscles may have to the lateral wall of the LV [19]. Anterior mitral leaflet extension with autologous pericardium has been employed by some surgeons [15, 16]. In this technique, the patch stiffens the anterior mitral leaflet, making it less likely to buckle in the presence of Venturi and flow drag forces. Seeburger and Mohr have reported a new approach using a minimally invasive technique for transmitral septal myectomy followed by complete resection and replacement of all anterior mitral leaflet chordae with longer neochordae by a loop technique [20].

In the current study, the mean IVST in HOCM was 16 mm and all of the patients had IVST of less than 20 mm, which is much smaller than those reported in Europe (23 mm)

[14, 16]. In a patient with thick interventricular septum, the amount of muscle resection would be large and we can expect enough release of abnormal attachment of the papillary muscles and reduction of the Venturi effect after isolated myectomy. On the other hand, if we can resect only small amount of septal muscle due to relatively thin interventricular septum, we would not properly achieve the release of abnormal attachment of the papillary muscles and reduction of the Venturi effect. If these two patients had the same degree of SAM, LVOTO, and mitral leaflet length before operation, the possibility of failure after isolated myectomy would be stronger in the patient with thin interventricular septum than the other. It is possible that isolated myectomy for the cases in the current study might not be sufficient to eradicate significant SAM and MR. We have not seen any recurrence of SAM during the follow-up. We believe that concomitant mitral valve surgery is necessary, especially for those with a relatively thin ventricular septum as seen in this study, although the small number of the patients is the major limitation of this study and a comparison study with a control group is necessary to prove this concept.

SAM and LVOTO in patients with sigmoid septum

Reports concerning SAM and LVOTO in patients with sigmoid septum are rare. Although the mechanisms of SAM and LVOTO are partly the same as that of HOCM and isolated muscle resection could be sufficient, deterioration of MR after myectomy has been reported [7]. Fujita et al. reported a patient with SAM and LVOTO due to sigmoid septum and normal mitral valve pathology who presented with severe MR just after myectomy [7]. The mitral valve had to be finally replaced in this case. The authors speculated that abnormal papillary muscle attachment might have caused the failure.

Mitral leaflet length was not measured in that report. Interestingly, in the current study, the mitral leaflets of the patients with sigmoid septum were elongated (anterior, 25 mm; posterior, 16 mm which were comparable to those in HOCM) compared to reported normal values (anterior, 19 mm; posterior, 10 mm) [21]. The abnormal papillary muscle attachment and elongation of the mitral leaflet might have contributed to SAM and LVOTO not only in patients with HOCM but also in patients with sigmoid septum. Although we did not perform mitral valve procedures for patients with sigmoid septum, careful follow-up is necessary to check for recurrence of SAM and MR after myectomy in sigmoid septum.

In conclusion, myectomy with mitral valve surgery is an option for HOCM with a relatively thin interventricular septum. The optimal treatment strategy for sigmoid septum needs to be established.

Acknowledgment

None

Disclosures

The authors declare that there is no conflict of interest.

References

1. Heric B, Lytle BW, Miller DP, Rosenkranz ER, Lever HM, Cosgrove DM. Surgical management of hypertrophic obstructive cardiomyopathy. Early and late results. *J Thorac Cardiovasc Surg* 1995; 110: 195-206; discussion 206-198
2. Cho YH, Quintana E, Schaff HV, et al. Residual and recurrent gradients after septal myectomy for hypertrophic cardiomyopathy-mechanisms of obstruction and outcomes of reoperation. *J Thorac Cardiovasc Surg* 2014; 148: 909-915; discussion 915-906
3. Smedira NG, Lytle BW, Lever HM, et al. Current effectiveness and risks of isolated septal myectomy for hypertrophic obstructive cardiomyopathy. *Ann Thorac Surg* 2008; 85: 127-133
4. McIntosh CL, Greenberg GJ, Maron BJ, Leon MB, Cannon RO, 3rd, Clark RE. Clinical and hemodynamic results after mitral valve replacement in patients with obstructive hypertrophic cardiomyopathy. *Ann Thorac Surg* 1989; 47: 236-246
5. Cooley DA, Leachman RD, Hallman GL, Gerami S, Hall RJ. Idiopathic hypertrophic subaortic stenosis. Surgical treatment including mitral valve replacement. *Arch Surg* 1971; 103: 606-609
6. Song JK. Role of noninvasive imaging modalities to better understand the mechanism of left ventricular outflow tract obstruction and tailored lesion-specific treatment options. *Circ J* 2014; 78: 1808-1815
7. Fujita K, Nakashima K, Kumakura H, Minami K. A Surgical Experience of Symptomatic Sigmoid Septum: Drastic Exacerbation of Mitral Regurgitation after Sufficient Ventricular Septal Myectomy. *Ann Thorac Cardiovasc Surg*

2013:

8. Matsui Y, Shiiya N, Murashita T, Sasaki S, Yasuda K. Mitral valve repair and septal myectomy for hypertrophic obstructive cardiomyopathy. *J Cardiovasc Surg (Torino)* 2000; 41: 53-56

9. Gersh BJ, Maron BJ, Bonow RO, et al. 2011 ACCF/AHA Guideline for the Diagnosis and Treatment of Hypertrophic Cardiomyopathy: a report of the American College of Cardiology Foundation/American Heart Association Task Force on Practice Guidelines. Developed in collaboration with the American Association for Thoracic Surgery, American Society of Echocardiography, American Society of Nuclear Cardiology, Heart Failure Society of America, Heart Rhythm Society, Society for Cardiovascular Angiography and Interventions, and Society of Thoracic Surgeons. *J Am Coll Cardiol* 2011; 58: e212-260

10. Hamada M, Ikeda S, Shigematsu Y. Advances in medical treatment of hypertrophic cardiomyopathy. *J Cardiol* 2014; 64: 1-10

11. Yu EH, Omran AS, Wigle ED, Williams WG, Siu SC, Rakowski H. Mitral regurgitation in hypertrophic obstructive cardiomyopathy: relationship to obstruction and relief with myectomy. *J Am Coll Cardiol* 2000; 36: 2219-2225

12. Lancellotti P, Moura L, Pierard LA, et al. European Association of Echocardiography recommendations for the assessment of valvular regurgitation. Part 2: mitral and tricuspid regurgitation (native valve disease). *Eur J Echocardiogr* 2010; 11: 307-332

13. Messmer BJ. Extended myectomy for hypertrophic obstructive cardiomyopathy. *Ann Thorac Surg* 1994; 58: 575-577

14. Nasser BA, Stamm C, Siniawski H, et al. Combined anterior mitral valve leaflet retention plasty and septal myectomy in patients with hypertrophic obstructive cardiomyopathy. *Eur J Cardiothorac Surg* 2011; 40: 1515-1520
15. Gutermann H, Pettinari M, Van Kerrebroeck C, et al. Myectomy and mitral repair through the left atrium in hypertrophic obstructive cardiomyopathy: the preferred approach for contemporary surgical candidates? *J Thorac Cardiovasc Surg* 2014; 147: 1833-1836
16. Vriesendorp PA, Schinkel AF, Soliman OI, et al. Long-Term Benefit of Myectomy and Anterior Mitral Leaflet Extension in Obstructive Hypertrophic Cardiomyopathy. *Am J Cardiol* 2014:
17. Furukawa K, Hayase T, Yano M. Mitral valve replacement and septal myectomy for hypertrophic obstructive cardiomyopathy. *Gen Thorac Cardiovasc Surg* 2013:
18. Minakata K, Sakata R. Surgical treatment for obstructive hypertrophic cardiomyopathy. *Gen Thorac Cardiovasc Surg* 2014; 62: 184-185
19. Swistel DG, Balaram SK. Surgical myectomy for hypertrophic cardiomyopathy in the 21st century, the evolution of the "RPR" repair: resection, plication, and release. *Prog Cardiovasc Dis* 2012; 54: 498-502
20. Seeburger J, Passage J, Borger MA, Mohr FW. A new concept for correction of systolic anterior motion and mitral valve regurgitation in patients with hypertrophic obstructive cardiomyopathy. *J Thorac Cardiovasc Surg* 2010; 140: 481-483
21. Maron MS, Olivotto I, Harrigan C, et al. Mitral valve abnormalities identified by cardiovascular magnetic resonance represent a primary

phenotypic expression of hypertrophic cardiomyopathy. *Circulation* 2011; 124:

40-47

Figure legends

Figure 1. Schematic of posterior mitral leaflet height reduction (a) and anterior mitral leaflet augmentation and retention plication (b). When the posterior leaflet was elongated (> 20 mm), it was excised and slid to reduce the leaflet height (a). For those with a relatively short posterior leaflet height (< 20 mm), we employed anterior mitral leaflet augmentation with autologous pericardial patch and retention plication by suturing the anterior leaflet to the corresponding posterior annulus to reduce excessive mobility of the anterior mitral leaflet (b). The dotted lines indicate incision lines.

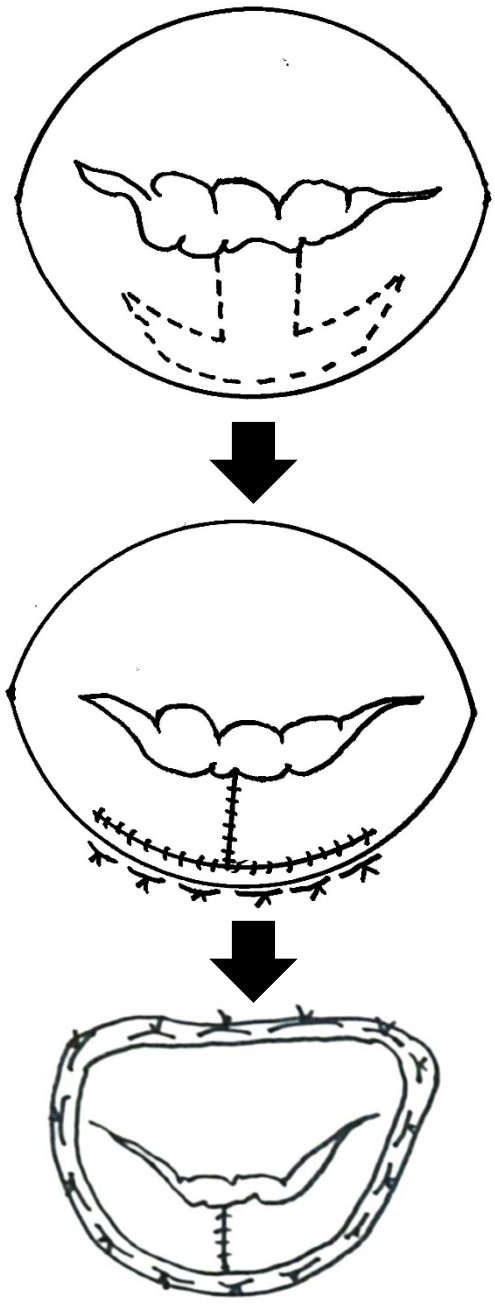
Figure 2. Intraoperative photos showing height reduction of the posterior mitral leaflet. (a, b) elongated posterior mitral leaflet (18 mm) (c, d) reduced height of the posterior mitral leaflet after leaflet plication and ring annuloplasty. LA, left atrium; PML, posterior mitral leaflet.

Figure 3. Representative pre- (a) and postoperative (b) echocardiographic images of an HOCM patient who underwent myectomy, anterior mitral leaflet augmentation, and retention plication. They are both apical 3-chamber views in mid-systole. Moderate MR was reduced to trivial MR after surgery. LVOTO, left ventricular outflow obstruction; MR, mitral regurgitation.

Figure 4. Changes of systolic anterior motion of the mitral valve, maximum LVOT pressure gradient, and MR grade in HOCM patients (a) and those without HOCM (b). LVOT, left ventricular outflow tract; last FU, last echocardiographic follow-up (3 ± 1 and 3 ± 2 years, respectively). * $p < 0.05$ vs. preoperative values.

Fig.1

a



b

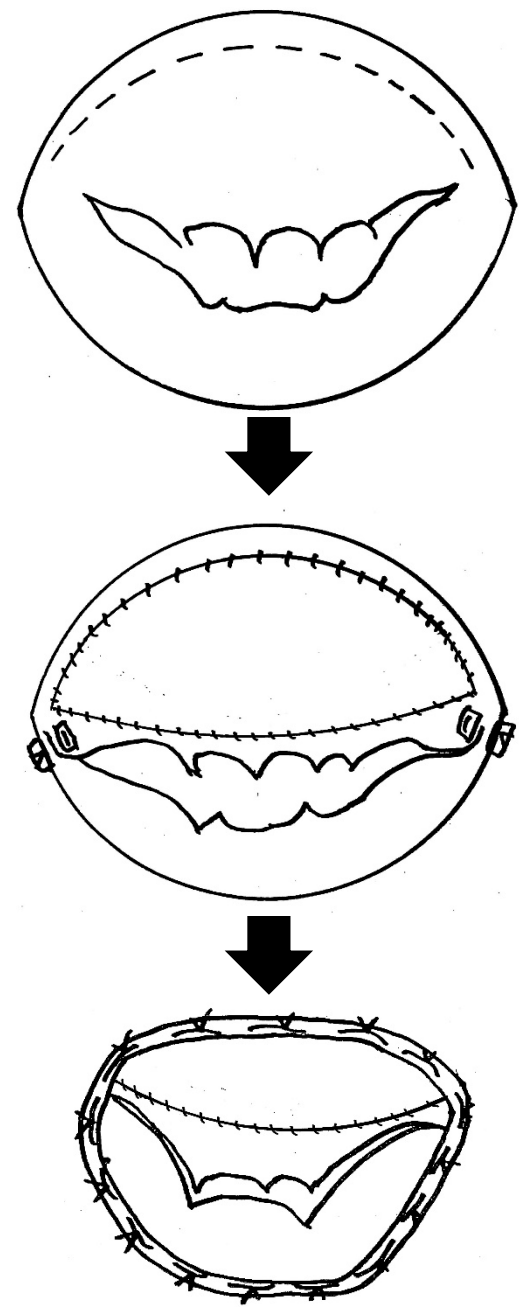


Fig.2

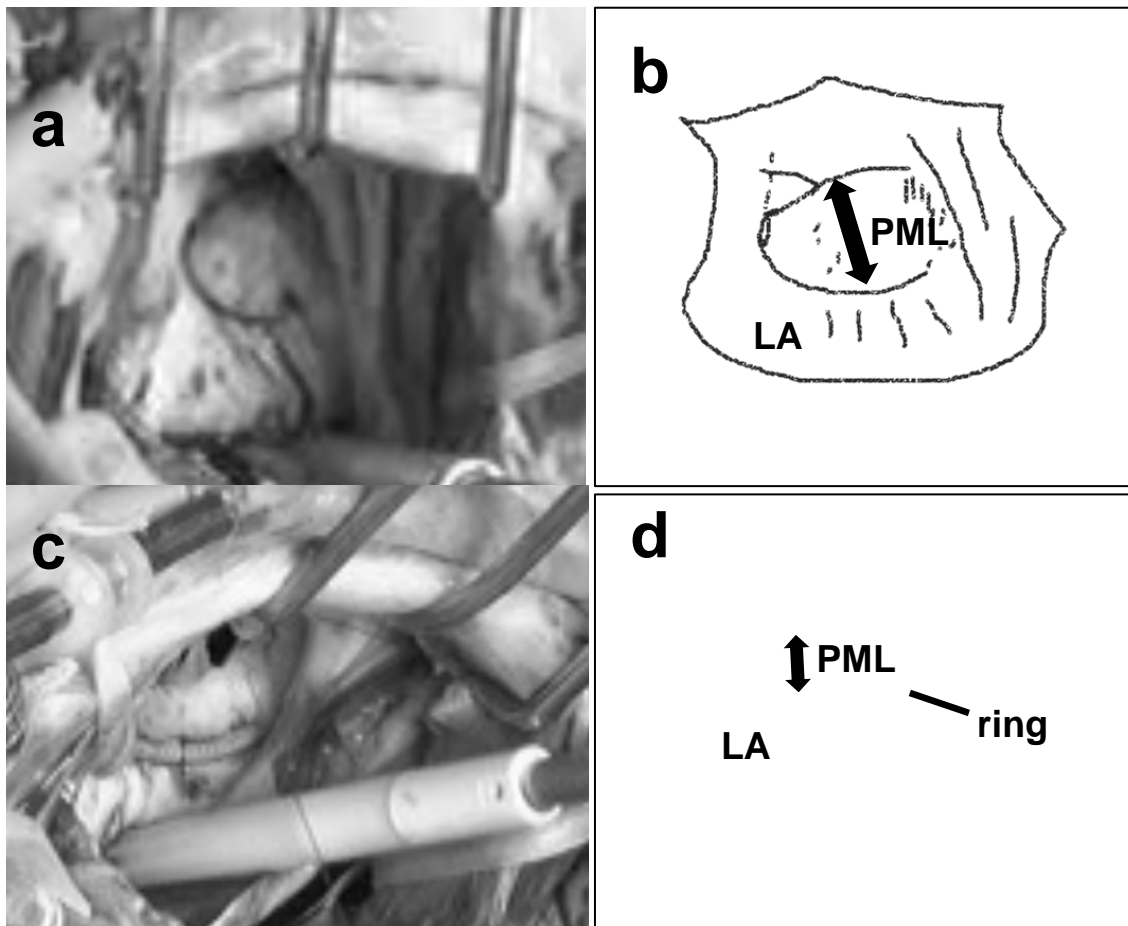
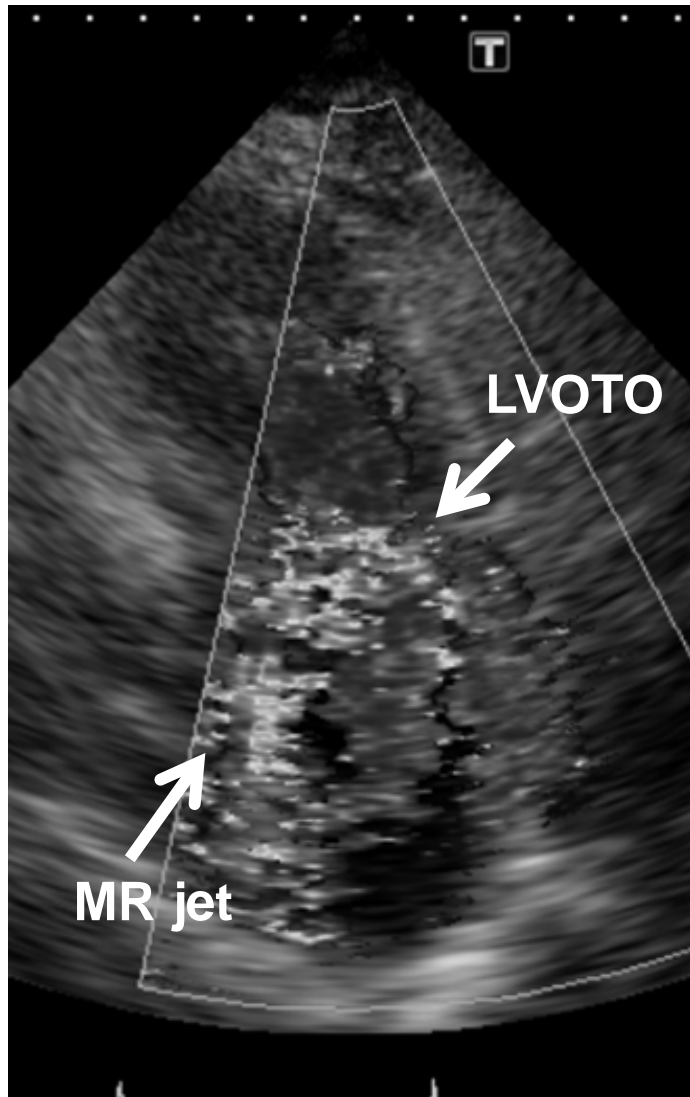


Fig.3

a



b

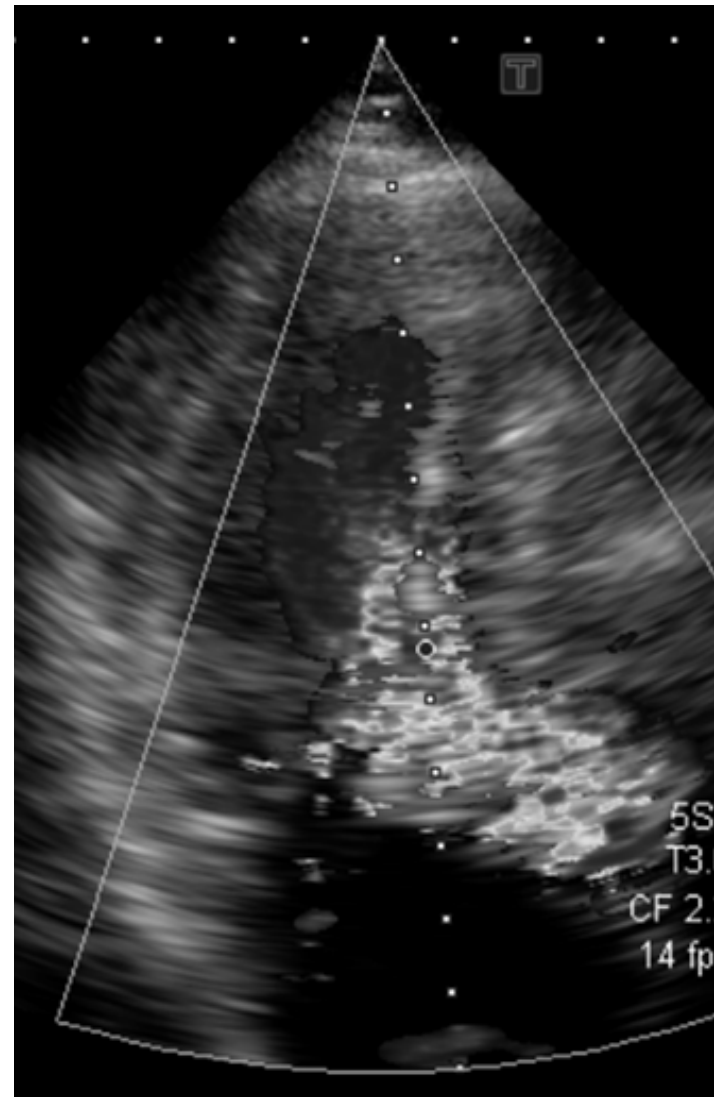
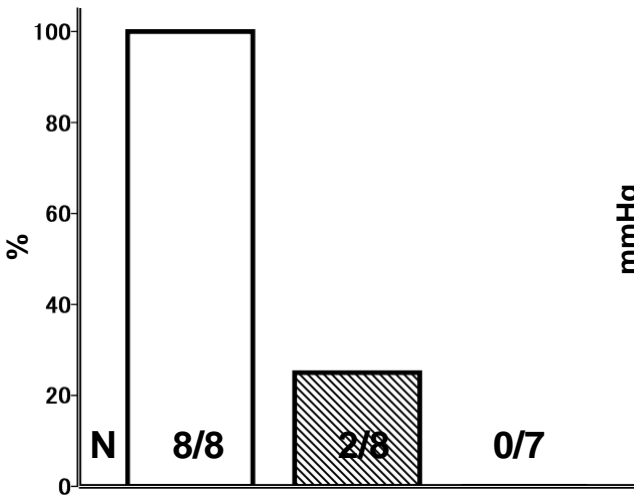
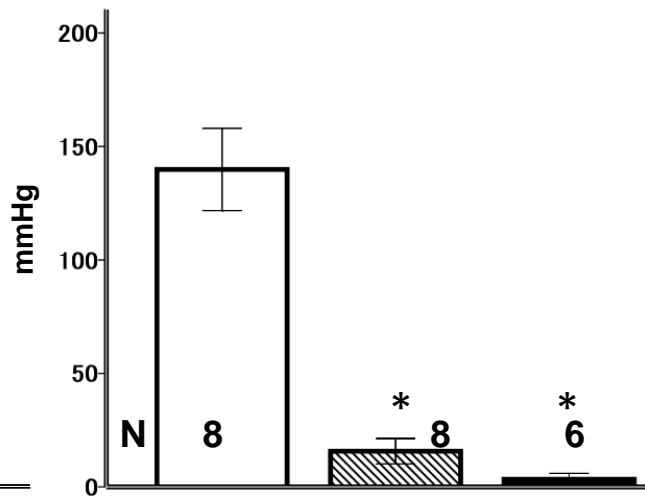


Fig.4

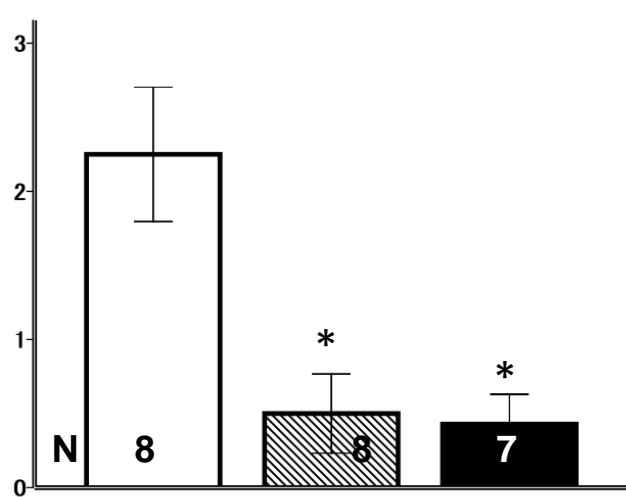
a systolic anterior motion of the mitral valve



max LVOT pressure gradient



mitral regurgitation



b

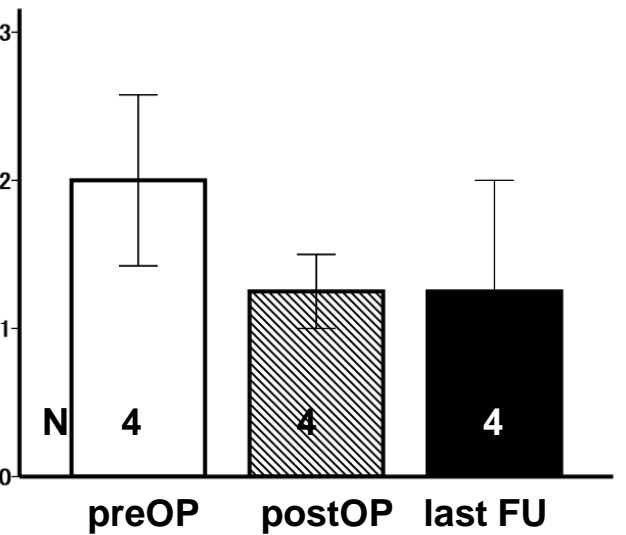
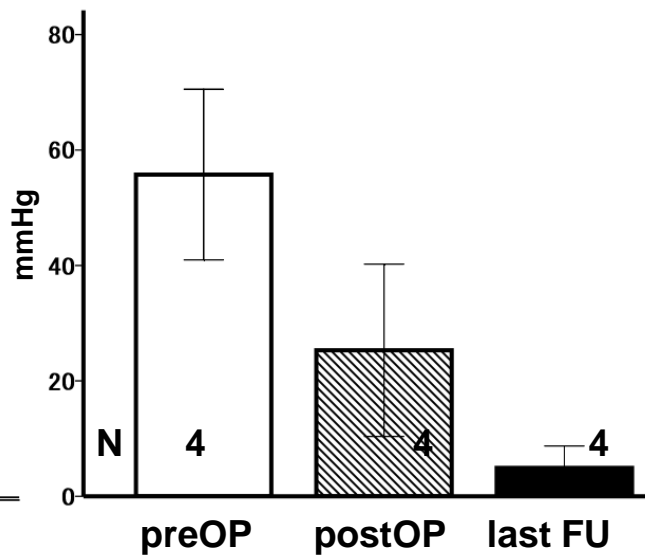
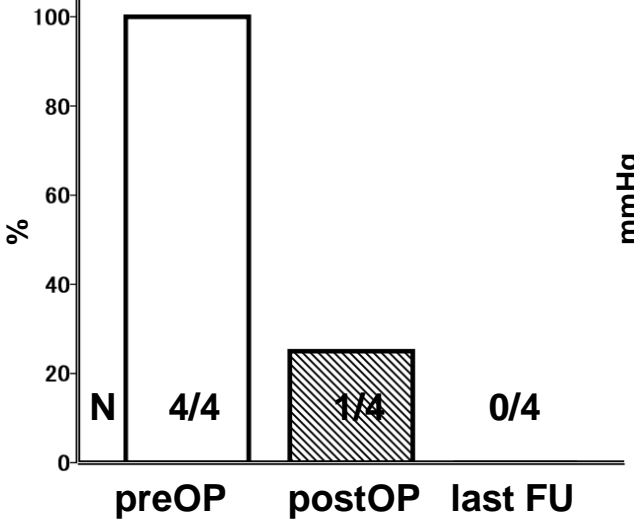


Table 1. Preoperative patients characteristics

	HOCM (n=8)	Others (n=4)
Age	65±3	66±1
Male	2 (25%)	1 (25%)
Medications		
beta blockers	8 (100%)	4 (100%)
disopyramide	4 (50%)	1 (25%)
cibenzoline	1 (13%)	1 (25%)
DDD pace maker	1 (13%)	0 (0%)
NYHA class	2.5±0.4	2.7±0.7
Echocardiography		
LVDd, mm	44±1	49±2
LVDs, mm	26±1	29±2
%FS, %	42±2	39±2
IVST, mm	16±1	13±2
PWT, mm	11±1	12±1
IVST/PWT ratio	1.4±0.1	1.1±0.0
SAM	8 (100%)	4 (100%)
sigmoid septum	0 (0%)	3 (75%)
severe aortic valve stenosis	0 (0%)	2 (50%)
Max LVOTPG, mmHg	140±18	56±15
Mitral regurgitation	2.3±0.5	2.0±0.6
Length of anterior MV, mm	27±2	25±1
Length of posterior MV, mm	19±1	16±2

Values ± standard error of the mean. DDD, dual pacing for both chambers, dual chamber activity sensing, and dual response; FS, fractional shortening; HOCM, hypertrophic obstructive cardiomyopathy; IVST, interventricular septal thickness; LVDd, left ventricular end-diastolic dimension; LVDs, left ventricular end-systolic dimension; LVOTPG, left ventricular outflow tract pressure gradient; MV, mitral valve; NYHA, New York Heart Association; PWT, left ventricular posterior wall thickness; SAM, systolic anterior motion of the mitral valve.

Table 2. Surgical procedures

	HOCM (n=8)	Others (n=4)
Myectomy	8 (100%)	4 (100%)
resected muscle length, mm	38±4	28±5
depth, mm	9±1	8±1
width, mm	10 ± 0.4	11±1
Mitral valve repair	4 (50%)	1 (25%)
posterior leaflet height reduction	3 (38%)	1 (25%)
anterior leaflet augmentation and retention plication	1 (13%)	0
mitral ring annuloplasty	2 (25%)	1 (25%)
Commissurotomy	0	1 (25%)
Mitral valve replacement	3 (38%)	0
due to infective endocarditis	1	-
mitral valve stenosis	1	-
other reason	1	-
Aortic valve replacement	1 (13%)	2 (50%)
Cardiopulmonary bypass time, min	218±34	229±58
Aortic cross clamp time, min	147±27	118±19

Values ± standard error of the mean. HOCM, hypertrophic obstructive cardiomyopathy