HOKKAIDO UNIVERSITY

Title	Cerebellar rotation abnormalities observed in Machado-Joseph Disease
Author(s)	Nomura, Taichi; Iwata, Ikuko; Harada, Taisuke et al.
Citation	Internal Medicine, 59(24), 3253-3254 https://doi.org/10.2169/internalmedicine.5070-20
Issue Date	2020-12-15
Doc URL	https://hdl.handle.net/2115/80002
Rights(URL)	https://creativecommons.org/licenses/by-nc-nd/4.0/
Type	journal article
File Information	59_5070-20.pdf

Hokkaido University Collection of Scholarly and Academic Papers : HUSCAP

Internal Medicine
The Japanese Society of Internal Medicine

doi: 10.2169/internalmedicine.5070-20
Intern Med 59: 3253-3254, 2020
http://internmed.jp

【 PICTURES IN CLINICAL MEDICINE 】

Cerebellar Rotation Abnormalities Observed in Machado-Joseph Disease

Taichi Nomura[1], Ikuko Iwata[1], Taisuke Harada[2] and Ichiro Yabe[1]

Key words: cerebellum, rotation, Machado-Joseph disease, MRI

(Intern Med 59: 3253-3254, 2020)
(DOI: 10.2169/internalmedicine.5070-20)

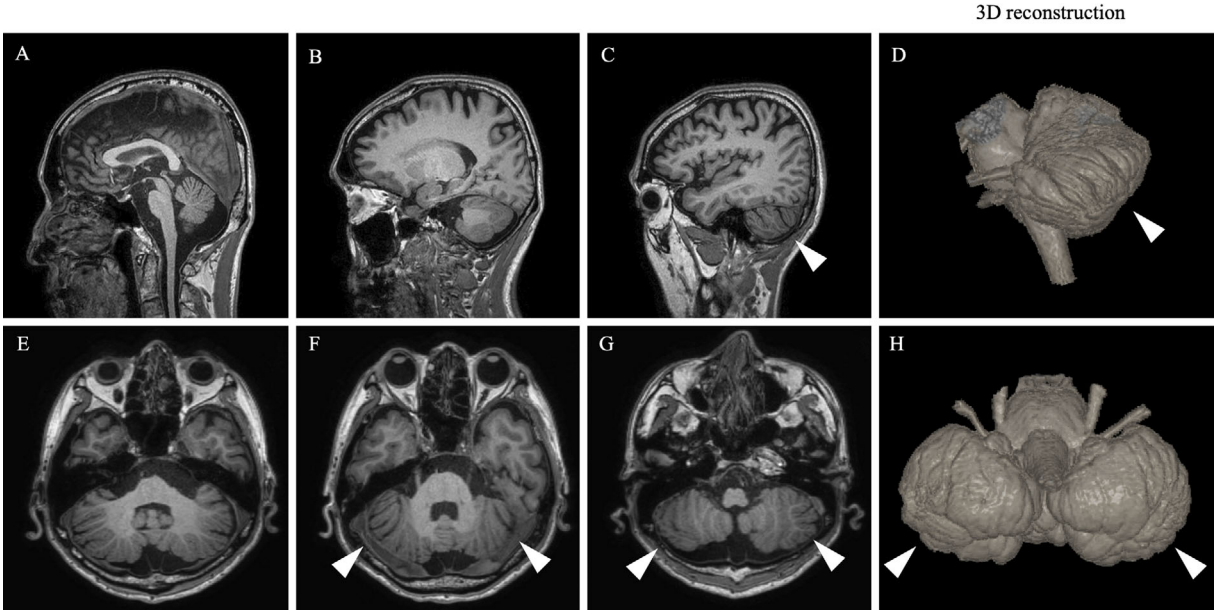

Picture 1.

A 58-year-old man complained of difficulty walking and limb numbness for the past 9 years and gait instability for the past 4 years. He presented with dysarthria, horizontal gaze nystagmus, diminished deep tendon reflex, bilateral Babinski sign, left dominant limb ataxia, and reduced superficial sensation. He reported a family history of autosomal dominant spinocerebellar ataxia and was diagnosed with Machado-Joseph disease (MJD). Magnetic resonance imaging revealed vertical clefts in the bilateral cerebellar hemispheres (arrowheads) with atrophy (Picture 1A-C, E-G), findings that were clarified by three-dimensional reconstructed images (Picture 1D, H), and a normal cerebrum (Picture 2). A genetic analysis showed an expanded ATXN3 allele (60 CAG repeats). Although Blakes's pouch cyst can compress and displace the cerebellum superiorly (1), no cyst or hydrocephalus was observed. Since the length of the CAG repeat is inversely correlated with the onset in MJD (2), the onset in the present case was earlier than in MJD patients with 60 repeats. Cerebellar abnormalities may exacerbate ataxia.

The authors state that they have no Conflict of Interest (COI).

Financial Support

This work was supported in part by a Grant-in-Aid for the Research Committee for Ataxic Diseases of the Research on Measures for Intractable Diseases of the Ministry of Health, Welfare and Labour, Japan.

[1]Department of Neurology, Faculty of Medicine and Graduate School of Medicine, Hokkaido University, Japan and [2]Department of Diagnostic Imaging, Hokkaido University Graduate School of Medicine, Japan
Received: April 13, 2020; Accepted: June 29, 2020; Advance Publication by J-STAGE: August 12, 2020
Correspondence to Dr. Ichiro Yabe, yabe@med.hokudai.ac.jp

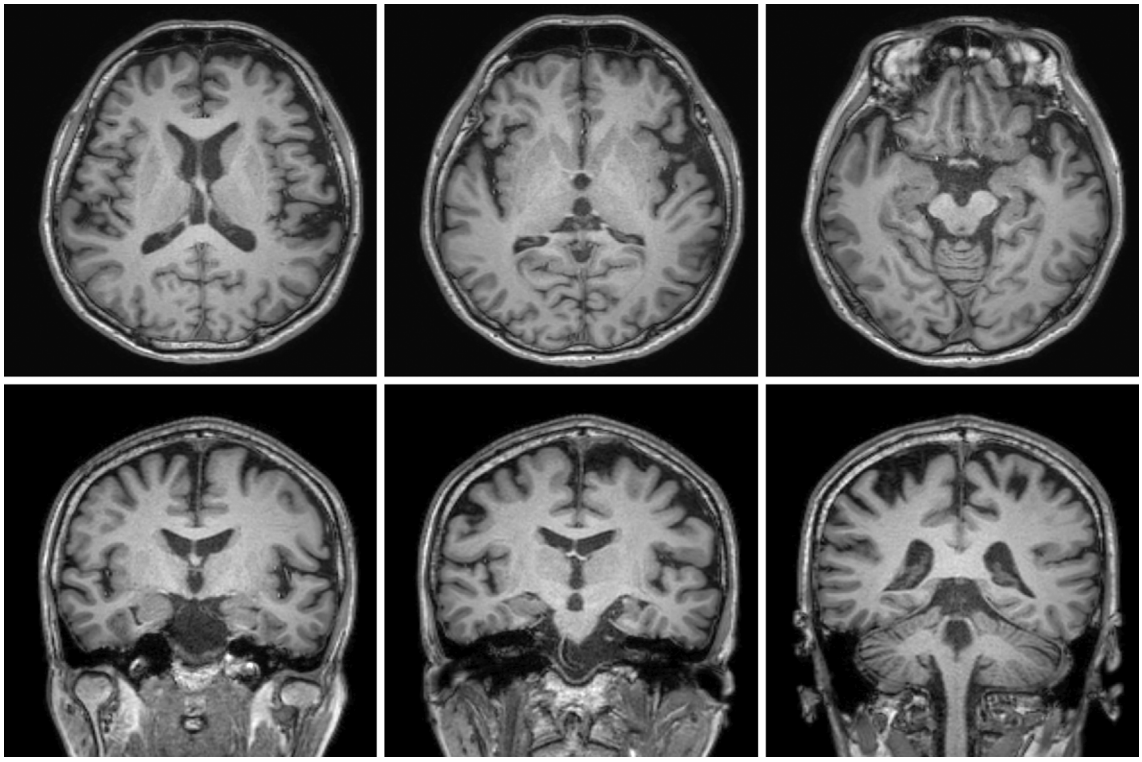

Picture 2.

Acknowledgement

We thank Mari Kimura for her assistance in this study and Azusa Nagai for providing useful advice on the clinical diagnosis.

References

1. Cornips EM, Overvliet GM, Weber JW, et al. The clinical spectrum of Blake's pouch cyst: report of six illustrative cases. Childs Nerv Syst **26**: 1057-1064, 2010.
2. Maruyama H, Nakamura S, Matsuyama Z, et al. Molecular features of the CAG repeats and clinical manifestation of Machado-Joseph disease. Hum Mol Genet **4**: 807-812, 1995.

The Internal Medicine is an Open Access journal distributed under the Creative Commons Attribution-NonCommercial-NoDerivatives 4.0 International License. To view the details of this license, please visit (https://creativecommons.org/licenses/by-nc-nd/4.0/).

© 2020 The Japanese Society of Internal Medicine