HOKKAIDO UNIVERSITY

Title	Reversible Cerebral Angiopathy after Viral Infection in a Pediatric Patient with Genetic Variant of RNF213
Author(s)	Echizenya, Ikuma; Tokairin, Kikutaro; Kawabori, Masahito et al.
Citation	Journal of stroke & cerebrovascular diseases, 29(2), 104549 https://doi.org/10.1016/j.jstrokecerebrovasdis.2019.104549
Issue Date	2020-02
Doc URL	https://hdl.handle.net/2115/80321
Rights	© 2019. This manuscript version is made available under the CC-BY-NC-ND 4.0 license http://creativecommons.org/licenses/by-nc-nd/4.0/
Rights(URL)	https://creativecommons.org/licenses/by-nc-nd/4.0/
Type	journal article
File Information	Echizenya2019.pdf

Hokkaido University Collection of Scholarly and Academic Papers : HUSCAP

Reversible Cerebral Angiopathy after Viral Infection in a Pediatric Patient with Genetic Variant of *RNF213*

Abstract

Ring finger protein (*RNF)213* is known as a susceptibility gene for moyamoya disease (MMD), which is characterized by bilateral carotid folk stenosis. Cerebral angiopathy after viral infection has been known to present angiographical appearance resembling MMD, however its pathogenesis and genetic background are not well known. We report a case of reversible cerebral angiopathy after viral infection in a pediatric patient with genetic variant of *RNF213* mutation. The patient had developed a severe headache after hand, foot, and mouth disease. Magnetic resonance imaging and magnetic resonance angiography (MRA) performed 2–3 weeks after disease onset revealed bilateral carotid folk stenosis and an old cerebral infarction in the left putamen. The patient's headache spontaneously resolved and the follow-up MRA showed a complete spontaneous resolution of the arterial stenosis after 9 months. We were able to determine genetic predisposition to angiopathy by identifying the *RNF213* c.14576G>A (rs112735431, p.R4859K) mutation. Based on the present case, we hypothesize that an *RNF213* variant might play an important role for the onset of post-viral cerebral angiopathy.

Keywords: cerebral angiopathy; moyamoya disease; *RNF213*; hand, foot, and mouth disease; enterovirus; viral infection.

Case Description

A 6-year-old Japanese boy without prior health problems or family history of stroke or moyamoya disease (MMD) visited a pediatric clinic due to severe headache. He had been diagnosed with hand, foot, and mouth disease (HFMD) 2–3 weeks prior and has had a persistent severe headache since. Magnetic resonance imaging (MRI) revealed an old cerebral infarction in the left putamen and magnetic resonance angiography (MRA) showed bilateral stenosis of the terminal portion of the internal carotid arteries (ICAs), middle cerebral arteries (MCAs), and anterior cerebral arteries (ACAs) (Fig. 1A, B).

The patient was referred to our hospital for further examination. However, the headache resolved and the follow-up MRA after 2 months revealed resolution of the bilateral ICA and MCA stenosis, with residual stenosis in the left proximal ACA (Fig. 1C). The follow-up MRA after 9 months showed no apparent cerebral artery stenosis, including the left ACA (Fig. 1D). Genotyping by Sanger sequencing revealed a heterozygous allele of the variant ring finger protein *(RNF)213* c.14576G>A (rs112735431, p.R4859K).

Discussion

Cerebral angiopathy, including ischemic stroke, has been reported after some viral infections such as herpesviruses, varicella zoster virus, adenovirus, parvovirus B19, rhinovirus, and influenza virus (1-5). HFMD is typically caused by enterovirus 71 or coxsackie virus, but is usually diagnosed based only on the clinical features, without serological viral detection, as in the present case. Piccolo et al. reported a case of cerebral angiopathy after enterovirus infection, but the diagnosis was not HFMD and further virus subtype determination was not performed (6). To the best of our knowledge, this is the first report of cerebral angiopathy after HFMD. We speculate

that progressive cerebral artery stenosis during the disease acme induced the severe headache and cerebral infarction in the present case.

Interestingly, the patient was found to have genetic variant of *RNF213*, which is associated with susceptibility to cerebral angiopathy, such as MMD or atherosclerotic stenosis (7-10). This is also the first report that associates post-viral angiopathy to genetic variant of *RNF213*. It is speculated that pediatric patients with this variant could harbor covert cerebral arteriopathy after viral infections. The present case suggests that genetic variant of *RNF213* is potentially common pathological pathway in both viral-induced cerebral angiopathy and MMD regarding their similar angiographical appearance of bilateral carotid folk stenosis. Therefore, identifying an *RNF213* variant may have a crucial role in detecting patients who could develop angiopathy or MMD after viral infections.

Conflicts of interest

None.

Funding

This research was supported by the JSPS KAKENHI (Grant Number 18K08931).

References

1. Forbes HJ, Williamson E, Benjamin L, et al. Association of herpesviruses and stroke: Systematic review and meta-analysis. PLoS One 2018;13:e0206163.

2. Helmuth IG, Mølbak K, Uldall PV, et al. Post-varicella arterial ischemic stroke in Denmark 2010 to 2016. Pediatr Neurol 2018;80:42-50.

3. Kutlesa M, Tesović G, Knezović I, et al. Ischemic stroke associated with adenoviral infection in a 4-year-old boy. Wien Klin Wochenschr 2009;121:776-779.

4. Fullerton HJ, Luna JM, Wintermark M, et al. Parvovirus B19 Infection in children with arterial ischemic stroke. Stroke 2017;48:2875-2877.

5. Bell ML, Buchhalter JR. Influenza A-associated stroke in a 4-year-old male. Pediatr Neurol 2004;31:56-58.

6. Piccolo B, Barsacchi M, Greco F, et al. Transient posterior cerebral arteriopathy: An unusual case enterovirus-related. Brain Dev 2019;41:214-216.

7. Kamada F, Aoki Y, Narisawa A, et al. A genome-wide association study identifies RNF213 as the first Moyamoya disease gene. J Hum Genet 2011;56:34-40.

8. Liu W, Morito D, Takashima S, et al. Identification of RNF213 as a susceptibility gene for moyamoya disease and its possible role in vascular development. PLoS One 2011;6:e22542.

9. Fujimura M, Sonobe S, Nishijima Y, et al. Genetics and biomarkers of moyamoya disease: Significance of RNF213 as a susceptibility gene. J Stroke 2014;16:65-72.

10. Miyawaki S, Imai H, Shimizu M, et al. Genetic variant RNF213 c.14576G>A in various phenotypes of intracranial major artery stenosis/occlusion. Stroke 2013;44:2894-2897.

Figure legends

Figure 1. Chronologic presentation of the MRI and MRA findings. (A) Fluid-attenuated inversion recovery image performed 2–3 weeks after headache onset revealed an old cerebral infarction in the left putamen (arrow). The lesion did not present a high-intensity signal on diffusion weighted

imaging, indicating acute cerebral infarction, nor a low-intensity signal in T2 star-weighted images, suggesting a hemorrhagic change (these are not shown). (B) Initial MRA performed at the same time revealed bilateral stenotic changes in the distal ICAs and in the proximal portions of the ACAs and MCAs (solid arrowheads). (C) MRA performed after 2 months showed spontaneous resolution of the bilateral ICA and MCA and the right ACA stenosis, with a residual left ACA stenosis (open white arrowhead). (D) MRA performed after 9 months showed complete disappearance of the arterial stenosis.

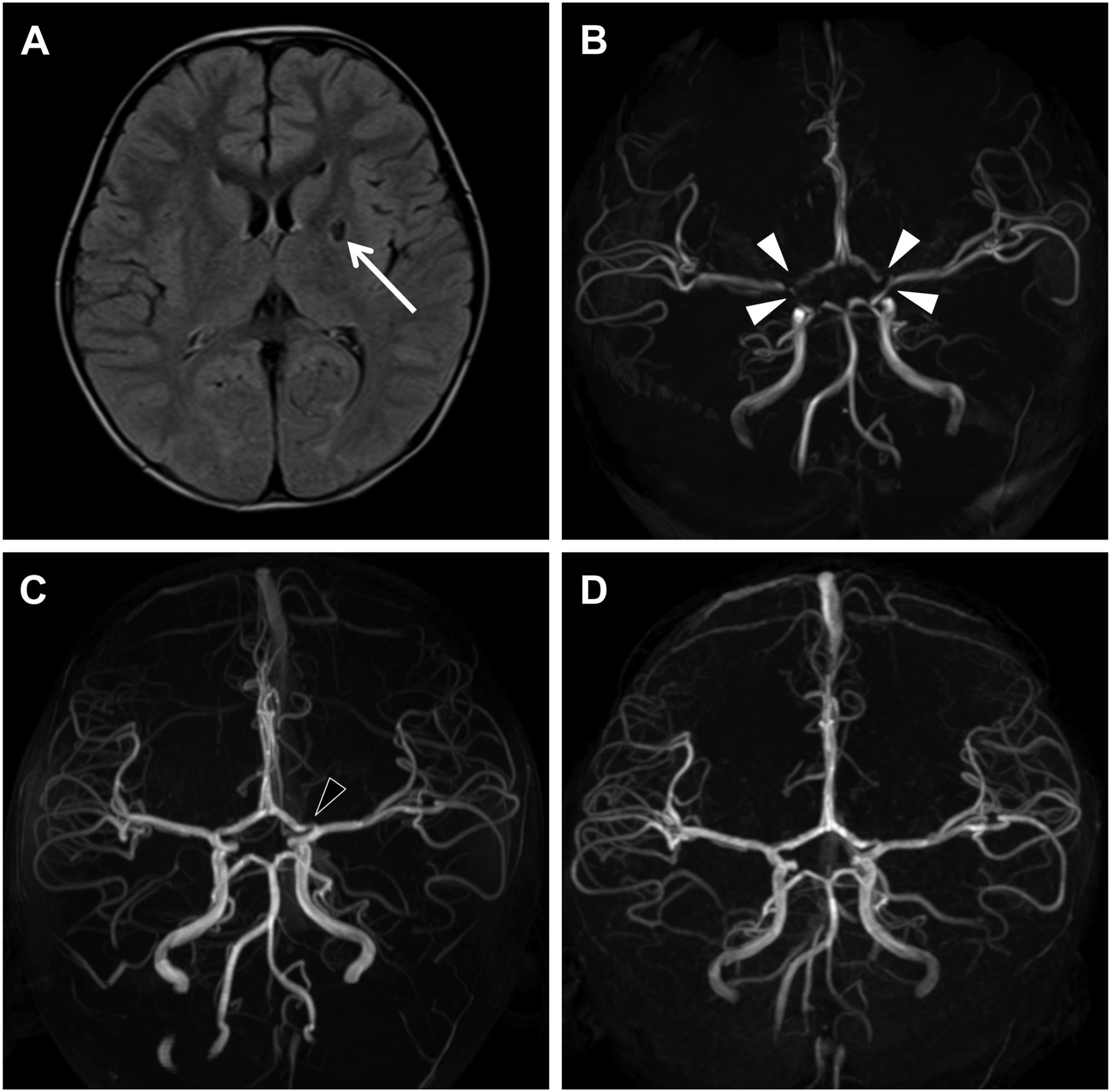
A
B
C
D