



HOKKAIDO UNIVERSITY

Title	Ovulatory follicle size investigated by ultrasonography and single artificial insemination with ovulation induction in the Japanese macaque (<i>Macaca fuscata</i>)
Author(s)	Takaesu, Noboru; Minami, Masako; Nagano, Masashi et al.
Citation	Japanese Journal of Veterinary Research, 70(1), 5-17
Issue Date	2022-02
DOI	https://doi.org/10.14943/jjvr.70.1.5
Doc URL	https://hdl.handle.net/2115/84410
Type	departmental bulletin paper
File Information	JJVR70-1_5-17_NoboruTakaesu_MasakoMinami.pdf



Ovulatory follicle size investigated by ultrasonography and single artificial insemination with ovulation induction in the Japanese macaque (*Macaca fuscata*)

Noboru Takaesu¹⁾, Masako Minami^{2,†)}, Masashi Nagano³⁾, Akihisa Kaneko⁴⁾, Yoriko Indo⁴⁾, Hiroo Imai⁴⁾, Hirohisa Hirai⁴⁾, Mariko Sashika¹⁾, Michito Shimozuru¹⁾, Munehiro Okamoto⁴⁾, Seiji Katagiri²⁾, Toshio Tsubota¹⁾ and Yojiro Yanagawa^{2,*)}

¹⁾Laboratory of Wildlife Biology and Medicine, Graduate School of Veterinary Medicine, Hokkaido University, Sapporo, Hokkaido 060-0818, Japan

²⁾Laboratory of Theriogenology, Graduate School of Veterinary Medicine, Hokkaido University, Sapporo, Hokkaido 060-0818, Japan

³⁾Laboratory of Animal Reproduction, School of Veterinary Medicine, Kitasato University, Towada, Aomori 034-8628, Japan

⁴⁾Primate Research Institute, Kyoto University, Inuyama, Aichi 484-8506, Japan

Received for publication, December 12, 2021; accepted, December 29, 2021

Abstract

In the Japanese macaque, artificial insemination (AI) has been successful, but it required repeated AI two to three times a day under anesthesia until ovulation was confirmed by laparoscopy. To reduce this invasiveness, the ovulation timing and size of preovulatory follicle need to be elucidated. However, ovulatory follicle size is not well understood as monitoring ovarian dynamics using ultrasonography has never been performed in this species. Further, although ovulation induction facilitates establishing the AI protocol, the effect of gonadotropin releasing hormone (GnRH) on ovulation induction has not been studied. Monitoring of ovarian dynamics by ultrasonography of six spontaneous ovulations clarified that the diameter of the ovulatory follicle before ovulation was 7.4 ± 1.5 (5.1–9.6 mm) and that ovulation occurred from Day 12 to 14 of the menstrual cycle. The effect of GnRH on ovulation induction was monitored in three monkeys, and one day after GnRH administration ovulations were induced with follicles of diameter of 4.7–7.4 mm. Further, AI with ovulation induction by GnRH was performed seven times using four females. Semen were inseminated in the uterus in four cases and into the cervix in three between Day 8 to 14 of the menstrual cycle. Only one female inseminated in the uterus on Day 12 became pregnant, but fetal development stopped at around 50 days of gestation. The present study investigated a less invasive single AI protocol with ovulation induction in the Japanese macaque, and the insemination technique needs to be developed further to improve the pregnancy rate.

Key Words: Artificial insemination, Japanese macaque, Ovarian dynamics, Ovulation induction, Ultrasonography

* Corresponding author:

Yojiro Yanagawa

Laboratory of Theriogenology, Graduate School of Veterinary Medicine, Hokkaido University, Sapporo, Hokkaido 060-0818, Japan

TEL/FAX: +81-11-706-5232

E-mail: yoji-y@vetmed.hokudai.ac.jp

† Contributed equally to the first author

doi: 10.14943/jjvr.70.1.5

Introduction

The Japanese macaque (*Macaca fuscata*) is species endemic to Japan. It is a popular zoo animal and is usually kept as a troop including both males and females in order to imitate their natural habitat. They are short day seasonal breeders, with males and females reaching sexual maturity at about four years of age and usually produce offspring every other year^{23,26} and the fecundity decreases around 20 years old^{23,26}. Since they breed successfully under captive conditions, their high fertility and mixed sex troop often result in overpopulation^{3,12}. Castration and vasectomy for males and implantation of slow release progesterone capsules for females are widely used to prevent breeding, but these approaches sometimes fail because of unintentional recanalization and removal of implants. Poor genetic diversity is also a common problem due to repeated reproduction in a closed colony of the Japanese macaque. Further the clannish nature of troops, in which introduced animals are often attacked and killed, makes the problem even more difficult³. For reproductive management, artificial insemination (AI) is a common technique in domestic animals¹⁸ and it has been applied to zoo animals including primates^{2,16} to limited extent. Well-planned contraception also contributes to appropriate reproductive management of captive Japanese macaque in zoos.

Successful AI has been reported in the Japanese macaque⁴⁰. Laparoscopic ovarian observation and AI under anesthesia were repeated several times until ovulation⁴⁰, but this protocol is not suitable for practical and routine use in zoos due to its invasiveness. In one study, animals conceived following at least two successive AIs on the day before and on the day of ovulation⁴⁰. Further, a single AI on the expected ovulation day³⁵ resulted in a pregnancy in the cynomolgus macaque (*Macaca fascicularis*). Therefore, to establish a single AI protocol, detection of timing of ovulation is important. The menstrual cycle is 25.3 ± 2.8 days²¹ and ovulation

timing ranges from Day 11 to 16 of the menstrual cycle²² which can be estimated by monitoring plasma estradiol or urinary estrogen metabolites in the Japanese macaque⁹. However, repeated sample collection and measurement to monitor these hormones are difficult in zoos, where they are kept in troops. Therefore, AI in combination with hormonal treatment for ovulation induction could lead to a single AI protocol for the Japanese macaque.

For ovulation induction, information about the ovarian dynamics, including the size of ovulatory follicles and the time it takes the follicle to reach a possible ovulation size is needed. Nigi (1977)²¹ reported morphological changes in follicles during the course of ovulation by laparoscope in the Japanese macaque, but the sizes of ovulatory follicles were not examined. Ultrasonography is commonly used to investigate ovarian dynamics during the estrous cycle in domestic animals^{28,29}, but it has never been performed in the Japanese macaque. In non-human primates, ultrasonographic observation of ovaries has been reported in some species to monitor their response to exogenous gonadotropin^{5,37,43}, but not in the Japanese macaque. Ovarian dynamics during the menstrual cycle have been investigated in the rhesus macaque (*Macaca mulatta*)^{5,19} and the cynomolgus macaque⁴¹. The mean diameter of ovulatory follicles before ovulation was about 6–7 mm and the follicular phase was about 14 days during a spontaneous cycle in rhesus and cynomolgus macaques. Since their menstrual cycle time and mean litter size (one) are almost the same with the Japanese macaque, the ovulatory follicle size might be similar to the Japanese macaque, but there may be differences because of their different body sizes (the Japanese macaque is larger than rhesus and cynomolgus macaques).

Ovulation induction using human chorionic gonadotropin (hCG) was previously reported in the Japanese macaque during the non-mating season under complete exogenous hormonal control of follicle development³⁹. However, repeated use of hCG is known to produce antibodies, even in

humans^{1,6,36,38}), which can neutralize the hCG and prevent the ovulatory effect. Furthermore, acquiring anti-hCG antibodies may affect maternal physiology, since macaque CG cross reacts with anti-hCG antibodies²⁰). On the other hand, gonadotropin releasing hormone (GnRH) has no antigenicity⁴) and is used for ovulation induction in various domestic animals⁸) without the detrimental effect of hCG. Further, the structure of GnRH is common among mammals^{17,34}). Therefore, the ovulatory effect of GnRH and the sensitive follicle size should be investigated in the Japanese macaque.

In the present study, to establish an AI protocol in the Japanese macaque, ovarian dynamics during the menstrual cycle were investigated by ultrasonography together with changes in ovarian steroid hormones. Further, the ovulatory effect of GnRH was evaluated, and a single AI was performed simultaneously.

Materials and Methods

Animals

Six female (5–11 years old) and four male (11–17 years old) Japanese macaques (*Macaca fuscata*) kept at the Primate Research Institute, Kyoto University (Inuyama, Aichi 484-8506, Japan), were used in the present study. Monkeys were kept in individual cages and fed on pellets for monkeys (Primate Diets AS, Oriental Yeast Co., Ltd, Tokyo) and a small amount of supplemental food (sweet potatoes, bananas, apples and peanuts). Water was supplied *ad libitum*. Estrus behavior of monkeys was observed for 15 min twice a day (at 9:00 and 15:00). The start of a menstrual period was defined as a day when any menstrual blood spotted on the floor or inside the cage was observed and this day was determined to be Day 1 of menstrual cycle. All experiments were approved by the Animal Welfare and Animal Care Committee, Primate Research Institute, Kyoto University (No. 2013-089, 2015-037, 2016-013, 2017-047).

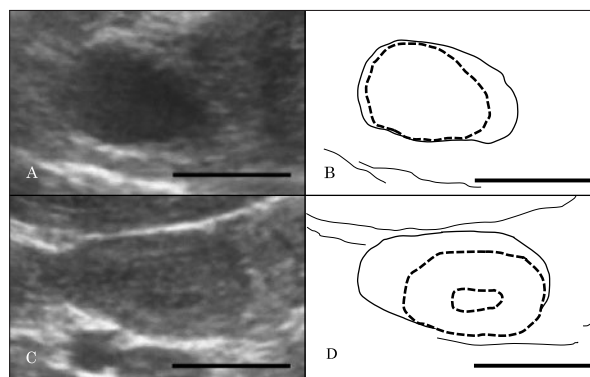


Fig. 1.

(A) An ultrasonographic image and (B) an illustration of an ovary with a dominant follicle at one day before ovulation. The diameter of follicle was 9.6 mm. (C) An ultrasonographic image and (D) an illustration of an ovary with a corpus luteum (CL) at six days after ovulation. The diameter of CL was 9.5 mm. Dotted line indicates structure (follicle or CL) in the ovary. bar = 10 mm

Ultrasonography of the ovaries and definition of ovulation

The ovaries were examined using an ultrasonography device (Prosound SSD-3500SX, Hitachi Aloka Medical, Ltd., Tokyo, Japan) attached to a convex transducer (UST-987-7.5, Hitachi Aloka Medical, Ltd.) via the abdominal wall without anesthesia. The monkey was restrained by a squeeze cage in the sitting position. The movies of the ovary were recorded on a PC attached to the ultrasonography device using image analyzing software (CyberLink PowerDirector 10, CyberLink Corp., Tokyo Japan). The number and size (mm) of follicles and corpora lutea (CLs), and their relative positions in the ovaries were recorded (Fig. 1). The dominant follicle was defined as a follicle that reached the maximum diameter during the follicular phase. Ovulation was defined as the disappearance of the dominant follicle or a distinct reduction in the diameter of the dominant follicle. The day of ovulation was defined as the next day of the last observation of the dominant follicle before ovulation confirmation.

Sample collection

Peripheral blood was collected from the

cephalic vein using a syringe containing 15 μ l/ml heparin. Collected blood was centrifuged at $1,100 \times g$ for 20 min at 4°C and the plasma was stored at -30°C until assays. Feces were collected by placing a tray under the individual cage around 16:00 and feces on the tray were sampled at 9:00 the next day and stored at -30°C .

Steroid hormone assay

Steroid hormone in plasma was extracted with diethyl ether and reconstituted with a buffer⁴²⁾. The feces were prepared as described previously¹³⁾ with slight modification. Briefly, feces were dried in a drying oven at 100°C for 24 hr and pulverized. Then, 0.1 g of the fecal powder was vortexed for 30 min in 5 ml of 80% methanol at room temperature and centrifuged at 4°C and $1190 \times g$ for 10 min to collect the supernatant used as the assay sample. Plasma and fecal concentrations of estradiol- 17β (E_2) and progesterone (P_4) were determined using competitive double antibody enzyme immunoassays as previously described⁴²⁾ with slight modification. Goat anti-rabbit serum (111-005-003, Jackson Immuno Research, Pennsylvania, USA), anti E_2 antibody (QF-121, Teikoku Hormone Mfg. Co., Ltd., Kanagawa, Japan), anti P_4 antibody (KZ-HS-P13, Cosmo Bio, Tokyo, Japan) and steroid hormone labeled by horseradish peroxidase were used. The intra and inter assay coefficients of variation were 4.0% and 5.1% for E_2 and 5.8 and 8.6% for P_4 , respectively. The plasma hormone concentration was recorded as the quantity per 1 ml of plasma and fecal hormone was recorded as the quantity per 1 g of dried feces.

Anesthesia

Monkeys were anesthetized with a combination of ketamine hydrochloride (5 mg/kg Ketamine Injection 5% Fujita, Fujita Pharmaceutical Co., Ltd., Tokyo, Japan), medetomidine hydrochloride (25 μ g/kg, Medetomine Injection Meiji, Fujita Pharmaceutical Co., Ltd.), and midazolam (125 μ g/kg, Midazolam Injection 10 mg Sandoz, Sandoz

K. K., Tokyo, Japan). All the drugs for anesthesia were administered intramuscularly. After the examination, 0.0625 mg/kg atipamezole (Mepatia injection Meiji, Fujita Pharmaceutical Co., Ltd.) was administered intramuscularly to antagonize the effects of medetomidine hydrochloride.

Semen collection and evaluation

Semen collection was carried out via electro-ejaculation. A handmade rectal probe with two longitudinal electrodes connected to an electron stimulator (Fujihira Industry Co., Ltd., Tokyo, Japan) was used. After anesthesia, each monkey was laid in a lateral position and the penis extending beyond the prepuce was washed with physiological saline. Then, the tip of penis was held inside a 50-ml polypropylene conical centrifuge tube (352070; Becton Dickinson, Franklin Lakes, NJ, USA). The rectal probe was lubricated with K-Y jelly (Johnson & Johnson Inc., New Brunswick, NJ, USA) and inserted around 8–10 cm into the rectum. A series of electrical stimuli were applied 10 times in a 3-sec-on/3-sec-off pattern at 5 to 15 V, as described previously¹⁰⁾. Electro stimulus started from 5 V and the voltage was increased by 5 V up to 15 V (5–10–15 V). After the collection, an equivalent volume of Tes-Tris Egg-yolk medium (TTE) to semen was added^{15, 31)}. In one case of semen collection (for AI in ID 2068 on January 15th, 2016), the remaining semen in the urethra after ejaculation was collected by inserting a catheter after electro ejaculation. A 10-MHz probe (HLV-375M; Honda Electronics Ltd., Toyohashi, Japan) attached to an ultrasonography device (HS-1500V; Honda Electronics Ltd.) was introduced into the rectum of each monkey as it lay in a lateral position to visualize the prostate. A 6 Fr polyvinyl chloride plastic catheter with a cap on its proximal end (46006, Atom Medical Corp., Tokyo, Japan) was inserted from the external urethral opening until the tip reached the prostate. After closing the catheter cap, it was retracted slowly. Liquid form semen in the catheter was expelled by flushing with 0.2 ml of TTE medium.

Semen collected by electroejaculation was

Table 1. Information on female monkeys and study items used

Female	Breeding season	Age at research	Parity	Study purpose			
				Menstrual cycle	Spontaneous ovulation	Ovulation induction	Artificial insemination
2068	2013-2014	8	parous	○		○	
	2015-2016	10	parous				○*
	2016-2017	11	parous				○
2099	2013-2014	9	nulliparous		○		
2140	2013-2014	8	nulliparous	○	○	○*	
2249	2013-2014	5	nulliparous		○		
	2016-2017	8	nulliparous				○
2366	2017-2018	9	nulliparous				○
	2017-2018	7	nulliparous				○
2408	2017-2018	7	parous				○

○: Animal used to investigate study items

*: Trials were performed twice during different menstrual cycles

^a If an animal was used for a different purpose in the same breeding season, each test was performed at different times.

Table 2. Day of ultrasonographic observation and diameter of follicles in ovaries during spontaneous and induced ovulation

Study purpose	Female	Breeding season	Day from menses										Diameter of follicle immediately before ovulation [†]			
			7	8	9	10	11	12	13	14	15	16				
Menstrual cycle	2068	2013-2014														7.9 [‡]
	2068	2013-2014			6.1		3.9								8.7	
	2140	2013-2014														5.8 [‡]
Spontaneous ovulation	2140	2013-2014							8.5	ND					8.2	
	2249	2013-2014					5.1					ND			8.2	
	2099	2013-2014							7.6			ND		8.3		
Ovulation induction	2068	2013-2014	3.9	4.8	6.1	7.4*	6.1					8.7				
	2140	2013-2014					4.7	4.7*		4.0		5.6				
	2140	2013-2014		3.0			3.9				5.2*	3.5				
Artificial insemination	2068	2015-2016		6.0* [#]	ND											
	2068	2015-2016			7.7* [#]	5.0										
	2068	2016-2017						7.3* [#]	ND							
	2249	2016-2017						7.6* [#]	ND							
	2249	2017-2018										8.0* [#]	ND			
	2366	2017-2018									10.0* [#]	5.5				
	2408	2017-2018						10.0* [#]	6.2							

^a The menstrual days with numbers or letters are days of ultrasonographic observation, while the number indicates the diameter (mm) of the follicle or corpus luteum.^b Shaded day indicates day of corpus luteum detection.^c The day from menses with box indicates the estimated day of ovulation.^d ND: No apparent structure was detected in the ovaries

*: Day of gonadotropin releasing hormone administration

#: Day of artificial insemination

†: No previous menses were observed as it was the first ovulation of the breeding season.

‡: The follicle size on the day preceding ovulation.

liquefied at 37°C for 30 min and centrifuged at 500 × g for 10 min. After removing most of the supernatant and coagulum, the sperm pellet was resuspended with a small amount of TTE medium and transferred to a 1.5 ml test tube. This process was omitted for liquid form semen collected by catheterization. The semen fractions from all males collected on the day were pooled and centrifuged at 500 × g. The mixed semen was evaluated for

total volume, concentration, total sperm number and motility. Sperm concentrations were examined using a hemocytometer with distilled water containing 0.3% calf serum. The total sperm number was calculated from the concentration and semen volume. The sperm motility was evaluated under light microscopy according to a previous study³¹⁾ with slight modification and the progressive motile sperm rate was calculated. The

Table 3. Condition of females on artificial insemination (AI day, semen preparation for AI and the results

Female	Date of AI	Semen preparation for AI				Condition of female and AI procedure			
		Number of donor males	Semen concentration ($\times 10^6/\text{ml}$)	Progressive motile sperm count ($\times 10^6$)	Progressive motile sperm (%)	Day of menstrual cycle at AI	Diameter of dominant follicle (mm)	Insemination site	Result
2068	2015/11/19	2	151	14.8	32	8	6.0	uterus	not pregnant
	2016/1/15	1*	210	61.0	55	9	7.7	uterus	not pregnant
	2017/2/6	2	900	27.0	30	12	7.3	uterus	pregnant
2249	2017/3/16	2	332	14.9	30	12	7.6	uterus	not pregnant
	2018/3/7	3	3000	225.0	15	14	8.0	cervix	not pregnant
2366	2018/3/7	3	3000	225.0	15	13	10.0	cervix	not pregnant
2408	2018/3/7	3	3000	225.0	15	11	10.0	cervix	not pregnant

^a Dominant follicle: The follicle of maximum size on the AI day.
 *: Semen was collected by electro-ejaculation and catheterization.

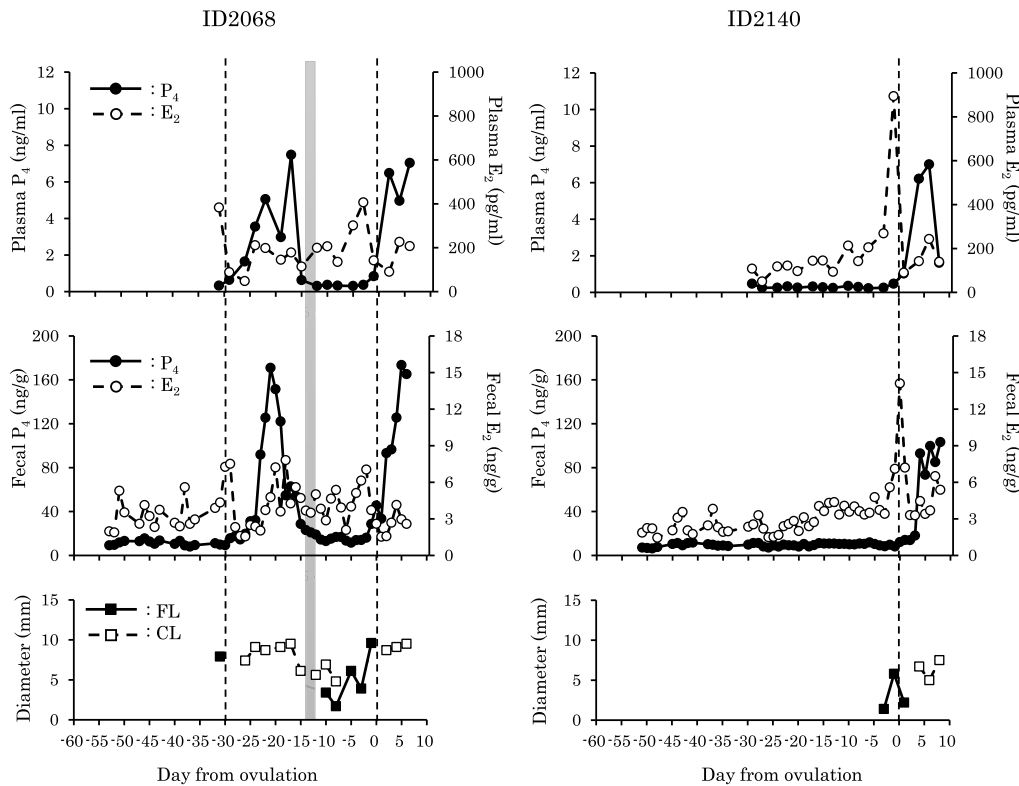


Fig. 2. Hormonal and ovarian dynamics of female monkeys with menstrual cycle monitoring. Broken line indicates ovulation day. Shaded box indicates menses. P₄: Progesterone, E₂: Estradiol-17 β , FL: Follicle, CL: Corpus luteum

semen were kept at 25°C in a water bath for up to 1 hr until insemination.

AI

The immobilized females were laid in an abdominal position and the peri-vaginal area was sterilized. Visualizing the external uterine orifice using a vaginal speculum, the tip of a custom-

ordered 120 mm long stainless animal feeding needle, with a round tip of 0.9 mm in diameter was inserted into the uterine cavity with manipulation of the cervix by finger rectal palpation. Then, a syringe filled with diluted semen was connected to the needle and 100–150 μl of semen was inseminated. If insertion into the uterus was impossible due to a complex cervical structure,

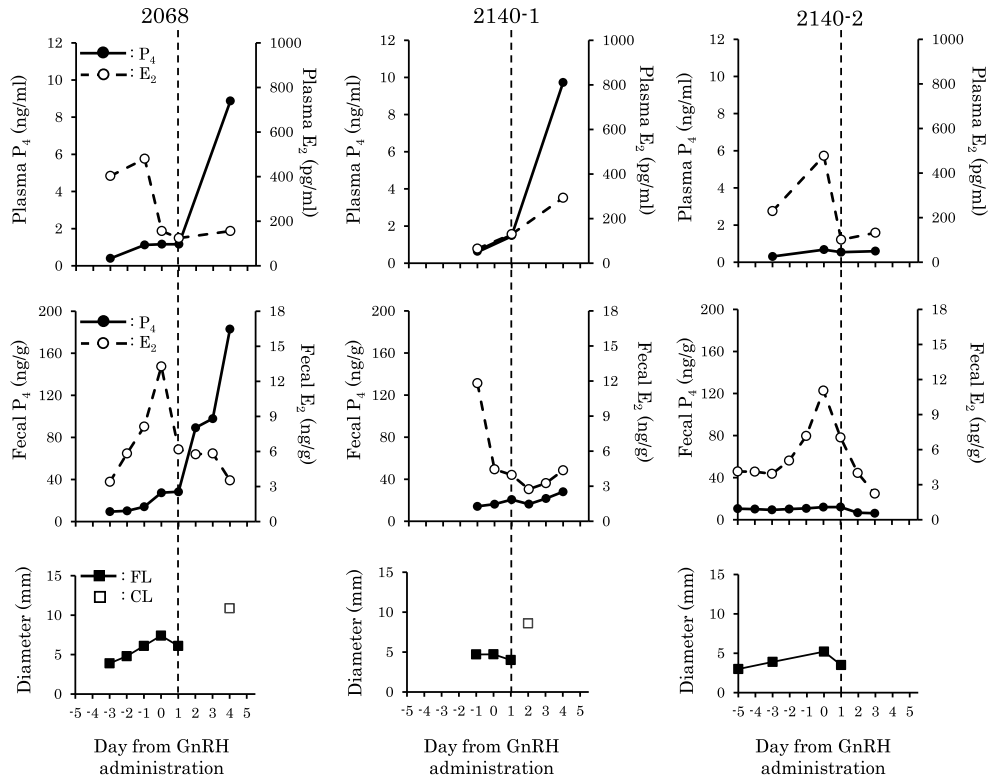


Fig. 3. Hormonal and ovarian dynamics of female monkeys subjected to ovulation induction by gonadotropin releasing hormone (GnRH). Broken line indicates ovulation day. P₄: Progesterone, E₂: Estradiol-17 β , FL: Follicle, CL: Corpus luteum

semen was inseminated into the cervical canal.

Study design

1. Ovarian and hormonal dynamics during the menstrual cycle and follicle size at spontaneous ovulation

Two female monkeys were used to monitor ovarian and hormonal dynamics during the menstrual cycle (Table 1). For 38 days from early November to the middle of December, ultrasonographic observation of ovaries and blood collection were done three times a week at one- or two-day intervals. During this period, feces were collected every day. Feces were also collected five days a week from the middle of October to early November prior to the ultrasonographic examination period. Further, changes in ovaries of three female monkeys were monitored from Day 9 to 16 of the menstrual cycle by ultrasonography

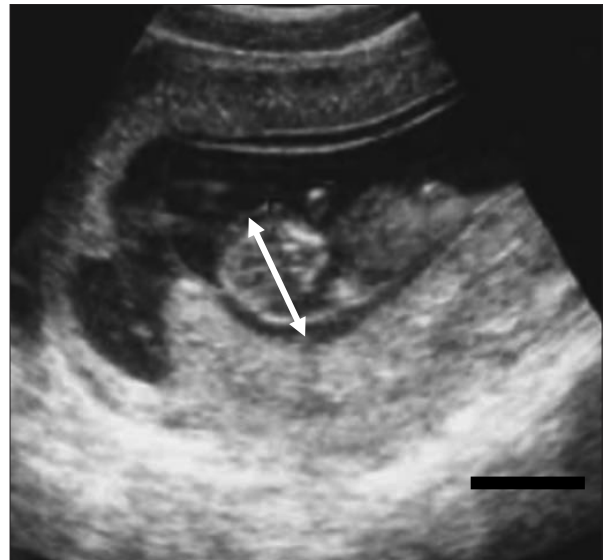


Fig. 4. Ultrasonographic image of the fetus of ID2068 at 71 days after artificial insemination (bar = 10 mm). Fetal age was estimated to be 50 days based on the biparietal diameter (white arrow: 12 mm).

with a zero to two days interval to confirm the ovulatory follicle diameter.

2. Ovulation induction by GnRH

Two female monkeys were used in three ovulation induction trials using GnRH (Table 1). As shown in Table 2, ultrasonographic ovarian observation and blood collection were performed daily or at intervals of one or two days from Day 7 to Day 16 of the menstrual cycle. Feces were collected daily during this study period for each monkey. A single dose (2 ml) of a GnRH analogue (100 µg as fertirelin acetate, Conceral injection, Nagase Medicals Co., Ltd., Hyogo, Japan) was administered intramuscularly from Day 10 to 13 of the menstrual cycle (Table 2).

3. AI with ovulation induction

A total of seven AI trials were performed for four female monkeys (Table 1 and 3). Ultrasonographic observation of ovaries was performed to confirm the presence of a dominant follicle of more than 5 mm in diameter prior to AI. A mixture of fresh semen collected from one to three monkeys on each AI day was used for insemination. Females were subjected to AI on Day 8–14 of the menstrual cycle and a single dose (2 ml) of GnRH was administered simultaneously for ovulation induction (Table 3). The dominant follicle was observed on the day following AI using ultrasonography without anesthesia to confirm the ovulation day. Pregnancy was diagnosed by ultrasonography in monkeys in which menses was not observed after AI.

Results

1. Ovarian and hormonal dynamics during the menstrual cycle and follicle size at spontaneous ovulation

Ovarian and hormonal dynamics in two females monitored for changes during menstrual cycle are shown in Fig. 2. One female showed two ovulations and another showed one. The inter

ovulation interval of one female was 29 days with a 17-day luteal phase and a 12-day follicular phase. The plasma E_2 concentration showed high value one to three days before ovulation day (406–894 pg/ml). Although fecal E_2 showed a peak at ovulation in female No. 2140, this was uncertain in female No.2068. The plasma P_4 concentration increased to over 1 ng/ml at one to three days after the ovulation day and decreased sharply just before the first day of menses. Fecal P_4 concentration showed similar changes to plasma P_4 concentration. Before the first ovulation in each animal, there was no increase in fecal P_4 concentration. The dominant follicle of one monkey (ID 2068) was in preovulatory stage at the first observation and ovulated by examination two days later. Dominant follicle was detectable four days after the start of menstruation and development of the diameter (3.4–9.6 mm) were observed for 10 days. CLs were detectable by ultrasonography two to four days after ovulation. Decrease of the diameter of CL (9.5–6.1 mm) was observed two to four days before menses (ID 2068). Table 2 shows changes in ovarian structure, including those of three females monitored at spontaneous ovulation as well as those monitored during the menstrual cycle. Spontaneous ovulation occurred from Day 12 to 14 of the menstrual cycle in four monkeys and the follicle diameter immediately before ovulation was 7.4 ± 1.5 mm (5.1–9.6 mm: in six ovulations).

2. Ovulation induction by GnRH

Changes in ovarian structure related to GnRH administration are shown in Table 2. In all three trials, a dominant follicle was ovulated the day after GnRH administration. The follicle diameter on the GnRH administration day was 5.8 ± 1.2 mm (4.7–7.4 mm: in three cases). CLs were detectable within one to three days after ovulation in two cases.

Hormonal and ovarian dynamics of ovulation induced monkeys are shown in Fig. 3. Plasma E_2 concentration increased in two out of three cases on the day of GnRH administration. In the other

case, plasma E_2 concentration increased slightly after GnRH administration. Meanwhile, fecal E_2 concentration increased by GnRH administration in all three cases. Plasma P_4 concentration increased within three days after ovulation in two cases, but it did not increase at two days after ovulation, which was last day of monitoring. Fecal P_4 concentration dynamics were similar to those of plasma in two cases (2068, 2140-2), but not in one case (2140-1).

3. AI with ovulation induction

Semen characteristics of monkeys inseminated via AI are shown in Table 3. Over 14×10^6 progressive motile sperm were inseminated in each AI. The mean progressive motile sperm number was $49.0 \pm 26.8 \times 10^6$ (14.8 – 225.0×10^6 sperms). Only one case that inseminated to the uterus became pregnant. At 71 days after AI, a fetus has confirmed by ultrasonography (Fig. 4). However, there was no fetal heart beat and the fetal age was estimated to be 50 days old according to the biparietal diameter²⁴⁾.

Discussion

This is the first study to monitor ovarian dynamics by ultrasonography in the Japanese macaque. The age of monkeys in this study were ranged 5–11 years old, in which monkeys were sufficiently matured and not degraded by aging^{23,26)}. During the breeding season, spontaneous ovulations were observed six times, and the diameter of the dominant follicle just before ovulation was 7.4 ± 1.5 mm. This size was larger than the preovulatory dominant follicle in the rhesus macaque (5.9 ± 1.8 mm⁵⁾, 5.3 ± 0.4 mm¹⁹⁾ and the cynomolgus macaque (6.8 ± 0.1 mm)⁴¹⁾, also measured by ultrasonography. The maximum diameter of the dominant follicle was 9.6 mm in this study, while that of the rhesus macaque was 7 mm¹⁹⁾. It seems that these differences occur due to the body size differences between the Japanese macaque (around 8 kg) and the other two species

(around 5 kg). On the other hand, the minimum size of the preovulatory follicle was 5.1 mm. This size was determined by observation with two days interval, which means ovulation could take place after follicular development during this interval. Therefore, follicle size of 5.1 mm could be a spontaneous preovulatory follicle size, further study is necessary to conclude the minimum size of preovulatory follicle. Spontaneous ovulation occurred between on Day 12 to 14 of the menstrual cycle, which was in the range of a previous study in the Japanese macaque²¹⁾.

Similar to a previous study that monitored the dynamics of steroid hormone in the Japanese macaque²²⁾, the E_2 concentration reached a peak before ovulation and the P_4 concentration increased after ovulation. As in the previous report⁹⁾, plasma and fecal hormones showed similar dynamics during the menstrual cycle. Fecal E_2 concentration reached a peak on the day after the plasma E_2 peak. Ovulation occurred on the next day or three days after the plasma E_2 peak, while it occurred the same day or the day following the fecal E_2 peak. This was the same as a previous report showing that ovulation occurred within two days after the plasma E_2 peak²²⁾. In the present study, we could show the stability of monitoring steroid hormone dynamics, even the measuring methods and the period is different. Further, ovarian dynamics first time monitored by ultrasonography in Japanese macaque showed that the hormonal dynamics truly reflect the ovarian dynamics in this species.

In this study, fertirelin acetate was used as GnRH analogue. The structure of GnRH is common in mammals^{17,34)}, and fertirelin acetate sufficiently induces secretion of luteinizing hormone (LH) and follicle stimulating hormone (FSH) in cows⁷⁾. Therefore, fertirelin acetate is competent in inducing ovulation in the Japanese macaque. In all cases of GnRH administration, ovulation was confirmed on the following day in the present study. Nigi and Torii (1991)²⁵⁾ reported that ovulation occurs within 48 h after the LH peak in the Japanese macaque, and within 3 hr

at the earliest. GnRH could induce the ovulation of follicles of more than 4.7 mm in diameter. In the rhesus macaque, dominant follicle selection is completed by Day 3 of the follicular phase when the diameter is around 3 mm⁵, which means the LH receptor is already expressed. In the present study, the smallest dominant follicle detectable by ultrasonography was 3.9 mm on Day 7 of the menstrual cycle. Therefore, the dominant follicle was probably selected by that period and the follicle size indicates the presence of the LH receptor. Further, this suggests that a greater than 5 mm diameter follicle is sufficient to react to the LH surge induced by GnRH administration, followed by ovulation in practical settings. In the three subjects monitored for both ovarian and hormonal dynamics during ovulation induction, the plasma E₂ concentrations were high around the day of ovulation induction in two subjects, and it was similar in fecal hormone dynamics. Meanwhile, the plasma E₂ concentration was at the baseline level in the other subject and this was the opposite of fecal dynamics. One possible reason is that plasma E₂ concentration had already increased before the start of monitoring and spontaneous ovulation occurred, although a reduction in follicle size was only detected after GnRH injection as with ovulation. The E₂ peak to LH peak interval was reported to be 20 to 30 hr²⁵, so the maximum estimated interval from the E₂ peak to ovulation is about 78 h. Therefore, in this case, plasma E₂ concentration already increased before monitoring and we could only detect it by a fecal hormone assay due to a delay in the plasma dynamics; spontaneous ovulation had already taken place at the time of ovulation induction.

In three cases of AI on 2018/3/7 (Table 3), semen mixture contained sperm collected from a male which is derived from same troop with recipient females. Since it was reported that reproduction in closed colony had been smoothly repeated³, AI between males and females from same troop did not affect the fecundity, In the present study, semen was inseminated once with ovulation induction with over 14.0×10^6

progressive motile sperm. In a previous report on AI in the Japanese macaque, semen was inseminated two to three times per ovulation and $5.0\text{--}10.0 \times 10^6$ sperm was inseminated each time⁴⁰. The pregnancy rate in present study was 14.3% (1/7), while it was 50% (3/6) in the previous report⁴⁰. Although the pregnancy rate was low, a single AI with ovulation induction was shown to be feasible to achieve pregnancy. The reason for the low pregnancy rate may be due to the site of insemination. The pregnancy rate of intracervical insemination of fresh semen was quite low in the Japanese macaque (0.0%: 0/3) and the rhesus macaque (33.3%: 1/3) compared to intrauterine insemination (100.0%: 3/3 and 57.1%: 8/14, respectively)^{30,40}. In macaque, the cervical canal is serpentine¹¹, so trans-cervical access to the uterus is difficult, especially in nulliparous females. Therefore, we must try other method to inseminate into the uterus, such as transabdominal insemination³⁵ or retaining semen in the vagina using a special device¹⁴.

Although semen was inseminated into the uterus, females did not become pregnant in three out of four cases. One of the possible reasons for this is timing of ovulation induction, since two cases were several days earlier considering the range of spontaneous ovulation (Day 10 to 14 of the cycle), even though the dominant follicles were ovulatory size. In the rhesus macaque, a follicle of 6 mm in diameter still showed enhanced growth with FSH and this improved the meiotic and developmental competence of oocytes³². For *in vitro* embryo production in the rhesus macaque, FSH priming before hCG administration enhances meiotic and developmental competence³³. Therefore, a gap of several days between the spontaneous ovulation and ovulation induction by GnRH administration in the present study may have impaired oocyte potential by depriving them of a few days of exposure to FSH. Since studies about oocyte competence usually focus on gonadotropin-induced situations, further study investigating the spontaneous cycle is needed to clarify this issue. Further, the diameter of follicles

at AI ranged 6.0–10.0 mm in present study. Although there is no previous study indicates preovulatory follicle size and developmental competence of oocytes inside the follicle in non-human primates, it was suggested that small preovulatory follicle size at GnRH administration decreased pregnancy rate in cattles²⁷⁾. Therefore, the effect of follicle size on fertility also should be taken into account in further study.

In the present study, the ovulatory size of the dominant follicle during the spontaneous cycle was estimated to be 7.4 ± 1.5 mm in the Japanese macaque. Further, we found that a follicle size over 5 mm was enough to induce ovulation by GnRH administration. When we perform AI with ovulation induction, it should be done within the period of spontaneous ovulation in the presence of an ovulatory size follicle along with intrauterine insemination.

Acknowledgments

This research was supported by the Cooperation Research Program of the Primate Research Institute, Kyoto University (2013-C-4, 2015-B-59, 2016-B-52 and 2017-B-15) and Collaborative Research Project organized by the Interuniversity Bio-Backup Project (IBBP) of the National Institute for Basic Biology.

References

- 1) Amato F, Warnes GM, Kirby CA, Norman RJ. Infertility caused by hCG autoantibody. *J Clin Endocrinol Metab* 87, 993-997, 2002.
- 2) Andrabi SMH, Maxwell WMC. A review on reproductive biotechnologies for conservation of endangered mammalian species. *Anim Reprod Sci* 99, 223-243, 2007.
- 3) Aoki K. Actual state and subjects in zoo. In: *Monkey of Japan: A mammalogical study of Japanese macaques*. Tsuji Y, Nakagawa N. eds. Univ. of Tokyo Press, Japan. pp. 245-264, 2017. (In Japanese)
- 4) Beekman NJCM, Schaaper WMM, Turkstra JA, Meloen RH. Highly immunogenic and fully synthetic peptide-carrier constructs targeting GNRH. *Vaccine* 17, 2043-2050, 1999.
- 5) Bishop CV, Sparman ML, Stanley JE, Bahar A, Zelinski MB, Stouffer RL. Evaluation of antral follicle growth in the macaque ovary during the menstrual cycle and controlled ovarian stimulation by high-resolution ultrasonography. *Am J Primatol* 71, 384-392, 2009.
- 6) Braunstein GD, Bloch SK, Rasor JL, Winikoff J. Characterization of anihuman chorionic-gonadotropin serum antibody appearing after ovulation induction. *J Clin Endocrinol Metab* 57, 1164-1172, 1983.
- 7) Chenault JR, Kratzer DD, Rzepkowski RA, Goodwin MC. LH and FSH response of Holstein heifers to fertirelin acetate, gonadorelin and buserelin. *Theriogenology* 34, 81-98, 1990.
- 8) Colazo MG, Mapletoft RJ. A review of current timed-AI (TAI) programs for beef and dairy cattle. *Can Vet J*, 55, 772-780, 2014.
- 9) Fujita S, Mitsunaga F, Sugiura H, Shimizu K. Measurement of urinary and fecal steroid metabolites during the ovarian cycle in captive and wild Japanese macaques, *Macaca fuscata*. *Ame J Primatol* 53, 167-176, 2001.
- 10) Fukui D, Nagano M, Nakamura R, Bando G, Nakata S, Kosuge M, Sakamoto H, Matsui M, Yanagawa Y, Takahashi Y. The Effects of Frequent Electroejaculation on the semen characteristics of a captive siberian tiger (*Panthera tigris altaica*). *J Reprod Dev* 59, 491-495, 2013.
- 11) Hafez ESE, Jaszczak S. Comparative anatomy and histology of the cervix uteri in non-human primates. *Primates* 13, 297-314, 1972.
- 12) Kappelhof J, Windig JJ. Controlling inbreeding rate in the European zoo population of Hamadryas baboons *Papio hamadryas* with a breeding circle. *J Zoo Aquar Res* 9, 26-34, 2021.
- 13) Kinoshita K, Inada S, Seki K, Sasaki A, Hama

- N, Kusunoki H. Long-term monitoring of fecal steroid hormones in female snow leopards (*Panthera uncia*) during pregnancy or pseudopregnancy. *PloS One* 6, e19314, 2011.
- 14) Koyama S, Fukuda K, Watanabe S, Kohara S, Tsuchiya H, Fukuzaki K, Nagano M, Uno Y, Hosoi Y. Development of a new device for artificial insemination in cynomolgus macaques. *J Reprod Dev* 62, 527-529, 2016.
 - 15) Li YH, Cai KJ, Kovacs A, Ji WZ. Effects of various extenders and permeating cryoprotectants on cryopreservation of cynomolgus monkey (*Macaca fascicularis*) spermatozoa. *J Androl* 26, 387-395, 2005.
 - 16) Lueders I, Allen WRT. Managed wildlife breeding-an undervalued conservation tool? *Theriogenology* 150, 48-54, 2020.
 - 17) Millar RP. GnRHs and GnRH receptors. *Anim Reprod Sci* 88, 5-28, 2005.
 - 18) Moore SG, Hasler JF. A 100-Year Review: Reproductive technologies in dairy science. *J Dairy Sci* 100, 10314-10331, 2017.
 - 19) Morgan PM, Hutz RJ, Kraus EM, Cormie JA, Dierschke DJ, Bavister BD. Evaluation of ultrasonography for monitoring follicular-growth in rhesus-monkeys. *Theriogenology* 27, 769-780, 1987.
 - 20) Munro CJ, Laughlin LS, Illera JC, Dieter J, Hendrickx AG, Lasley BL. ELISA for the measurement of serum and urinary chorionic gonadotropin concentrations in the laboratory macaque. *Am J Primatol* 41, 307-322, 1997.
 - 21) Nigi H. Laparoscopic observations of ovaries before and after ovulation in the Japanese monkey (*Macaca fuscata*). *Primates* 18, 243-259, 1977.
 - 22) Nigi H. Periovarian time courses of plasma estradiol and progesterone in the Japanese monkey (*Macaca fuscata*). *Primates* 24, 410-418, 1983.
 - 23) Nigi H. Japanese macaque, physiology of reproduction. *Doubutsu-sha, Tokyo*. pp. 146-219, 1983. (In Japanese)
 - 24) Nigi H, Hayama S, Sawada T, Sakamoto M. Estimation of delivery date using biparietal diameter of fetus in Japanese macaque., The 1991 annual meeting of the mammal society of Japan. 1991.
 - 25) Nigi H, Torii R. Periovarian time courses of serum LH in the Japanese monkey (*Macaca fuscata*). *Exp Anim* 40, 401-405, 1991.
 - 26) Nomura T, Nigi H, Ohsawa N, Ando A, Tanaka T, Tajima Y, Kotera S. Reproduction of Japanese monkeys. *Acta Endocrinologica*, 71, 473-482, 1972.
 - 27) Perry GA, Smith MF, Lucy MC, Green JA, Parks TE, MacNeil MD, Roberts AJ, Geary TW. Relationship between follicle size at insemination and pregnancy success. *Proc Natl Acad Sci USA* 102, 5268-5273, 2005.
 - 28) Pierson RA, Ginther OJ. Ultrasonic-imaging of the ovaries and uterus in cattle. *Theriogenology* 29, 21-37, 1988.
 - 29) Ravindra JP, Rawlings NC, Evans ACO, Adams GP. Ultrasonographic study of ovarian follicular dynamics in ewes during the oestrous cycle. *Reproduction* 101, 501-509, 1994.
 - 30) Sanchez-Partida LG, Maginnis G, Dominko T, Martinovich C, McVay B, Fanton J, Schatten G. Live rhesus offspring by artificial insemination using fresh sperm and cryopreserved sperm. *Biol Reprod* 63, 1092-1097, 2000.
 - 31) Sankai T, Terao K, Yanagimachi R, Cho F, Yoshikawa Y. Cryopreservation of spermatozoa from cynomolgus monkeys (*Macaca fascicularis*). *J Reprod Fertil* 101, 273-278, 1994.
 - 32) Schramm RD, Bavister BD. Follicle-stimulating hormone priming of rhesus monkeys enhances meiotic and developmental competence of oocytes matured in vitro. *Biol Reprod* 51, 904-912, 1994.
 - 33) Schramm RD, Bavister BD. A macaque model for studying mechanisms controlling oocyte development and maturation in human and non-human primates. *Hum Reprod* 14, 2544-2555, 1999.
 - 34) Sherwood N. The GnRH family of peptides.

- Trends Neurosci 10, 129-132, 1987.
- 35) Shimozawa N, Ageyama N, Nakayama S, Koie H, Yasutomi Y. Ultrasound-guided, transabdominal, intrauterine artificial insemination for cynomolgus macaques (*Macaca fascicularis*) based on estimated timing of ovulation. *J Am Assoc Lab Anim Sci* 60, 125-132, 2021.
- 36) Sokol RZ, McClure RD, Peterson M, Swerdloff RS. Gonadotropin therapy failure secondary to human chorionic gonadotropin-induced antibodies. *J Clin Endocrinol Metab*, 52, 929-933, 1981.
- 37) Suresh B, Puttabyatappa M, Peter AT, Medhamurthy R, Seshagiri PB. Assessment of ovarian follicular dynamics and folliculogenesis associated endocrine profiles following gonadotropin stimulation in the bonnet monkey. *Gen Comp Endocrinol* 253, 25-32, 2017.
- 38) Thau RB, Goldstein M, Yamamoto Y, Burrow GN, Phillips D, Bardin CW. Failure of gonadotropin therapy secondary to chorionic gonadotropin-induced antibodies. *J Clin Endocrinol Metab* 66, 862-867, 1988.
- 39) Torii R, Nigi H. The artificial fecundation in Japanese monkeys (*Macaca fuscata*) by induced ovulation and artificial-insemination in nonmating season. *Exp Anim* 41, 243-246, 1992.
- 40) Torii R, Nigi H. Successful artificial insemination for indoor breeding in the Japanese monkey (*Macaca fuscata*) and the cynomolgus monkey (*Macaca fascicularis*). *Primates* 39, 399-406, 1998.
- 41) van Diepen HA, Pansier J, Wesselink PO, van Drie A, van Duin M, Mulders S. Non-invasive translational cynomolgus model for studying folliculogenesis and ovulation using color doppler ultrasonography. *J Med Primatol* 41, 18-23, 2012.
- 42) Yanagawa Y, Matsuura Y, Suzuki M, Saga SI, Okuyama H, Fukui D, Bando G, Nagano M, Katagiri S, Takahashi Y, Tsubota T. Accessory corpora lutea formation in pregnant Hokkaido sika deer (*Cervus nippon yesoensis*) investigated by examination of ovarian dynamics and steroid hormone concentrations. *J Reprod Dev* 61, 61-66, 2015.
- 43) Yang S, He X, Niu Y, Wang X, Lu B, Hildebrandt TB, Goeritz F, Jewgenow K, Zhou Q, Ji W. Dynamic changes in ovarian follicles measured by ultrasonography during gonadotropin stimulation in rhesus monkeys. *Theriogenology* 72, 560-565, 2009.