Studies on teratogenicity of maternal hypoglycemia in rats and rabbits

（ラットとウサギにおける母動物低血糖と催奇形性に関する研究）

Chiharu Kuwata

Contents

Abbreviations

$AUC_{0\text{-}24h}$	area under the plasma concentration-time curve up to 24 h
chx10	visual system homeobox 2
Cmax	maximum plasma concentration
E	embryonic day
DF	dose-finding
EFD	embryo-fetal developmental toxicity
FGF	fibroblast growth factor
GK	glucokinase
h	hour
HE	hematoxylin and eosin
HRP	horseradish peroxidase
ICH	International Conference on Harmonisation
INL	inner neuroblastic layer
MITF	microphthalmia-associated transcription factor
NR	neural retina
ONF	optic nerve fiber
ONL	outer neuroblastic layer
Pax6	paired box 6
RPE	retinal pigmented epithelium
SD	standard deviation
TGF-β	Transforming Growth Factor-β
TK	toxicokinetic
Tmax	time to reach maximum plasma concentration

Tuj-1	anti-Neuronal Class III β-Tubulin
T2DM	type 2 diabetes mellitus

Notes

Contents of this thesis have been published as follows:

1. Kuwata C, Saeki N, Honda K, Matsuoka T, Tsuchiya Y, Shimomura K. Effects of maternal hypoglycemia on fetal eye and skeleton development in rats. Reprod Toxicol. 71, 135-141, 2017

2. Kuwata C, Matsuoka T, Ohshima Y, Yahagi S, Watanabe T, Tsuchiya Y, Shimomura K. Effects of glucokinase activator, DS-7309, on embryo-fetal developmental toxicity in rats and rabbits. Regul Toxicol Pharmacol. 129, 105119, 2022

3. Kuwata C, Maejima T, Hakamata S, Yahagi S, Matsuoka T, Tsuchiya Y. Disruption of fetal eye development caused by insulin-induced maternal hypoglycemia in rats. Reprod Toxicol. 112, 68-76, 2022

General introduction

Diabetes during pregnancy is one of the most common maternal disorders and its prevalence is increasing [33]. Insulin is currently the only option for treating diabetes in pregnant women according to several sets of practice guidelines [6,37]. Because of its large molecular size, insulin cannot pass the placental barrier by facilitated diffusion, so it rarely affects fetuses directly [23,63,81]. Meanwhile, almost all launched oral antidiabetic drugs, which have a small molecular size and can reach the fetus through the placenta unlike insulin, are contraindicated during pregnancy because they showed teratogenic potential and/or embryo-fetal lethality when administered to animals in non-clinical study during development [43,80] .

When developing a new drug, nonclinical embryo-fetal developmental toxicity (EFD) studies have to be conducted to support human clinical trials and marketing authorization, in accordance with to the International Conference on Harmonisation (ICH) guidelines [35]. To detect unexpected adverse effects on reproduction and embryo-fetal development for human risk assessment during pregnancy, EFD studies in two experimental animal species treated throughout the period of organogenesis are required. In EFD studies, a dose level that is higher than the therapeutic dose should be tested to evaluate potential adverse effects by investigating pregnant maintenance, fetal viability, fetal developmental retardation, and teratogenicity.

Generally, there are two possible mechanisms underlying the teratogenicity of drugs. One is a direct effect of drugs on fetuses by crossing the placenta from mother to fetus. The other is an indirect effect of drugs on fetuses due to maternal conditions induced by drugs. If the drug has a direct effect on fetuses, then it should be contraindicated in pregnant woman due to its own teratogenic potential; however, if the drug shows an indirect effect on fetuses, its use during pregnancy may be acceptable by controlling the maternal conditions. Therefore, it is very important to elucidate the underlying mechanism when a candidate drug shows teratogenicity in animal studies.

Antidiabetic drugs can cause maternal hypoglycemia due to their exacerbated pharmacological action. Subsequently, these drugs may induce teratogenicity in fetuses via maternal hypoglycemia, although it remains controversial whether maternal hypoglycemia can cause teratogenicity in fetuses. Eriksson [19] and Landauer [43] reported that insulin caused fetal teratogenicity due to maternal hypoglycemia without crossing the placental barrier. It

was also shown that the administration of insulin to pregnant animals from an early stage of pregnancy caused eye anomalies in their fetuses in rats [52,53] or rabbits [14] and axial skeleton anomalies in their fetuses in rats [76] or mice [72] when examined at a late stage of pregnancy. In addition to the aforementioned in vivo studies, Akazawa et al. [2,3] showed that insulin-induced hypoglycemia interrupted neural embryogenesis in rats in early pregnancy period by whole-embryo culture. However, some other in vivo studies demonstrated that insulin did not show teratogenicity despite causing severe hypoglycemia lasting for 1 to 7 h or mild hypoglycemia for 48 h [29,31,38,65]. The reason for this discrepancy has not yet been fully elucidated and the detailed pathogenesis of the anomalies in fetuses caused by insulin also remains unclear.

DS-7309 was developed for the treatment of type 2 diabetes mellitus (T2DM) by Daiichi Sankyo Co., Ltd. (Tokyo, Japan). DS-7309 activates glucokinase (GK), which is distributed primarily in the liver and beta cells of the pancreas and catalyzes the phosphorylation of glucose to synthesize glucose-6-phosphate [73]. In response to a high blood glucose level, GK promotes the secretion of insulin from beta cells and subsequent glycogenesis in the liver, and induces reduction of the blood glucose level [47,48]. Therefore, GK is an attractive target for treating T2DM [28,49,79].

The teratogenic potential of DS-7309 has been recognized in EFD studies using rats and rabbits. However, it is unclear how fetal anomalies developed and whether the teratogenicity of DS-7309 is due to a direct effect on fetuses or an indirect effect caused via maternal hypoglycemia. Therefore, in this work, comprehensive investigation of teratogenicity induced by DS-7309 was conducted as follows: As described in Chapter 1, the toxicological effects of DS-7309 on pregnancy and embryo-fetal development in rats and rabbits and maternal blood glucose levels were examined. Then, as indicated in Chapter 2, four different types of insulin, which rarely affect fetuses directly, were used to cause different types of maternal hypoglycemia (in terms of the severity and duration) in order to characterize the teratogenicity induced by maternal hypoglycemia and to investigate the relationship between the duration and severity of maternal hypoglycemia and teratogenicity in detail. Finally, as shown in Chapter 3, the pathogenesis of and factors contributing to hypoglycemia-induced eye anomalies were further investigated.

Chapter 1.

Effects of glucokinase activator, DS-7309, on embryo-fetal developmental toxicity in rats and rabbits

1. Introduction

The oral antidiabetic agent DS-7309 (molecular formula: $C_{22}H_{24}N_4O_6S \cdot CH_4O_3S$; molecular weight: 568.62 [Atomic weights of the elements 2007 (IUPAC2007, 2009)]) was discovered and synthesized at Daiichi Sankyo Co, Ltd. (Tokyo, Japan). DS-7309 activates GK, which is distributed primarily in the liver and beta cells of the pancreas and catalyzes the phosphorylation of glucose to synthesize glucose-6-phosphate [73]. In response to a high blood glucose level, GK promotes the secretion of insulin from beta cells and subsequent glycogenesis in the liver, and induces reduction of the blood glucose level [47,48]. Therefore, GK is an attractive target for treating T2DM [28,49,79]. In a rat model of T2DM, DS-7309 significantly decreased plasma glucose level with increasing dose at doses from 0.83 to 25 mg/kg (unpublished data). This suggests that DS-7309 could have a glucose-lowering effect in T2DM, patients.

The most important source of energy for normal fetal growth is glucose provided from dams via the placenta because fetuses cannot produce adequate glucose until a late stage of pregnancy [30]. Although it remained still controversial whether maternal hypoglycemia can cause teratogenicity in fetuses, several reports have described that maternal hypoglycemia during pregnancy induces pregnancy failure and/or impaired embryo-fetal development in chickens, mice, rats, and rabbits [9,19,31].

Consequently, when investigating the effects of anti-T2DM drugs for pregnant animals on embryo-fetal development, it is important to investigate whether the embryo-fetal findings are due to direct effects of the drug on the pregnancy and fetus or indirect effects caused via maternal hypoglycemia. Therefore, in the present study, the author extended the examination of the effects of DS-7309 on reproduction and embryo-fetal toxicity in rats and rabbits by measuring the time-course changes in blood glucose levels. To the best of my knowledge, this is the first study using appropriate doses of GK activator to assess fetuses in non-diabetic normoglycemic rats and rabbits.

2. Materials and methods

2.1 Test substance

DS-7309 was suspended in water for injection (Japanese Pharmacopoeia; Otsuka Pharmaceutical Factory, Inc., Tokushima, Japan) at a dose level of 3, 10, or 100 mg/kg (5 mL/kg) in rats, and 10, 30, or 100 mg/kg (5 mL/kg) in rabbits (doses are expressed as a free form of DS-7309). The high dose level was selected to induce some minimal maternal toxicities based on information from previous dose-finding (DF) studies. In these DF studies (rats: 30, 100, and 300 mg/kg, 5 mL/kg; rabbits: 10, 30, 100, and 300 mg/kg, 5 mL/kg), death and a moribund condition were observed in 2/8 and 1/8 pregnant rats, respectively, at 300 mg/kg, while premature delivery was observed in 4/7 pregnant rabbits at 300 mg/kg. Additional findings included external eye and tail anomalies in rat fetuses at 300 mg/kg, decreased fetal body weight in rats at 100 mg/kg or more, and significantly increased fetal mortality in rats and rabbits at 300 mg/kg (In these DF studies, neither visceral nor skeleton examinations were conducted). Water for injection was used as a vehicle control. The dosing volume was based on the most recent individual body weight.

2.2 Animals

Eight-week-old female and 15-week-old male Sprague-Dawley (Crl:CD(SD)) rats (n = 108/sex) were obtained from Charles River Laboratories Japan, Inc. (Kanagawa, Japan). After acclimation, female rats at 10 weeks of age were housed with males for mating, and 103 pregnant rats were obtained. Twenty to 21 pregnant rats per group were assigned to 4 toxicity groups and 5 pregnant rats per group were assigned to 4 toxicokinetic (TK) and glucose measurement subgroups. Seventeen-week-old female (n = 134) and 24-week-old male (n = 28) New Zealand White (Kbl:NZW) rabbits were obtained from Kitayama Labes Co., Ltd. (Nagano, Japan). Females at 19 to 20 weeks of age and males were mated after acclimation, and 87 pregnant females were obtained. Seventeen to 21 pregnant rabbits per group were assigned to 4 toxicity groups and 3 pregnant rabbits per group were assigned to 4 TK and glucose measurement groups. The remaining 47 females were excluded from the study and were used for other studies. The day of copulation was defined as Day 0 of pregnancy. Apart from during the mating period, rats and rabbits were housed individually. They were kept in a controlled environment at a room temperature from 20°C to 26°C for rats or 18°C to 28°C for rabbits, humidity from 30% to 70%, and an illumination period of

12 h per day (from 07:00 to 19:00). Certified pellet food sterilized by 60Co-γ irradiation (30 kGy, CRF-1 for rats or LRC4 for rabbits; Oriental Yeast Co., Ltd., Tokyo, Japan) and tap water were supplied *ad libitum*. All animal procedures were performed in accordance with the guidelines of the Animal Care and Use Committee of Daiichi Sankyo Co., Ltd. The experimental protocols were approved by the Institutional Animal Care Committee of Daiichi Sankyo Co., Ltd.

2.3. Experimental protocol for rats

2.3.1. Reproductive and developmental toxicity evaluation

Pregnant rats were given DS-7309 orally by gavage once daily from Days 7 to 17 of pregnancy. The oral administration route was selected in accordance with the intended clinical route. The dose regimen was determined to cover the period of organogenesis. Body weights were measured on Days 0, 3, 7, 9, 11, 13, 15, 17, and 20 of pregnancy. Food consumption was calculated from the amount supplied on Days 3, 7, 9, 11, 13, 15, 17, and 20 of pregnancy, and the amount remaining on the next day. Pregnant rats were euthanized on Day 20 of pregnancy. After euthanasia, necropsy and Cesarean section were performed. The number of corpora lutea was counted and the sex of the fetus was determined based on the anogenital distance under a stereomicroscope. The numbers of implantations, live fetuses, and embryo-fetal deaths were counted, and the placentae were observed macroscopically. Embryo-fetal deaths were classified as implantation site, early resorption, late resorption, or dead fetus. Live fetuses were weighed and examined externally under a stereomicroscope. Live fetuses of each litter were allocated almost equally to visceral or skeleton observation. The head observation was performed by Wilson's method after fixation in Bouin's fluid [83] and the thoracic and abdominal organs were examined by Nishimura's microdissection method under a stereomicroscope. Skeleton anomalies and variations, and the degree of ossification were examined after staining by Dawson's method [18].

2.3.2. TK analysis and blood glucose measurement

Blood samples (0.3 mL/time point) were taken from the jugular vein of unanesthetized animals on Days 7 and 17 of pregnancy. TK analysis was performed using samples prior to dosing (only on Day 17 of pregnancy) and 0.5, 2, 7, and 24 h after dosing.

Blood glucose measurement was performed with samples at 0.5 and 7 h after dosing. Whole blood was collected in a blood sampling tube containing heparin lithium (Microtainer; Nippon Becton Dickinson Company, Ltd., Tokyo, Japan) and centrifuged at 8,000 × *g* and 4°C for 5 min to obtain plasma. Plasma concentrations of the free form of DS-7309 were measured by tandem mass spectrometry (Prominence UFLC system, Shimadzu Corp., Kyoto, Japan; mass spectrometer, AB Sciex QTRAP5500, AB Sciex, Tokyo, Japan). The quantitation range was 0.2 to 500 ng/mL. As TK parameters, maximum plasma concentration (Cmax), time to reach maximum plasma concentration (Tmax), and area under the plasma concentration-time curve up to 24 h ($AUC_{0\text{-}24h}$) were calculated. Blood glucose levels were measured using an autoanalyzer (TBA-200FR; Canon Medical Systems Corporation, Tochigi, Japan). After the final blood collection, all rats were euthanized by the inhalation of an excessive amount of carbon dioxide on Day 20 of pregnancy. Then, the presence of implantation sites was checked to confirm pregnancy.

2.4. Experimental protocol for rabbits

2.4.1. Reproductive and developmental toxicity evaluation

Pregnant rabbits were given DS-7309 orally once daily from Days 6 to 18 of pregnancy. The oral administration route was selected in accordance with the intended clinical route. The dose regimen was determined to cover the period of organogenesis. Body weights were measured on Days 0, 3, 6, 9, 12, 15, 18, 21, 24, and 28 of pregnancy. Food consumption was calculated from the amount supplied on Days 1 to 28 of pregnancy in rabbits, and the amount remaining on the next day. Pregnant rabbits were euthanized on Day 28 of pregnancy. The examinations after euthanasia were performed in the same way as in rats except for the sex determination, and external, visceral, and skeleton observations. External and visceral observations were performed macroscopically in all fetuses. Sex of the fetus was determined by examination of the internal genital organs macroscopically. Cerebral ventricles were examined macroscopically after fixation in 99.5% ethanol, and the heart was examined by Nishimura's microdissection method under fixation in 10 vol% neutral buffered formalin. Skeleton observation was performed macroscopically for all fetuses in the same way as in rats.

2.4.2. TK analysis and blood glucose measurement

Blood samples (0.3 mL/time point) were taken from the auricular vein of unanesthetized animals prior to dosing (only on Day 18) and at 0.5, 2, 4, 7, and 24 h after dosing on Days 6 and 18 of pregnancy for TK analysis and blood glucose measurement. Collected whole blood was treated and used for TK analysis and determination of blood glucose level as in rats. After the final blood collection, all rabbits were euthanized by the injection of 1.3 mL/kg somnopentyl into the auricular vein on Day 28 of pregnancy. Then, the presence of implantation sites was checked to confirm pregnancy.

2.5. Statistical analysis

After calculating group mean ± standard deviation (SD) values, the difference of mean values between the control and treatment groups was statistically analyzed as follows. For body weight; food consumption; fetal body weight; and numbers of corpora lutea, implantations, post-implantation losses, live fetuses, and sacrocaudal vertebrae (rabbits), the homogeneity of variance between groups was analyzed by Bartlett's test. If the variance was homogeneous, Dunnett's test was subsequently applied. If the variance was not homogeneous, then nonparametric Dunnett's test was applied. For the number of sacrocaudal vertebrae in rats, F test was applied to evaluate the homogeneity of variance (significance level: 25%). Subsequently, Student's t-test was used when the variance was homogeneous or Welch's t-test when it was not. For blood glucose levels, Dunnett's test was used. For pre- and post-implantation loss rates, sex ratio, and rates of fetuses with external and visceral (rats), or skeleton anomalies and variations (rabbits), non-parametric Dunnett's test was used. For the rates of fetuses with visceral anomalies (rabbits), and skeleton anomalies or variations (rats), Wilcoxon's rank sum test was applied. A P-value less than 0.05 was considered to reflect a statistically significant difference. To take into account the litter effect, the litter was used as the sample unit, and the average of pre- or post-implantation loss rate, sex ratio, or the prevalence of anomalies in the fetal specimens from each dam was averaged by the number of dams.

3. Results

3.1 Rats

3.1.1. Clinical observation, food consumption, and body weight in pregnant rats

DS-7309 did not induce deaths or any treatment-related changes in clinical observations. In the 100 mg/kg group, food consumption was higher during the treatment period than in the control group, and then dropped after the end of treatment with a significantly lower value on Day 20 of pregnancy (Figure 1-1). However, no treatment-related changes were noted in body weight (Figure 1-2). There were no treatment-related changes in food consumption or body weight with DS-7309 at doses up to 10 mg/kg.

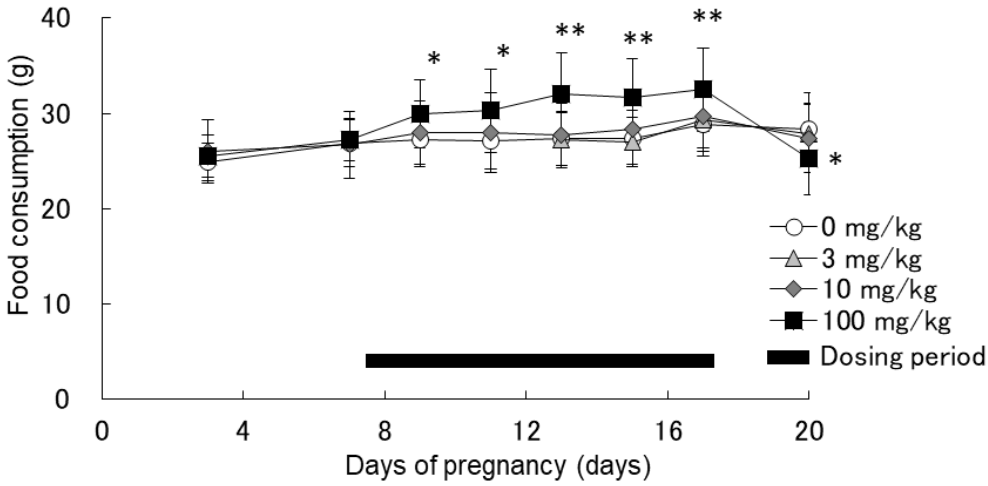

Figure 1-1 Food consumption values in DS-7309-treated pregnant rats.

Pregnant rats (n = 20 to 21) were administered DS-7309 at 0 (vehicle), 3, 10, or 100 mg/kg from Days 7 to 17 of pregnancy. Food consumption was calculated from the amount supplied on Days 3, 7, 9, 11, 13, 15, 17, and 20 of pregnancy and the amount remaining on the next day.

Significant difference from the control group: *: $p < 0.05$, **: $p < 0.01$ by Dunnett's test.

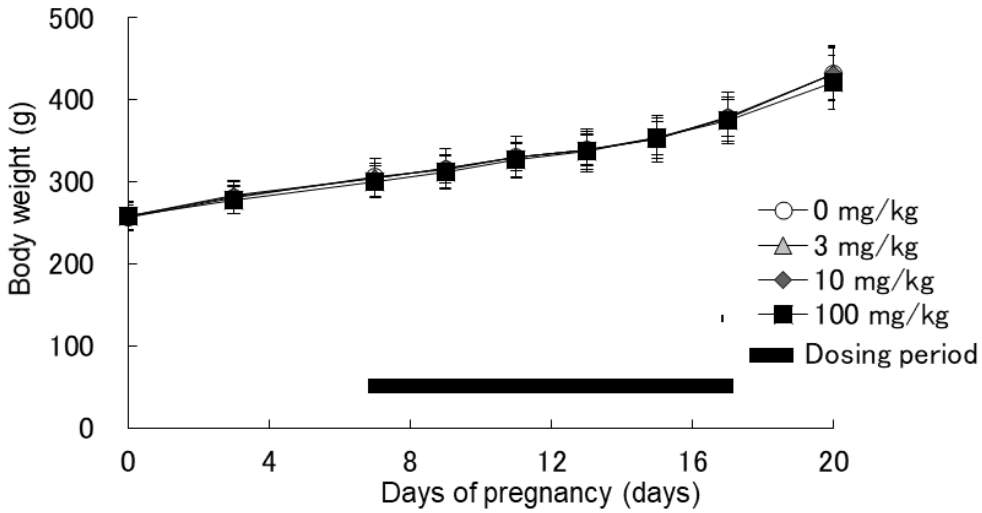

Figure 1-2 Body weight values in DS-7309-treated pregnant rats.

Pregnant rats (n = 20 to 21) were administered DS-7309 at 0 (vehicle), 3, 10, or 100 mg/kg from Days 7 to 17 of pregnancy. Body weights were measured on Days 0, 3, 7, 9, 11, 13, 15, 17, and 20 of pregnancy.

3.1.2. Cesarean section of pregnant rats

In the 100 mg/kg group, there was significantly lower fetal body weight than in the control group (Table 1-1). Except for the above, there were no treatment-related changes in the necropsy findings; the placentae findings; the numbers of corpora lutea, implantations, and live fetuses; the rate of pre-implantation loss; the rate and number of post-implantation losses; or the sex ratio.

Table 1-1 Summary results of Cesarean section of DS-7309-treated pregnant rats.

Test article	Control	DS-7309		
Dose (mg/kg)	0	3	10	100
No. of pregnant females	21	21	21	20
No. of dams with live fetuses	21	21	21	20
No. of corpora lutea	17.0 ± 2.7[a]	16.7 ± 2.1	17.1 ± 2.1	16.7 ± 2.3
No. of implantations	15.4 ± 4.0[a]	15.2 ± 2.7	16.1 ± 2.7	16.0 ± 2.1
Pre-implantation loss rate (%)	11.0 ± 19.5[a]	8.8 ± 10.7	5.6 ± 10.7	4.0 ± 4.4
Post-implantation loss rate (%)	4.8 ± 7.1[a]	5.4 ± 8.0	3.8 ± 4.9	5.8 ± 5.9
No. of post-implantation losses	17[b] (0.8 ± 1.2[a])	15 (0.7 ± 0.8)	13 (0.6 ± 0.8)	19 (1.0 ± 1.0)
Implantation sites	0[b]	0	0	0
Early resorptions	15[b]	14	10	16
Late resorptions	1[b]	1	3	2
Dead fetuses	1[b]	0	0	1
No. of live fetuses	307[b] (14.6 ± 3.8[a])	305 (14.5 ± 3.1)	326 (15.5 ± 1.5)	300 (15.0 ± 2.0)
Male	156[b]	154	179	145
Female	151[b]	151	147	155
Sex ratio (male%)	48.2 ± 18.2[a]	51.4 ± 15.2	54.5 ± 14.1	47.6 ± 11.3
Fetal body weight (g)				
Male	4.07 ± 0.20[a]	4.23 ± 0.19	4.13 ± 0.27	3.68 ± 0.24**
Female	3.93 ± 0.20[a]	4.03 ± 0.21	3.89 ± 0.22	3.47 ± 0.21**
Necropsy findings	-	-	-	-
Placental findings	-	-	-	-

Pregnant rats (n = 20 to 21) were administered DS-7309 at 0 (vehicle), 3, 10, or 100 mg/kg from Days 7 to 17 of pregnancy. Cesarean section was performed on Day 20 of pregnancy. To take into account the litter effect, the litter was used as the sample unit, and the average of pre- or post-implantation loss rate or sex ratio from each dam was averaged by the number of dams.

Significant difference from the control group: **: $p < 0.01$ by Dunnett's test.

[a]: Mean ± standard deviation per litter, [b]: Total number per group, -: No noteworthy findings.

3.1.3. External, visceral, and skeleton observations in rat fetuses

In the control group, normal eye bulges were observed bilaterally (Table 1-2 and Figure 1-3, A). In contrast, unilateral or bilateral eye anomalies such as absent or small eye bulges were observed in the 100 mg/kg group (Table 1-2 and Figure 1-3, B). The prevalence of absent eye bulge in the 100 mg/kg group was significantly higher than in the control group (Table 1-2).

A summary of the results of visceral observation in rat fetuses is shown in Table 1-3 and Figure 1-3. Normal eyes were observed in the control group (Figure 1-3, C), while eye anomalies such as anophthalmia and microphthalmia were observed in the 100 mg/kg group (Figure 1-3, D). Eye anomalies were seen unilaterally or bilaterally. The prevalence of fetuses with anophthalmia significantly increased in the 100 mg/kg group (Table 1-3). In the 100 mg/kg group, the prevalences of microphthalmia and coloboma of the optic nerve also tended to increase compared with those in the control group.

No statistically significant increases were noted in the skeleton anomalies, skeleton variations, or degree of ossification in the group with the highest dose of DS-7309 (100 mg/kg) in comparison with the levels in the control group (Table 1-4). Therefore, the specimens in the groups with lower doses (3 and 10 mg/kg) were not examined.

Table 1-2 Summary results of fetal external observation in fetuses from DS-7309-treated pregnant rats.

Test article	Control	DS-7309		
Dose (mg/kg)	0	3	10	100
No. of dams	21	21	21	20
No. of fetuses examined	307[a]	305	326	300
No. of fetuses with anomalies	3[a] (5.5 ± 21.8)[b]	1 (0.4 ± 1.7)	1 (0.3 ± 1.3)	11 (3.8 ± 8.1)
Domed head	1 (4.8 ± 21.8)	0 (0.0 ± 0.0)	0 (0.0 ± 0.0)	0 (0.0 ± 0.0)
Absent eye bulge[c]	0 (0.0 ± 0.0)	0 (0.0 ± 0.0)	0 (0.0 ± 0.0)	10 (3.5 ± 7.1)[##]
Small eye bulge[c]	0 (0.0 ± 0.0)	1 (0.4 ± 1.7)	0 (0.0 ± 0.0)	1 (0.3 ± 1.5)
Short snout	1 (0.3 ± 1.5)	0 (0.0 ± 0.0)	0 (0.0 ± 0.0)	0 (0.0 ± 0.0)
Misshapen nose	1 (4.8 ± 21.8)	0 (0.0 ± 0.0)	0 (0.0 ± 0.0)	0 (0.0 ± 0.0)
Cleft plate	1 (0.3 ± 1.5)	0 (0.0 ± 0.0)	0 (0.0 ± 0.0)	0 (0.0 ± 0.0)
Protruding tongue	1 (4.8 ± 21.8)	0 (0.0 ± 0.0)	0 (0.0 ± 0.0)	0 (0.0 ± 0.0)
Narrowed tail	0 (0.0 ± 0.0)	0 (0.0 ± 0.0)	1 (0.3 ± 1.3)	0 (0.0 ± 0.0)
Anal atresia	1 (0.4 ± 1.7)	0 (0.0 ± 0.0)	1 (0.3 ± 1.3)	0 (0.0 ± 0.0)

Pregnant rats (n = 20 to 21) were administered DS-7309 at 0 (vehicle), 3, 10, or 100 mg/kg from Days 7 to 17 of pregnancy. Cesarean section and the external observation were performed on Day 20 of pregnancy. To take into account the litter effect, the litter was used as the sample unit and the prevalence of anomalies in the fetal specimens from each dam was averaged by the number of dams.

Significant difference from the control group: [##]: $p < 0.01$ by the non-parametric Dunnett's test (joint ranking method).

[a]: Total number per group, [b]: Mean incidence ratio (%, shown as mean ± standard deviation),

[c]: Absent and small eye bulges were observed unilaterally or bilaterally.

Table 1-3 Summary results of fetal visceral observation in fetuses from DS-7309-treated pregnant rats.

Test article	Control	DS-7309		
Dose (mg/kg)	0	3	10	100
No. of dams	20[a]	21	21	20
No. of fetuses examined	148[b]	145	157	300
No. of fetuses with anomalies	11[b] (7.4 ± 10.5)[c]	11 (8.9 ± 9.8)	6 (3.9 ± 7.8)	10 (7.3 ± 19.0)
Misshapen cerebrum	1 (4.8 ± 3.2)	0 (0.0 ± 0.0)	0 (0.0 ± 0.0)	1 (0.7 ± 3.2)
Anophthalmia[d]	0 (0.0 ± 0.0)	0 (0.0 ± 0.0)	0 (0.0 ± 0.0)	3 (2.3 ± 5.6)[#]
Microphthalmia[d]	0 (0.0 ± 0.0)	1 (0.8 ± 3.6)	0 (0.0 ± 0.0)	5 (3.8 ± 11.8)
Coloboma of optic nerve	0 (0.0 ± 0.0)	1 (0.8 ± 3.6)	0 (0.0 ± 0.0)	7 (5.4 ± 14.5)
Thymic remnant in neck	1 (0.6 ± 2.8)	2 (2.2 ± 7.6)	2 (1.2 ± 3.8)	1 (0.6 ± 2.5)
Membranous ventricular septum defect	6 (4.3 ± 7.9)	3 (2.5 ± 6.6)	3 (2.0 ± 5.1)	2 (1.4 ± 6.4)
Supernumerary coronary ostium	1 (0.5 ± 2.2)	1 (0.7 ± 3.1)	1 (0.7 ± 3.1)	0 (0.0 ± 0.0)
Persistent left umbilical artery	2 (1.3 ± 4.3)	4 (2.8 ± 5.9)	0 (0.0 ± 0.0)	0 (0.0 ± 0.0)

Pregnant rats (n = 20 to 21) were administered DS-7309 at 0 (vehicle), 3, 10, or 100 mg/kg from Days 7 to 17 of pregnancy. After Cesarean section on Day 20 of pregnancy, the visceral observation was performed with half of the fetal specimens by Wilson's method after fixation in Bouin's fluid.

To take into account the litter effect, the litter was used as the sample unit and the prevalence of anomalies in the fetal specimens from each dam was averaged by the number of dams.

Significant difference from the control group: [#]: $p < 0.05$ by the non-parametric Dunnett's test (joint ranking method).

[a]: Control group included 21 pregnant rats but one pregnant rat had only one fetus, which was allocated to the skeleton observation, [b]: Total number per group, [c]: Mean incidence ratio (%, shown as mean ± standard deviation), [d]: Anophthalmia and microphthalmia were observed unilaterally or bilaterally.

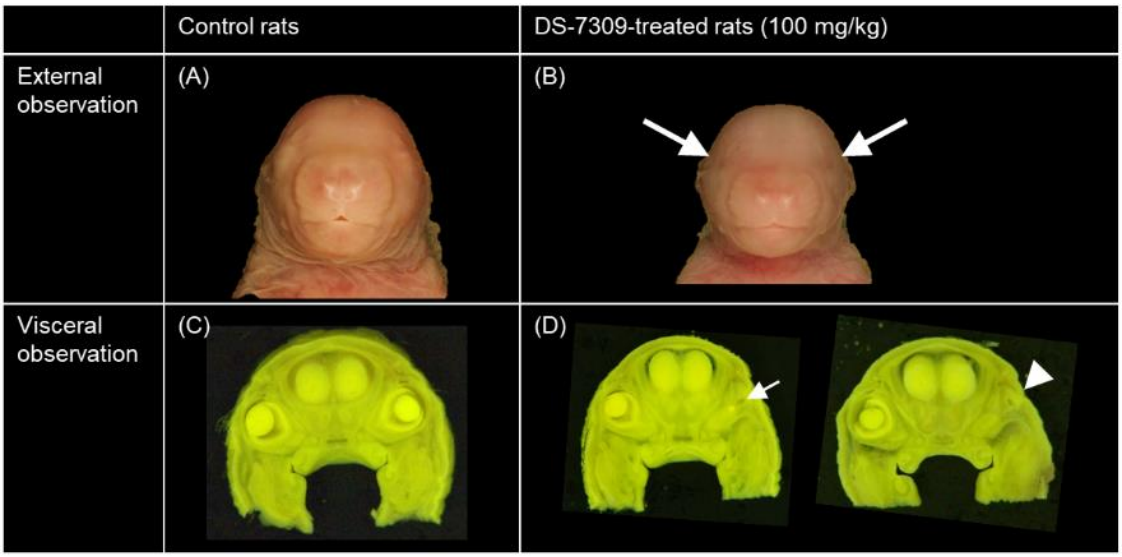

Figure 1-3 External and visceral anomalies in fetuses from pregnant rats given 100 mg/kg DS-7309.

Pregnant rats (n = 20) were administered DS-7309 at 0 (vehicle) or 100 mg/kg from Days 7 to 17 of pregnancy. On Day 20 of pregnancy, Cesarean section in dams and external observation in fetuses were performed (A, B). Half of the fetal specimens were observed by Wilson's method for visceral observation after fixation in Bouin's fluid for more than 2 weeks (C, D). The thick arrow indicates absence of eye bulge. The thin arrow indicates microphthalmia. The arrowhead indicates anophthalmia.

Table 1-4 Summary results of fetal skeleton observation in fetuses from DS-7309-treated pregnant rats.

Test article	Control	DS-7309
Dose (mg/kg)	0	100
No. of dams	21	20
No. of fetuses examined	159[a]	157
Anomalies		
No. of fetuses with anomalies	3[a] (6.3 ± 22.7)[b]	0 (0.0 ± 0.0)
Misshapen frontal	1 (4.8 ± 21.8)	0 (0.0 ± 0.0)
Bent scapula	2 (1.6 ± 7.3)	0 (0.0 ± 0.0)
Variation		
No. of fetuses with variations	19[a] (11.7 ± 15.0)[b]	23 (14.1 ± 22.0)
Cervical rib	1 (0.5 ± 2.4)	0 (0.0 ± 0.0)
Full supernumerary rib	0 (0.0 ± 0.0)	2 (1.3 ± 5.6)
Short supernumerary rib	10 (5.5 ± 9.2)	18 (11.0 ± 17.6)
Wavy rib	3 (2.4 ± 10.9)	2 (1.3 ± 3.9)
Short 13th rib	0 (0.0 ± 0.0)	1 (0.6 ± 2.8)
Bipartite ossification of thoracic centrum	5 (3.3 ± 6.1)	0 (0.0 ± 0.0)[†]
Bipartite ossification of lumbar centrum	1 (0.7 ± 3.1)	0 (0.0 ± 0.0)
Sacralization	0 (0.0 ± 0.0)	1 (0.6 ± 0.4)
Ossifications		
No. of sacrocaudal vertebrae	8.2 ± 0.3[c]	8.2 ± 0.4

Pregnant rats (n = 20 to 21) were administered DS-7309 at 0 (vehicle), 3, 10, or 100 mg/kg from Days 7 to 17 of pregnancy. After Cesarean section on Day 20 of pregnancy, the skeleton anomalies and variations, and degree of ossification were examined with half of the fetal specimens.

The head was observed by Wilson's method after fixation in Bouin's fluid and the thoracic and abdominal organs were examined by Nishimura's microdissection method under a stereomicroscope.

To take into account the litter effect, the litter was used as the sample unit and the prevalence of anomalies in the fetal specimens from each dam was averaged by the number of dams.

Significant difference from the control group: [†]: $p < 0.05$ by the Wilcoxon's rank sum test.

Since no differences were noted in the skeleton observation between control and 100 mg/kg groups, 3 and 10 mg/kg groups were not examined.

[a]: Total number per group, [b]: Mean incidence ratio (%, shown as mean ± standard deviation), [c]: Mean ± standard deviation.

3.1.4. TK and blood glucose level measurement in pregnant rats

On both Days 7 and 17 of pregnancy (the first and last days of dosing), Cmax and $AUC_{0\text{-}24h}$ increased with increasing dose (Table 1-5). There were no apparent changes in the TK parameters after repeated dosing.

On Day 7 of pregnancy (the first day of dosing), blood glucose levels showed decreases at 0.5 and 7 h after dosing in all DS-7309-treated groups with statistical significance in the 100 mg/kg group at 7 h (Figure 1-4). On Day 17 of pregnancy (the last day of dosing), the blood glucose level at 0.5 h after dosing fell to approximately 40 to 50 mg/dL in all DS-7309-treated groups. In the 100 mg/kg group, this severe hypoglycemia remained at least 7 h after dosing. In the 3 and 10 mg/kg groups, severe hypoglycemia was transient and reversible. The blood glucose levels at 7 h after dosing were considered to be almost normal, although statistical significance was still shown in the 10 mg/kg group.

Table 1-5 Toxicokinetic parameters in DS-7309-treated pregnant rats.

Test article	DS-7309		
Dose (mg/kg)	3	10	100
No. of dams	5	5	5
Cmax (ng/mL)			
PD 7[a]	400 ± 220[c]	2460 ± 250	17,800 ± 3600
PD 17[b]	784 ± 232	3030 ± 1150	16,600 ± 5900
Tmax (h)			
PD 7	0.5 ± 0.0	0.5 ± 0.0	0.5 ± 0.0
PD 17	0.5 ± 0.0	0.5 ± 0.0	2.1 ± 2.8
AUC_{0-24h} (ng・h/mL)			
PD 7	494 ± 252	4380 ± 720	142,000 ± 43,000
PD 17	1060 ± 220	5560 ± 1290	147,000 ± 48,000

Pregnant rats (n = 5) were administered DS-7309 at 3, 10, or 100 mg/kg from Days 7 to 17 of pregnancy. Blood samples (0.3 mL/time point) were taken from the jugular vein of unanesthetized animals prior to dosing (only on Day 17) and at 0.5, 2, 7, and 24 h after dosing on Days 7 and 17 of pregnancy for TK analysis. Plasma concentrations of the free form of DS-7309 were measured by tandem mass spectrometry.

Cmax: Maximum plasma concentration, PD: Days of pregnancy, Tmax: Time to reach maximum plasma concentration, AUC_{0-24h}: Area under the plasma concentration-time curve up to 24 h.

[a]: The first day of dosing, [b]: The last day of dosing, [c]: Mean ± standard deviation.

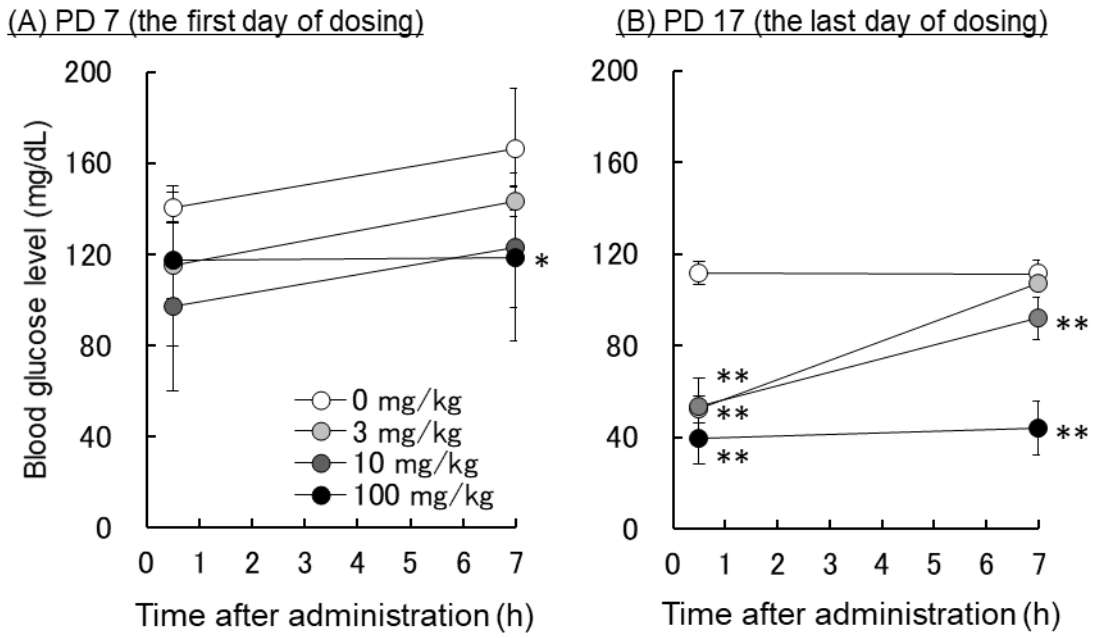

Figure 1-4 Blood glucose levels in DS-7309-treated pregnant rats.

Pregnant rats (n = 5) were administered DS-7309 at 0 (vehicle), 3, 10, or 100 mg/kg from Days 7 to 17 of pregnancy (PDs 7 to 17). Blood samples were taken from 5 rats at each time point. The measurements were conducted on PD 7 (the first day of dosing, [A]) and on PD 17 (the last day of dosing, [B]). Blood was collected 0.5 and 7 h after the dosing. Significant difference from the control group: *: $p < 0.05$, **: $p < 0.01$ by Dunnett's test.

3.2. Rabbits

3.2.1. Clinical observation, food consumption, and body weight in pregnant rabbits

One animal in the 10 mg/kg group was found dead on Day 20 of pregnancy. Before death, it did not show any changes in clinical observations, food consumption, or body weight. Furthermore, no abnormalities were noted in the macroscopic observation. Except for this rabbit, no treatment-related changes in clinical observations were induced by DS-7309.

In the 100 mg/kg group, food consumption values were higher than in the control group in the latter half of the dosing period and then decreased to the control group level after the dosing period (Figure 1-5). In the groups with doses up to 30 mg/kg, food consumption was not affected by DS-7309 treatment. No difference in body weight was detected in any DS-7309-treated groups compared with the level in the control group (Figure 1-6).

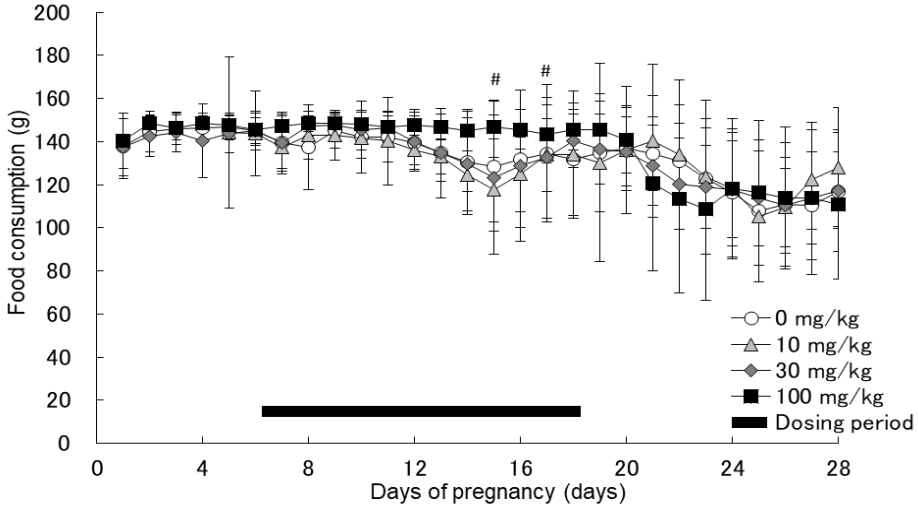

Figure 1-5 Food consumption values in DS-7309-treated pregnant rabbits.

Pregnant rabbits (n = 17 to 21) were administered DS-7309 at 0 (vehicle), 10, 30, or 100 mg/kg from Days 6 to 18 of pregnancy. Food consumption was calculated from the amount supplied on Days 1 through 28 of pregnancy and the amount remaining on the next day.

Significant difference from the control group: #: $p < 0.05$ by non-parametric Dunnett's test (joint ranking method).

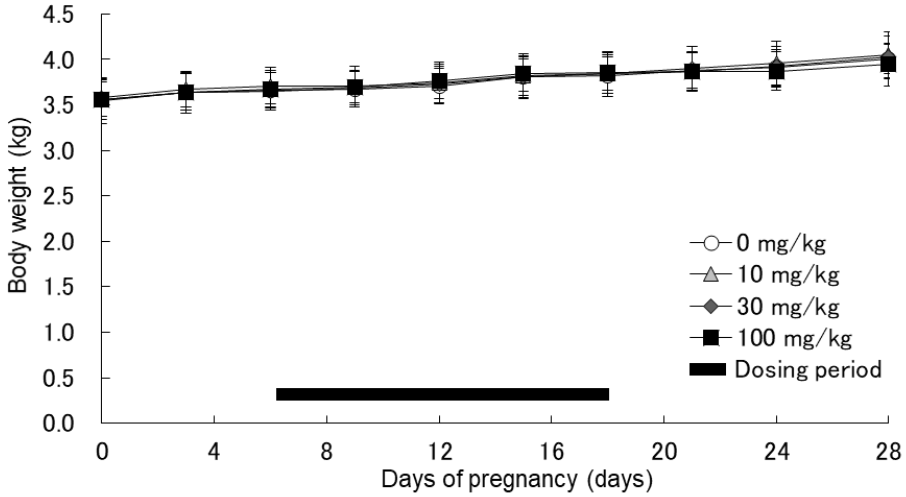

Figure 1-6 Body weight values in DS-7309-treated pregnant rabbits.

Pregnant rabbits (n = 17 to 21) were administered DS-7309 at 0 (vehicle), 10, 30, or 100 mg/kg from Days 6 to 18 of pregnancy. Body weights were measured on Days 0, 3, 6, 9, 12, 15, 18, 21, 24, and 28 of pregnancy.

3.2.2. Cesarean section of pregnant rabbits

In the 100 mg/kg group, statistically significant increases in the rate and number of post-implantation losses, and a lower number of live fetuses were noted compared with those in the control group (Table 1-6). Except for these changes, there were no treatment-related changes in the necropsy findings; the placentae findings; the numbers of corpora lutea, implantations, and live fetuses; the rate of pre-implantation loss; the rate and number of post-implantation losses; or the sex ratio.

Table 1-6 Summary results of Cesarean section of DS-7309-treated pregnant rabbits.

Test article	Control	DS-7309		
Dose (mg/kg)	0	10	30	100
No. of pregnant females	21	17	19	18
No. of dams with live fetuses	21	17	19	18
No. of corpora lutea	9.7 ± 1.4[a]	9.9 ± 1.7	10.2 ± 1.9	9.7 ± 1.6
No. of implantations	8.4 ± 1.6[a]	8.6 ± 2.3	9.5 ± 2.6	9.1 ± 1.9
Pre-implantation loss rate (%)	11.9 ± 16.3[a]	13.2 ± 15.0	8.5 ± 17.0	7.0 ± 10.4
Post-implantation loss rate (%)	2.6 ± 5.7[a]	4.9 ± 9.4	4.8 ± 8.0	40.4 ± 30.3[##]
No. of post-implantation losses	5[b] (0.2 ± 0.5)[a]	9 (0.5 ± 1.1)	9 (0.5 ± 0.8)	67 (3.7 ± 2.7)[##]
Implantation sites	0[b]	0	0	0
Early resorptions	1[b]	8	5	63
Late resorptions	0[b]	1	2	2
Dead fetuses	4[b]	0	2	2
No. of live fetuses	172[b] (8.2 ± 1.5)[a]	138 (8.1 ± 1.9)	171 (9.0 ± 2.6)	96 (5.3 ± 2.8)**
Male	93[b]	69	80	50
Female	79[b]	69	91	46
Sex ratio (male%)	54.6 ± 15.9[a]	52.5 ± 16.9	46.2 ± 19.5	53.4 ± 22.2
Fetal body weight (g)				
Male	36.2 ± 3.1[a]	36.7 ± 3.4	37.5 ± 4.6	38.5 ± 5.5
Female	35.2 ± 3.4[a]	36.2 ± 3.3	35.4 ± 5.0	36.5 ± 4.6
Necropsy findings	-	-	-	-
Placental findings	-	-	-	-

Pregnant rabbits (n = 17 to 21) were administered DS-7309 at 0 (vehicle), 10, 30, or 100 mg/kg from Days 6 to 18 of pregnancy. Cesarean section was performed on Day 28 of pregnancy.

To take into account the litter effect, the litter was used as the sample unit, and the average of pre- or post-implantation loss rate or sex ratio from each dam was averaged by the number of dams.

Significant difference from the control group: [##]: $p < 0.01$ by the non-parametric Dunnett's test (joint ranking method), **: $p < 0.01$ by Dunnett's test.

[a]: Mean ± standard deviation per litter, [b]: Total number per group, -: No noteworthy findings.

3.2.3. External, visceral, and skeleton observations in rabbit fetuses

Regarding the external observations, no statistically significant increases were noted in any groups compared with the control group (Table 1-7). Since no statistically significant increases in the visceral anomalies were induced in the group with the highest dose of DS-7309 (100 mg/kg) compared with the control group (Table 1-8), the specimens in the groups with lower doses (10 and 30 mg/kg) were not examined.

A summary of the results of skeleton observation in rabbit fetuses is shown in Table 1-9 and Figure 1-7. In the 100 mg/kg group, statistically significant increases in the prevalences of fetuses with skeleton anomalies, fused rib, and fused thoracic arch were noted compared with those in the control group (Table 1-9). Other axial skeleton anomalies such as absent rib and thoracic hemivertebra were also observed in the 100 mg/kg group, albeit without statistically significant differences compared with the control group. There were no statistically significant differences in the prevalence of fetuses with skeleton variations between the 100 mg/ kg and control groups; however, a statistically significant increase was observed in the prevalence of fetuses with lumbarization in the 100 mg/ kg group compared with that in the control group. There were no statistically significant increases in the prevalence of skeleton anomalies and variations at up to 30 mg/kg. DS-7309 did not induce apparent changes in ossification of sacrocaudal vertebrae.

Table 1-7 Summary results of fetal external observation in fetuses from DS-7309-treated pregnant rabbits

Test article	Control	DS-7309		
Dose (mg/kg)	0	10	30	100
No. of dams	21	17	19	18
No. of fetuses examined	172[a]	138	171	96
No. of fetuses with anomalies	1[a] (0.6 ± 2.7)[b]	1 (0.7 ± 3.0)	0 (0.0 ± 0.0)	2 (3.7 ± 15.7)
Omphalocele	1 (0.6 ± 2.7)	1 (0.7 ± 3.0)	0 (0.0 ± 0.0)	2 (3.7 ± 15.7)

Pregnant rabbits (n = 17 to 21) were administered DS-7309 at 0 (vehicle), 10, 30, or 100 mg/kg from Days 6 to 18 of pregnancy. Cesarean section and the external observation were performed on Day 28 of pregnancy. To take into account the litter effect, the litter was used as the sample unit and the prevalence of anomalies in the fetal specimens from each dam was averaged by the number of dams. There were no statistically significant changes.

[a]: Total number per group, [b]: Mean incidence ratio (%, shown as mean ± standard deviation).

Table 1-8 Summary results of fetal visceral observation in fetuses from DS-7309-treated pregnant rabbits.

Test article	Control	DS-7309
Dose (mg/kg)	0	100
No. of dams	21	18
No. of fetuses examined	172[a]	96
No. of fetuses with anomalies	61[a] (33.0 ± 23.8)[b]	22 (27.4 ± 26.0)
Thymic remnant in neck	1 (0.5 ± 2.4)	1 (1.9 ± 7.8)
Cor triloculare	1 (0.6 ± 2.7)	0 (0.0 ± 0.0)
Supernumerary coronary ostium	58 (31.4 ± 22.0)	16 (17.0 ± 17.4)[†]
Dilated aorta	0 (0.0 ± 0.0)	1 (5.6 ± 23.6)
Narrowed pulmonary trunk	1 (0.6 ± 2.7)	0 (0.0 ± 0.0)
Retroesophageal subclavian	2 (1.1 ± 4.8)	4 (4.3 ± 10.1)
Abnormal lung lobation	0 (0.0 ± 0.0)	1 (1.9 ± 7.8)
Absent gallbladder	0 (0.0 ± 0.0)	1 (0.6 ± 2.4)
Dilated renal pelvis	0 (0.0 ± 0.0)	1 (1.9 ± 7.8)

Pregnant rabbits (n = 17 to 21) were administered DS-7309 at 0 (vehicle), 10, 30, or 100 mg/kg from Days 6 to 18 of pregnancy. After Cesarean section on Day 28 of pregnancy, the visceral observation was performed with all fetal specimens. The thoracic and abdominal organs, and major vessels were examined macroscopically, and then the heart was examined by Nishimura's microdissection method under fixation in 10 vol% neutral buffered formalin.

To take into account the litter effect, the litter was used as the sample unit and the prevalence of anomalies in the fetal specimens from each dam was averaged by the number of dams.

Significant difference from the control group: [†]: $p < 0.05$ by the Wilcoxon's rank sum test.

Since no toxicologically significant differences were noted in the visceral observation between control and 100 mg/kg groups, 10 and 30 mg/kg groups were not examined.

[a]: Total number per group, [b]: Mean incidence ratio (%, shown as mean ± standard deviation).

Figure 1-7 Skeleton anomalies in fetuses from pregnant rabbits given 100 mg/kg DS-7309.

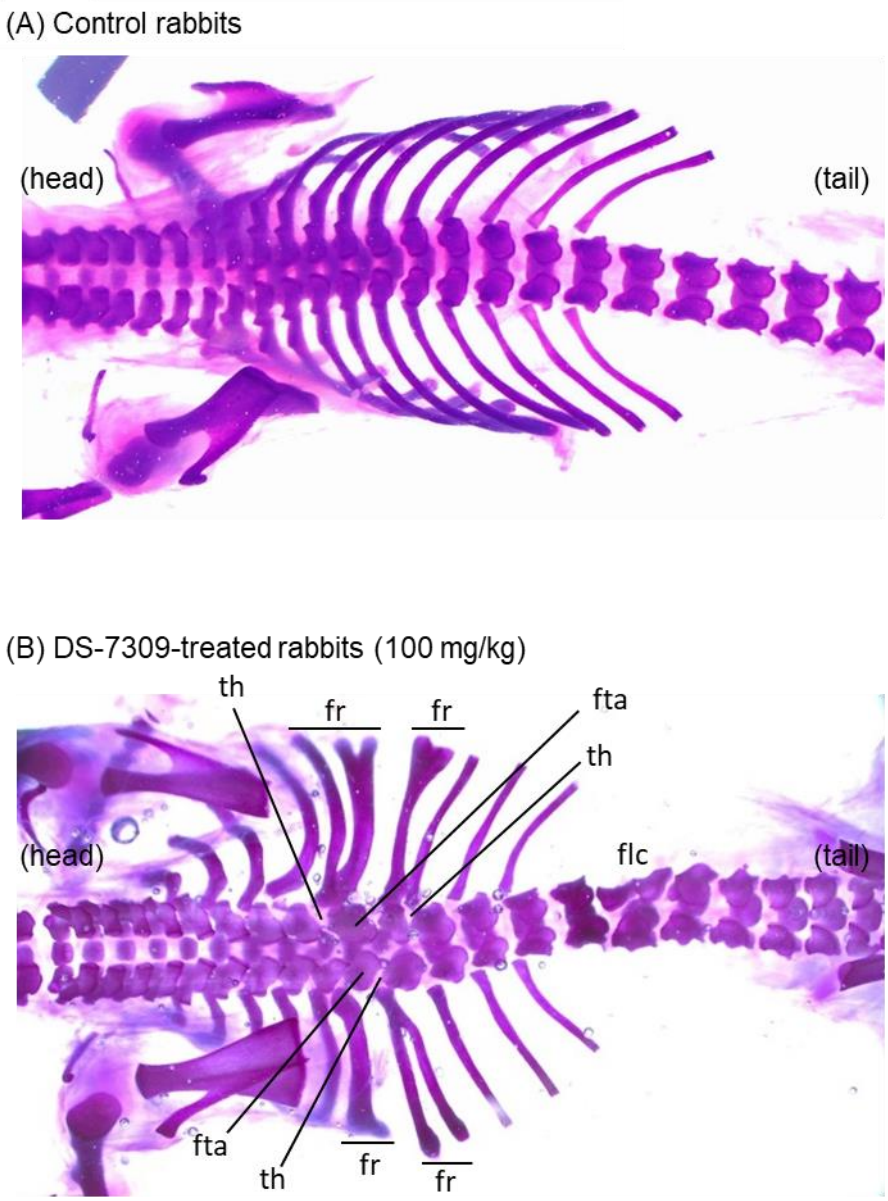

Pregnant rabbits (n = 17 to 21) were administered DS-7309 at 0 (vehicle) or 100 mg/kg from Days 6 to 18 of pregnancy. Cesarean section was performed in dams on Day 28 of pregnancy. Skeleton anomalies and variations, and the degree of ossification were examined in fetuses after staining by Dawson's method. (A): Control rabbits, (B): DS-7309-treated rabbits (100 mg/kg). th, thoracic hemivertebra; fr, fused rib; fta, fused thoracic arch; lh, lumbar hemivertebra; flc, fused lumbar centrum.

Table 1-9 Summary results of fetal skeleton observation in fetuses from DS-7309-treated pregnant rabbits

Test article	Control	DS-7309		
Dose (mg/kg)	0	10	30	100
No. of dams	21	17	19	18
No. of fetuses examined	172[a]	138	171	96
No. of fetuses with anomalies	8[a] (5.4 ± 9.2)[b]	6 (3.7 ± 12.3)	2 (1.5 ± 6.6)	33 (39.5 ± 33.3)[##]
Extra sternebral ossification site	0 (0.0 ± 0.0)	2 (1.2 ± 4.9)	0 (0.0 ± 0.0)	0 (0.0 ± 0.0)
Fused sternebra	1 (0.8 ± 3.6)	2 (1.3 ± 3.8)	0 (0.0 ± 0.0)	0 (0.0 ± 0.0)
Misaligned sternebra	2 (1.2 ± 5.5)	1 (0.6 ± 2.4)	1 (0.8 ± 3.3)	0 (0.0 ± 0.0)
Absent rib	1 (0.5 ± 2.4)	0 (0.0 ± 0.0)	1 (0.8 ± 3.3)	5 (5.2 ± 12.7)
Branched rib	2 (1.7 ± 5.9)	0 (0.0 ± 0.0)	1 (0.8 ± 3.3)	2 (2.8 ± 8.6)
Fused rib	2 (1.2 ± 3.8)	0 (0.0 ± 0.0)	0 (0.0 ± 0.0)	28 (34.2 ± 33.0)[##]
Short rib	0 (0.0 ± 0.0)	0 (0.0 ± 0.0)	0 (0.0 ± 0.0)	1 (0.9 ± 3.9)
Fused cervical arch	0 (0.0 ± 0.0)	0 (0.0 ± 0.0)	1 (0.8 ± 3.3)	0 (0.0 ± 0.0)
Fused cervical centrum	0 (0.0 ± 0.0)	0 (0.0 ± 0.0)	1 (0.8 ± 3.3)	0 (0.0 ± 0.0)
Hemicentric cervical centrum	0 (0.0 ± 0.0)	0 (0.0 ± 0.0)	1 (0.8 ± 3.3)	0 (0.0 ± 0.0)
Fused thoracic arch	1 (0.6 ± 2.7)	0 (0.0 ± 0.0)	0 (0.0 ± 0.0)	18 (25.8 ± 34.8)[##]
Small thoracic arch	0 (0.0 ± 0.0)	0 (0.0 ± 0.0)	0 (0.0 ± 0.0)	2 (3.2 ± 9.5)
Fused thoracic centrum	1 (0.5 ± 2.4)	0 (0.0 ± 0.0)	0 (0.0 ± 0.0)	1 (0.8 ± 3.4)
Hemicentric thoracic centrum	2 (1.2 ± 3.8)	0 (0.0 ± 0.0)	0 (0.0 ± 0.0)	3 (3.1 ± 7.4)
Misaligned thoracic centrum	0 (0.0 ± 0.0)	0 (0.0 ± 0.0)	0 (0.0 ± 0.0)	3 (4.6 ± 16.0)
Split cartilage of thoracic centrum	0 (0.0 ± 0.0)	0 (0.0 ± 0.0)	0 (0.0 ± 0.0)	2 (2.2 ± 6.6)
Thoracic hemivertebra	1 (0.5 ± 2.4)	0 (0.0 ± 0.0)	0 (0.0 ± 0.0)	4 (10.1 ± 25.6)
Fused lumbar arch	0 (0.0 ± 0.0)	0 (0.0 ± 0.0)	0 (0.0 ± 0.0)	2 (2.8 ± 8.6)
Fused lumbar centrum	0 (0.0 ± 0.0)	0 (0.0 ± 0.0)	0 (0.0 ± 0.0)	2 (6.5 ± 23.7)
Hemicentric lumbar centrum	0 (0.0 ± 0.0)	0 (0.0 ± 0.0)	0 (0.0 ± 0.0)	2 (3.7 ± 15.7)
Misaligned lumbar centrum	0 (0.0 ± 0.0)	0 (0.0 ± 0.0)	0 (0.0 ± 0.0)	1 (1.9 ± 7.8)
Lumbar hemivertebra	0 (0.0 ± 0.0)	0 (0.0 ± 0.0)	0 (0.0 ± 0.0)	1 (5.6 ± 23.6)
Supernumerary lumbar vertebra	0 (0.0 ± 0.0)	1 (0.6 ± 2.4)	0 (0.0 ± 0.0)	1 (1.9 ± 7.8)
Fused sacral arch	0 (0.0 ± 0.0)	0 (0.0 ± 0.0)	0 (0.0 ± 0.0)	2 (2.8 ± 8.6)
Misaligned sacral centrum	0 (0.0 ± 0.0)	0 (0.0 ± 0.0)	0 (0.0 ± 0.0)	1 (0.9 ± 4.0)
Split cartilage of sacral centrum	0 (0.0 ± 0.0)	0 (0.0 ± 0.0)	0 (0.0 ± 0.0)	1 (1.9 ± 7.8)

Test article	Control	DS-7309		
Dose (mg/kg)	0	10	30	100
No. of dams	21	17	19	18
No. of fetuses examined	172[a]	138	171	96
Fused caudal centrum	2 (1.3 ± 4.3)	0 (0.0 ± 0.0)	0 (0.0 ± 0.0)	1 (1.4 ± 5.9)
Hemicentric caudal centrum	0 (0.0 ± 0.0)	0 (0.0 ± 0.0)	0 (0.0 ± 0.0)	1 (0.9 ± 3.9)
Misaligned caudal centrum	0 (0.0 ± 0.0)	0 (0.0 ± 0.0)	0 (0.0 ± 0.0)	2 (2.8 ± 8.6)
Misshapen caudal centrum	0 (0.0 ± 0.0)	0 (0.0 ± 0.0)	0 (0.0 ± 0.0)	1 (1.1 ± 4.7)
No. of litters with variations	20	16	19	17
No. of fetuses with variations	134[a] (75.2 ± 28.9)[b]	111 (77.7 ± 28.2)	134 (79.0 ± 19.1)	84 (81.7± 28.0)
Cervical rib	3 (1.7 ± 5.6)	3 (2.2 ± 4.9)	5 (3.3 ± 7.5)	1 (0.9 ± 3.9)
Full supernumerary rib	89 (50.4 ± 33.3)	89 (62.3 ± 33.4)	104 (60.8 ± 26.6)	71 (70.8 ± 30.9)
Short supernumerary rib	40 (21.4 ± 22.8)	19 (13.2 ± 14.6)	24 (14.5 ± 15.1)	11 (8.6 ± 15.4)
Sacralization	2 (1.6 ± 7.3)	0 (0.0 ± 0.0)	0 (0.0 ± 0.0)	0 (0.0 ± 0.0)
Lumbarization	27 (15.1 ± 19.4)	44 (29.6 ± 29.2)	33 (20.8 ± 21.8)	59 (61.3 ± 36.2)[##]
Unossified pubis	2 (1.2 ± 3.8)	0 (0.0 ± 0.0)	3 (1.8 ± 4.5)	1 (0.5 ± 2.1)
Ossifications				
No. of sacrocaudal vertebrae	19.5 ± 0.5[c]	19.6 ± 0.5	19.7 ± 0.4	19.8 ± 0.5

Pregnant rabbits (n = 17 to 21) were administered DS-7309 at 0 (vehicle), 10, 30, or 100 mg/kg from Days 6 to 18 of pregnancy. After Cesarean section on Day 28 of pregnancy, the skeleton anomalies and variations, and the degree of ossification were examined with all fetal specimens stained by Dawson's method. To take into account the litter effect, the litter was used as the sample unit and the prevalence of anomalies in the fetal specimens from each dam was averaged by the number of dams.

Significant difference from the control group: [##]: $p < 0.01$ by the non-parametric Dunnett's test (joint ranking method).

[a]: Total number per group, [b]: Mean incidence ratio (%, shown as mean ± standard deviation),

[c]: Mean ± standard deviation.

3.2.4. TK and blood glucose level measurement in pregnant rabbits

The Cmax and $AUC_{0\text{-}24h}$ values increased with increasing DS-7309 dose (Table 1-10). There were no apparent changes in the TK parameters after repeated dosing.

Blood glucose levels after DS-7309 dosing in pregnant rabbits are shown in Figure 1-8. On Day 6 of pregnancy (the first day of dosing), the blood glucose levels decreased to approximately 100 mg/dL 0.5 h after the dosing in all DS-7309-treated groups and the duration of these low blood glucose levels was prolonged according to the dose increment. In the 10 mg/kg group, the decreased blood glucose level recovered to almost the same level as in the control group by 2 h after dosing. In the 30 mg/kg group, the lower glucose level was sustained until 4 h after dosing, and then recovered to almost the same level as in the control group at 7 h after dosing. Meanwhile, in the 100 mg/kg group, the decreased glucose level (around 100 mg/dL) was sustained until 7 h after dosing and then returned to the control level at 24 h after dosing. On Day 18 of pregnancy (the last day of dosing), the decreases in blood glucose levels induced by DS-7309 were more pronounced. The blood glucose level fell to approximately 90 mg/dL in the 10 mg/kg group or to approximately 60 mg/dL in the 30 and 100 mg/kg groups. The duration of these low blood glucose levels was prolonged with a dose increment. The blood glucose level recovered to almost the same level as in the control group by 4 h after dosing in the 10 mg/kg group, 7 h after dosing in the 30 mg/kg group, but 24 h after dosing in the 100 mg/kg group.

Table 1-10 Toxicokinetic parameters in DS-7309-treated pregnant rabbits.

Test article	DS-7309		
Dose (mg/kg)	10	30	100
No. of dams	3	3	3
Cmax (ng/mL)			
PD 6[a]	52.5 ± 28.1[c]	824 ± 513	3100 ± 1610
PD 18[b]	54.2 ± 33.5	822 ± 65	6370 ± 2790
Tmax (h)			
PD 6	0.5 ± 0.0	0.5 ± 0.0	1.5 ± 0.9
PD 18	0.5 ± 0.0	0.5 ± 0.0	0.5 ± 0.0
$AUC_{0\text{-}24h}$ (ng・h/mL)			
PD 6	90.1 ± 26.8	1130 ± 580	6720 ± 1810
PD 18	95.9 ± 28.3	1190 ± 180	9710 ± 1650

Pregnant rabbits (n = 3) were administered DS-7309 at 10, 30, or 100 mg/kg from Days 6 to 18 of pregnancy. Blood samples (0.3 mL/time point) were taken from the auricular vein of unanesthetized animals prior to dosing (only on Day 18) and at 0.5, 2, 4, 7, and 24 h after dosing on Day 6 and 18 of pregnancy for TK analysis.

Cmax: Maximum observed plasma concentration, PD: Days of pregnancy, Tmax: Time to reach maximum plasma concentration, $AUC_{0\text{–}24h}$: Area under the plasma concentration-time curve up to 24 h.

[a]: The first day of dosing, [b]: The last day of dosing, [c]: Mean ± standard deviation.

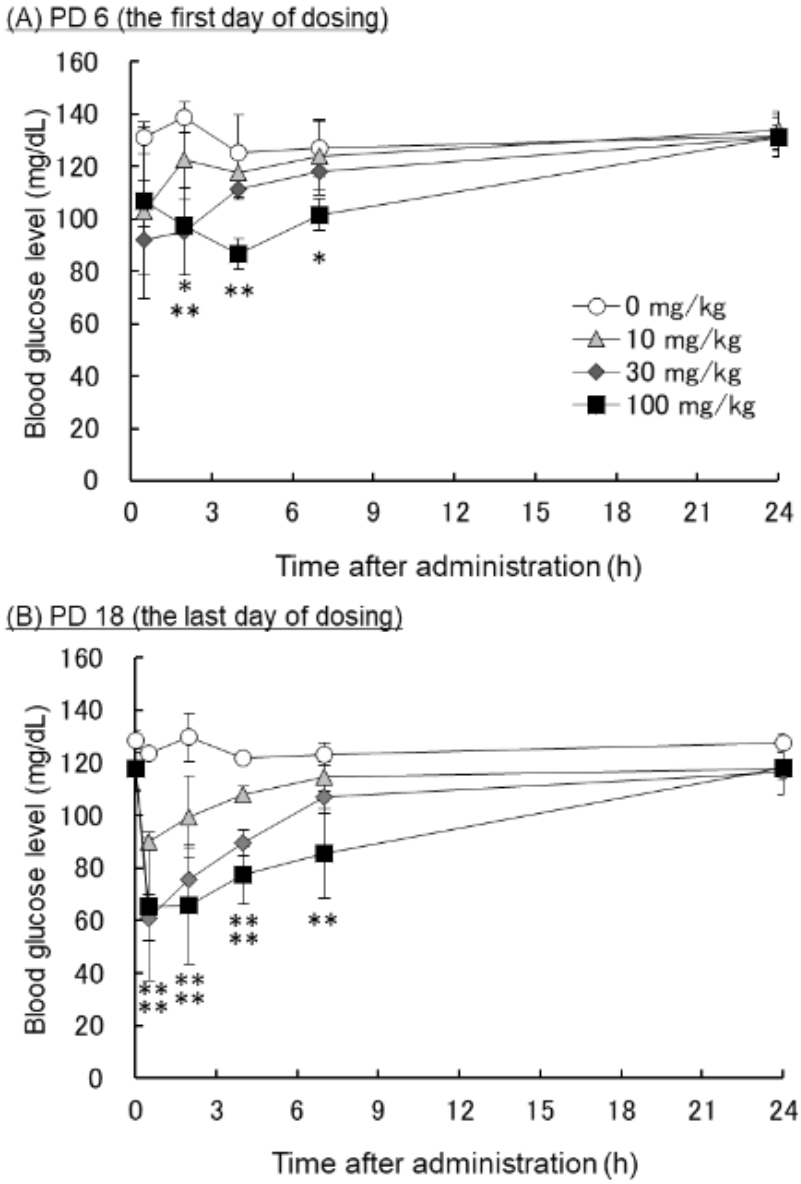

Figure 1-8 Blood glucose levels in DS-7309-treated pregnant rabbits.

Pregnant rabbits (n = 3) were administered DS-7309 at 0 (vehicle), 10, 30, or 100 mg/kg from Days 6 to 18 of pregnancy (PDs 6 to 18). Blood samples were taken from 3 rabbits at each time point. The measurements were conducted on PD 6 (the first day of dosing, [A]) and on PD 18 (the last day of dosing, [B]). Blood was collected prior to dosing (only on PD 18) and at 0.5, 2, 4, 7, and 24 h after the dosing.

Significant difference from the control group: *: $p < 0.05$, **: $p < 0.01$ by Dunnett's test.

4. Discussion

DS-7309 is a GK activator that was expected to decrease the maternal blood glucose level. Since it has been reported that maternal hypoglycemia during pregnancy can induce pregnancy failure and/or impaired embryo-fetal development in animals [9,19,31], the author measured maternal time-course changes in blood glucose levels and examined the effects of DS-7309 on reproduction and embryo-fetal toxicity in rats and rabbits.

Blood glucose levels decreased after dosing on Days 7 and 17 of pregnancy in all DS-7309-treated pregnant rats with dose increment, consistent with the Cmax and $AUC_{0\text{-}24h}$ values, which increased with increasing dose. In contrast to the transiently reduced glucose levels in the groups treated at doses up to 10 mg/kg, the 100 mg/kg group showed severe (approximately 40 mg/dL) and sustained hypoglycemia on Day 17 of pregnancy. Increased food consumption during the dosing period was observed only in the 100 mg/kg group, which suggested compensatory reactions to hypoglycemia and reflected a severe and consistent hypoglycemic condition. Then, food consumption turned to decrease after the dosing period as an adaptive response to the increased food consumption subsequent to hypoglycemia during the dosing period.

In the fetal examinations, live fetal body weight was significantly decreased in the 100 mg/kg group. In this group, DS-7309 also induced eye anomalies such as absent and small eye bulge, anophthalmia, microphthalmia, and coloboma of the optic nerve. Eriksson reported that maternal hypoglycemia during pregnancy induces clear fetal body weight loss and fetal teratogenicity including the same eye anomalies as seen in the present study [19]. In several reports, insulin was injected into pregnant animals in order to investigate the effects of maternal hypoglycemia during pregnancy on their fetuses. This approach was applied because insulin does not pass the placental barrier by facilitated diffusion due to its large molecular size, so it does not affect fetuses directly. Even when extremely small amounts of insulin-IgG immune complex were transferred via FcRn during the late pregnancy period, any significant effects on fetuses were not observed [23,63,81]. Jensen et al. reported that maternal hypoglycemia induced by insulin caused impairment of embryo-fetal development including decreased fetal body weight and fetal eye anomalies such as microphthalmia in rats [36]. Miyamoto et al. and Chomette also showed that insulin-induced maternal hypoglycemia caused similar fetal eye anomalies in rats [52,53] and rabbits [14]. Accordingly, decreased fetal body weight and fetal eye anomalies

induced by DS-7309 were considered to be a result of maternal hypoglycemia rather than the direct effect of DS-7309 on the fetuses, although the possibility of DS-7309 having a direct effect cannot be completely ruled out. While eye anomalies such as small eye bulge, microphthalmia, and coloboma of the optic nerve were noted in the 3 mg/kg group, these findings were not considered to be treatment-related due to the lack of dose dependence and the prevalences generally being within the range of historical data of the test facility (e.g., 0.0% to 0.4% for small eye bulge, 0.0% to 0.8% for microphthalmia).

In the rabbit study, one dam died in the 10 mg/kg group; however, this death was not judged as treatment-related since no abnormalities in clinical signs, body weight, food consumption, or necropsy were noted in this animal, and neither death nor any clinical signs were observed at up to 300 mg/kg in a DF study. After dosing of DS-7309, the blood glucose levels decreased to approximately 100 mg/dL in all DS-7309- treated groups, accompanied by a remarkable reduction to approximately 60 mg/dL after repeat dosing in the 30 and 100 mg/kg groups. The duration of hypoglycemia was observed to be prolonged with dose increment on both Day 6 and Day 18 of pregnancy. In the 100 mg/kg group, the longest persistence of severe maternal hypoglycemia was observed up to 7 h after dosing and then recovered at 24 h after dosing. In contrast, the blood glucose levels at up to 30 mg/kg were almost comparable to that in the control group at 7 h after dosing. Similar to the findings in the rat study, higher food consumption was seen in the 100 mg/kg rabbit group than in the control group during the dosing period, which then decreased after the dosing period. This is also considered to have been due to compensation for the severe and sustained hypoglycemia.

In the Cesarean section of pregnant rabbits, there were statistically significant increases in the number and rate of post-implantation losses, and a decrease in the number of live fetuses in the 100 mg/kg group. These changes may also have been induced by severe maternal hypoglycemia, which alters hormone levels and results in an inability to maintain the decidua, as discussed by Hannah and Moore [29]. Several reports have also described that embryo-fetal death was caused by insulin-induced maternal hypoglycemia [19,29,31].

In the fetal skeleton examination, axial skeleton anomalies were observed only in the 100 mg/kg group. Eriksson also indicated that maternal hypoglycemia during pregnancy induced fetal skeleton anomalies as well as eye anomalies in several experimental animals [19]. Additionally, axial skeleton anomalies in the fetuses of dams with insulin-induced

hypoglycemia were reported in rats by Tanigawa [76] and mice by Smithberg [72]. Therefore, the fetal skeleton anomalies observed in this study were considered to be attributable to maternal hypoglycemia, although a direct effect of DS-7309 cannot be completely ruled out.

In conclusion, DS-7309 showed hypoglycemic effects with dose increment in both rats and rabbits, and severe and sustained maternal hypoglycemia was noted only in the 100 mg/kg group. Although it cannot be completely clarified whether the fetal anomalies were caused by maternal hypoglycemia or GK activation via a direct effect of DS-7309, the author considered that the eye anomalies in rat fetuses and skeleton anomalies in rabbit fetuses were attributable to maternal hypoglycemia, in turn leading to fetal hypoglycemia. Decreased fetal body weight in rats and increases in the number and rate of post-implantation losses, and decreases in the number of live fetuses in rabbits could also be related to maternal hypoglycemia. These findings indicate that the treatment with DS-7309 could lead to embryo-fetal toxicity including teratogenicity in rats and rabbits. Severe and continuous maternal hypoglycemia was considered to be an important factor for this embryo-fetal toxicity, although the mechanism underlying the embryo-fetal toxicity from maternal hypoglycemia remains incompletely understood. Investigating the relationship between the severity/duration of hypoglycemia and fetal anomalies, and the process by which eye and skeleton anomalies develop may provide novel insights into the mechanism of embryo-fetal toxicity under maternal hypoglycemia.

5. Summary

The toxicological effects of DS-7309, a glucokinase activator, on pregnancy and embryo-fetal development in rats and rabbits and maternal blood glucose levels were examined. DS-7309 was administered at 3, 10, or 100 mg/kg to rats from Days 7 to 17 of pregnancy or at 10, 30, or 100 mg/kg to rabbits from Days 6 to 18 of pregnancy. In rats, maternal hypoglycemia (approximately 50 mg/dL) was seen at 3 and 10 mg/kg, but it recovered 7 h after dosing, leading to no toxic changes. In contrast, continuous severe maternal hypoglycemia (approximately 40 mg/dL, ≥7 h), fetal eye anomalies, and decreased fetal body weight were noted at 100 mg/kg. In rabbits, no fetal anomalies were seen at 10 and 30 mg/kg where maternal blood glucose level dropped to approximately 60 to 90 mg/dL, but recovered by 7 h after dosing at the latest. In contrast, at 100 mg/kg, severe hypoglycemia (around 60 mg/dL) was maintained and did not recover until 24 h after dosing; it resulted in decreased fetal viability and increased fetal skeleton anomalies. These findings indicate that DS-7309 could lead to embryo-fetal toxicity in rats and rabbits, with such toxicity considered to be related to continuous severe maternal hypoglycemia.

Chapter 2.

Effects of maternal hypoglycemia on fetal eye and skeleton development in rats

1. Introduction

As shown in Chapter 1, DS-7309 exhibited hypoglycemia and teratogenicity on fetal eye and skeleton in rats and rabbits, respectively. Fetal toxicity caused by DS-7309 was considered to be related to the duration and severity of maternal hypoglycemia because lower doses of DS-7309 induced mild to severe but rapidly recovered hypoglycemia without accompanying teratogenicity, while teratogenicity on fetuses was recognized only at the highest dose that induced continuous (≥7 h) and severe (approximately 50 mg/dL) maternal hypoglycemia. It has also been described that maternal hypoglycemia during pregnancy induces pregnancy failure and/or impaired embryo-fetal development in chickens, mice, rats, and rabbits [10,19,31]; however, some other in vivo studies demonstrated that severe maternal hypoglycemia did not show teratogenicity despite causing severe hypoglycemia [29,31,38,65]. The reason for this discrepancy has not been fully elucidated yet. Furthermore, it was still unclear how fetal anomalies develop when the drug induces maternal hypoglycemia.

To investigate the effects of maternal hypoglycemia during pregnancy on fetuses, the author conducted a further experiment using insulin because insulin does not pass the placental barrier by facilitated diffusion due to its large molecular size, so it rarely affects fetuses directly [23,63,81]. In this experiment, since fetal examination was conducted in late pregnancy period, the author focused on eye and skeleton anomalies, which DS-7309 also induced in rats and rabbits EFD studies. To compare the duration of maternal hypoglycemia, the author used the following four different forms of insulin: insulin human and insulin aspart, which are taken shortly before mealtimes and work quickly to control the rapid rise in blood glucose level after a meal [77,78]; and insulin glargine and insulin detemir, which are taken once daily for 24 h insulin coverage and work longer to control blood glucose level throughout the day.

2. Materials and methods

2.1. Insulin

Four forms of insulin injection were used for this research. (1) Insulin human [genetical recombination (Novolin R®, Novo Nordisk, Denmark)] at 200 IU/kg, qd, (2) insulin aspart [genetical recombination (NovoRapid®, Novo Nordisk, Denmark)] at 200 or 400 IU/kg, bid (2nd dose was given 4 h after 1st administration), (3) insulin glargine [genetical recombination (Lantus®, Sanofi, France)] at 100 or 200 IU/kg, qd, and (4) insulin detemir [genetical recombination (Levemir®, Novo Nordisk, Denmark)] at 300 or 500 IU/kg, qd. Physiological saline (Japanese Pharmacopoeia, Otsuka Pharmaceutical Factory, Inc., Japan) was used as a vehicle control. Dose levels and regimens were selected to induce maternal hypoglycemia without lethality [55, 56,57,69)] and dose levels were approximately 9 to 12,000 times higher than human therapeutic dose levels when calculated as units/body surface area assuming the human body weight was 60 kg [13)].

2.2. Animals

Female and male Sprague-Dawley rats were obtained from Charles River Laboratories Japan, Inc. (Kanagawa, Japan). After acclimatization, male and female rats were housed together for mating at 10 to 12 weeks of age. The day on which copulation was confirmed was referred to as Day 0 of pregnancy. Rats were housed individually in bracket cages except for the mating period and kept in a controlled environment at a room temperature from 20°C to 26°C, and humidity from 30% to 70% with an illumination period of 12 h per day (6:00 to 18:00 or 18:00 to 6:00 in Experiment 1, 7:00 to 19:00 in Experiment 2). Certified pellet food sterilized by ^{60}Co-γ irradiation (30 kGy, CRF-1, Oriental Yeast Co., Ltd.) and tap water were supplied *ad libitum*. All animal procedures were performed in accordance with the guidelines of the Animal Care and Use Committee of DAIICHI SANKYO CO., LTD. (Tokyo, Japan). The experimental protocols were approved by the Institutional Animal Care Committee of DAIICHI SANKYO CO., LTD.

2.3. Experimental protocol

2.3.1. Blood glucose level measurement:

Six pregnant rats per group were given aforementioned insulin injections subcutaneously from Days 6 to 11 of pregnancy 2 h after the lights came on. Dosing period was determined since this period covered sensitive period of eye and axial skeleton anomalies, and the previous reports [52,53,76] support the appropriateness of this dosing period. Blood collection (0.2 mL/timepoint) for glucose level measurement was done from the jugular vein of unanesthetized animals on Days 6 and 11 of pregnancy prior to dosing and 1, 3, 6, 9, 12, 15, 18, 21, and 24 h after dosing from 3 animals at each time point. Whole blood samples were collected in blood sampling tubes containing heparin lithium (Microtainer: Nippon Becton Dickinson Company, Ltd., Japan) and centrifuged at 8,000 × g and 4°C for 5 minutes to obtain plasma. Blood glucose levels were measured using an autoanalyzer (TBA-2000FR, Toshiba Medical Systems Corporation, Japan). After the final blood collection, all rats were euthanized by inhalation of excessive amounts of carbon dioxide on Day 12 or Day 13 of pregnancy.

2.3.2. Teratogenicity examination:

Six to 8 pregnant rats per group were given insulin injections in the same manner as in Experiment 1. Food consumption was calculated from the amount supplied on Days 2, 6, 7, 9, 11, 14, 16, and 19 of pregnancy and the amount remaining on the next day. Body weights were measured on Days 0, 3, 6, 8, 10, 12, 15, 17, and 20 of pregnancy. On Day 20 of pregnancy, pregnant rats were euthanized by carbon dioxide inhalation, and necropsy and Cesarean section was performed as done in Chapter 1. Each fetus was divided into 2 parts (head and body), and the head was examined by Wilson's method after fixation in Bouin's fluid [83]. Skeleton anomalies, variations, and the degree of ossification were examined with the trunk of the body stained by Dawson's method [18].

2.4. Statistical analysis

For blood glucose level, food consumption, body weight, fetal body weight, and number of corpora lutea, implantations, post-implantation losses, live fetuses, and sacrocaudal vertebrae, group mean ± SD values were calculated at each time point. Then, the difference of mean values between the control group and treatment groups were statistically analyzed as follows. The homogeneity of the variance between groups was

analyzed by Bartlett's test. If the variance was homogeneous, Dunnett's test was subsequently applied. If the variance was not homogeneous, then nonparametric Dunnett's test was applied. For pre- and post-implantation loss rate, sex ratio, rate of fetuses with external, head, or skeleton anomalies or variations, two-tailed Fisher's exact test was applied. A *P*-value less than 0.05 was classified as a statistically significant change.

3. Results

3.1. Blood glucose level measurement:

The blood glucose levels after insulin injection to pregnant rats are shown in Figure 2-1. All four forms of insulin caused hypoglycemia. The duration of hypoglycemia was different among groups, but it was induced in a dose-dependent manner within the same forms of insulin.

3.1.1. Day 6 of pregnancy (the first day of dosing)

In insulin human or aspart groups, glucose levels decreased to approximately 50 mg/dL and the changes were sustained until 6 h after injection (Figure 2-1, A). Then, glucose levels increased to almost the same level as in the control group by 9 h (insulin human or aspart [low dose]) or 12 h after injection (aspart [high dose]). After injection of glargine or detemir, glucose levels of pregnant rats also decreased to approximately 50 mg/dL and were sustained at this level until 9 h after injection (Figure 2-1, A). Then, blood glucose levels began to increase in both glargine and detemir groups; however, the levels remained lower than those in the control group until 18 h after injection.

3.1.2. Day 11 of pregnancy (the final day of dosing)

Each insulin injection induced hypoglycemia as on Day 6 of pregnancy and its severity of change was similar (Figure 2-1, B). On the other hand, the duration of hypoglycemia in the glargine or detemir groups extended to 15 or 24 h, respectively, after injection on Day 11 of pregnancy compared with 9 h after injection on Day 6 of pregnancy .

3.2. Teratogenicity examination:

3.2.1. Clinical observation, food consumption, and body weight in pregnant rats after the insulin injection

In the detemir (high dose) group, 1 dam died on Day 10 of pregnancy and 2 dams showed abnormalities such as decreased activity and/or irregular respiration on Day 11 of pregnancy. Other insulin injections did not cause any changes in general condition. The mean food consumption and body weight values are shown in Figures 2-2 and 2-3, respectively. During the treatment period, food consumption and body weight gain increased in the glargine or detemir groups. Other insulin injections caused no treatment-related changes in food consumption or body weight.

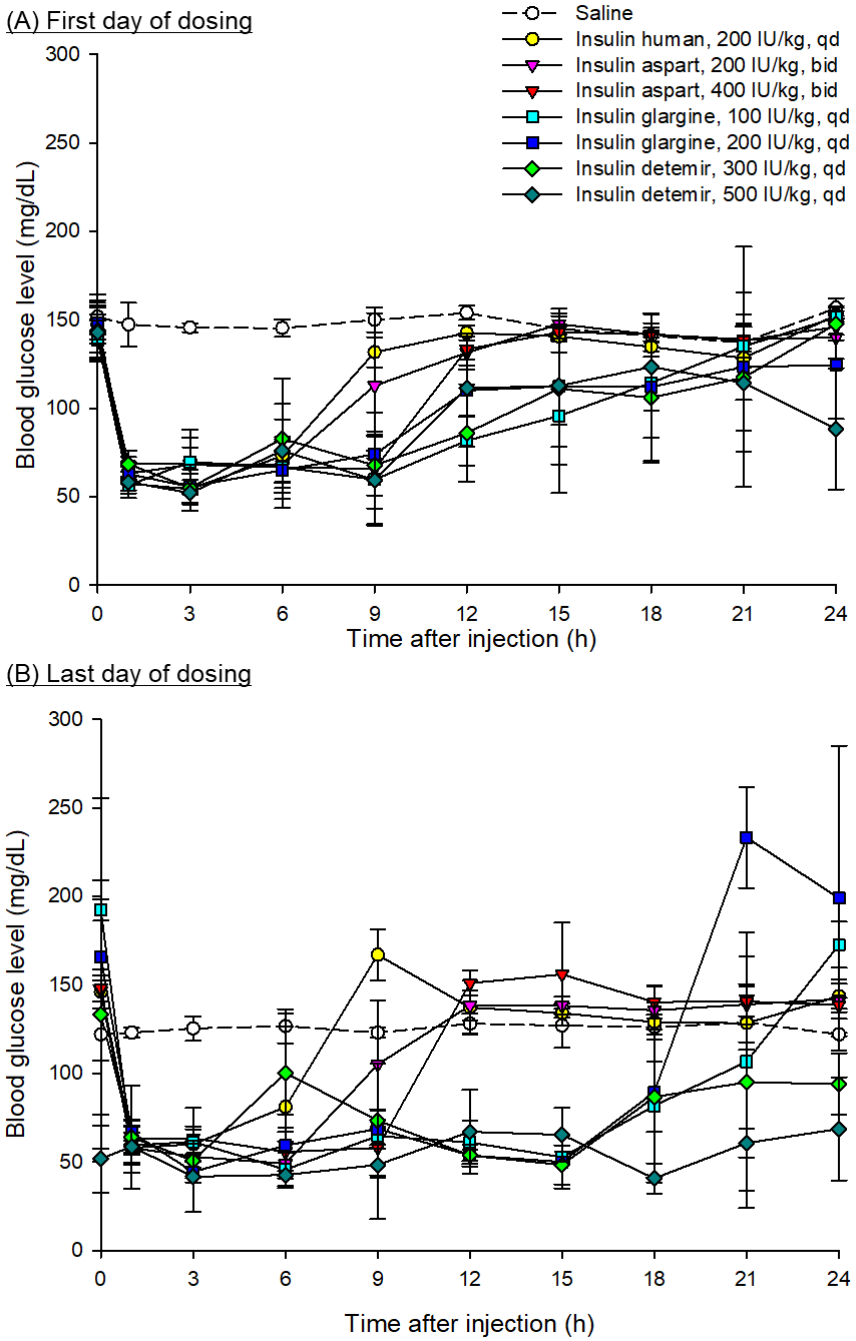

Figure 2-1 Time course of blood glucose levels in 4 different forms of insulin-treated groups.

Total of 6 pregnant rats were given insulin injections and blood samples were taken from 3 rats at each time point. The measurements were conducted on Day 6, the first day of dosing (A) and on Day 11, the last day of dosing (B). Blood was collected prior to dosing and 1, 3, 6, 9, 12, 15, 18, 21, 24 h after dosing. All values represent means.

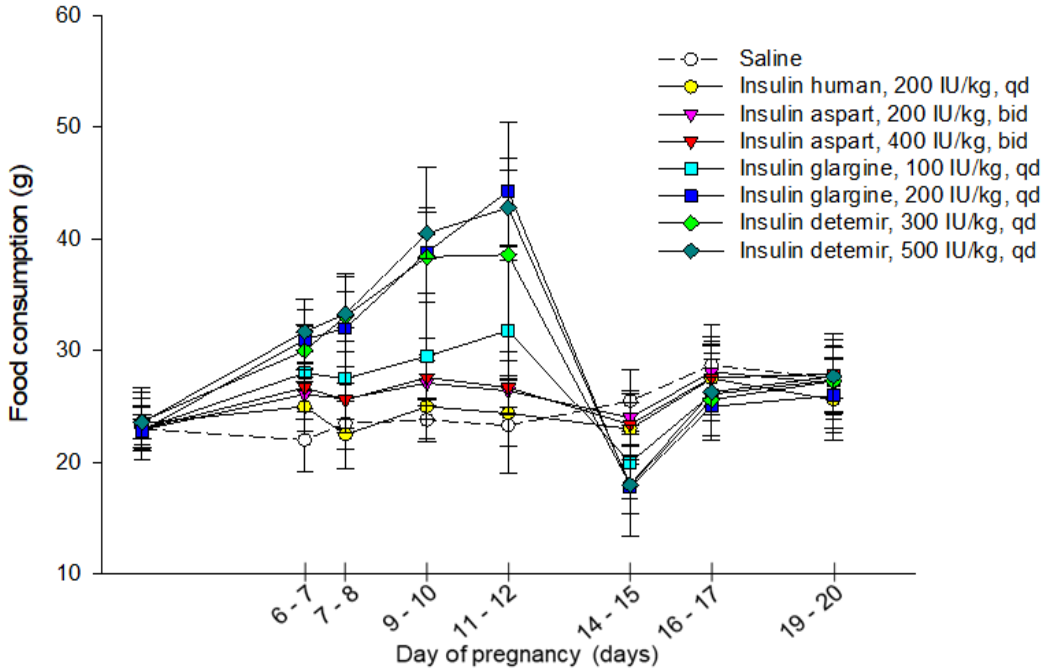

Figure 2-2 Food consumption values in 4 different forms of insulin-treated groups. Food consumption was calculated from the amount supplied on Days 2, 6, 7, 9, 11, 14, 16, and 19 of pregnancy and the amount remaining on the next day.

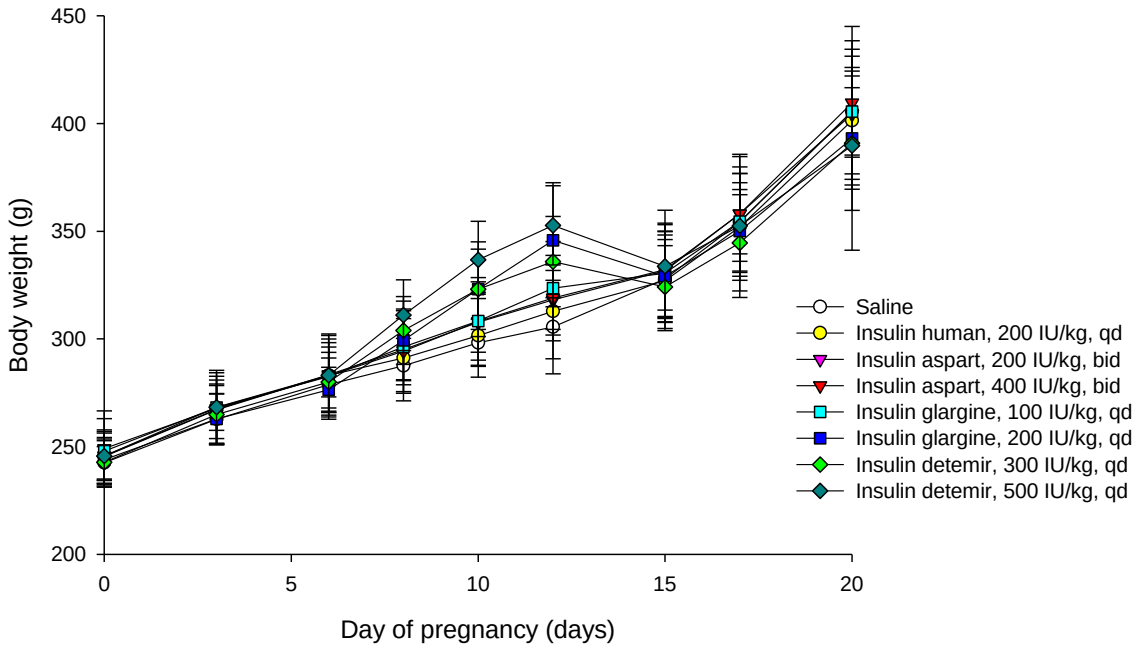

Figure 2-3 Body weight values in 4 different forms of insulin-treated groups.
Body weights were measured on Days 0, 3, 6, 8, 10, 12, 15, 17, and 20 of pregnancy.

3.2.2. Cesarean section of pregnant rats

Summary results of Cesarean section of pregnant rats treated with 4 different forms of insulin are shown in Table 2-1. Increases in the number or rate of post implantations losses, the number of early resorptions, and a decrease in the number of live fetuses were seen in the high-dose of glargine or detemir groups with the statistical significances on the rate of post-implantation losses (Table 2-1). Other insulin injections caused no treatment-related changes in the necropsy findings; the placentae; the number of corpora lutea, implantations, and live fetuses; the rate of pre-implantation loss; and the rate or number of post-implantation losses; or sex ratio.

Table 2-1 Summary results of Cesarean section of 4 different forms of insulin-treated groups.

Test article	Control	Insulin Human	Insulin Aspart		Insulin Glargine		Insulin Detemir	
Dose (IU/kg)	0	200	200	400	100	200	300	500
No. of pregnant females	6	8	7	7	8	8	7	6
No. of dams with live fetuses	6	8	7	7	8	8	7	6
No. of corpora lutea	15.8[a]	14.8	16.0	15.7	16.0	14.8	14.1	15.7
No. of implantations	14.8[a]	14.4	14.0	15.6	15.5	13.4	14.0	14.0
Pre-implantation loss rate (%)	6.3	2.5	12.5	0.9	3.1	9.3	1.0	10.6
Post-implantation loss rate (%)	2.2	4.3	7.1	4.6	4.8	14.0**	9.2	21.4**
No. of post-implantation losses	2[b] (0.3)	5 (0.6)	7 (1.0)	5 (0.7)	6 (0.8)	15 (1.9)	9 (1.3)	18 (3.0)
Implantation sites	0[b]	0	0	0	0	0	0	0
Early resorptions	2[b]	4	6	5	6	15	7	18
Late resorptions	0[b]	1	0	0	0	0	2	0
Dead fetuses	0[b]	0	1	0	0	0	0	0
No. of live fetuses	87[b] (14.5)[a]	110 (13.8)	91 (13.0)	104 (14.9)	118 (14.8)	92 (11.5)	89 (12.7)	66 (11.0)
Male	45[b]	62	55	50	60	45	43	37
Female	42[b]	48	36	54	58	47	46	29
Sex ratio (Male%)	51.7	56.4	60.4	48.1	50.8	48.9	48.3	56.1
Fetal Body Weight (g)								
Male	4.04[a]	3.99	4.01	3.88	3.84	3.71	3.80	3.81
Female	3.83[a]	3.81	3.69	3.71	3.69	3.53	3.61	3.54
Necropsy findings	-	-	-	-	-	-	-	-
Placental findings	-	-	-	-	-	-	-	-

Pregnant rats (n = 6 to 8) were administered insulin human at 200 IU/kg, insulin aspart at 200 or 400 IU/kg, insulin glargine at 100 or 200 IU/kg, or insulin detemir at 300 or 500 IU/kg from Days 6 to 11 of pregnancy. Cesarean section was performed on Day 20 of pregnancy.

Significant difference from the control group: **:$p < 0.01$ by Fisher's exact test.

[a]: Mean value, [b]: Total number per group, -: No noteworthy findings.

3.2.3. External, head and skeleton observations in fetuses

Summary results of external and head observation in fetuses are shown in Table 2-2 and Figure 2-4. In the control group, both eye bulges were observed in external observations (Figure 2-4, A), and normal eye were observed in head observations (Figure 2-4, C). In the glargine or detemir groups, absent eye bulges were observed in external observations (Figure 2-4, B). Eye anomalies such as anophthalmia and microphthalmia, and coloboma of optic nerve were observed in head observations (Figure 2-4, D). Eye anomalies were seen unilaterally or bilaterally, and increases in the incidence of fetuses with eye anomalies in the glargine (high dose) and detemir groups were statistically significant (Table 2-2). In insulin human and aspart groups, no external anomalies, including eye anomalies, were observed.

Summary results of skeleton observation in fetuses are shown in Table 2-2 and Figure 2-5. Normal axial skeleton were observed in the control group (Figure 2-5, A). Axial skeleton anomalies (thoracic vertebrae and rib) were observed in the aspart (high dose), glargine or detemir groups (Figure 2-5, B). A statistically significant increase in the incidence of fetuses with axial skeleton anomalies was seen in the detemir (high dose) group and an increase in the incidence of skeleton variations (thoracic vertebrae and rib) was observed in all insulin treated groups (Table 2-2). Insulin human or aspart (low dose) did not induce any skeleton anomalies or variations. There were no apparent changes in ossifications of sacrocaudal vertebrae in any insulin treated group

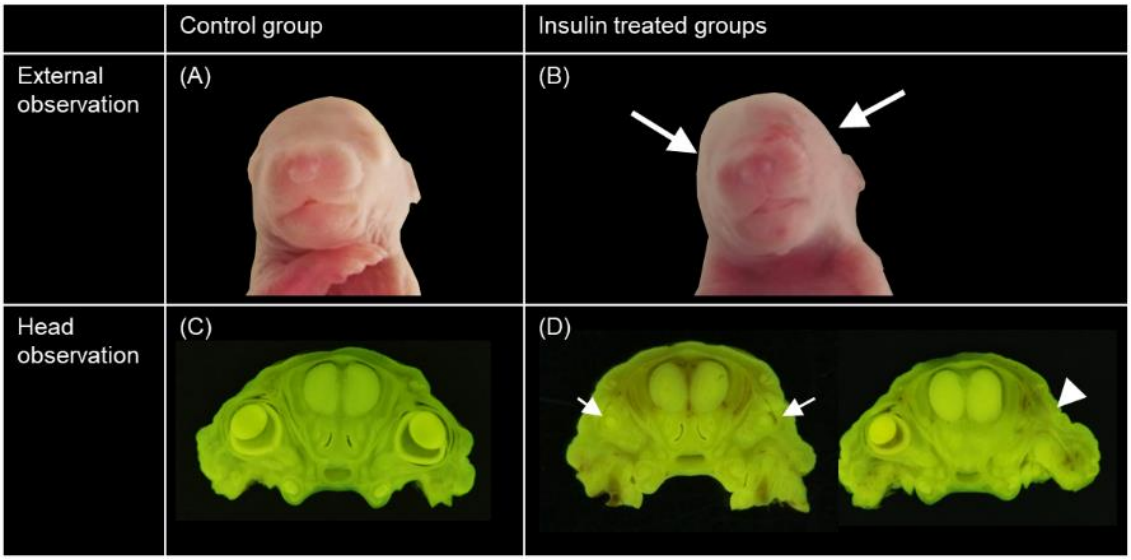

Figure 2-4 Eye anomalies in fetuses from insulin-treated groups.
The external observation was performed on the day of necropsy (A, B). Head was observed by Wilson's method after fixation in Bouin's fluid for more than 2 weeks (C, D). The large arrow indicates absent of eye bulge. The small arrow indicates microphthalmia. The arrowhead indicates anophthalmia.

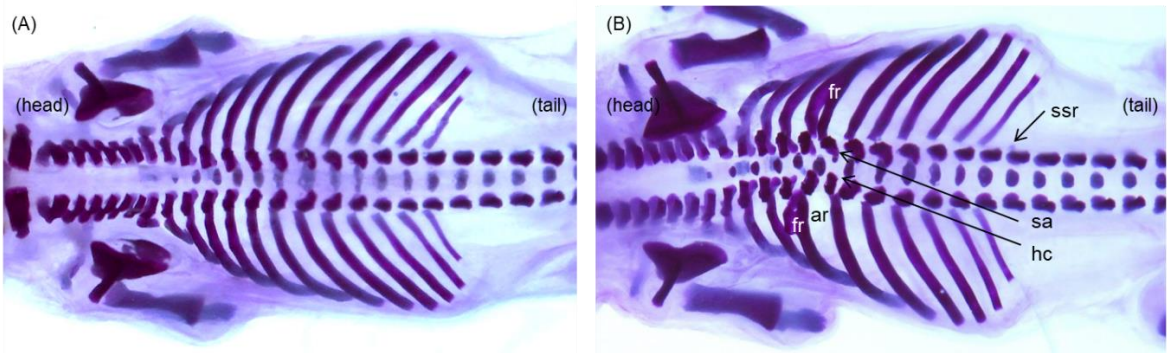

Figure 2-5 Skeleton anomalies in fetuses from insulin-treated groups.
Skeleton anomalies, variations, and the degree of ossification were examined with the trunk of the body stained by Dawson's method. (A): Control group, (B): Insulin treated group. ar, absent rib; fr, fused rib; sa, small thoracic arch; hc, hemicentric thoracic centrum; ssr, short supernumerary rib.

Table 2-2 Summary results of fetal observation of 4 different forms of insulin-treated groups.

Test article	Control	Insulin Human	Insulin Aspart		Insulin Glargine		Insulin Detemir	
Dose (IU/kg)	0	200	200	400	100	200	300	500
No. of dams	6	8	7	7	8	8	7	6
No. of fetuses examined	87	110	91	104	118	92	89	66
External observation								
No. of fetuses with absent eye bulge	0[a] (0.0)[b]	0 (0.0)	0 (0.0)	0 (0.0)	4 (3.4)	13 (14.1)**	7 (7.9)*	6 (9.1)**
Head observation								
No. of fetuses with eye anomalies	0 (0.0)	0 (0.0)	0 (0.0)	0 (0.0)	4 (3.4)	13 (14.1)**	7 (7.9)*	6 (9.1)**
Anophthalmia	0 (0.0)	0 (0.0)	0 (0.0)	0 (0.0)	1 (0.8)	1 (1.1)	1 (1.1)	1 (1.5)
Microphthalmia	0 (0.0)	0 (0.0)	0 (0.0)	0 (0.0)	3 (2.5)	12 (13.0)**	6 (6.7)*	5 (7.6)*
Coloboma of optic nerve	0 (0.0)	0 (0.0)	0 (0.0)	0 (0.0)	4 (3.4)	13 (14.1)**	7 (7.9)*	6 (9.1)**
Skeleton observation								
No. of fetuses with axial skeleton anomalies[c]	0 (0.0)	1 (0.9)	1 (1.1)	3 (2.9)	2 (1.7)	2 (2.2)	3 (3.4)	4 (6.1)*
No. of fetuses with variations	5 (5.7)	21 (19.1)**	21 (23.1)**	15 (14.4)	29 (24.6)**	29 (31.5)**	36 (40.4)**	22 (33.3)**
Full supernumerary rib	0 (0.0)	0 (0.0)	0 (0.0)	0 (0.0)	0 (0.0)	5 (5.4)	0 (0.0)	3 (4.5)
Short supernumerary rib	4 (4.6)	19 (17.3)**	12 (13.2)	12 (11.5)	28 (23.7)**	22 (23.9)**	35 (39.3)**	19 (28.8)**
Short 13th rib	0 (0.0)	0 (0.0)	1 (1.1)	0 (0.0)	0 (0.0)	0 (0.0)	0 (0.0)	0 (0.0)
Bipartite ossification of thoracic centrum	1 (1.1)	3 (2.7)	1 (1.1)	4 (3.8)	1 (0.8)	3 (3.3)	1 (1.1)	0 (0.0)
Unossified thoracic centrum	0 (0.0)	0 (0.0)	7 (7.7)*	1 (1.0)	2 (1.7)	3 (3.3)	0 (0.0)	0 (0.0)
Lumbarization	0 (0.0)	1 (0.9)	1 (1.1)	0 (0.0)	0 (0.0)	7 (7.6)*	1 (1.1)	2 (3.0)

Ossifications								
Sacrocaudal vertebrae	8.1[d]	7.9	7.9	7.8	8.1	8.3	8.2	8.4

Pregnant rats (n = 6 to 8) were administered insulin human at 200 IU/kg, insulin aspart at 200 or 400 IU/kg, insulin glargine at 100 or 200 IU/kg, or insulin detemir at 300 or 500 IU/kg from Days 6 to 11 of pregnancy. Cesarean section was performed on Day 20 of pregnancy. The external observation was performed on the day of necropsy. Head was examined by Wilson's method after fixation in Bouin's fluid, and skeleton anomalies, variations, and the degree of ossification were examined with the trunk of the body stained by Dawson's method.
Significant difference from the control group: **:$p < 0.01$, *:$p < 0.05$ by Fisher's exact test
[a]: Total number per group, [b]: Mean incidence ratio (%), [c]: Including absent rib, branched rib, fused rib, short rib, fused thoracic arch, small thoracic arch, hemicentric thoracic centrum, and/or absent thoracic vertebra, [d]: Mean value.

4. Discussion

Insulin is widely used for investigating effects of maternal hypoglycemia during pregnancy since it doesn't pass the placental barrier by facilitated diffusion due to its large molecular size. Although there have been several reports investigating the teratogenic potential of insulin-induced maternal hypoglycemia, the definitive conclusion has not been derived yet. Therefore, the purpose of this study was to investigate the insulin-induced maternal hypoglycemic condition leading to teratogenicity in detail by focusing on eye and skeleton anomalies.

In the present study, blood glucose levels in all pregnant rats given insulin injections decreased quickly to approximately 50 mg/dL and this severe hypoglycemia remained at least 6 h after injection. The longest persistence of maternal severe hypoglycemia up to 15 h or more on Day 11 of pregnancy was observed in rats given glargine and detemir, followed in order by aspart (high dose), aspart (low dose) and insulin human. During the treatment period, increases in food consumption and body weight gain were noted in glargine- and detemir-treated rats. Detemir-treated rats also showed some abnormalities in clinical observation such as decreased activity and/or irregular respiration. These were thought to be compensation reactions to hypoglycemia and reflect severe and consistent hypoglycemic condition.

In the Cesarean section of pregnant rats, increases in the number or rate of post implantations and the number of early resorptions, and a decrease in the number of live fetuses were seen in high-dose of glargine or detemir groups. These changes may be caused by maternal severe hypoglycemia, which alter hormone levels and result in breaking down and nonmaintenance of the decidua, as Hannnah and Moore reported [29)].

In the fetal examination, eye anomalies including anophthalmia and microphthalmia accompanied with coloboma of the optic nerve were observed in the glargine or detemir groups as in the DS-7309-treated rats. Axial skeleton anomalies, which were also similar to fetal anomalies observed in the DS-7309-treated rabbits, were observed in the aspart (high dose), glargine or detemir groups. In the present study, although the incidence of eye or skeleton anomalies was limited, their occurrence was considered to be related to insulin treatment for 2 reasons. First, the insulin-induced teratogenicity had same site of origin which was considered to be matched to the treatment duration set in this study

and in other studies [52,53,76]. In the previous studies, Miyamoto et al. reported an increased incidence of eye anomalies by 0.4 to 5.0% [52,53], and Tanigawa et al. reported an increased incidence of rib or costal cartilage anomalies by 8.2 or 24.7% [76]. Their increased incidence of eye or skeleton anomalies was also limited. Second, eye or skeleton anomalies have been rarely observed in our background data of Sprague-Dawley rats (only 2 among 4732 fetuses [0.04%] or 6 of 2156 fetuses [0.28%], respectively). These facts indicate that the teratogenicity seen in these experiments did not occur spontaneously, but was induced by insulin-induced maternal hypoglycemia.

My experiment revealed that fetuses showing eye anomalies were taken from dams only exhibiting severe (≤50 mg/dL) and persistent hypoglycemia (up to 15 h on Day 11 of pregnancy) in the glargine or detemir groups. By contrast, no eye anomalies were observed in fetuses from insulin human or aspart groups and exhibiting relatively shorter duration (no more than 6 or 9 h on Day 11 of pregnancy) of severe hypoglycemia. These results suggest that continuous severe hypoglycemia for approximately 15 h as shown on Day 11 of pregnancy in this study is necessary to induce eye anomalies in rats. Similar results were also shown by Miyamoto et al. [53], and it was reported that ultralente insulin induced severe (≤50 mg/dL) and persistent hypoglycemia for 24 h and caused fetal eye anomalies; however, no eye anomalies were observed in fetuses from pregnant rats showing severe, but shorter duration of severe hypoglycemia less than 12 h per day. Additionally, glargine-induced severe hypoglycemia (−60% compared to the control group) lasting for 2 h per day didn't show teratogenicity either in rats or rabbits [31]. These reports support my suggestion that long-lasting maternal severe hypoglycemia during the period of early organogenesis is necessary to induce eye anomalies in fetuses.

In addition, in the present study, aspart (high dose), glargine, or detemir groups showed severe hypoglycemia lasting for at least 9 h and their fetuses had axial skeleton anomalies. On the other hand, no skeleton anomalies were observed in fetuses from insulin human or aspart (low dose) groups and showing severe hypoglycemia lasting no more than 6 h. These results suggest that persistent severe hypoglycemia is also necessary to induce skeleton anomalies as well as eye anomalies in rats. In addition, the author considered the increased incidence of skeleton variation (thoracic vertebrae and rib) was related to the insulin treatment; however, the author judged these changes were not toxicologically

significant because the term variation is defined as indicating a divergence beyond the usual range of structural constitution that may not adversely affect survival or health by U.S. Environmental Protection Agency [1].

Contrary to these results, Hannah and Moore [29] and Hofman et al. [31] reported that skeleton anomalies were not recognized in fetuses from pregnant rats having insulin-induced hypoglycemia. In the former article, although Hannah and Moore concluded fetal anomalies like supernumerary ribs and duplicated vertebral centra were induced due to hypoglycemia by insulin, observed changes were variations and therefore, the author judged that insulin did not induce fetal anomalies under their experimental conditions. The author supposed that the reason of failing to induce fetal anomalies is the mildness of hypoglycemia (the lowest blood glucose level was 80 mg/dL in the insulin-treated group). In the case of Hofman et al. [31], glargine caused severe hypoglycemia (−60 % compared to the control group), but the blood glucose level recovered to the control level within 2 h after administration. In other reports, while skeleton observation was performed, blood glucose levels were not fully measured, and it is considered to be difficult to evaluate any relationship between blood glucose levels and skeleton anomalies [65,72,76].

Although it is well recognized that insulin does not pass the placenta due to its large molecular weight, there is no clear data indicating that 4 insulin formulations the author used here does not pass the placenta during the early pregnancy period, when placenta is relatively immature. However, the author strongly believes teratogenicity seen in this experiment and in previous reports were the result of maternal hypoglycemia rather than fetal hyperinsulinemia. Akazawa et al. demonstrated that teratogenicity and growth retardation were induced in the embryo cultured in hypoglycemic serum, but these changes disappeared when highly-concentrated glucose was supplied [3]. At the same time, no teratogenicity was seen in the embryo cultured in control serum supplemented with highly-concentrated insulin in the whole embryo culture system. Besides, Buchanan et al. demonstrated that although fetal anomalies and growth retardation were seen in the Day 11.6 of embryo from hypoglycemic pregnant rats, neither fetal anomalies nor growth retardation was induced in the embryo from euglycemic pregnant rats treated with insulin and glucose in vivo [9].

In conclusion, these results demonstrate that insulin administration to pregnant rats induced fetal eye and axial skeleton anomalies, which were similar to fetal anomalies observed in the DS-7309-treated rats or rabbits, due to maternal hypoglycemia. Duration (≥9 h) of maternal severe hypoglycemia (blood glucose levels reduced to approximately 50 mg/dL) were the key factors to induce fetal anomalies and much longer duration of hypoglycemia is considered to be necessary to cause eye anomalies.

5. Summary

The relationship between insulin-induced maternal hypoglycemia and teratogenicity was investigated in detail. Four different forms of insulin (insulin human, aspart, glargine, or detemir) were injected subcutaneously at 1 or 2 dose levels to Sprague-Dawley rats from Days 6 to 11 of pregnancy, and measurement of blood glucose levels and fetal examination were conducted. In the insulin human and aspart (low dose) groups, while severe hypoglycemia (approximately 50 mg/dL) was seen, it lasted only 6 h and no fetal anomalies were observed. Fetal axial skeleton anomalies were observed in the aspart (high dose) group, which exhibited intermediate-duration of severe hypoglycemia (9 h). Eye and axial skeleton anomalies were observed in the glargine and detemir groups, which exhibited continuous severe hypoglycemia (15 h). These results revealed that insulin-induced maternal hypoglycemia caused fetal eye and skeleton anomalies, which were similar to fetal anomalies observed in the DS-7309-treated rats or rabbits, and the causative key factors were duration and severity of maternal hypoglycemia.

Graphical summary　Maternal blood glucose levels and fetal anomalies in pregnant rats treated with 4 forms of insulin

Test article	Dose level (IU/kg/day)	Maternal blood glucose level	Fetal anomalies (%)	
			Eye	Axial skeleton
Control	-	-	-	-
Insulin human	200	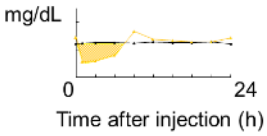 ↓	-	-
Insulin aspart	200	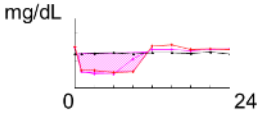 ↓	-	-
	400	↓↓	-	↑ (2.9)
Insulin glargine	100	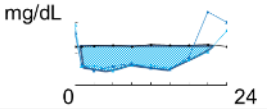 ↓↓↓	↑ (3.4)	↑ (1.7)
	200	↓↓↓	↑ (14.1)	↑ (2.2)
Insulin detemir	300	 ↓↓↓	↑ (7.9)	↑ (3.4)
	500	↓↓↓	↑ (9.1)	↑ (6.1)

・Insulin-induced maternal hypoglycemia caused fetal eye and axial skeleton anomalies in rats.

・Duration (≥ 9 hours) of maternal severe hypoglycemia (blood glucose levels reduced to approximately 50 mg/dL) was the key factors to induce fetal anomalies.

・Much longer duration of hypoglycemia is necessary to cause eye anomalies than skeleton anomalies.

Chapter 3.

Disruption of fetal eye development caused by insulin-induced maternal hypoglycemia in rats

1. Introduction

As the author demonstrated in Chapter 2, the key factors behind the induction of fetal eye and skeleton anomalies by insulin injection to pregnant rats were the duration (≥9 h) and severity (around 50 mg/dL) of maternal hypoglycemia. It was also clearly shown that continuous severe hypoglycemia (15 h in duration at around 50 mg/dL) induced fetal eye anomalies such as anophthalmia, microphthalmia, and coloboma of the optic nerve. However, it is still unclear whether maternal hypoglycemia-induced fetal eye anomalies involved developmental retardation or disruption, and furthermore, when and how the eye anomalies developed.

The process of eye development starts from embryonic day (E)9 and continues into the postpartum period [5,15,16,20,21,25,26,59]. Eye formation begins with outgrowth from the forebrain toward the head surface ectoderm for development of the optic vesicle from E9 to E10. The lateral wall of the optic vesicle is then indented and forms the two-layered optic cup by E11. The inner layer of the optic cup forms the sensory layer of the retina (neural retina: NR) and the outer layer forms the retinal pigmented epithelium (RPE) from E12. In the NR, the increased retinal progenitor cells emigrate to the inside of the NR and divide it into two layers: the outer neuroblastic layer (ONL) and the inner neuroblastic layer (INL) [12,64,67,71,84]. The nerve fibers of retinal ganglion cells in the INL extend along the optic stalk to the brain and are called optic nerve fibers. Additionally, anterior optic cup differentiates into the iris and ciliary body by E20. During the development of the lens and retina, there is close interaction between them. The optic vesicle induces the formation of the lens placode in the overlying ectoderm, and the lens placode induces the formation of the NR from E11. Then, the lens placode turns into the lens pit, and separates from the surface ectoderm to develop the lens vesicle by E11 [15]. While the anterior cells of the lens vesicle proliferate and form lens epithelium cells, the posterior cells of the lens vesicle are denucleated and elongate to form lens fibers in the cavity of the lens vesicle, which progressively diminishes and finally disappears completely by E14.

Several reports have shown that fetal eye anomalies such as microphthalmia and/or anophthalmia were also induced by cyclophosphamide [60], thalidomide [39,50], the purine analog 2-chloro-2′-deoxyadenosine [45], hypervitaminosis A [74], or methylmercury [58]; however the pathogenesis of microphthalmia and anophthalmia remains unclear. Against

this background, the purpose of the present study was to clarify whether the fetal eye anomalies due to maternal hypoglycemia involved developmental retardation or disruption, and to elucidate when and how these anomalies develop by periodic histopathological examination and immunostaining. In this study, insulin glargine was injected from Days 6 to 11 of pregnancy at 200 IU/kg to ensure the induction of anophthalmia or microphthalmia by severe and long-lasting maternal hypoglycemia (15 h in duration at around 50 mg/dL), in accordance with my previous study described in Chapter 2.

The present study featured periodic histopathological examination of fetal eyes during E10 to E20 and immunostaining for the microphthalmia-associated transcription factor (MITF); visual system homeobox 2 (chx10); anti-Neuronal Class III β-Tubulin (Tuj-1); crystallin α, β, and γ; E-cadherin; and paired box 6 (Pax6). The expression of MITF on the optic cup is stimulated by t ransforming growth factor-β (TGF-β) around E11 and/or activin released from the mesenchyme and essential for the acquisition and maintenance of RPE cell identity, but not for the presumptive NR or optic stalk [8,22,32,54)]. The expression of chx10 is regulated by fibroblast growth factor (FGF) released from the surface ectoderm and crucial for NR cell identity, but not for RPE around E11 to E12. Subsequently, chx10 is retained in the ONL to identify retinal progenitor cells, but is downregulated in the INL and optic stalk because that location includes only differentiated NR cells [8,11,32,34,46,61,67)]. Tuj-1 is expressed in the retinal ganglion cells and optic nerves. Crystallin α, β, and γ are the major structural proteins in the vertebrate eye lens [4)]. E-cadherin is a cell adhesion protein that contributes to separation of the invaginated lens vesicle from the surface ectoderm and lens cell polarity [62)]. Finally, Pax6 is a key regulator of eye and pancreatic development, and a transcription factor that maintains glucose homeostasis by regulating insulin biosynthesis and secretion [15,24,70)].

2. Materials and methods

2.1 Insulin

Insulin glargine [genetical recombination (Lantus®)] was purchased from Sanofi K.K. (Tokyo, Japan). Physiological saline (Japanese Pharmacopoeia, Otsuka Pharmaceutical Factory, Inc., Japan) was used as a vehicle control.

2.2 Animals

Female and male Sprague-Dawley rats were obtained from Charles River Laboratories Japan, Inc. (Kanagawa, Japan). After acclimation, female rats at 10 weeks of age were housed together with male rats for mating. The day on which copulation was confirmed was referred to as Day 0 of pregnancy. Rats were housed individually in bracket cages except for during the mating period and kept in a controlled environment at a temperature from 20°C to 26°C, and humidity from 30% to 70% with an illumination period of 12 h (07:00 to 19:00) per day. Certified pellet food sterilized by ^{60}Co-γ irradiation (30 kGy, CRF-1; Oriental Yeast Co., Ltd.) and chlorinated water were supplied *ad libitum*. All animal procedures were performed in accordance with the guidelines of the Animal Care and Use Committee of Daiichi Sankyo Co., Ltd. (Tokyo, Japan). The experimental protocols were approved by the Institutional Animal Care Committee of Daiichi Sankyo Co., Ltd.

2.3 Experimental design

The experimental groups were composed of 3 to 5 pregnant rats/group that were given vehicle or insulin. The pregnant rats were euthanized periodically on E10 to E15, E17, and E20. Fetal eyes were obtained, processed as shown in Section 2.5.1, and examined microscopically. Immunohistochemical analysis of fetal eyes was also conducted as described in Section 2.5.2.

2.4 Insulin treatment of dams and Cesarean section

The pregnant rats were given 200 IU/kg of insulin glargine to induce maternal hypoglycemia (insulin-treated group) or physiological saline (control group) subcutaneously once daily from Days 6 to 11 of pregnancy. The dose level and dosing period were selected to induce maternal hypoglycemia without lethality and eye anomalies in

fetuses, in accordance with previous reports [31,41,69]. The dose level of 200 IU/kg was approximately 19 to 3,000 times higher than human therapeutic dose levels when calculated as units/body surface area, assuming a human body weight of 60 kg [13]. The dosing period used in this study covered the period of susceptibility to eye anomalies, and matched those in previous studies [52,53]. On the day of necropsy, pregnant rats were euthanized by carbon dioxide inhalation and Cesarean section was performed.

2.5. Pathological examinations

2.5.1. Histopathology

Each embryo or fetus was fixed in 4% paraformaldehyde solution (for E10 to E17) or Bouin's fluid (for E20) and embedded in paraffin by routine procedures. Serial sections of 2 to 3 μm thickness were stained with hematoxylin and eosin (HE) and examined microscopically (more than 3 fetuses/group).

2.5.2. Immunohistochemistry

Immunostaining was performed for Ki-67 on E14; chx 10 and MITF on E11, E12, and E15; Tuj-1, crystallin α, β, and γ, and E-cadherin on E17; and Pax6 on E10, E11, and E12.

2.5.2.1. Primary and secondary antibodies

Ready-to-use rabbit anti-Ki-67 (catalog No. 418071; Nichirei Biosciences Inc., Tokyo, Japan), sheep anti-chx10 (1:50, catalog No. X1180P; Exalpha Biologicals Inc., MA, USA), mouse anti-MITF (1:1,000, catalog No. X1405M; Exalpha Biologicals Inc.), mouse anti-Tuj-1 (1:2,000, catalog No. 801201; Biolegend, CA, USA), rabbit anti-crystallin α (1:1,000, ab5595; Abcam plc, Cambridge, UK), rabbit anti-crystallin β (1:50, catalog No. sc-22745; Santa Cruz Biotechnology, Inc., TX, USA), rabbit anti-crystallin γ (1:50, catalog No. sc-22746; Santa Cruz Biotechnology, Inc.), mouse anti-E-cadherin (1:50, catalog No. M3612; Dako Japan Inc., Kyoto, Japan), and rabbit anti-Pax6 (1:600, catalog No. 901301; BioLegend, Inc.) were used as primary antibodies. The secondary antibodies used were as follows: MAX peroxidase-labeled anti-rabbit IgG (catalog No. 414181; Nichirei Biosciences Inc.) for anti-Ki-67; Dako Envision system horseradish peroxidase (HRP)-

labeled polymer anti-mouse (catalog No. K4001; Dako Japan Inc.) for anti-Tuj-1, MITF, and E-cadherin; polyclonal rabbit anti-sheep HRP (catalog No. P0163; Dako Japan Inc.) for anti-chx10; Dako Envision system HRP-labeled polymer anti-rabbit (catalog No. K4002; Dako Japan Inc.) for anti-crystallin α, β, and γ; and polyclonal goat anti-rabbit Biotin (catalog No. E0432; Dako Japan Inc.) for Pax6.

2.5.2.2. Specimen preparation

Sections were autoclaved in Targeted Retrieval Solution (pH 6.1, catalog No. S1699; Dako Japan Inc.) at 96°C for 50 min for anti-crystallin α, β, and γ, or at 121°C for 15 min for the other targets. After the pretreatment, endogenous peroxidase activity was quenched by incubation in 3 v/v% H_2O_2 at room temperature for 15 min (MITF, Tuj-1, E-cadherin, chx10, Pax6). Then, incubation was performed in rabbit and goat serum at room temperature for 15 min (chx10 and Pax6, respectively), and protein block (catalog No. X0909; Dako Japan Inc.) for 30 min at room temperature. The sections were then incubated with the primary antibody for 1 h at room temperature or 37°C (only for chx10), followed by incubation with secondary antibodies as described in Section 4.5.2.1 and streptavidin at room temperature for 30 min (only for Pax6, catalog No. P0397; Dako Japan Inc.). The reacted products were visualized with a 3,3′-diaminobenzidine tetrahydrochloride substrate. The sections were counterstained with Mayer's hematoxylin.

2.5.3. TUNEL assay

The sections were subjected to TUNEL assay on E14 with an ApopTag® Peroxidase In Situ Apoptosis Detection Kit (Chemicon International Inc., Temecula, CA, USA), in accordance with the manufacturer's instructions (n = 8 to 9/group). Semi-quantitative analysis was performed to determine the rates of TUNEL-positive cells among lens epithelial cells, nucleated lens fiber cells, or total lens cells.

2.6. Statistical analysis

To analyze the rate of TUNEL-positive cells in the rat fetus lens, group mean ± SD values were calculated by REDPOST/BI (SAS System Release 9.2; SAS Institute Inc.). The significance of the difference of mean values between the control and insulin-treated groups

was analyzed by Wilcoxon's rank sum test. A P-value less than 0.05 was considered to indicate a statistically significant change.

3. Results

3.1. Microscopic examination of fetal eyes from E10 to E20

The results of microscopic examinations of fetal eyes on E10 to E15, E17, and E20 are shown in Figure 3-1. No difference was observed in the development of optic vesicles between the control and insulin-treated groups on E10 (Figure 3-1, A-1, A-2, I-1, and I-2).

On E11, the optic vesicle folded inward, resulting in the optic cup and the inner layer of optic cup, which was the presumptive NR, being thickened in the control group (Figure 3-1, B-2). In contrast, in the insulin-treated group (Figure 3-1, J-2), neither invagination of the optic vesicle nor thickening of the presumptive NR was observed, and the optic vesicle was smaller than that in the control group. At the same time, while the surface ectoderm in the control group was thickened, and the lens placode was formed, the surface ectoderm was rarely or never thickened in the insulin-treated group.

On E12, whereas the shape of the eye field in the control group was circular or oval (Figure 3-1, C-2), that in the insulin-treated group was an inverse triangle and small (Figure 3-1, K-2). In the control group, the stratified NR was further thickened and invaginated toward the single-layered RPE without space between NR and RPE (Figure 3-1, C-2). In contrast, in the insulin-treated group, the space between NR and RPE still remained, although invagination of the NR towards RPE was observed (Figure 3-1, K-2). The RPE in the insulin-treated group was thicker than that in the control group and it was difficult to distinguish the outer layer of the optic cup from the optic stalk, which was also thicker than that in the control group. Besides, the lens vesicle was formed by separating from the overlying surface ectoderm in the control group; however, separation from the overlying ectoderm was not fully completed and the lens pit was still observed in the insulin-treated group.

By E12, basic ocular components including retina, lens, and optic stalk had formed, and from E13, each structure further developed to achieve visual function in the control group, as detailed below. On E13, lens fibers were elongated and lens vesicle with a thin cavity was observed (Figure 3-1, D-2). On E14, lens fiber cells increasingly elongated and the lumen of the lens vesicle was eventually completely obliterated (Figure 3-1, E-2). The NR was divided into 2 layers (INL and ONL), optic nerve fiber (ONF) was layered along INL, and the cornea appeared on E15 (Figure 3-1, F-2). Subsequently, from E15 through

E17, each ocular component was enlarged (Figure 3-1, G-2). Finally, the eyelids closed (Figure 3-1, H-1) and all ocular components including the retina, ciliary body, iris, lens, and cornea had normally developed by E20 (Figure 3-1, H-1 and H-2).

By contrast, 4 major morphological defects were observed in the insulin-treated group during E13 to E20 (Figure 3-1, L-2 to Q-2). (1) Hypoplasia of the retina, lens, and cornea was seen during E13 to E20 (Figure 3-1, L-2 to Q-2). (2) Increased cell debris was observed in the lens from E13 to E15 (Figure 3-1, L-2 to N-2) and in the retina from E14 to E15 (Figure 3-1, M-2 and N-2). (3) Lens fiber cells failed to adequately elongate, and the lumen of the lens vesicle remained even on E13 and E14 (Figure 3-1, L-2 and M-2). (4) Degeneration of the lens fiber cells was seen and there was no connection between the lens fiber cells and the anterior lens epithelial layer on E15, E17, and E20 (Figure 3-1, N-2 to Q-2), resulting in the lumen being filled with degenerative lens fiber cells and eosinophilic materials (marked with asterisks). On E20, dramatic eye disruption was observed in the insulin-treated group (Figure 3-1, P-1, Q-1, P-2, and Q-2). The NR was composed of 2 layers and overlaid the rear of the lens in the control group (Figure 3-1, H-1); however, NR in the insulin-treated group was extremely small and consisted of only a single layer that could not overlay the lens anymore (Figure 3-1, P-2 and Q-2). Besides, a lack of peripheral structures of the eye such as ciliary body and iris was noted in the insulin-treated group (Figure 3-1, P-2 and Q-2). Additionally, in the control group, lens epithelial cells were highly polarized and only the anterior lens epithelial cells were nucleated; they were cuboidal or columnar in shape, and the lens fiber cells in the posterior lens were elongated and denucleated (Figure 3-1, H-2). In contrast, in the insulin-treated group, polarity of the lens was lost; nucleated lens epithelial cells that were cuboidal or columnar in shape localized along not only the anterior but also the posterior lens (Figure 3-1, P-2) or, in some cases, no lens epithelial cells were observed anywhere (Figure 3-1, Q-2). Three eyes showing anophthalmia macroscopically were classified as having anophthalmia (1 eye) and microphthalmia (2 eyes) histopathologically.

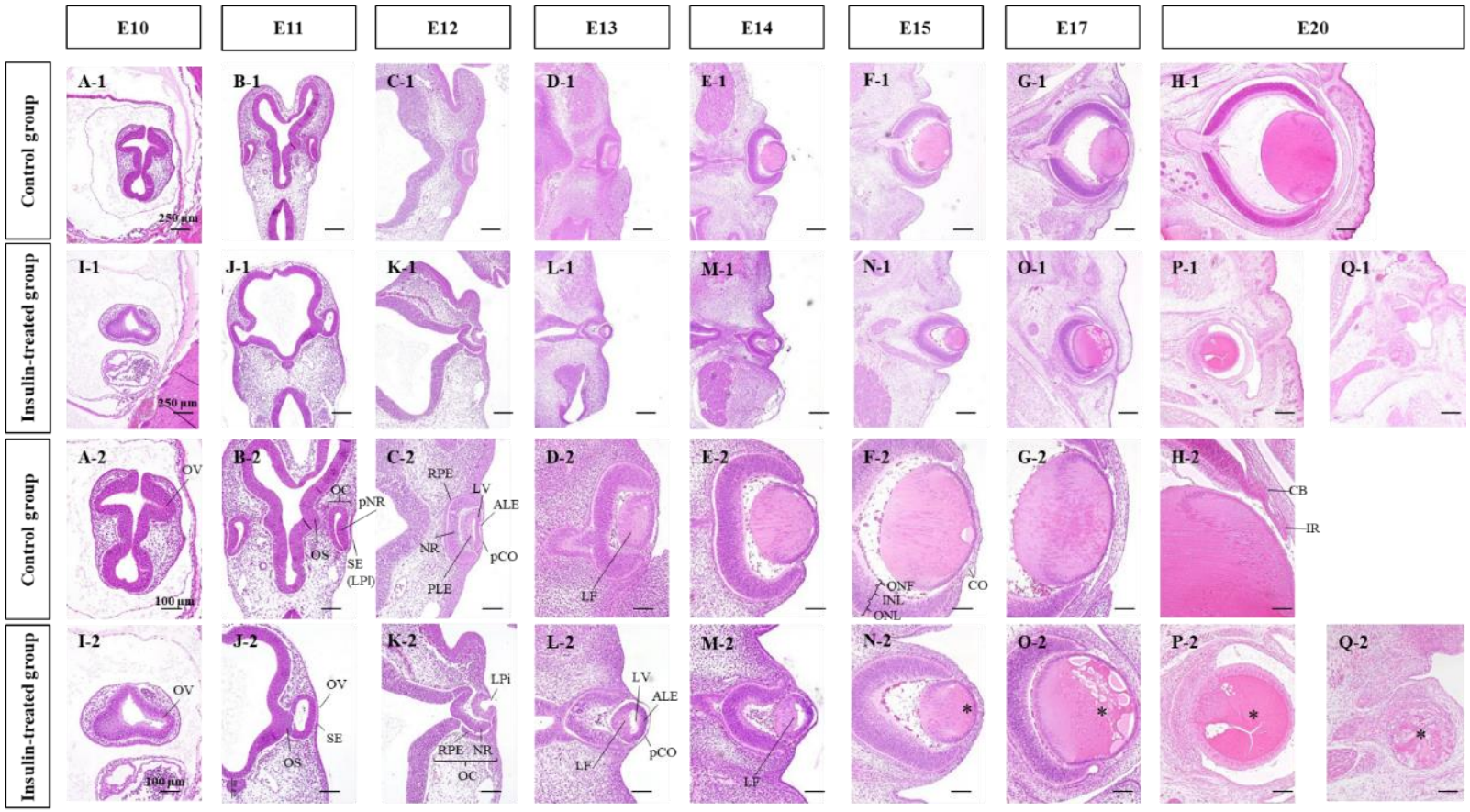

Figure 3-1 Effects of insulin-induced maternal hypoglycemia on fetal eye development from E10 through E20

Eye sections were stained with HE on E10 to E15, E17, and E20 in the control (A to H) and insulin-treated (I to Q) groups. OV, optic vesicle; OC, optic cup; OS, optic stalk; pNR, presumptive neural retina; LPl, lens placode; SE, surface ectoderm; LPi, lens pit; RPE, retinal pigmented epithelium; NR, neural retina; LF, lens fibers; ALE, anterior lens epithelium cells; pCO, presumptive cornea; PLE, posterior lens epithelium; LV, lens vesicle; CO, cornea; INL, inner neuroblastic layer; ONL, outer neuroblastic layer; ONF, optic nerve fiber; CB, ciliary body; IR, iris; *, the lumen filled with degenerative lens fiber cells and eosinophilic material. Scale bars = 250 µm in A-1 to Q-1; 100 µm in A-2 to Q-2 (higher magnification of A-1 to Q-1)

3.2. Cell proliferation of fetal eyes on E14

To assess the cell proliferation activity of fetal eyes, Ki-67 immunohistochemistry was performed on E14 (Figure 3-2, A and C). Ki-67-positive cells were observed among the NR epithelial cells, RPE cells, lens epithelial cells, and presumptive corneal cells in the control group (Figure 3-2, A). In the insulin-treated group, there were tendencies for the rate of Ki-67-positive cells to decrease among the NR epithelial cells and RPE cells compared with the levels in the control group (Figure 3-2, C). In addition, some nucleated lens fiber cells in the insulin-treated group showed positivity for Ki-67 (indicated by black arrowheads), which were not observed in the control group.

3.3. Cell death of fetal eyes on E14

Cell death of fetal eyes was assessed by TUNEL assay on E14 (Figure 3-2, B-1, B-2, D-1, and D-2). In the control group, TUNEL-positive cells were mainly observed around the optic nerve head (Figure 3-2, B-1 and B-2, indicated by white arrowheads). In the insulin-treated group, TUNEL-positive cells slightly increased among the epithelial cells of the retina (Figure 3-2, D-1 and D-2), except for the optic nerve head, compared with the level in the control group (data not shown). Additionally, TUNEL-positive cells increased among both lens epithelial cells and nucleated lens fiber cells (indicated by a black arrow) in the insulin-treated group. In semi-quantitative analysis, the rates of TUNEL-positive cells among the lens epithelial cells, nucleated lens fiber cells, and total lens cells were markedly increased in the insulin-treated group compared with those in the control group (Figure 3-3).

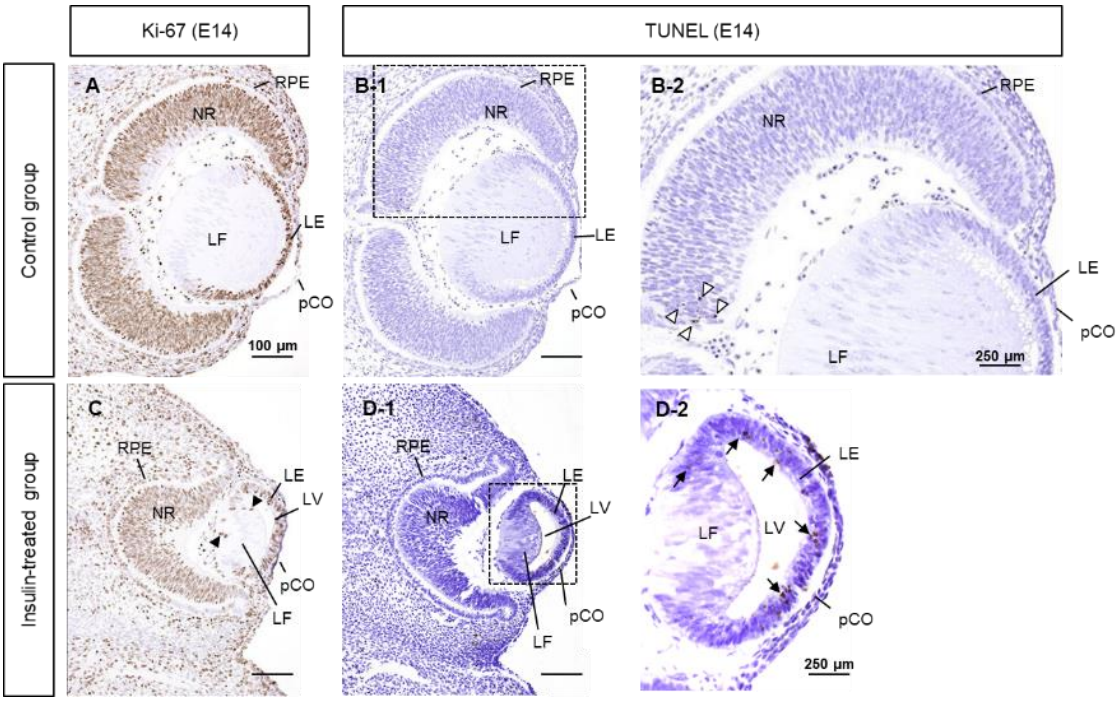

Figure 3-2 Immunohistochemical evaluation of the expression of Ki-67 and TUNEL assay in the rat fetal eye on E14.

Immunostaining for Ki-67 (A and C) and TUNEL assay (B and D) were conducted for the rat fetal eyes in the control and insulin-treated groups on E14. RPE, retinal pigmented epithelium; NR, neural retina; LF, lens fiber cells; LE, lens epithelium cells; LV, lens vesicle; pCO, presumptive cornea; black arrowhead, Ki-67-positive lens fiber cells; white arrowhead or black arrow, TUNEL-positive lens epithelium cells. Scale bars = 100 µm in A, B-1, C, and D-1; 250 µm in B-2 and D-2 (higher magnification of B-1 and D-1).

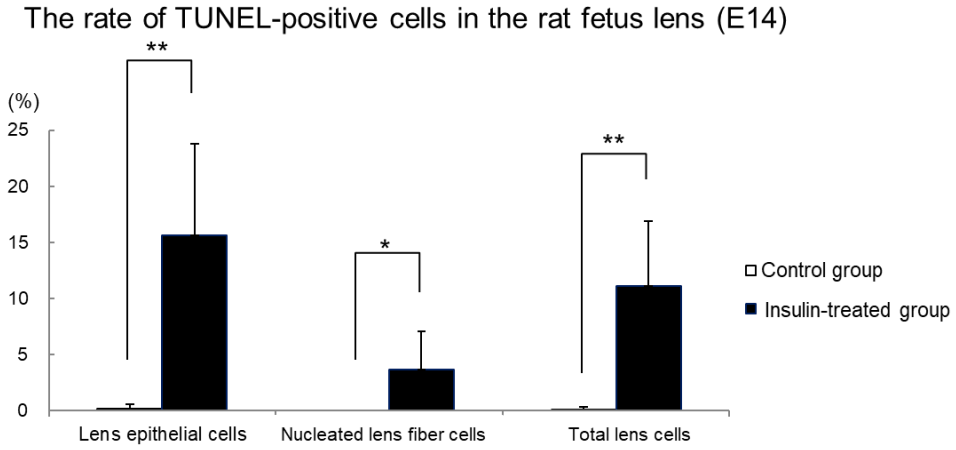

Figure 3-3 The rate of TUNEL-positive cells in the rat fetus lens on E14.

Data are expressed as the mean ± SD (n = 8 to 9/group). *P < 0.05, **P < 0.01 vs. control group by Wilcoxon rank sum test.

3.4. Expression of retinal markers on E15 or E17

To investigate the effects of maternal hypoglycemia on the differentiation of fetal retina, the expression levels of MITF (an RPE marker) in the retina on E15, chx10 (a marker of cells in the ONL) on E15, and Tuj-1 (a marker of retinal ganglion cells) on E17 were assessed (Figure 3-4). There was no clear difference in the expression level of MITF between the control and insulin-treated groups (Figure 3-4, A-1, A-2, D-1, and D-2). In contrast, notable differences in the expression levels of chx10 (Figure 3-4, B-1, B-2, E-1, and E-2) and Tuj-1 (Figure 3-4, C and F) were noted. In the control group, chx10 was strongly expressed in the cells in the ONL, but rarely in the INL (Figure 3-4, B-1 and B-2); however, unclear polarity of chx10 across the whole of the NR was observed in the insulin-treated group (Figure 3-4, E-1 and E-2). Moreover, while Tuj-1-positive cells were noted in the ganglion cell layer and optic nerve in the control group, they were rarely noted in the insulin-treated group (Figure 3-4, C and F).

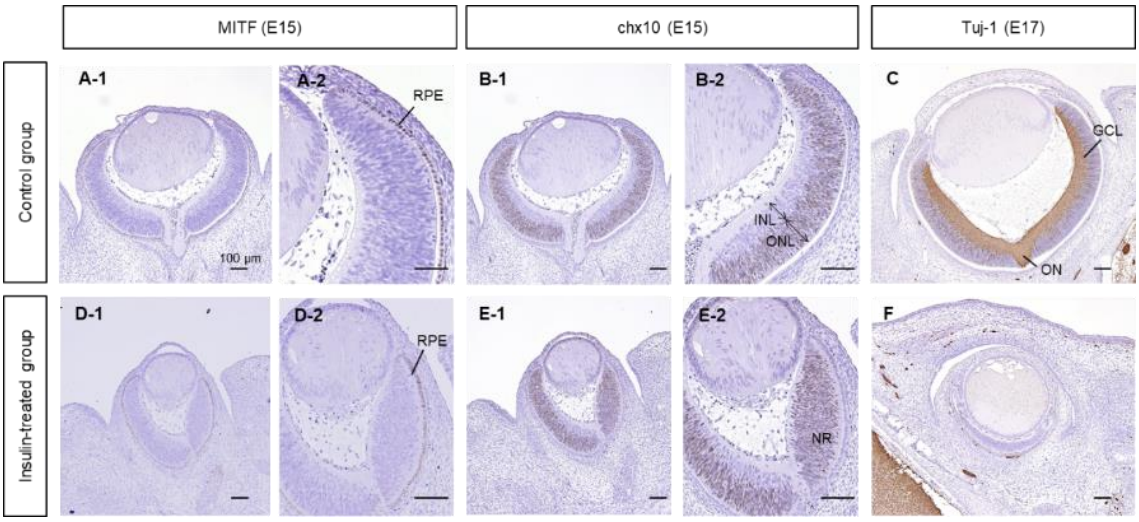

Figure 3-4 Immunohistochemical evaluation of the expression of MITF and chx10 on E15, and of Tuj-1 on E17 in the rat fetal eye.

Rat fetuses were immunostained for MITF (A and D) and chx10 (B and E) on E15, and for Tuj-1 (C and F) on E17 in the control and insulin-treated groups. RPE, retinal pigmented epithelium; INL, inner neuroblastic layer; ONL, outer nuclear layer; NR, neural retina; GCL, ganglion cell layer; ON, optic nerve. All scale bars = 100 μm (A-2, B-2, D-2, and E-2 are the same photographs as A-1, B-1, D-1, and E-1 with higher magnification).

3.5. Expression of transcription factors required for early eye development on E10, E11, and/or E12

To further investigate the cause of the defects in eye development in the insulin-treated group, the expression level of Pax6, a master control gene for eye development; MITF, a transcription factor for inducing RPE; and chx10, a transcription factor for the development of the NR during early eye development, were examined on E10, E11, and/or E12 (Figure 3-5). There were no differences in the expression level and cell types expressing Pax6 between the control and insulin-treated groups (Figure 3-5, A to C and H to J). All fetuses both in the control and insulin-treated groups expressed Pax6 in the optic vesicle, optic cup, retina including RPE and NR, optic stalk, lens placode, and lens vesicle. The cells positive for MITF were detected only in the presumptive RPE in the control group on E11 and E12 (Figure 3-5, D and E). Interestingly, in the insulin-treated group, the cells positive for MITF were detected not only in the presumptive RPE but also in the presumptive NR at low frequency on E11 (Figure 3-5, K); however, they were confined to the RPE on E12 (Figure 3-5, L) as in the control group. A high expression level of chx10 was observed in the presumptive NR in the control group, but not in the insulin-treated group on E11 (Figure 3-5, F and M). On E12, chx10-positive cells were observed in the NR in both the control and insulin-treated groups (Figure 3-5, G and N).

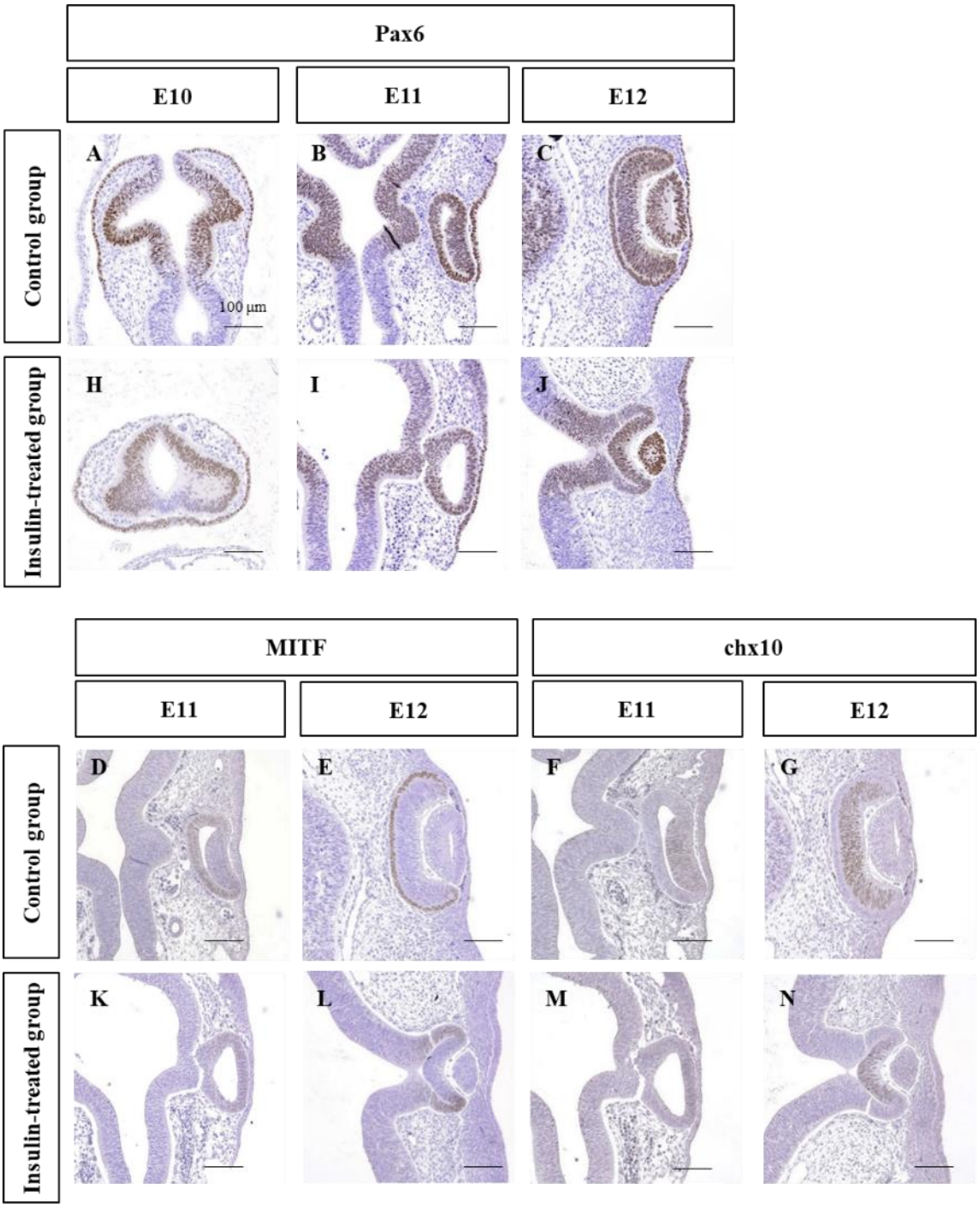

Figure 3-5 Immunohistochemical evaluation of the expression of Pax6, MITF, and chx10 on E10 to E12 in the rat fetal eye.

Rat fetuses were immunostained for Pax6 on E10 to E12 (A to C, H to J), MITF on E11 and E12 (D, E, K, and L), and chx10 on E11 and E12 (F, G, M, and N) in the control and insulin-treated groups. All scale bars = 100 µm.

3.6. Expression of crystallin α, β, and γ and E-cadherin on E17

To elucidate the mechanism underlying the defects during eye development in the insulin-treated group, the expression levels of crystallin α, β, and γ, and E-cadherin were also examined. Lens fibers were strongly positive for crystallin α, β, and γ immunostaining both in the control and insulin-treated groups (Figure 3-6, A to C and E to G). Lens epithelium cells were also strongly positive for crystallin α, and equivocal to moderately positive for crystallin β and γ both in the control and insulin-treated groups. The lumen filled with degenerative lens fiber cells and eosinophilic materials (Figure 3-6, E, F and G, marked with asterisks) in the insulin-treated group was positive for crystallin α, β, and γ. E-cadherin-positive cells were equally observed among the lens epithelium cells and corneal cells both in the control and insulin-treated groups (Figure 3-6, D and H).

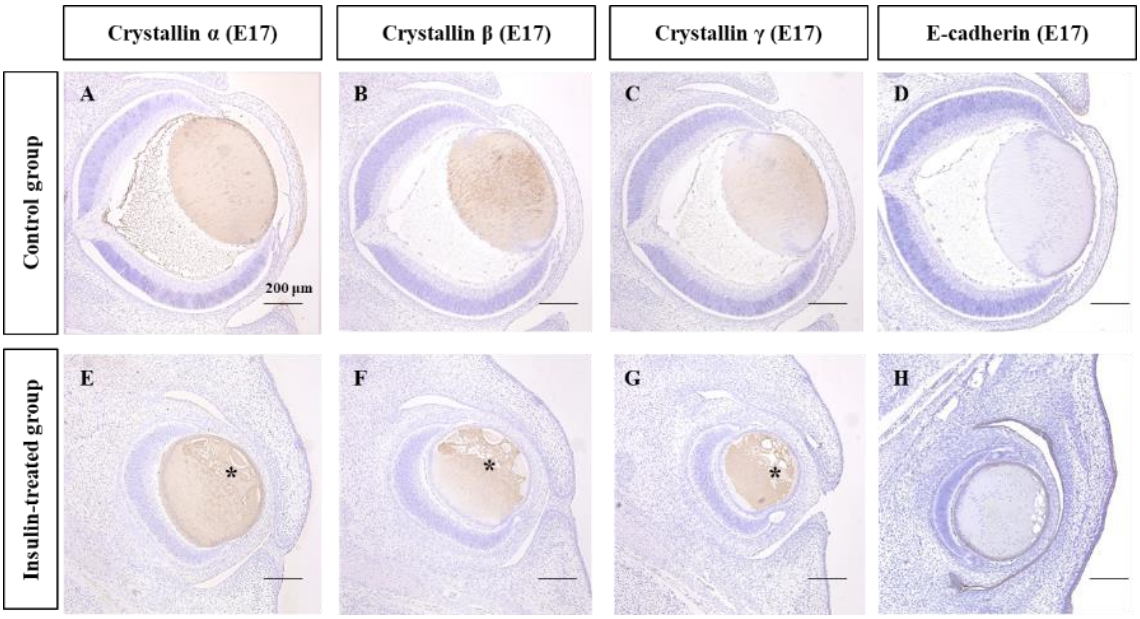

Figure 3-6 Immunohistochemical evaluation of the expression of crystallin α, β, and γ, and E-cadherin on E17 in the rat fetal eye.

Rat fetuses were immunostained for crystallin α (A and E), β (B and F), and γ (C and G), and MITF (D and H) on E17 in the control and insulin-treated groups. *, the lumen filled with degenerative lens fiber cells and eosinophilic material. All scale bars = 200 μm.

4. Discussion

The author previously elucidated that the key factors for insulin to induce fetal eye anomalies such as anophthalmia and microphthalmia, and coloboma of optic nerve were the severity and continuousness of maternal hypoglycemia in Chapter 2; however, it had remained unclear whether fetal eye anomalies induced by insulin-induced maternal hypoglycemia were developmental retardation or disruption. Hence, the author conducted the present study to clarify the nature of the fetal eye anomalies due to maternal hypoglycemia. In our experiments, all ocular components including the retina, lens, and cornea developed normally by E20 in the control group. In contrast, in the insulin-treated group, the eyes were smaller than those in the control group and histopathological abnormalities including defects, hypoplasia, and/or degeneration of the retina, lens, and cornea were observed. Therefore, it was considered that hypoglycemia-induced microphthalmia and anophthalmia were caused not by simple developmental retardation, but by developmental disruption with structural anomalies, suggesting a difference from nanophthalmia, which is defined as small eyes without structural anomalies. In contrast, the eyelids developed normally in the insulin-treated group. It is well known that the eyelids develop independently from other eye components [51)], despite there being close collaboration among the retina, lens, and cornea in their own differentiation via the transmission and receipt of inductive signals from each other [15,26)]. Taken together, these results provide evidence that hypoglycemia due to the injection of insulin in pregnant rats caused developmental impairment of any of the retina, lens, or cornea, which in turn led to disruption of the interaction among these components; induced defects, hypoplasia, and/or degeneration of all of them; and resulted in microphthalmia or anophthalmia on E20.

In addition, time-course histopathological examinations of fetal eyes from E10 to E20 revealed when and how these eye anomalies were induced. In the control group, all ocular components including the retina, lens, and cornea developed normally and became larger over the studied period, as previously reported [5,16,20)]. In contrast, there was disruption of eye development, including hypoplasia, increased cell debris, morphological defects, lost polarization, and degeneration, from E11 in the insulin-treated group. These findings corresponded to the results reported in a previous review [68)]; namely, disruptions of earlier eye developmental steps caused microphthalmia, anophthalmia, or coloboma with defects

in multiple ocular components, while disruption of later eye developmental steps induced defects in the differentiation of specialized tissues/cells resulting in retinal dystrophies, cataract, or corneal opacification.

Immunostaining for Ki-67 and TUNEL assay were performed for the fetal eyes in the insulin-treated group on E14, which revealed cell debris in the lens and retina, suggesting changes in the rates of cell proliferation and cell death in the lens and retina. Although lens epithelium cells and retinal cells were positive for Ki-67 both in the control and insulin-treated groups, a trend for a decrease in Ki-67-positive cells was noted in the insulin-treated group. TUNEL assay showed increased cell death among the epithelial cells of the retina and lens in the insulin-treated group. These findings indicated that decreases in cell proliferation and increases in cell death resulted in the small eye in the insulin-treated group. In the control group, the lens fiber cells in the posterior lens were elongated and mostly denucleated and were negative for Ki-67 and TUNEL assay on E17; however, in the insulin-treated group, the lens fiber cells were positive for Ki-67 and TUNEL assay, indicating a failure of enucleation resulting in abnormal differentiation and maturation of lens.

Interestingly, there was no clear difference in the expression of MITF, a marker of RPE, between the control and insulin-treated groups on E15. In contrast, the expression of chx10, an ONL marker, differed between the insulin-treated group and the control group on E15. Specifically, in the control group, chx10 was expressed mainly in the ONL and rarely in the INL. This difference in expression resulted in a clear border between the ONL and INL, whereas in the insulin-treated group its expression was high throughout the entire NR, which looked like a single layer. Previous reports showed that chx10 was expressed throughout the entire NR region before E14, and then retained only in the ONL but downregulated in the INL and optic stalk on E15 [8,11,46]. This is because retinal progenitor cells, which are positive for chx10, remain only in the ONL, while differentiated NR cells, which are negative for chx10, migrate to the INL and optic stalk [8,11,32,34,46,61,67]. Moreover, although Tuj-1-positive cells were seen in the INL in the control group on E17, indicating the appropriate differentiation of the retinal ganglion cells, they were rarely seen in the insulin-treated group. This suggested the disruption of differentiation into retinal ganglion cells in the insulin-treated group. Therefore, my results indicated that insulin-induced

maternal hypoglycemia disrupts fetal eye differentiation and the emigration of retinal progenitor cells, resulting in the failure of NR to divide into the two-layered NR (ONL and INL).

Pax6 is one of the most essential transcription factors in the initial stage of eye development and is responsible for forming optic vesicle and subsequent eye development [15,17,26,70,82]. Pax6 mutations are well known to induce eye anomalies such as small eye, cataract, aniridia, and Peter's anomaly in fruit flies, mice, rats, and humans. Pax6 is also a key transcription factor for developing pancreas during the fetal period and regulating the production of insulin after birth [7,24,42,82], suggesting that Pax6 is a glucose-sensitive factor. Tan et al. showed that hyperglycemia in the chick embryo eye induced eye malformation, but this was rescued by restoring Pax6 expression using proanthocyanidins [75]. Nevertheless, my results demonstrated that there was no difference in the expression of Pax6 and optic vesicle formation between the control and insulin-treated groups, indicating that insulin-induced maternal hypoglycemia caused fetal eye anomalies by a different mechanism from that in Pax6 mutants.

Histopathological examination revealed that hypoplasia and degeneration of optic vesicle/optic cup and lens placode/lens vesicle on E11 through E12 would be a trigger of eye anomalies. The expression of MITF and chx10 on E11 in the insulin-treated group was ectopic and suppressed. The expression of MITF, which is regulated by TGFβ released from surrounding extraocular tissues, has been reported to induce RPE around E11 [22]. Meanwhile, the expression of chx10, which is regulated by FGF released from surface ectoderm (lens placode), was found to induce NR around E11 [34,61]. While the author did not evaluate the expression of MITF and chx10 on E10, since optic vesicle on E10 did not contact with the surface ectoderm due to mesenchyme between optic vesicle and surface ectoderm in my experiment, it was considered too early to evaluate MITF and chx10 expression on E10. Taken together, insulin-induced maternal hypoglycemia triggered morphological changes in the presumptive NR/RPE and lens, resulting in an abnormal interaction between presumptive RPE and surrounding extraocular area or presumptive NR and surface ectoderm (lens placode) on E11. Consequently, the abnormal expression of MITF and chx10 were induced and then further abnormalities in the retina and lens were developed on E11 through E12.

Immunostaining for crystallin α, β, and γ on E17 revealed that lens fiber and lens epithelium were positive both in the control and insulin-treated groups and that the eosinophilic material in the lumen of the insulin-treated group was crystallin that had leaked from lens fibers. While the significance of this crystallin findings remains unclear, it was shown that insulin-induced maternal hypoglycemia did not intensely disrupt crystallin production of fetal eyes. Hence, a different mechanism not involving JNK (c-Jun NH2-terminal kinase) inhibition or hyperglycemia [40,66] that modulated crystallin production and resulted in cataract was thought to have contributed to the induction of eye anomalies in the insulin-treated group. Moreover, E-cadherin was not affected by insulin-induced maternal hypoglycemia, suggesting that fetal eye anomalies due to insulin-induced maternal hypoglycemia were caused by a different mechanism from that in Ras transgenic mice showing abnormal crystallin and E-cadherin localization [10].

In conclusion, my results proved that maternal hypoglycemia by injecting insulin into pregnant rats from days 6 to 11 of pregnancy induced developmental disruption, but not simple developmental retardation (nanophthalmia), in fetal eyes. The insulin-induced maternal hypoglycemia-induced developmental disruption in fetal eyes was characterized by defects, hypoplasia, and degeneration in the retina and lens and was observed from E11 during formation of the optic cup. Although the mechanism underlying the abnormal eye development has not been fully elucidated in this study, these results revealed the possible trigger of developmental abnormalities under maternal severe hypoglycemia. Further investigation on the mechanism may help to understand a primary point of action and give a novel insight in prevention of hypoglycemia-induced eye anomalies. My study also indicated that fetal eye anomalies might be triggered by a failure of the presumptive retina and lens to interact. Furthermore, my study demonstrated the importance of maternal blood glucose monitoring and its control to prevent fetuses from eye developmental disruption, but not eye developmental retardation, under the treatment with anti-diabetic drugs such as insulin for pregnant patients.

5. Summary

The author previously revealed that insulin-induced severe and long-lasting maternal hypoglycemia in rats caused anophthalmia and microphthalmia in fetuses; however, it remained unclear whether hypoglycemia-induced eye anomalies were developmental retardation or disruption, and when and how they developed. Hence, the author induced hypoglycemia in pregnant Sprague-Dawley rats by injecting insulin from Days 6 to 11 of pregnancy and performed periodic histopathological examination of fetal eyes from embryonic days (E)10 to 20.

On E10, optic vesicle had developed normally both in the control and insulin-treated group; however, on E11, optic cup (OC) had developed in the control group but not in the insulin-treated group. On E12, neural retina (NR), retinal pigmented epithelium (RPE), lens, and presumptive cornea had been observed in the control group. In contrast, lens pit and OC with remaining space between RPE and NR had developed in the insulin-treated group. From E13 to E15, developmental disruption characterized by defects, hypoplasia, and degeneration in the retina, lens, and cornea was observed in the insulin-treated group, resulting in anophthalmia or microphthalmia on E20. Moreover, the expression of MITF and chx10, which are essential for early eye development by expressing in the presumptive retina and lens and regulating each other's expression level, was ectopic and suppressed on E11.

In conclusion, insulin-induced maternal hypoglycemia caused developmental disruption, but not simple developmental retardation of fetal eyes, and its trigger might be a failure of presumptive retina and lens to interact on E11.

Graphical Summary

Schematic overview of eye development from embryonic day (E)10 through E20 in the control and hypoglycemia groups.

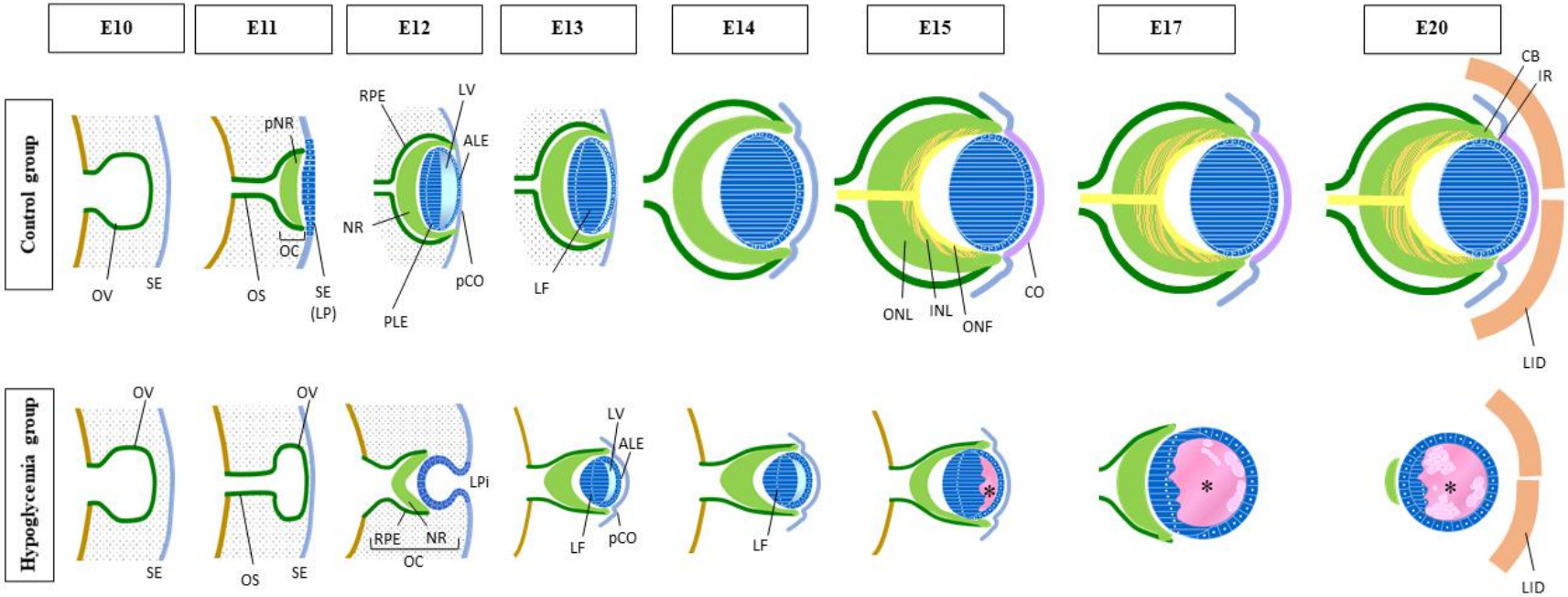

Control group: E10, eye formation began with development of the optic vesicle (OV). E11, OV folded inward and formed the optic cup (OC) with presumptive neural retina (pNR) inducing the lens placode (LP) in the overlying surface ectoderm (SE) and the optic stalk (OS) developed. E12, eye field was oval, and neural retina (NR) and retinal pigmented epithelium (RPE) developed. Lens vesicle (LV) consisted of posterior lens epithelium (PLE) and anterior lens epithelium (ALE), which was covered by the presumptive cornea (pCO). E13 to E14, PLE elongated the lens fiber (LF) to dismiss the cavity of the LV and denucleated. E15, cornea (CO) formed and NR divided into 3 layers: the outer neuroblastic layer (ONL), the inner neuroblastic layer (INL), and the optic nerve fibers (ONF). E15 to E20, iris (IR), ciliary body (CB), and eyelid (LID) developed.

Hypoglycemia group: E10, eye formation began with development of the OV as in the control group; however, eye formation from E11 in the hypoglycemia group differed from that in the control group. E12, the eye field was shaped as a small triangle, and the lens pit (LPi) and OC developed; however, a space between RPE and NR remained. E13 to E15, LF failed to denucleate and did not adequately elongate, so the lumen of the LV remained and was then filled with eosinophilic materials (*). E17 to E20, hypoplasia and degeneration of the retina and lens were noted, and neither ciliary body nor iris developed, indicating that the anophthalmia or microphthalmia was caused by developmental disruption.

Conclusion

Insulin is currently the only option for the treatment of diabetes in pregnant women. Although some reports describing that insulin is teratogenic during pregnancy in animals have been published, insulin cannot pass the placental barrier by facilitated diffusion due to its large molecular size, so it rarely affects fetuses directly and can be prescribed during pregnancy. Conversely, almost all launched oral antidiabetic drugs, whose molecular size is small and can reach fetuses, are contraindicated during pregnancy because of their potential for teratogenicity and/or embryo-fetal lethality in animal studies. The teratogenic potential of DS-7309, a glucokinase activator that was developed as an oral antidiabetic drug, has been recognized in embryo-fetal developmental toxicity studies using rats and rabbits. However, it was unclear how fetal anomalies developed and whether the teratogenicity of DS-7309 is due to direct effects of the drug on fetuses or indirect effects caused by maternal hypoglycemia. Therefore, comprehensive investigation of the teratogenicity induced by DS-7309 was conducted as follows:

In Chapter 1, the toxicological effects of DS-7309 on pregnancy and embryo-fetal development in rats and rabbits and maternal blood glucose levels were examined. DS-7309 was administered at 0, 3, 10, or 100 mg/kg to Sprague-Dawley rats from Days 7 to 17 of pregnancy or at 0, 10, 30, or 100 mg/kg to New Zealand White rabbits from Days 6 to 18 of pregnancy. Necropsy and fetal examination were performed on Day 20 of pregnancy in rats or Day 28 of pregnancy in rabbits. In rats, maternal severe hypoglycemia (approximately 50 mg/dL) was seen at 3 and 10 mg/kg, but it recovered by 7 h after dosing without any toxic changes in fetuses. In contrast, continuous severe maternal hypoglycemia (≥7 h), fetal eye anomalies, and decreased fetal body weight were noted at 100 mg/kg. In rabbits, no fetal anomalies were seen at 10 and 30 mg/kg where maternal blood glucose level dropped to approximately 60 to 90 mg/dL, but recovered by 7 h after dosing at the latest. Meanwhile, at 100 mg/kg, severe hypoglycemia (around 60 mg/dL) was maintained and did not recover until 24 h after dosing; it resulted in decreased fetal viability and increased fetal skeleton anomalies. These findings indicate that DS-7309 could lead to teratogenicity in rats and rabbits, which was considered to be related to continuous severe maternal hypoglycemia.

In Chapter 2, the relationship between the duration and severity of maternal hypoglycemia and teratogenicity was investigated in detail by the administration of insulin, which rarely affects fetuses directly, to pregnant rats. Four different forms of insulin (insulin human, insulin aspart, insulin glargine, and insulin detemir) or physiological saline were subcutaneously injected at 1 or 2 dose levels to Sprague-Dawley rats from Days 6 to 11 of pregnancy. Time-course measurement of blood glucose levels, and fetal examination were conducted. In the insulin human and insulin aspart (low dose) groups, while severe hypoglycemia (approximately 50 mg/dL) was seen, it lasted only 6 h and no fetal anomalies were observed. In contrast, fetal axial skeleton anomalies were observed in the insulin aspart (high dose) group, which exhibited severe hypoglycemia of an intermediate duration (9 h). Eye and axial skeleton anomalies were observed in the insulin glargine and insulin detemir groups, which exhibited continuous severe hypoglycemia (≥15 h). These results revealed that insulin-induced maternal hypoglycemia caused fetal eye and skeleton anomalies, which were similar to fetal anomalies observed in the DS-7309-treated rats or rabbits. In addition, the key causative factors for this teratogenicity were the duration and severity of maternal hypoglycemia.

In Chapter 3, the pathogenesis of and factors contributing to hypoglycemia-induced eye anomalies were further investigated in pregnant Sprague-Dawley rats given insulin glargine from Days 6 to 11 of pregnancy at the same dose level as the study described in Chapter 2 or physiological saline as a control group. Periodic histopathological examination of fetal eyes from embryonic days (E)10 to 20 revealed that the optic vesicle had developed normally in both the control and the insulin-treated group on E10. However, on E11, optic cup (OC) had developed in the control group but not in the insulin-treated group. On E12, neural retina (NR), retinal pigmented epithelium (RPE), lens, and presumptive cornea had differentiated in the control group, while incomplete differentiation in the insulin-treated group up to the lens pit and OC was observed. In addition, whereas the space between RPE and NR had disappeared as development progressed, that space had remained in the insulin-treated group. From E13 to E15, developmental disruption characterized by defects, hypoplasia, and degeneration in the retina, lens, and cornea was observed in the insulin-treated group, resulting in anophthalmia or microphthalmia on E20. Moreover, the expression of MITF and chx10, which are essential for early eye development by being

expressed in the presumptive retina and lens and regulating each other's expression level, was ectopic and suppressed on E11. These results indicated that insulin-induced maternal hypoglycemia caused developmental disruption, but not simple developmental retardation of fetal eyes. In addition, its trigger might be morphological changes in the presumptive retina and lens on E11, resulting in a failure of presumptive retina and lens to interact on E11, leading to subsequent hypoplasia of optic vesicle/cup and lens vesicle placode/vesicle.

In conclusion, a glucokinase activator, DS-7309, induced fetal eye and skeleton anomalies in rats and rabbits, which were similar to the fetal anomalies observed in the insulin-treated rats and rabbits. Insulin was suggested to induce fetal anomalies via severe and continuous maternal hypoglycemia without direct effects on fetuses. Therefore, it was considered that DS-7309-induced fetal anomalies were caused by an indirect effect due to maternal hypoglycemia as in case of insulin. Furthermore, the author demonstrated that the eye anomalies induced by maternal hypoglycemia were developmental disruption, but not simple developmental retardation, the trigger for which might be a failure of presumptive retina and lens to interact on E11. My work provides additional insights into the risks of maternal hypoglycemia to fetuses and demonstrates the importance of monitoring maternal blood glucose and its control to prevent fetuses from suffering eye developmental disruption and skeleton anomalies under the treatment of pregnant patients with antidiabetic drugs.

Acknowledgments

I would like to express my sincere gratitude to my supervisor, Professor Kazuhiro Kimura (Laboratory of Biochemistry, Graduate School of Veterinary Medicine, Hokkaido University), for the inspection and critical review of this manuscript.

I would also like to express my deep appreciation to my deputy examiners, Professor Yasuhiro Kon (Laboratory of Anatomy, Graduate School of Veterinary Medicine, Hokkaido University), Professor Ken-ichi Otsuguro (Laboratory of Pharmacology, Graduate School of Veterinary Medicine, Hokkaido University), and Associate Professor Yuko Okamatsu (Associate Professor of Laboratory of Biochemistry, Graduate School of Veterinary Medicine, Hokkaido University), for their invaluable advice on improving this manuscript.

I am deeply grateful to Dr. Yoshimi Tsuchiya, Vice President of the Medicinal Safety Research Laboratories, Daiichi Sankyo Co., Ltd., for her constant encouragement and considerate guidance during my research and manuscript writing.

I greatly appreciate Dr. Kazuhiro Shimomura, Vaccine Research Laboratories, Daiichi Sankyo Co., Ltd., for the guidance and supervision based on his expertise in reproductive and developmental toxicology.

I also thank Toshiki Matsuoka, Takanori Maejima, Toshiyuki Watanabe, and Ken Sakurai for their kind instructions and advice during my research.

My great appreciation is also extended to Katsumi Fujita, Satoko Yahagi, Naoko Saeki, Yoshiko Ohshima, Yasuko Kato, Shinobu Hakamata, Kumi Honda, and colleagues at Medicinal Safety Research Laboratories, Daiichi Sankyo Co., Ltd., for their technical support.

Finally, I am grateful to Kazunori Kuwata, Muneharu Kuwata, Yugo Kuwata, Yoichi Suzuki, Hitomi Suzuki, and other family members for understanding and heart-warming support.

References

1) Agency EP. Guidelines for Developmental Toxicity Risk Assessment. Federal Register 56, 63798-63826, 1991.
2) Akazawa M, Akazawa S, Hashimoto M, Akashi M, Yamazaki H, Tahara D, Yamamoto H, Yamaguchi Y, Nakanishi T, Nagataki S. Effects of brief exposure to insulin-induced hypoglycemic serum during organogenesis in rat embryo culture. Diabetes 38, 1573-1578, 1989.
3) Akazawa S, Akazawa M, Hashimoto M, Yamaguchi Y, Kuriya N, Toyama K, Ueda Y, Nakanishi T, Mori T, Miyake S, et al. Effects of hypoglycaemia on early embryogenesis in rat embryo organ culture. Diabetologia 30, 791-796, 1987.
4) Andley UP. Crystallins in the eye: Function and pathology. Prog Retin Eye Res 26, 78-98, 2007.
5) Andley UP. The lens epithelium: focus on the expression and function of the alpha-crystallin chaperones. Int J Biochem Cell Biol 40, 317-323, 2008.
6) Araki E, Goto A, Kondo T, Noda M, Noto H, Origasa H, Osawa H, Taguchi A, Tanizawa Y, Tobe K, Yoshioka N. Japanese Clinical Practice Guideline for Diabetes 2019. Diabetol Int 11, 165-223, 2020.
7) Balakrishnan S, Sadasivam M, Kannan A, Panneerselvam A, Prahalathan C. Glucose modulates Pax6 expression through the JNK/p38 MAP kinase pathway in pancreatic beta-cells. Life Sci 109, 1-7, 2014.
8) Baumer N, Marquardt T, Stoykova A, Spieler D, Treichel D, Ashery-Padan R, Gruss P. Retinal pigmented epithelium determination requires the redundant activities of Pax2 and Pax6. Development 130, 2903-2915, 2003.
9) Buchanan TA, Schemmer JK, Freinkel N. Embryotoxic effects of brief maternal insulin-hypoglycemia during organogenesis in the rat. J Clin Invest 78, 643-649, 1986.
10) Burgess D, Zhang Y, Siefker E, Vaca R, Kuracha MR, Reneker L, Overbeek PA, Govindarajan V. Activated Ras alters lens and corneal development through induction of distinct downstream targets. BMC Dev Biol 10, 13, 2010.

11) Burmeister M, Novak J, Liang MY, Basu S, Ploder L, Hawes NL, Vidgen D, Hoover F, Goldman D, Kalnins VI, Roderick TH, Taylor BA, Hankin MH, McInnes RR. Ocular retardation mouse caused by Chx10 homeobox null allele: impaired retinal progenitor proliferation and bipolar cell differentiation. Nat Genet 12, 376-384, 1996.

12) Carter-Dawson LD, LaVail MM. Rods and cones in the mouse retina. II. Autoradiographic analysis of cell generation using tritiated thymidine. J Comp Neurol 188, 263-272, 1979.

13) CDER/FDA. Guidance for Industry Estimating the Maximum Safe Starting Dose in Initial Clinical Trials for Therapeutics in Adult Healthy Volunteers, 2005.

14) Chomette G. [Developmental disorders after insulin shock in pregnant rabbits]. Beitr Pathol Anat 115, 439-451, 1955.

15) Chow RL, Lang RA. Early eye development in vertebrates. Annu Rev Cell Dev Biol 17, 255-296, 2001.

16) Cvekl A, Ashery-Padan R. The cellular and molecular mechanisms of vertebrate lens development. Development 141, 4432-4447, 2014.

17) Davis-Silberman N, Kalich T, Oron-Karni V, Marquardt T, Kroeber M, Tamm ER, Ashery-Padan R. Genetic dissection of Pax6 dosage requirements in the developing mouse eye. Hum Mol Genet 14, 2265-2276, 2005.

18) Dawson AB. A note on the staining of the skeleton of cleared specimens with alizarin red S. Strain technol 1, 1926.

19) Eriksson UJ. Congenital malformations in diabetic animal models--a review. Diabetes Res 1, 57-66, 1984.

20) F.J. Lovicu MLRE. Lens induction and determination, Cambridge University Press, New York. pp. 27-47, 2004.

21) Fuhrmann S. Eye morphogenesis and patterning of the optic vesicle. Curr Top Dev Biol 93, 61-84, 2010.

22) Fuhrmann S, Levine EM, Reh TA. Extraocular mesenchyme patterns the optic vesicle during early eye development in the embryonic chick. Development 127, 4599-4609, 2000.

23) Garcia-Bournissen F, Feig DS, Koren G. Maternal-fetal transport of hypoglycaemic drugs. Clin Pharmacokinet 42, 303-313, 2003.

24) Gosmain Y, Katz LS, Masson MH, Cheyssac C, Poisson C, Philippe J. Pax6 is crucial for beta-cell function, insulin biosynthesis, and glucose-induced insulin secretion. Mol Endocrinol 26, 696-709, 2012.

25) Graw J. Eye development. Curr Top Dev Biol 90, 343-386, 2010.

26) Graw J. Genetic aspects of embryonic eye development in vertebrates. Dev Genet 18, 181-197, 1996.

27) Greuter MJ, van Emmerik NM, Wouters MG, van Tulder MW. Quality of guidelines on the management of diabetes in pregnancy: a systematic review. BMC Pregnancy Childbirth 12, 58, 2012.

28) Grimsby J, Sarabu R, Corbett WL, Haynes NE, Bizzarro FT, Coffey JW, Guertin KR, Hilliard DW, Kester RF, Mahaney PE, Marcus L, Qi L, Spence CL, Tengi J, Magnuson MA, Chu CA, Dvorozniak MT, Matschinsky FM, Grippo JF. Allosteric activators of glucokinase: potential role in diabetes therapy. Science 301, 370-373, 2003.

29) Hannah RS, Moore KL. Effects of fasting and insulin on skeletal development in rats. Teratology 4, 135-140, 1971.

30) Hay WW, Jr. Placental-fetal glucose exchange and fetal glucose metabolism. Trans Am Clin Climatol Assoc 117, 321-339; discussion 339-340, 2006.

31) Hofmann T, Horstmann G, Stammberger I. Evaluation of the reproductive toxicity and embryotoxicity of insulin glargine (LANTUS) in rats and rabbits. Int J Toxicol 21, 181-189, 2002.

32) Horsford DJ, Nguyen MT, Sellar GC, Kothary R, Arnheiter H, McInnes RR. Chx10 repression of Mitf is required for the maintenance of mammalian neuroretinal identity. Development 132, 177-187, 2005.

33) Hunt KJ, Schuller KL. The increasing prevalence of diabetes in pregnancy. Obstet Gynecol Clin North Am 34, 173-199, vii, 2007.

34) Hyer J, Mima T, Mikawa T. FGF1 patterns the optic vesicle by directing the placement of the neural retina domain. Development 125, 869-877, 1998.

35) ICH. International council for harmonisation of technical requirements for pharmaceuticals for human use. Detection of reproductive and developmental toxicity for human pharmaceuticals. S5 (R3), 2020.

36) Jensen VFH, Molck AM, Lykkesfeldt J, Fels JJ, Andersen L, Renaut R, McGuigan F, Akesson KE, Bogh IB. Importance of gestational hypoglycaemia for foetal malformations and skeletal development in rats. Reprod Toxicol 91, 14-26, 2020.

37) Jovanovic L. American Diabetes Association's Fourth International Workshop-Conference on Gestational Diabetes Mellitus: summary and discussion. Therapeutic interventions. Diabetes Care 21 Suppl 2, B131-137, 1998.

38) Kawaguchi M, Tanigawa K, Tanaka O, Kato Y. Embryonic growth impaired by maternal hypoglycemia during early organogenesis in normal and diabetic rats. Acta Diabetol 31, 141-146, 1994.

39) Knobloch J, Schmitz I, Gotz K, Schulze-Osthoff K, Ruther U. Thalidomide induces limb anomalies by PTEN stabilization, Akt suppression, and stimulation of caspase-dependent cell death. Mol Cell Biol 28, 529-538, 2008.

40) Kumar PA, Reddy PY, Srinivas PN, Reddy GB. Delay of diabetic cataract in rats by the antiglycating potential of cumin through modulation of alpha-crystallin chaperone activity. J Nutr Biochem 20, 553-562, 2009.

41) Kuwata C, Saeki N, Honda K, Matsuoka T, Tsuchiya Y, Shimomura K. Effects of maternal hypoglycemia on fetal eye and skeleton development in rats. Reprod Toxicol 71, 135-141, 2017.

42) Laakso M. Not for the eyes only: PAX6 and glucose metabolism. Diabetologia 52, 381-384, 2009.

43) Landauer W. Is Insulin a teratogen? Teratology 5, 129-135, 1972.

44) Lapolla A, Dalfra MG, Fedele D. Insulin therapy in pregnancy complicated by diabetes: are insulin analogs a new tool? Diabetes Metab Res Rev 21, 241-252, 2005.

45) Lau C, Narotsky MG, Lui D, Best D, Setzer RW, Mann PC, Wubah JA, Knudsen TB. Exposure-disease continuum for 2-chloro-2'-deoxyadenosine (2-CdA), a prototype teratogen: induction of lumbar hernia in the rat and species comparison for the teratogenic responses. Teratology 66, 6-18, 2002.

46) Liu IS, Chen JD, Ploder L, Vidgen D, van der Kooy D, Kalnins VI, McInnes RR. Developmental expression of a novel murine homeobox gene (Chx10): evidence for roles in determination of the neuroretina and inner nuclear layer. Neuron 13, 377-393, 1994.

47) Matschinsky FM. Glucokinase as glucose sensor and metabolic signal generator in pancreatic beta-cells and hepatocytes. Diabetes 39, 647-652, 1990.

48) Matschinsky FM, Magnuson MA, Zelent D, Jetton TL, Doliba N, Han Y, Taub R, Grimsby J. The network of glucokinase-expressing cells in glucose homeostasis and the potential of glucokinase activators for diabetes therapy. Diabetes 55, 1-12, 2006.

49) Matschinsky FM, Zelent B, Doliba N, Li C, Vanderkooi JM, Naji A, Sarabu R, Grimsby J. Glucokinase activators for diabetes therapy: May 2010 status report. Diabetes Care 34 Suppl 2, S236-243, 2011.

50) Matsubara Y, Mikami T. [Teratogenic potentially of single dose of thalidomide in JW-NIBS rabbits]. Jikken Dobutsu 34, 295-302, 1985.

51) Matthew H. Kaufman JBLB. The Anatomical Basis of Mouse Development, Academic Press, 1999.

52) Miyamoto M, Sakaguchi T, Midorikawa O. Teratogenic Effects of Sulfonylureas and Insulin in Rats. Congenital Anomalies 17, 31-37, 1977.

53) Miyamoto M, Sakaguchi T, Midorikawa O. Teratogenicity of Regular Insulin and Ultralente Insulin in Rats Congenital Anomalies 19, 291-297, 1979.

54) Nguyen M, Arnheiter H. Signaling and transcriptional regulation in early mammalian eye development: a link between FGF and MITF. Development 127, 3581-3591, 2000.

55) NovoNordiskInc. Levemir (insulin detemir) [FDA: Pharmacology and Toxicology Review], Available from: http://www.accessdata.fda.gov/scripts/cder/daf/index.cfm?event=overview.process&ApplNo=021536, 2005.

56) NovoNordiskInc. Novolin FlexPen, InnoLet, Novolin R 100 IU/mL (insulin human) [PMDA: Interview form], Available form: http://www.pmda.go.jp/PmdaSearch/iyakuDetail/GeneralList/2492403A4, 2021.

57) NovoNordiskInc. Novolog (insulin aspart recombinant) [FDA: Pharmacology Review (s)], Available form: http://www.accessdata.fda.gov/scripts/cder/daf/index.cfm?event=overview.process&ApplNo=020986, 2000.

58) O'Hara MF, Charlap JH, Craig RC, Knudsen TB. Mitochondrial transduction of ocular teratogenesis during methylmercury exposure. Teratology 65, 131-144, 2002.

59) Ogino H, Ochi H, Reza HM, Yasuda K. Transcription factors involved in lens development from the preplacodal ectoderm. Dev Biol 363, 333-347, 2012.

60) Peiffer RL, McCullen R, Alles AJ, Sulik KK. Relationship of cell death to cyclophosphamide-induced ocular malformations. Teratog Carcinog Mutagen 11, 203-212, 1991.

61) Pittack C, Grunwald GB, Reh TA. Fibroblast growth factors are necessary for neural retina but not pigmented epithelium differentiation in chick embryos. Development 124, 805-816, 1997.

62) Pontoriero GF, Smith AN, Miller LA, Radice GL, West-Mays JA, Lang RA. Co-operative roles for E-cadherin and N-cadherin during lens vesicle separation and lens epithelial cell survival. Dev Biol 326, 403-417, 2009.

63) Poon K, King AB. Glargine and detemir: Safety and efficacy profiles of the long-acting basal insulin analogs. Drug Healthc Patient Saf 2, 213-223, 2010.

64) Rapaport DH, Wong LL, Wood ED, Yasumura D, LaVail MM. Timing and topography of cell genesis in the rat retina. J Comp Neurol 474, 304-324, 2004.

65) Ream JR, Jr., Weingartern PL, Pappas AM. Evaluation of the prenatal effects of massive doses of insulin in rats. Teratology 3, 29-32, 1970.

66) Reddy VS, Kumar CU, Reddy GB. Effect of chronic hyperglycemia on crystallin levels in rat lens. Biochem Biophys Res Commun 446, 602-607, 2014.

67) Reese BE. Development of the retina and optic pathway. Vision Res 51, 613-632, 2011.

68) Reis LM, Semina EV. Conserved genetic pathways associated with microphthalmia, anophthalmia, and coloboma. Birth Defects Res C Embryo Today 105, 96-113, 2015.

69) SanofiAventisUS. Lantus (insulin glargine recombinant) [FDA: Pharmacology Review (s)], Available form http://www.accessdata.fda.gov/scripts/cder/daf/index.cfm?event=overview.process&ApplNo=021081, 2000.

70) Shaham O, Menuchin Y, Farhy C, Ashery-Padan R. Pax6: a multi-level regulator of ocular development. Prog Retin Eye Res 31, 351-376, 2012.

71) Sidman RL. Histogenesis of mouse retina studied with thymidine-H3, Academic Press., New York. pp. 487-505, 1961.
72) Smithberg M, Runner MN. Teratogenic Effects of Hypoglycemic Treatments in Inbred Strains of Mice. Am J Anat 113, 479-489, 1963.
73) Sternisha SM, Miller BG. Molecular and cellular regulation of human glucokinase. Arch Biochem Biophys 663, 199-213, 2019.
74) Sulik KK, Dehart DB, Rogers JM, Chernoff N. Teratogenicity of low doses of all-trans retinoic acid in presomite mouse embryos. Teratology 51, 398-403, 1995.
75) Tan RR, Zhang SJ, Li YF, Tsoi B, Huang WS, Yao N, Hong M, Zhai YJ, Mao ZF, Tang LP, Kurihara H, Wang Q, He RR. Proanthocyanidins Prevent High Glucose-Induced Eye Malformation by Restoring Pax6 Expression in Chick Embryo. Nutrients 7, 6567-6581, 2015.
76) Tanigawa K, Kawaguchi M, Tanaka O, Kato Y. Skeletal malformations in rat offspring. Long-term effect of maternal insulin-induced hypoglycemia during organogenesis. Diabetes 40, 1115-1121, 1991.
77) Tibaldi JM. Evolution of insulin: from human to analog. Am J Med 127, S25-38, 2014.
78) Torlone E, Di Cianni G, Mannino D, Lapolla A. Insulin analogs and pregnancy: an update. Acta Diabetol 46, 163-172, 2009.
79) Toulis KA, Nirantharakumar K, Pourzitaki C, Barnett AH, Tahrani AA. Glucokinase Activators for Type 2 Diabetes: Challenges and Future Developments. Drugs 80, 467-475, 2020.
80) Tran ND, Hunter SK, Yankowitz J. Oral hypoglycemic agents in pregnancy. Obstet Gynecol Surv 59, 456-463; quiz 485, 2004.
81) Trujillo AL. Insulin Analogs and Pregnancy. Diabetes Spectrum 20, 94-101, 2007.
82) Wang Q, Fang WH, Krupinski J, Kumar S, Slevin M, Kumar P. Pax genes in embryogenesis and oncogenesis. J Cell Mol Med 12, 2281-2294, 2008.
83) Wilson JG. Methods for administrating agents and detecting malformations in experimrntal animals. Chicago: University of Cicago Press, 1965.
84) Young RW. Cell differentiation in the retina of the mouse. Anat Rec 212, 199-205, 1985.

Summary in Japanese

インスリンは、現在妊婦に使用できる唯一の糖尿病治療薬である。インスリンは、妊娠動物への投与で胎子毒性を示すとの報告があるものの、分子量が約5800 と比較的大きいため胎盤を受動拡散で通過することができず、胎子に直接作用を及ぼさないと考えられ、妊婦でも服薬が可能とされている。一方、その他の経口糖尿病治療薬の多くは分子量が小さく胎盤を通過して胎子に直接影響を与える可能性があり、動物実験で催奇形性又は胚・胎子致死作用を示したため、妊娠期の服薬は禁忌とされている。経口糖尿病治療薬として開発されていたグルコキナーゼアクチベーターである DS-7309 を妊娠ラット及び妊娠ウサギに投与すると胎子に奇形がみられた。しかし、DS-7309 がどのように胎子異常を引き起こすのか、それは DS-7309 の胚・胎子への直接作用なのか、あるいは母動物の低血糖を介した間接作用なのかは明らかではない。そこで、本研究では、DS-7309 によって引き起こされる奇形について、包括的な検討を行った。

第一章では、DS-7309 を用いて、ラットとウサギの妊娠及び胚・胎子の発達に及ぼす影響並びに母動物の血糖値推移を調べた。DS-7309 を 0、3、10、100 mg/kg で Sprague-Dawley ラットの妊娠 7 から 17 日に 1 日 1 回経口投与し、妊娠 20 日に剖検及び胎子観察を行った。その結果、3 及び 10 mg/kg 群で母動物の重度の低血糖（約 50 mg/dL）がみられたが、投与 7 時間後には回復し、胎子毒性も認められなかった。一方、100 mg/kg 群では 7 時間以上続く持続的かつ重度の母動物の低血糖がみられ、胎子の眼部奇形及び胎子体重の減少が認められた。また、New Zealand White ウサギの妊娠 6 から 18 日に 0、10、30、100 mg/kg で経口投与し、妊娠 28 日に剖検及び胎子観察を行った。ウサギを用いた試験では、10 及び 30 mg/kg 群で母動物の血糖値が 60～90 mg/dL まで低下したが 7 時間後に回復し、胎子毒性は認められなかった。一方、100 mg/kg では重度の低血糖（約 60 mg/dL）が投与 24 時間後まで継続し、胎子生存率の減少及び胎子骨格異常が認められた。以上のことから、DS-7309 はラットとウサギで胎子に奇形を引き起こすこと、それらには母動物の重篤かつ持続的な低血糖が関連している可能性が考えられた。

第二章では、胎盤を通過しないため胎子に直接作用を示さないインスリンを妊娠ラットに投与し、母動物の低血糖と胎子の異常について詳細に検討した。4 種の異なるインスリン製剤（ヒトインスリン、インスリンアスパルト、インスリングラルギン、インスリンデテミル）又は生理食塩水（対照群）を各 1～2 用量で妊

娠 6 から 11 日まで Sprague-Dawley ラットに 1 日 1～2 回皮下投与し、妊娠 20 日に剖検して胎子観察を行った。また母動物の投与後血糖値の推移を確認した。ヒトインスリン群及びインスリンアスパルト低用量群では、約 50 mg/dL の重篤な低血糖が 6 時間持続したが、胎子異常は認められなかった。一方、インスリンアスパルト高用量群では、重篤な低血糖が 9 時間持続し、胎子骨格異常が認められた。インスリングラルギン群及びインスリンデテミル群では、重篤な低血糖が 15 時間以上持続し、胎子観察で眼及び骨格に異常が認められた。以上の結果から、インスリンによる母動物低血糖は胎子の眼及び骨格に異常を引き起こし、その異常は DS-7309 投与で胎子に認められた異常と同質であることが確認された。さらに、インスリンによる催奇形性には母動物の低血糖の重篤度及びその持続時間が重要であることが示唆された。

第三章では、母動物低血糖により生じる胎子の眼の異常について病理学的検査を実施し、異常発生推移を詳細に検討し、さらには異常発生に関与する因子の探索を行った。妊娠 6 から 11 日の Sprague-Dawley ラットに、第二章と同用量のインスリングラルギン又は生理食塩水（対照群）を 1 日 1 回皮下投与し、胎齢 10 から 20 日に経時的な病理学的検査を行った。その結果、胎齢 10 日では対照群及びインスリン群共に発生異常は認められなかったが、対照群では胎齢 11 日で眼杯が発生しているにも関わらず、インスリン群では眼杯が認められなかった。胎齢 12 日において、対照群では神経網膜、網膜色素上皮、水晶体、角膜予定域が分化した一方、インスリン群での分化は眼杯及び水晶体窩までであった。さらに、対照群では発生が進み神経網膜層及び色素上皮層間の空隙が消失したのに対し、インスリン群では消失せず残存していた。胎齢 13 から 15 日にかけて、インスリン群では網膜、水晶体、及び角膜の欠損、変性、及び低形成を主体とする発生異常が認められ、胎齢 20 日には小眼球症や無眼球症がみられた。さらに、網膜又は水晶体予定域に発現し、互いの発現を調節することで初期眼部発生に必須の役割を果たす転写因子 MITF と chx10 の発現を調べたところ、胎齢 11 日で発現の異所性及び抑制が認められた。したがって、母動物へのインスリン投与による胎子の無眼球症や小眼球症は、単なる発生遅延ではなく発生異常により生じていると考えられた。加えて、胎齢 11 日における網膜予定域と水晶体予定域の形態学的な変化により生じた網膜予定域と水晶体予定域の相互作用障害がこの発生異常のトリガーであり、続いて眼胞／眼胚や水晶体板／水晶体胞の変性を伴う低形成が惹き起こされたと示唆された。

以上、本研究により、グルコキナーゼアクチベーターである DS-7309 の妊娠ラットや妊娠ウサギへの投与でみられた胎子の眼及び骨格の奇形は、胎盤を通過しないインスリンにより誘発される胎子奇形と同質のものであり、さらに母動物の持続的かつ重篤な低血糖の関与が示唆された。つまり、DS-7309 は胎子に直接作用して奇形を惹起しているのではなく、インスリンと同様に母動物の低血糖を介して間接的に胎子奇形を引き起こしていると考えられた。また、母動物の低血糖により生じる無・小眼球症は発生遅延ではなく発生異常であり、胎齢 11 日に認められる網膜予定域と水晶体予定域の相互作用障害がトリガーである可能性が示唆された。以上、本研究により、母動物の低血糖が胎子に与えるリスクについて新たな知見が得られ、妊婦が経口糖尿病治療薬を服薬する際には、血糖値の適切なモニター及びコントロールにより胎子の眼と骨の奇形を防ぐことが重要であると考えられた。

眼部発生の概要（対照群及びインスリン群、胎齢10から20日）

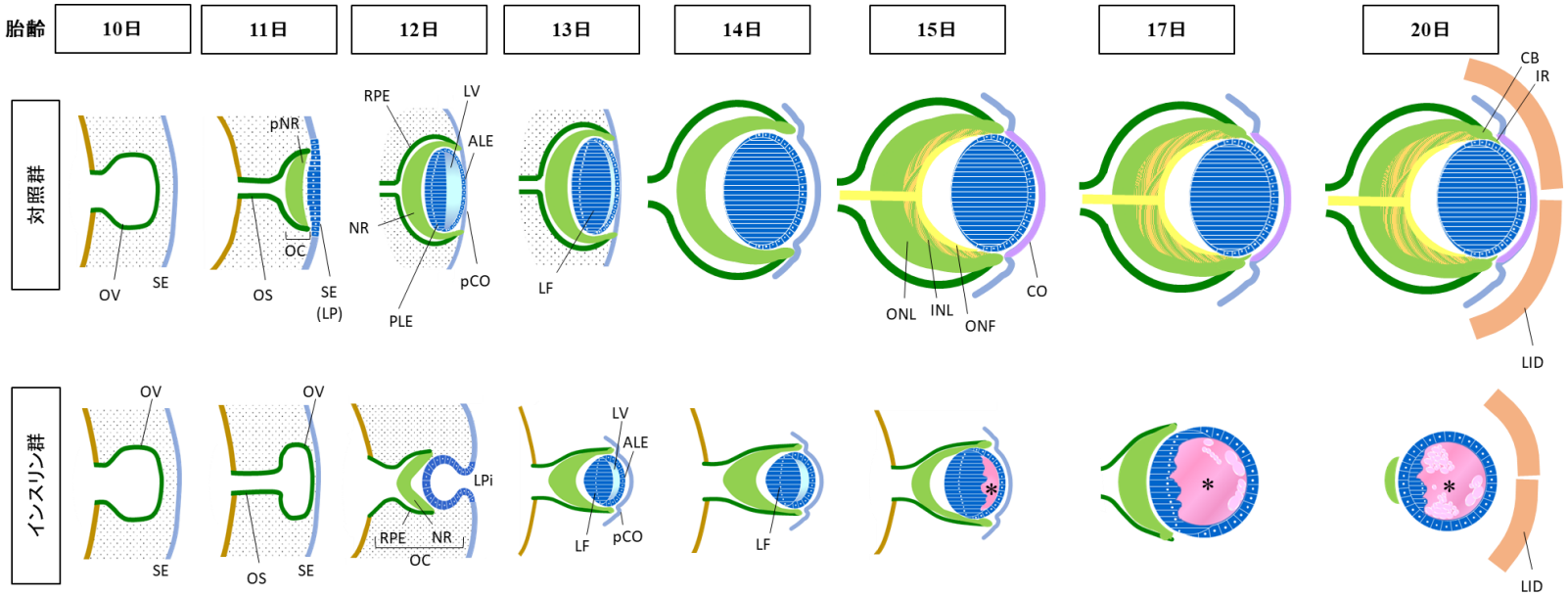

対照群：胎齢 10 日で眼胞（OV）が形成され眼発生が開始した。胎齢 11 日では眼胞は陥入し眼杯（OC）を形成し、神経網膜予定域（pNR）が表皮外胚葉に作用し水晶体板（LP）を誘導した。また、眼茎（OS）も発生した。胎齢 12 日には眼部は円形となり、神経網膜（NR）及び網膜色素上皮（RPE）が発生した。水晶体胞（LV）は後壁の水晶体上皮細胞（PLE）と前壁の水晶体上皮細胞（ALE)から成り、前壁部は角膜予定域（pCO）に接していた。胎齢 13 から 14 日では、後壁の水晶体上皮細胞から水晶体線維細胞（LF）が伸長して水晶体胞腔が消失し、水晶体線維細胞は脱核して水晶体線維となった。胎齢 15 日では角膜（CO）が形成され、神経網膜は、外神経芽細胞層（ONL）、内神経芽細胞層（INL）、及び視神経繊維層の 3 層に分かれた。胎齢 15 から 20 日にかけて、虹彩（IR）、毛様体（CB）、眼瞼（LID）が発生した。

インスリン群：胎齢 10 日では対照群と同様に眼胞が形成されたが、胎齢 11 日以降の眼発生は対照群と異なっていた。胎齢 11 日では眼杯が認められず、胎齢 12 日で眼杯及び水晶体窩（LPi）が発生したが、神経網膜と網膜色素上皮間の空隙は残存しており、眼部は小型の三角形を呈した。胎齢 13 から 15 日にかけて水晶体線維細胞は脱核しておらず、身長は不十分で水晶体腔が残存し、好酸性物質が蓄積した (*)。胎齢 17 から 20 日にかけて、網膜や水晶体の低形成及び変性がみられ、虹彩や毛様体は認められなかった。以上のことから、小眼球症や無眼球症は発生異常に起因することが示された。