



HOKKAIDO UNIVERSITY

Title	AUSCULTATORY AND PHONOCARDIOGRAPHIC STUDIES ON THE CARDIOVASCULAR SYSTEM OF THE NEWBORN THOROUGHbred FOAL
Author(s)	MACHIDA, Noboru; YASUDA, Jun; TOO, Kimehiko
Citation	Japanese Journal of Veterinary Research, 35(4), 235-250
Issue Date	1987-10-30
DOI	https://doi.org/10.14943/jjvr.35.4.235
Doc URL	https://hdl.handle.net/2115/8930
Type	departmental bulletin paper
File Information	KJ00002376903.pdf



AUSCULTATORY AND PHONOCARDIOGRAPHIC STUDIES ON THE CARDIOVASCULAR SYSTEM OF THE NEWBORN THOROUGHBRED FOAL

Noboru MACHIDA, Jun YASUDA and Kimehiko TOO

(Accepted for publication September 12, 1987)

In 20 newborn thoroughbred foals cardiovascular examinations were made on the heart rate and detailed auscultation of the cardiovascular murmurs, which were also recorded by phonocardiography, was conducted between birth and two weeks of age.

A transient bradycardia, which was slower than the near-term fetal heart rate, was noted in neonates immediately after birth. Rapid and progressive increase in the heart rate between 5 and 40 minutes postpartum was observed together with a slower decrease after that time.

Cardiovascular murmurs in newborn foals consisted of a continuous murmur arising from the ductus arteriosus and a systolic murmur auscultated over the aortic area. The continuous murmur appeared 10–15 minutes after birth and disappeared 60–84 hours postpartum in most foals. Thus the physiologic closure of the ductus arteriosus appeared to occur around the postnatal 3rd day. The systolic murmur became auscultable at around the time of the disappearance of the continuous murmur and also could be heard for a short time soon after delivery, suggesting that this murmur may be related to a rise in systemic vascular resistance accompanied by closure of the ductus arteriosus or the umbilical vessels.

Furthermore, we examined the effect of changes in the heart rate due to injection of isoproterenol, atropine and propranolol on the intensity of the systolic murmur and discussed the occurrence of the murmur in newborn foals.

Key words : ductus arteriosus, foal, continuous murmur, systolic murmur, phonocardiogram

INTRODUCTION

In newborn animals, the circulation system undergoes dramatic changes to enable adaptation to autonomous life. During fetal life the vascular resistance to flow in the lungs is high and the pulmonary circulation is minimal. The pressure in the right

* Veterinary Hospital, Faculty of Veterinary Medicine, Hokkaido University, Sapporo 060, Japan

ventricle exceeds that in the left. Moreover, at birth there is a changeover of the pulmonary circulation into a low resistance system after the onset of breathing and an increase in systemic vascular resistance due to the removal of placental circulation, leading to a rise in the left ventricular pressure and a fall in the right. The lumen of the ductus arteriosus gradually begins to narrow in near-term fetuses, and after birth, begins to constrict rapidly, resulting in its obliteration up to a few days after delivery.¹¹⁾ These perinatal functional changes in the circulatory system reflect the following anatomical changes of the neonatal heart: a decrease in the ratio of the right ventricular weight to the total ventricular weight and a more significant increase in the left ventricular wall thickness than in the right in newborn foals.¹⁰⁾ In spite of the postnatal functional and morphological changes in the cardiovascular system, comparatively few data of newborn foals are available.

It is generally accepted that the continuous murmur attributed to flow through the ductus arteriosus from the aorta to the pulmonary artery is heard for a short time after birth. Reportedly this murmur was audible 5~15 minutes after delivery and disappeared by the time the foal was 90 hours old.¹²⁾ LOMBARD et al.⁹⁾ reported that the typical machinery murmur of an open ductus arteriosus was heard in most foals on their first day of life, but disappeared rapidly. The murmur is related to turbulence within the pulmonary trunk due to rapid flow through a constricted ductus arteriosus from the aorta to the pulmonary trunk.³⁾ Under experimental conditions, the murmur became auscultable when the ductus arteriosus was constricted due to decreased blood flow and volume and increased blood velocity, and continued until the constriction reduced the original flow rate to less than 10% of the initial value.³⁾ The ductus arteriosus in newborn foals was considered to close physiologically on the 2nd to 3rd postnatal day by auscultation¹²⁾ and by 16 hours postpartum by angiography.¹³⁾

Thus the physiologic closure time of the ductus arteriosus differs according to the available reports. In this connection, our morphological study revealed that the ductal closure occurred in 3 of 14 foals examined on the 1st day of life, in 2/6 on the 2nd day and in 9/9 on the 3rd day or later, suggesting that the ductus arteriosus closes physiologically within about 3 days after birth.¹¹⁾

Furthermore, a loud systolic murmur was recorded over the left heart base in most newborn foals after the disappearance of the continuous murmur derived from the constricted ductus, and it persisted in a large number of foals over 2 to 3 months of age.⁹⁾ Details of the systolic murmur, however, are not clear.

The purpose of this study was to determine the physiologic closure time of the ductus arteriosus and to confine our previous morphological findings that the ductus arteriosus closes physiologically within about 3 days after birth. We also investigated in detail the origin and cause of the systolic murmur in newborn foals.

MATERIALS AND METHODS

The subjects of this study were 20 newborn thoroughbred foals (8 colts and 12 fillies) from one herd of pregnant mares from a racehorse farm in Hokkaido. All but one foal, which underwent undue prolongation of delivery, were delivered spontaneously following the normal course of parturition, of which the durations were under about 30 minutes. The gestational age at the time of delivery ranged from 319 to 354 days (Mean \pm S. D. : 337.6 ± 8.0 days of gestation). Sixteen newborn foals were considered to be in good condition at birth and they began to breath at once; however, the remaining 4 foals were markedly depressed with irregular cardiac rhythms showing atrial fibrillation (3 cases; DFi, HHa and SMa) and sinus arrhythmia including second degree atrioventricular block (one case; DMo), which were demonstrated by electrocardiography performed immediately after birth.

Examinations of the heart rate, detailed auscultations of the cardiovascular murmurs and recordings of phonocardiograms in all 20 newborn foals were conducted. In addition, fetal electrocardiograms were recorded once between 1 and 7 days before birth in 12 of the 20 foals, and the fetal heart rate prior to delivery was calculated.

Auscultation of the chest by a stethoscope was performed over the area of the ductus arteriosus, which is in the left 3rd or 4th intercostal space at the level of the shoulder, and over the four valve areas. At the same time, the heart rate was counted per minute with the foal in the resting state of standing or in the recumbent position without any restraints.

The occurrence and the presence or absence of a murmur attributed to flow through a constricted ductus were noted. The intensity of cardiovascular murmurs was graded according to the scale of DETWEILER et al.⁶⁾ Sixteen to 25 separate auscultations in each of the foals were done in the first 108 hours of life, and a total of 41 observations was made between 5 to 14 days. The number of observations made in the first 108 hours of life varied with the animal because many foals were put out to pasture during the day and could not be studied at the scheduled times.

Phonocardiograms were obtained from all newborn foals within the first 24 hours and then twice between 3 and 5 days of age in all but 3 foals. Additional recordings were done two to three times in 10 foals ranging in age from 6 to 14 days. During the procedure the foals were in a standing position and remained in a quiescent state. Moreover, examination was made of the effect of changes in the heart rate by injection of isoproterenol (Protanol; 0.8mg), atropine (3.2mg) or propranolol (Inderal; 24mg) on the intensity of the early systolic murmur using two additional thoroughbred foals at 7 days and one month of age.

Three foals, including one of the above-mentioned 20 foals (SMa), underwent cardiac catheterization at the ages of 18 hours, 8 days and one month, respectively, in order to record blood pressures of the left and right ventricles and to confirm the presence or absence of left-to-right shunt through the ductus arteriosus. In angiocar-

diography, the catheter in the left common carotid artery was advanced to the ascending aorta and then into the left ventricle, and a total of 5 radiographs was obtained before, during and after hand injection of 100 ml contrast medium. Fluid-filled catheter-pressure transducer systems were used for pressure measurements.

The anatomical state of the ductus arteriosus was assessed at necropsy in 4 foals including the 3 animals in which angiographic study had been performed, and was related to the recorded murmurs and angiocardiographic findings.

RESULTS

Heart rate

The heart rates described in this chapter are limited to those of 16 newborn foals which had no arrhythmias and were in good condition at birth.

Fetal electrocardiograms recorded in 10 of the 16 normal newborn foals within a week before parturition showed that the fetal heart rate ranged from 61 to 75 beats per min (Mean \pm S. D., 67.8 ± 4.8 , $n=10$) (Fig. 1). Auscultation performed just after birth revealed that the rate dropped to 55.9 ± 6.1 beats per min ($n=16$) (Fig. 1). In 9 of the 10 animals in which fetal electrocardiography was performed, the heart rate soon after birth was apparently slower than in those near term. Thus, a transient bradycardia was noted in the newborns immediately after delivery. After several minutes, rapid and progressive elevation of the heart rate was observed coinciding with the newborns' activity and efforts to stand, and the peak heart rate of 173.6 ± 34.7 beats per min was recorded at the 40th minute of life (Fig. 1). At around this time, many of the foals were able to rise to their feet and stand for the first time, and their heart rates showed a considerable variation. Once standing for the first time had been accomplished, the heart rate tended to decrease significantly. Namely, the rate fell from 150.7 ± 35.6 beats per min at 60 min to 113.3 ± 20.4 at 120 min and to 107.7 ± 21.1 at 180 min. Thereafter, a very gradual decrease was found in the heart rate, reaching 86.6 ± 5.1 beats per min ($n=5$) at the 14th day of life, and it did not vary much among individuals (Fig. 1), after which no further analyses were performed.

Cardiovascular murmurs

Cardiovascular murmurs in normal newborn foals were classified into the following two types according to the results of auscultation and phonocardiography. Type I showed a continuous or transsystolic murmur which possessed a high-pitched quality and extended decrescendo into early diastole, with its peak intensity about late systole (Fig. 2). It was best auscultated over the left 3rd or 4th intercostal space under the triceps muscle at the level of the shoulder and was regarded as the murmur resulting from flow through the constricted ductus arteriosus from the aorta to the pulmonary artery. Type II demonstrated a crescendo-decrescendo systolic murmur which had a soft or rough ejection quality with varying duration from the first half to the end of the systolic period (Fig. 3). The site of maximum intensity of this murmur was in the

aortic valve area. These two types of murmurs were clearly distinguishable from each other on auscultation.

Continuous murmur: In 12 of 16 normal newborn foals, the continuous murmur attributed to flow through the patent ductus (Type I) appeared 10 or 15 minutes after birth and in 3 newborns in the first 25~50 minutes of life, whereas it was absent in one foal (DGi) throughout the examination period (Tab. 1). In 2 cases with atrial fibrillation (DFi) or sinus arrhythmia (DMo), of which durations were within several minutes after delivery, the time at onset of the murmur was 15 and 30 minutes, respectively. However, there was a longer interval of time from birth to the first detection of the murmur (140 and 150 minutes) in 2 foals suffering from atrial fibrillation (HHa and SMa), which persisted for the first 170 to 200 minutes after birth, respectively.

The intensity of this murmur varied between grades I and IV out of V (Tab. 1), with greater intensity occurring during the increased heart rate period. Furthermore, variations in intensity were recognized with respiration, being louder during expiration.

The time at which the continuous murmur disappeared could be determined in 17 foals including 3 cases (DMo, DFi and HHa) with transient arrhythmias which had occurred after birth. In many instances, the murmur of the patent ductus decreased gradually in intensity from about one day prior to the disappearance, but in some foals the intensity remained almost constant. Out of 14 normal foals, the murmur disappeared in one foal at the 18th hour for the first time, and thereafter, in 2 foals up to the 48th hour, in 5 foals up to the 60th hour, in 10 foals up to the 72nd hour, in 13 foals up to the 84th hour and in all 14 foals by the 96th hour of age. In 3 cases with transient arrhythmias, the murmur disappeared from 60 to 84 hours of age (Tab. 1).

Systolic murmur: It was common for the crescendo-decrescendo systolic murmur (Type II) to become audible over the aortic valve area immediately before or after the disappearance of the continuous murmur (Type I). In 2 foals (LSp and RSp), the disappearance of the continuous murmur preceded the onset of the systolic murmur for a few days. In one instance (DGi), no cardiovascular murmur was present until 8 days of age, and thereafter, only the systolic murmur became auscultable abruptly for no apparent reason. The systolic murmur tended to increase in intensity as the heart rate increased. Conversely, the decrease of loudness was noted when the foal was sleeping and was at rest in a recumbent position.

Furthermore, systolic murmurs over the aortic valve area could be heard for some time soon after birth in 5 foals together with a continuous murmur over the area of the ductus arteriosus (Tab. 1). The murmurs were audible from several minutes postpartum following constriction and rupture of the umbilical cord and disappeared by the first 3 hours of life, whereas the systolic murmur persisted throughout the observation period in one case (NTa). This systolic murmur had a tendency to be longer, louder and slightly more abrupt than the short early systolic murmur observed

TABLE 1 Cardiac murmurs auscultated in 20 newborn foals

Age	Normal																Arrhythmia			
	LSp	DGi	RSp	SAg	DDr	DFr	TLe	DMA	CPa	MSe	SCo	PCl	GMa	MBa	NTa	PMo	DMo	DFi	HHa	SMA
5 min	(-)	(-)	(-)	(-)	(-)	(-)	(-)	(-)	(-)	(-)	(-)	(-)	(-)	(-)	(-)	(-)	(-)	(-)	(-)	(-)
10 min	(-)	(-)	(-)	cII	cI*	cII	(-)	(-)	(-)	(-)*	(-)	cII	(-)	cI	cIV*	(-)*	(-)	(-)	(-)	(-)
15 min	(-)	(-)	(-)	cII	cI*	cII	cII	cII	(-)	cII*	cI	cII*	cII	cIII	cIV*	cII*	(-)	cIII	(-)	(-)
20 min	(-)	(-)	(-)	cII	cII*	cII	cIII	cII	(-)	cII*	cI	cIII*	cII	cIII	cIV*	cIII*	(-)	cIII	(-)	(-)
25 min	(-)	(-)	(-)	cII	cII*	cIII	cIII	cII	cI	cII*	cIII	cIII*	cII	cIII	cIII*	cII	(-)	cIII	(-)	(-)
30 min	(-)	(-)	cI	cIII	cII*	cIII	cIII	cIII	cII	cII*	cIII	cIII*	cIII	cIV	cIII*	cII	cI	cIII	(-)	(-)
40 min	(-)	(-)	cII	cII	cII*	cIII	cIV	cIII	cIII	cII*	cIV	cIII	cIII	cIV	cIII*	cII	cIII	cIII	(-)	(-)
50 min	cI	(-)	cII	cII	cII*	cIII	cIV	cIII	cIII	cII*	cIV	cIV	cIII	cIV	cIII*	cII	cIII	cIII	(-)	(-)
60 min	cI	(-)	cII	cIII	cII*	cIII	cIV	cIII	cIII	cIII	cIII	cIV	cIV	cIV	cIII*	cIII	cII	cIII	(-)	(-)
90 min	cI	(-)	cII	cIII	cII*	cII	cIV	cIII	cIII	cII	cIII	cIV	cIII	cIV	cIII*	cIII	cIV	cIII	(-)	(-)
120 min	cI	(-)	cII	cIII	cII*	cIII	cIV	cIII	cIII	cII	cIII	cIII	cIII	cIII	cII*	cIII	cIII	cIII	cII	(-)
180 min	cII	(-)	cII	cII	cII*	cIII	cIV	cIII	cIII	cII	cII	cIII	cIV	cIII	cIII*	cII	cIII	cIII	cII	cI
6 hr	cII	(-)	cII	cIII	cIII	cIII	cIII	cIII	cIII	cII	cII	cIII	cIII	cIII	cIII*	cIII	cIII	cII	cIV	cIII
9 hr	cIII	(-)	cII	cIII	cIII	cIII	cIII	cIII	cIII	cII		cIII				cIII	cII	cII	cIV	cII
12 hr	cII	(-)	cII	cIII	cIII	cIII	cIII	cIII	cII	cII		cIII					cII	cIII	cIII	cII
18 hr	cIII	(-)	(-)	cII	cII	cII	cII	cIII		cII	cII	cII	cIII	cIII	cII*	cIII	cII	cII	cII	cII
24 hr	cIII	(-)	(-)	cIII	cIII	cII	cIII	cIII		cII		cII	cIII	cII	cII*	cIII	cIII	cII	cII	cII
36 hr	cIII	(-)	(-)	cIII	cIII	cIII	cIII	cIII		cIII		cII	cIII	cII	cII*	cII	cIII	cIII	cII	cII
48 hr	cII	(-)	(-)	cIII	cIII	cI	cIII	cIII		cII	cII	cII	cII	sII	cII*	cII	cIII	cIII	cII	cII
60 hr	cI	(-)	(-)	cII	cII	cII	cII	sII		cI	sII	sII	cII	sII	cII*	sII	cIII	cIII	sI	sII
72 hr	(-)	(-)	(-)	cII	sII	cIII	cII			(-)			sII	sIII	cIII*		sIII		sII	sII
84 hr	(-)		(-)	cII	sII	sIII	sII			sI		sII			sIII		sIII	sII		sI
96 hr		(-)	sII	sIII	sII	sII	sII	sII					sII	sII	sIII		sIII			sI
108 hr				sIII	sIII					(-)										
5 days	(-)			sIII	sIII						sII			sIII	sIII		sIII		sI	sI
6 days	sIII	(-)		sIII						sIII	sI								sII	sII
7 days		(-)		sIII						sIII						sII				sII
8 days		(-)								sIII						sIII				
9 days	sIII	sIII													sII		sII			
10 days		sI												sII	sII		sII			
11 days														sII						sII
12 days													sII							sII
13 days										sIII			sIII							sII
14 days										sIII	sI	sII				sII	sII			

c : continuous murmur, s : systolic murmur, I,II,III and IV : intensity of a murmur graded according to the scale of DETWEILER et al.⁶⁾,
 (-) : no murmur, * : systolic murmur also auscultated together with continuous one

after the disappearance of the continuous one, but both systolic murmurs were almost similar in quality to each other on auscultation (Fig. 4).

In the next experiment isoproterenol, atropine or propranolol were administered to 2 additional newborn foals to examine the effect of heart rate changes on the intensity of early systolic murmur. Very rapid and significant increase of the heart rate was achieved by the injection of isoproterenol, reaching more than 250 beats per min (30 seconds later of the injection), and a systolic murmur of greater intensity was produced (Fig. 5). On the other hand, propranolol reduced the heart rate by about 5~15% 4 minutes after the administration. During a plateau phase, the systolic murmur tended to diminish its amplitude and was often undetected (Fig. 6). After the injection of atropine, there was a rise in the heart rate from 80 to 110 beats per min; however, no remarkable changes in the intensity of the murmur were recognized.

These results indicated that generally the murmur attributed to flow through the patent ductus appears 10 to 15 minutes after birth and disappears up to 84 hours of age, and that the crescendo-decrescendo systolic murmur is an ejection flow murmur that is not associated with the patent ductus, suggesting that no interrelationship exists between continuous and systolic murmurs.

Blood pressure, angiocardiology and autopsy

As shown in table 2, there was almost no difference in the blood pressure between both ventricles in an 18-hour-old foal (SMa). Thereafter, the left ventricular pressure rose while the right one gradually fell. Consequently, the pressure difference became larger (Tab. 2). The angiocardiology obtained soon after the start of the injection from an 18-hour-old foal (SMa) with a continuous murmur, in which the contrast medium was distributed into both the descending aorta and the branches of the pulmonary artery, suggested the presence of a left-to-right shunt through the ductus arteriosus (Fig. 7). In an 8-day-old foal which possessed a crescendo-decrescendo systolic murmur, the angiocardiology showed that the contrast medium was present only in the aortic arch immediately after the start of the injection (Fig. 8-a). Moreover the caudal vena cava and the pulmonary artery were visualized at the end of the injection (Fig. 8-b). Similar angiograms were obtained also from a 31-day-old foal. These findings indicate that the foal had functionally closed ductus arteriosus.

TABLE 2 Systolic blood pressure measurements of 3 foals

	18-hour-old	8-day-old	31-day-old
Left ventricle (mmHg)	90~95	98~104	125~132
Right ventricle (mmHg)	89~92	86~ 91	79~ 82

Necropsy was performed in these 3 foals and in one additional foal (RSp) to confirm the angiocardigraphic findings and to examine the relationship between the murmur and the state of the ductus. In the foal (SMa) sacrificed at the 18th hour after birth, the ductal lumen retained a certain degree of patency (less than 4 mm in the internal diameter). The ductus arteriosus in the 8- and 31-day-old foals was completely obliterated. Also, in a 4-day-old foal (RSp), in which the systolic murmur was present just before it was sacrificed, the ductal lumen had disappeared (Fig. 9).

DISCUSSION

Heart rate

It is generally accepted that there is a temporary increase in the heart rate of foals after birth. However, detailed information on the alterations of the heart rate with the passage of time in the newborn stage is limited to a report by ROSSDALE.¹²⁾ In the present study, rapid increase of the heart rate between 5 and 40 minutes after birth was observed together with a slower decrease after that time. This is in agreement with the findings of ROSSDALE,¹²⁾ who stated that the heart rate of foals changes during the period of adaptation to the extra-uterine environment, and its marked increase was noted during the time that the foal was attempting to stand.

Among the results on the heart rate, there was one interesting observation of transient bradycardia just after birth. There have been no previous reports on the heart rate of newborn foals just after delivery, especially on neonatal transient bradycardia, except for the brief description by ROSSDALE.¹²⁾ TOO et al.¹⁵⁾ reported that the fetal heart rate maintained a lower level during the whole course of parturition than that immediately before the beginning of parturition. A similar observation was made by COLLES et al.²⁾ in the first stages of induced parturition. However, in these reports the heart rate was not examined immediately after birth, and thus it remains unclear whether the bradycardia occurs during parturition and continues into the neonatal period or not. Since continuous recording of the fetal heart rate during parturition was not performed in the present study, no conclusive statement can be made on the occurrence of neonatal bradycardia. However, we have collected evidence for the appearance of fetal progressive bradycardia during the whole course of both spontaneous and induced parturitions in 3 thoroughbred mares (unpublished data). It was thus considered that the fetal bradycardia caused during parturition continues until immediately after birth and that the neonatal bradycardia is physiological and probably induced by a compression of the fetal body due to an increase in intra-uterine pressure with labour-pains, a decrease in blood flow to the fetus accompanied with contraction of the uterine wall and a compression of the fetal head⁸⁾ or the thorax in the parturient canal. Also, the bradycardia appears to continue until a rise in systemic vascular resistance accompanied by a constriction of the umbilical vessel takes place. Further investigations are now in progress applying the technique of

fetal electrocardiography and employing a greater number of animals in order to clarify the time of the onset and cause of the fetal and neonatal bradycardia during and after delivery.

Continuous murmur

Our previous morphological observation of the ductus arteriosus in newborn foals showed that the ductal closure occurs within 3 days after birth.¹¹⁾ The purpose of the present study was to confirm this observation by auscultation. Including the conclusion that the continuous murmur attributed to flow through the ductus arteriosus disappears 60 to 84 hours after birth in most foals, it was confirmed from both the morphological and physiological findings that the ductus arteriosus closes physiologically up to the 3rd day, and at the latest to the 4th day postpartum, in normal newborn foals.

In 2 foals affected with atrial fibrillation which persisted for the first 170 and 200 minutes after birth, respectively, the onset of the continuous murmur was obviously delayed as compared with normal foals. In newborn animals a large number of alveoli are still collapsed and not fully expanded and the lungs are themselves not fully aerated.⁴⁾ Under these conditions, it seems possible that a lower cardiac output due to continued atrial fibrillation might induce a hypoxic condition which delays the onset of the murmur arising from the constricted ductus arteriosus. This hypothesis may be supported by obvious evidence of cyanosis and inactivity in the foals.

In the present study, different intensity of the continuous murmur was heard at different times in the same animal. An increase in the intensity during expiration can be accounted for by lower pulmonary vascular resistance during this time and the consequent increase in the velocity of flow through the ductus arteriosus.³⁾ In general, the continuous murmur gradually became louder within 30 minutes. This phenomenon may be attributed to the fact that the intensity of the murmur had increased with the narrowing of the ductal lumen or that the apparent intensity had changed with a rise in the heart rate due to activity.

The continuous murmur was absent in one normal foal during the examination period. The murmur of the constricted ductus was reported to be absent sometimes in sick foals on the first day of life.^{12,13)} However, comprehensive physical examinations of the present foal continuing from birth up to 4 months of age yielded no abnormal findings, although the foal showed a delicate build at birth. Thus, even in normal newborn foals, the continuous murmur may not necessarily be audible through the chest wall.

Systolic murmur

A description of early systolic murmur in newborn foals was given only by LOMBARD et al.,⁹⁾ who stated that systolic murmurs detected over the left heart base were recorded in a large number of newborn pony foals and that they could be generated by turbulence in the left ventricular outflow tract and be considered

innocent flow murmurs.

The origin of the systolic murmur in newborn foals is uncertain, but there was some evidence suggesting that the murmur is related closely to the increased velocity and volume of aortic flow. Firstly, it was clear that the occurrence of the systolic murmur was not related directly to flow through the ductus arteriosus according to the angiocardiographic findings. Secondly, the systolic murmur was confined to the aortic valve area. Thirdly, a much louder systolic murmur was produced readily with the rapid heart rate induced by the injection of isoproterenol. Conversely, the intensity of the murmur diminished markedly and often disappeared when the heart rate was reduced by about 5~15% of the initial value after the injection of propranolol, because the cardiac output in the newborn animal had already increased to the maximum.⁵⁾ Finally, the systolic murmur became audible at around the time of the disappearance of the continuous murmur and after postnatal ligation of the umbilical cord for cutting.

At birth, constriction and obliteration of the umbilical vessels takes place, and as a consequence, increases of the blood volume and the vascular resistance in the systemic circulation cause a rise in the left ventricular pressure, leading to increased velocity of aortic flow.⁵⁾ Similarly, occlusion of the ductus arteriosus give rise to increases in systemic vascular resistance and arterial pressure, which has been confirmed by the results of experiments by DAWES^{4,5)} in which the ductus arteriosus was tied. Thus it is conceivable that the occurrence of the systolic murmur may be related to a rise of systemic vascular resistance accompanied by closure of the ductus arteriosus or the umbilical vessels.

In conclusion, the systolic murmur in newborn foals was considered to be produced by rapid blood flow which exceeds a critical value in aortas of insufficient diameter and to be qualitatively identical to the innocent systolic murmur occurring in normal young horses.⁷⁾

ACKNOWLEDGEMENTS

The authors are grateful to the staffs of the Shadai Farm for their donation of the materials. We also wish to thank the veterinarians of the Shadai Farm, Drs. N. TSUNODA, H. AKITA and M. TAGAMI, for their valuable advice.

REFERENCES

- 1) AMOROSO, E. C., DAWES, G. S. & MOTT, J. C. (1958): Patency of the ductus arteriosus in the newborn calf and foal. *Br. Heart J.*, **20**, 92-96
- 2) COLLES, C. M., PARKES, R. D. & MAY, C. J. (1978): Foetal electrocardiography in the mare. *Equine Vet. J.*, **10**, 32-37
- 3) DAWES, G. S., MOTT, J. C. & WIDDICOMBE, J. G. (1955): The cardiac murmur from the patent ductus arteriosus in newborn lambs. *J. Physiol.*, **128**, 344-360
- 4) DAWES, G. S., MOTT, J. C. & WIDDICOMBE, J. G. (1955): The patency of the ductus

- arteriosus in newborn lambs and its physiological consequences. *J. Physiol.*, **128**, 361–383
- 5) DAWES, G. S. (1961): Changes in the circulation at birth. *Brit. Med. Bull.*, **17**, 148–153
 - 6) DETWEILER, D. K. & PATTERSON, D. F. (1972): The cardiovascular system. *In*: Equine medicine and surgery Ed. CATCOTT, E. J. & SMITHCORS, J. F. 2. ed., Illinois: Am. Vet. Pub.
 - 7) FREGIN, G. F. (1982): The cardiovascular system. *In*: Equine medicine and surgery. Ed. MANSMAN, R. A., McALLISTER, E. S. & PRATT, P. W., 3. ed., California: Am. Vet. Pub.
 - 8) HON, E. H. (1958): The electronic evaluation of the foetal heart rate. *Am. J. Obstet. Gynec.*, **75**, 1215–1230
 - 9) LOMBARD, C. W., EVANS, M., MARTIN, L. & TEHRANI, J. (1984): Blood pressure, electrocardiogram and echocardiogram measurements in the growing pony foal. *Equine Vet. J.*, **16**, 342–347
 - 10) MACHIDA, N., YASUDA, J. & TOO, K. (1987): A morphometric study of fetal and newborn cardiac growth in the horse. *Equine Vet. J.*, (in press)
 - 11) MACHIDA, N., YASUDA, J. & TOO, K. (1987): A morphological study on the obliteration processes of the ductus arteriosus in the horse. *Equine Vet. J.*, (in press)
 - 12) ROSSDALE, P. D. (1967): Clinical studies on the newborn thoroughbred foal. II. Heart rate, auscultation and electrocardiogram. *Br. Vet. J.*, **123**, 521–532
 - 13) ROSSDALE, P. D. (1969): Clinical studies on 4 newborn thoroughbred foals suffering from convulsions with special reference to blood gas chemistry and pulmonary ventilation. *Res. Vet. Sci.*, **10**, 279–291
 - 14) SCOTT, E. A., KNELLER, S. K. & WITHERSPOON, D. M. (1975): Closure of ductus arteriosus determined by cardiac catheterization and angiography in newborn foals. *Am. J. Vet. Res.*, **36**, 1021–1023
 - 15) TOO, K., KANAGAWA, H. & KAWATA, K. (1967): Fetal and maternal electrocardiograms during parturition in a mare. *Jpn. J. Vet. Res.*, **15**, 5–13

EXPLANATION OF FIGURES

- Fig. 1 Changes of heart rate in newborn foals.
- Fig. 2 Continuous murmur recorded over the area of the ductus arteriosus in a 24-hour-old foal. SM : systolic murmur, DM : diastolic murmur, S1 : first heart sound, S2 : second heart sound, LF : low-frequency record, HF : high-frequency record, ECG : A-B lead electrocardiogram.
- Fig. 3 Short early systolic murmur recorded over the aortic area 84 hours after birth.
- Fig. 4 Longer systolic murmur recorded over the aortic area 15 minutes postpartum.
- Fig. 5 Three extracts from a continuous phonocardiogram recorded over the aortic area of a 7-day-old foal during tachycardia following isoproterenol treatment. A much louder systolic murmur was produced at increased heart rate (HR) 4 minutes after the injection (b). Thereafter, the murmur became smaller gradually with reduced heart rate (c). (a) : A phonocardiogram immediately before the injection of isoproterenol.
- Fig. 6 Phonocardiograms recorded over the aortic area of a 30-day-old foal before (a) and after (b) propranolol treatment. Intensity of the systolic murmur diminished markedly following a decrease in heart rate.
- Fig. 7 Angiocardiogram from an 18-hour-old foal with a continuous murmur, showing the contrast medium in the descending aorta and the branches of the pulmonary artery soon after the start of the injection.
- Fig. 8 Angiocardiogram from an 8-day-old foal with a systolic murmur, showing the contrast medium only in the aortic arch and the descending aorta immediately after the start of the injection (a). At the end of the injection, the pulmonary arteries were visualized together with the caudal vena cava (b).
- Fig. 9 Ductus arteriosus in an 18-hour-old foal (left) with a remaining lumen and in 4- and 8-day-old foals (center and right) with occluded lumina.

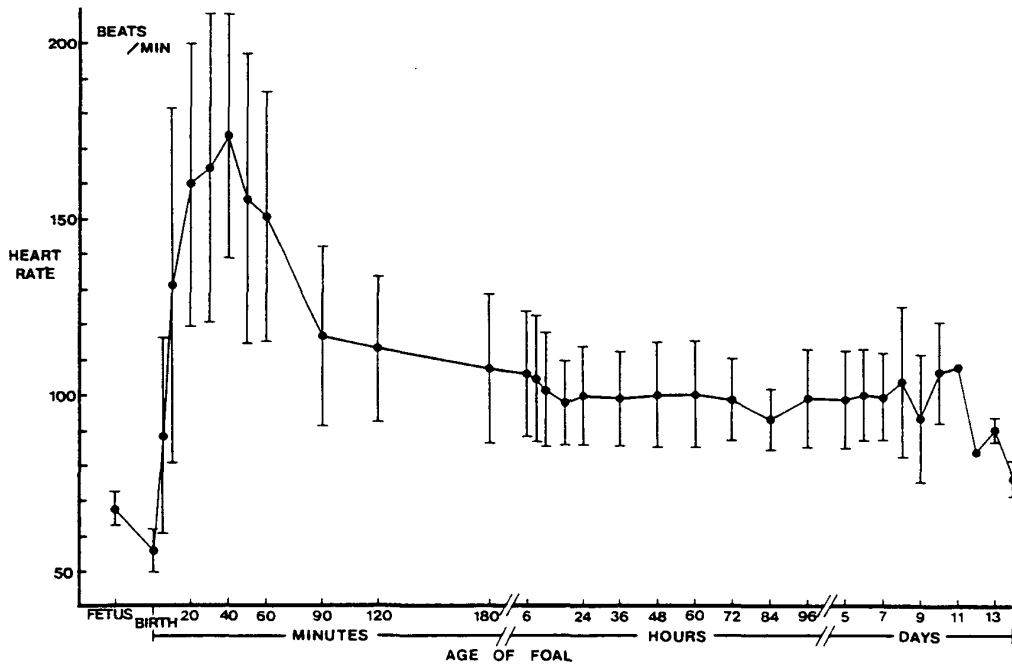


Fig. 1

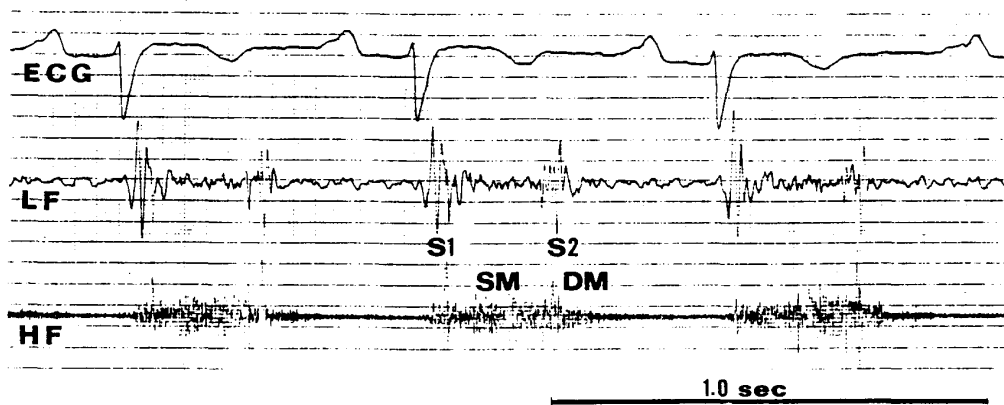


Fig. 2

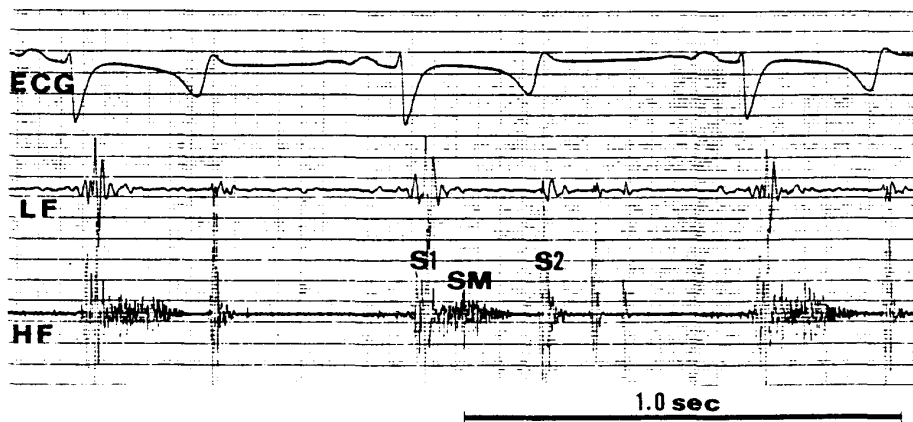


Fig. 3

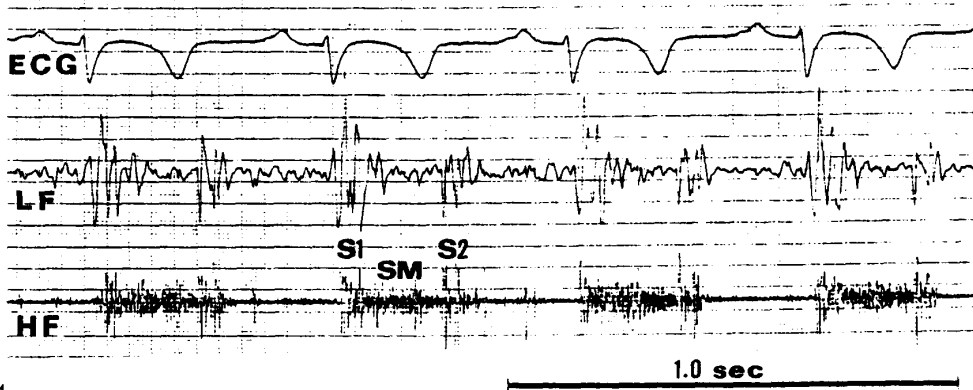


Fig. 4

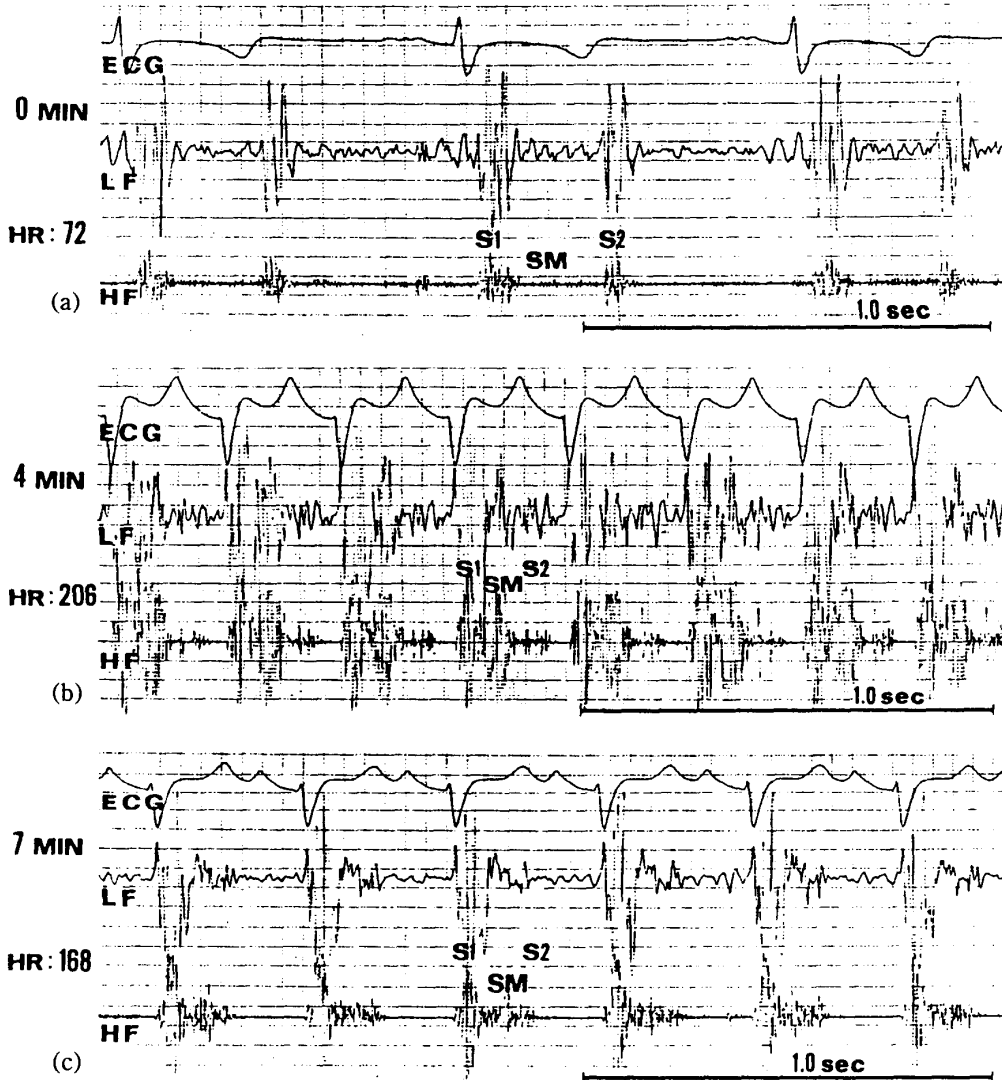


Fig. 5

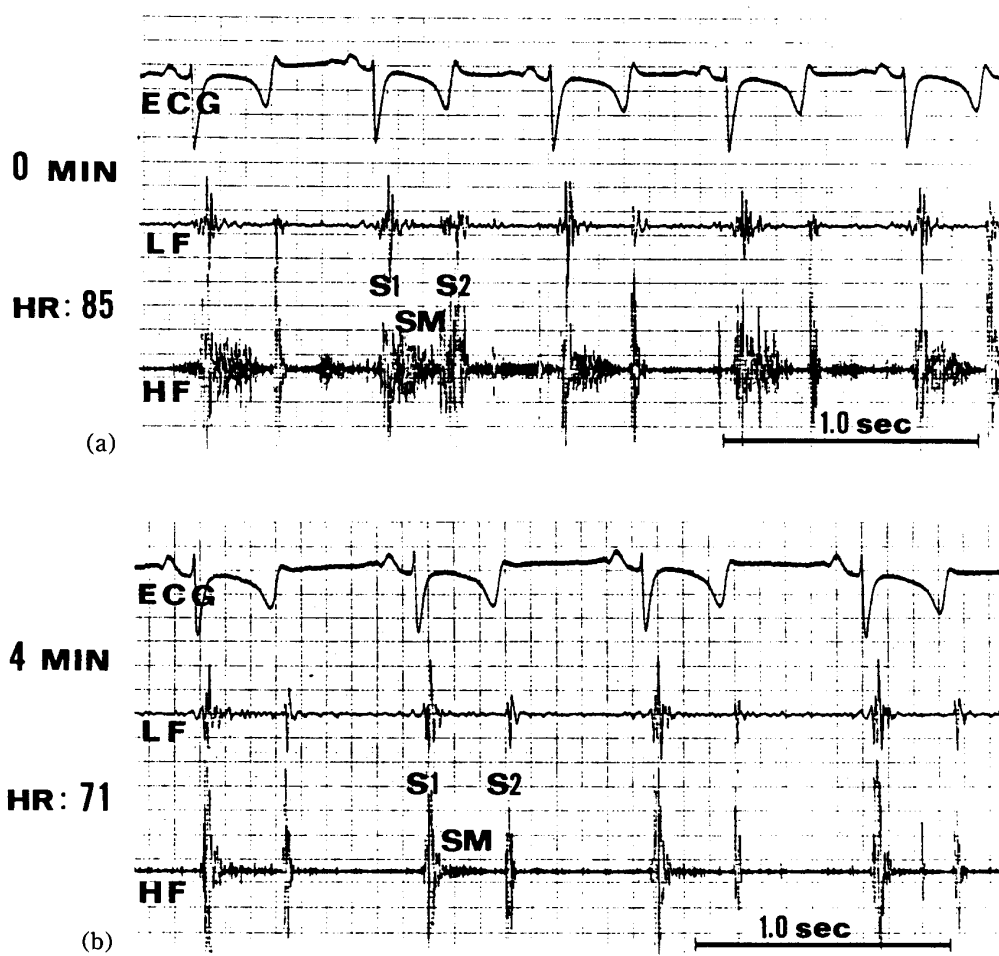


Fig. 6

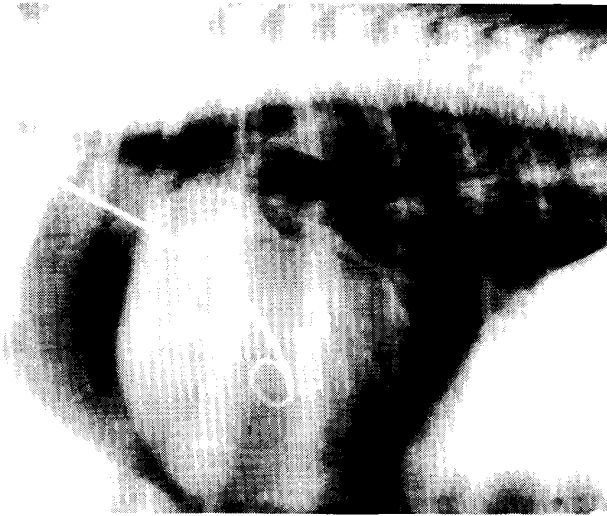


Fig. 7

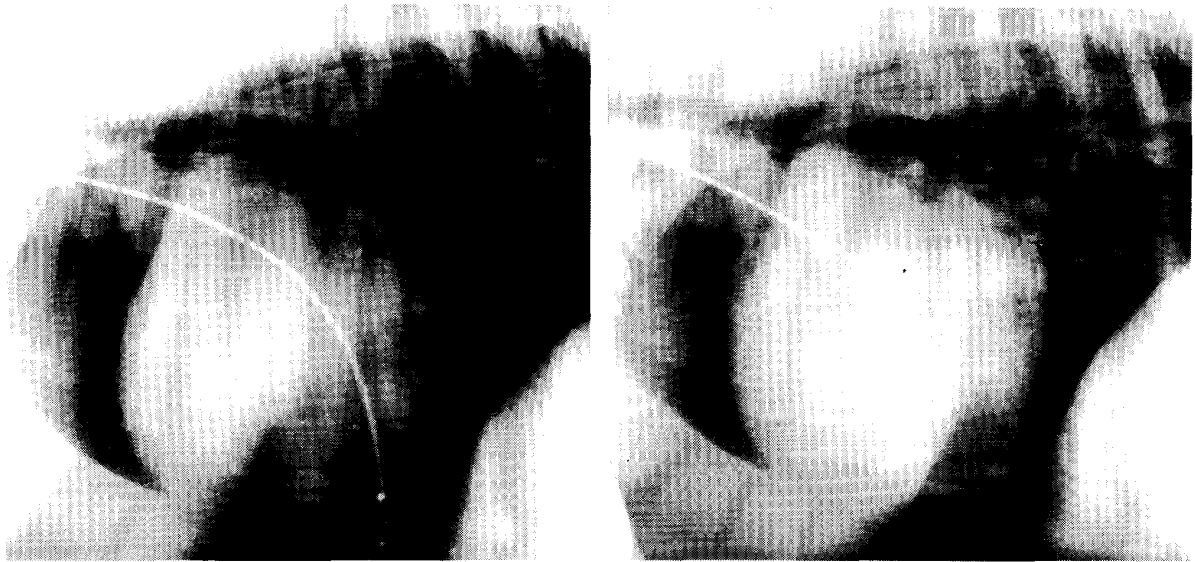

Fig. 8

(a)

(b)




Fig. 9)

10

5