



HOKKAIDO UNIVERSITY

Title	DIFFERENCE OF VIRULENCE IN CAUSING METRITIS IN HORSES BETWEEN HEAVILY ENCAPSULATED, LESS HEAVILY ENCAPSULATED AND NON-CAPSULATED STRAINS OF KLEBSIELLA PNEUMONIAE CAPSULAR TYPE 1
Author(s)	KIKUCHI, Naoya; HIRAMUNE, Takashi; TANIYAMA, Hiroyuki et al.
Citation	Japanese Journal of Veterinary Research, 35(4), 263-273
Issue Date	1987-10-30
DOI	https://doi.org/10.14943/jjvr.35.4.263
Doc URL	https://hdl.handle.net/2115/8932
Type	departmental bulletin paper
File Information	KJ00002376905.pdf



DIFFERENCE OF VIRULENCE IN CAUSING
METRITIS IN HORSES BETWEEN HEAVILY
ENCAPSULATED, LESS HEAVILY ENCAPSULATED
AND NON-CAPSULATED STRAINS OF
KLEBSIELLA PNEUMONIAE CAPSULAR TYPE 1

Naoya KIKUCHI,¹ Takashi HIRAMUNE,¹ Hiroyuki TANIYAMA² and Ryo YANAGAWA³

(Accepted for publication September 17, 1987)

Heavily encapsulated strain of *Klebsiella pneumoniae* (*K. pneumoniae*) capsular type 1 inoculated into the uterus of a mare and filly caused severe and moderate metritis, respectively, while the less heavily encapsulated strain caused only very slight metritis in only 1 of 2 mares and nothing in a filly. Heavily encapsulated strain was recovered from uterine swabs of the mare and filly until the 25th and 21st post-inoculation days (PIDs), respectively, and was recovered at autopsy on the 23rd and 48th PIDs from the uterus and vagina, respectively. Less heavily encapsulated strain was recovered from uterine swabs of only 1 mare until the 8th PID only, but not from the remaining mare and filly, and the recovery of the organisms from the uterus and vagina at autopsy on the 20th and 27th PIDs was negative. Non-capsulated strain did not cause any metritis in a mare and a filly and the organisms were not recovered from uterine swabs from the 2nd PID nor at autopsy on the 20th and 21st PIDs from the uterus and vagina.

Key words: *Klebsiella pneumoniae*, encapsulation, virulence, metritis, horse.

INTRODUCTION

Klebsiella pneumoniae (*K. pneumoniae*) is an important cause of metritis in mares. Predominance of *K. pneumoniae* capsular type 1 as the causal agent of metritis in mares has been reported.^{2,3,4,7)}

In the previous study,⁵⁾ it was shown 1) that less heavily encapsulated strains of *K. pneumoniae* capsular type 1 were isolated from semen of healthy stallions and

¹⁾ Department of Epizootiology, School of Veterinary Medicine, Rakuno Gakuen University, Ebetsu, 069, Japan

²⁾ Department of Veterinary Pathology, School of Veterinary Medicine, Rakuno Gakuen University, Ebetsu, 069, Japan

³⁾ Department of Hygiene and Microbiology, Faculty of Veterinary Medicine, Hokkaido University, Sapporo 060, Japan

cervical swabs of mares suffering from metritis, and 2) that less heavily encapsulated strains were distributed predominantly in semen of healthy stallions while heavily encapsulated strains were distributed predominantly in cervical swabs of mares with metritis. Less heavily encapsulated strains were low or intermediate in virulence for mice and were easily ingested by equine and murine polymorphonuclear leukocytes (PMNL), while heavily encapsulated strains were highly virulent for mice and protected from phagocytosis by the PMNL. The difference of virulence between heavily and less heavily encapsulated strains is considered to have some relation to the following epidemiological findings: 1) that mares bred to stallions carrying less heavily encapsulated strains did not develop metritis, while mares bred to stallions carrying heavily encapsulated strains did⁴⁾; and 2) that less heavily encapsulated strains of *K. pneumoniae* capsular type 1 were isolated from mares suffering from metritis at the rate of only 8.4%.⁵⁾ Virulence of less heavily encapsulated strains of capsular type 1 was thought to be tested in mares.

Experimental uterine infection of mares with *K. pneumoniae* capsular type 1 was reported only once.⁸⁾ A pony mare was inoculated with *K. pneumoniae* capsular type 1 strain (designated as *K. aerogenes* according to an old classification, and encapsulation of the strain was not specified) with the inoculum size of 6×10^8 CFU. The strain was recovered from the cervix of the pony at 48 hrs post inoculation only and from the clitoris/urethra at 24 hrs, 48 hrs and 20 days post inoculation. No sign of external vulval discharge and no real evidence of vaginal and cervical inflammation were shown. Experimental uterine infection of mares with *K. pneumoniae* capsular types 68 and 10 isolated from the genital tract of stallions with a history of breeding problems showed that inoculated mares became infected and remained infected until the post-inoculation estrous cycle was initiated or completed, and that the numbers of *K. pneumoniae* decreased in the uterus of mares after completing the estrous cycle after inoculation.¹⁾

In the present study, experimental uterine infection of mares with heavily encapsulated, less heavily encapsulated and non-capsulated strains of *K. pneumoniae* capsular type 1 was made to determine if there is any relation between bacterial encapsulation and the ability of bacteria to cause metritis in mares.

MATERIALS AND METHODS

Bacteria

F6, heavily encapsulated strain, was isolated from cervical swab of a mare suffering from metritis.⁵⁾ RK26, the less heavily encapsulated strain, was isolated from semen of a healthy stallion.⁵⁾ Strain f6, the non-capsulated strain, was a variant obtained from strain F6.⁵⁾ The Organisms forming smooth colonies of these strains were suspended in 10% skim milk and stored at -80°C until used.

Horses

Seven horses (4 mares and 3 fillies) of thoroughbred breed, 1 to 20 years old, were allotted to 3 groups: group 1 consisted of 2 horses (a mare and a filly) inoculated with the heavily encapsulated strain; group 2 consisted of 3 horses (2 mares and a filly) inoculated with the less heavily encapsulated strain; group 3 consisted of 2 horses (a mare and a filly) inoculated with the non-capsulated variant. Mares inoculated with 5 mg of dinoprost tromethamine (Prostin F2 Alpha, The Upjohn Co., Kalamazoo, Mich.) to induce estrus, but the treatment was successful in only half of the mares, as described below.

Preparation of inoculum

The organisms forming smooth colonies were cultured at 37°C overnight in Trypticase Soy broth (BBL, Cockeysville, U. S. A.). Organisms were harvested and washed twice by centrifugation and resuspended in phosphate-buffered saline solution (pH 7.2) and stored overnight at 4°C. After viable count was determined by plating serial dilutions of the suspension on Trypticase Soy agar (BBL), the organisms were inoculated into the uterus. Viable count of residual bacterial suspension was finally determined.

Method of inoculation

Of the 7 horses, 4 mares were artificially induced into estrus with 5 mg of dinoprost tromethamine. Estrus was determined by rectal palpation of the ovaries. Only 2 (horse Nos. 3 and 5) of the 4 mares exhibited estrus. Three fillies were not treated with the hormone. The external genitalia were cleaned with benzalconium chloride solution. A vaginal speculum was passed into the vagina, after which a sterile swab was picked up with a cervical forceps and inserted carefully through the speculum and cervix into the uterus. After the uterine swab was obtained, mares or fillies were inoculated with 1×10^8 to 6×10^9 CFU of bacteria into the uterus using a sterile insemination catheter fitted a Syringe.

Sampling and cultural method

Uterine swabs for bacteriologic culture were collected on determined post-inoculation days (PIDs) with a sterile cotton-tipped swabs. Contamination of the uterine swabs by the cervix was unavoidable. Swabs were sampled every day in the 1st week and once every several days thereafter. Inoculated horses were sacrificed on the 20th to 48th PIDs. Reproductive organs were removed and opened. Pieces of mucosa for bacterial recovery were removed from the right and left uterine horns, uterine body, cervix and vagina. The swab sample was streaked on Trypticase Soy agar supplemented with 5% horse blood and Deoxycholate-Hydrogen sulfide-Lactose agar (Nissui Pharmaceutical Co. Ltd., Tokyo), and the mucosa specimens and a section of ovaries were stamped on the media, and incubated at 37°C for 24 hrs. The number of colonies isolated was recorded.

Clinical and hematological observation

The inoculated mares were examined daily for signs of metritis (cervicitis,

vaginitis and exudate), and the rectal temperature was taken. Hematological (white blood cell count, differential count of white blood cells) and rectal examinations were performed at the same time as the uterine swabs were sampled.

Pathological examination

Uterine specimens for histology were fixed in 10% neutral buffered formalin. The fixed tissue was embedded in paraffin, sectioned at $5\ \mu\text{m}$ in thickness, and stained with hematoxylin and eosin.

RESULTS

Clinical findings

Horse No. 1 (mare), inoculated in the anestrus with 1.0×10^9 CFU of heavily encapsulated strain F6, discharged yellowish-white colored fluid from the cervix from the 2nd PID for 19 days and exhibited severe hyperemia and edema of the cervical and vaginal mucosae from the 3rd PID for 23 days. No such clinical findings were found thereafter before sacrifice on the 48th PID. Horse No. 2 (filly) inoculated with 1.0×10^8 CFU of the same strain exhibited vaginal exudate from the 3rd PID for 10 days, as well as hyperemia and edema of the cervical and vaginal mucosae from the 3rd PID for 12 days. No clinical findings were found thereafter before sacrifice on the 23rd PID (Table 1, Fig. 1).

Horse No. 3 (mare) inoculated in the estrous stage with 6.1×10^9 CFU of less heavily encapsulated strain RK26 exhibited discharge from the 3rd PID for 5 days, and hyperemia and edema of the cervical and vaginal mucosae from the 2nd PID for 3 days. No such clinical signs were observed thereafter before the day of sacrifice on the 27th PID. Two other horses (No. 4, mare in estrus and No. 5, filly) inoculated with 3.7×10^9 and 1.2×10^9 CFU of the strain, respectively, did not show any clinical signs during the period of 20 and 24 days after inoculation, respectively (Table 1, Fig. 1).

Horse No. 6 (mare in anestrus) and No. 7 (filly) inoculated with 1.3×10^9 and 1.0×10^9 CFU of non-capsulated variant f6, respectively, did not show any clinical signs (Table 1, Fig. 1).

No fibrile response was observed in any of the inoculated horses. No remarkable increase of leukocytes nor nuclear shift to the left of neutrophils was found in any of the horses.

Recovery of *K. pneumoniae* from uterine swabs

Recovery of *K. pneumoniae* from uterine swabs of the inoculated horses was shown in Table 1 and Fig. 1. Horse No. 1 inoculated with heavily encapsulated strain discharged numerous organisms from the 1st to the 25th PIDs. No recovery of the organisms was found on the 30th, 37th and 44th PIDs. Horse No. 2 inoculated with the same strain discharged the organisms from the 2nd to 21st PIDs, with varying numbers of organisms.

TABLE 1 Clinical findings and recovery of *K. pneumoniae* organisms from horses inoculated with 3 differently encapsulated strains of *K. pneumoniae* capsular type 1

Horses							Clinical findings				Recovery of <i>K. pneumoniae</i> organisms ^a					
							Exudate		Cervicitis		Duration of bacterial isolation from uterine swabs (PID)	At autopsy				
No.	Age (years)	Estrous cycle	Termination (PID)	Inoculum Strain	Capsulation	Size (CFU)	Day of appearance after inoculation	Duration (days)	Day of appearance after inoculation	Duration (days)		Vagina	Cervix	Uterine body	Uterine horn	Ovaries
1	14	Anestrus	48	F6	Heavy	1.0×10^9	2nd	19	3rd	23	1st - 25th	++++	++++	++++	++++	-
2	1		23	F6	Heavy	1.0×10^8	3rd	10	2nd	12	2nd - 21st	-	+	+	+	-
3	20	Estrus	27	RK26	Less heavy	6.1×10^9	3rd	5	2nd	3	1st - 8th	-	-	-	-	-
4	8	Estrus	20	RK26	Less heavy	3.7×10^9	-	-	-	-	-	-	-	-	-	-
5	1		24	RK26	Less heavy	1.2×10^9	-	-	-	-	-	-	-	-	-	-
6	9	Anestrus	21	f6	Non	1.3×10^9	-	-	-	-	-	-	-	-	-	-
7	1		20	f6	Non	1.0×10^9	-	-	-	-	1st	-	-	-	-	-

^a Colonies per plate grown from stamped specimens of pieces of mucosa from the vagina, cervix, uterine body and uterine horn, and from pieces from the ovaries were shown. + + + +, more than 400 colonies; +, 1 to 10 colonies; -, no growth.

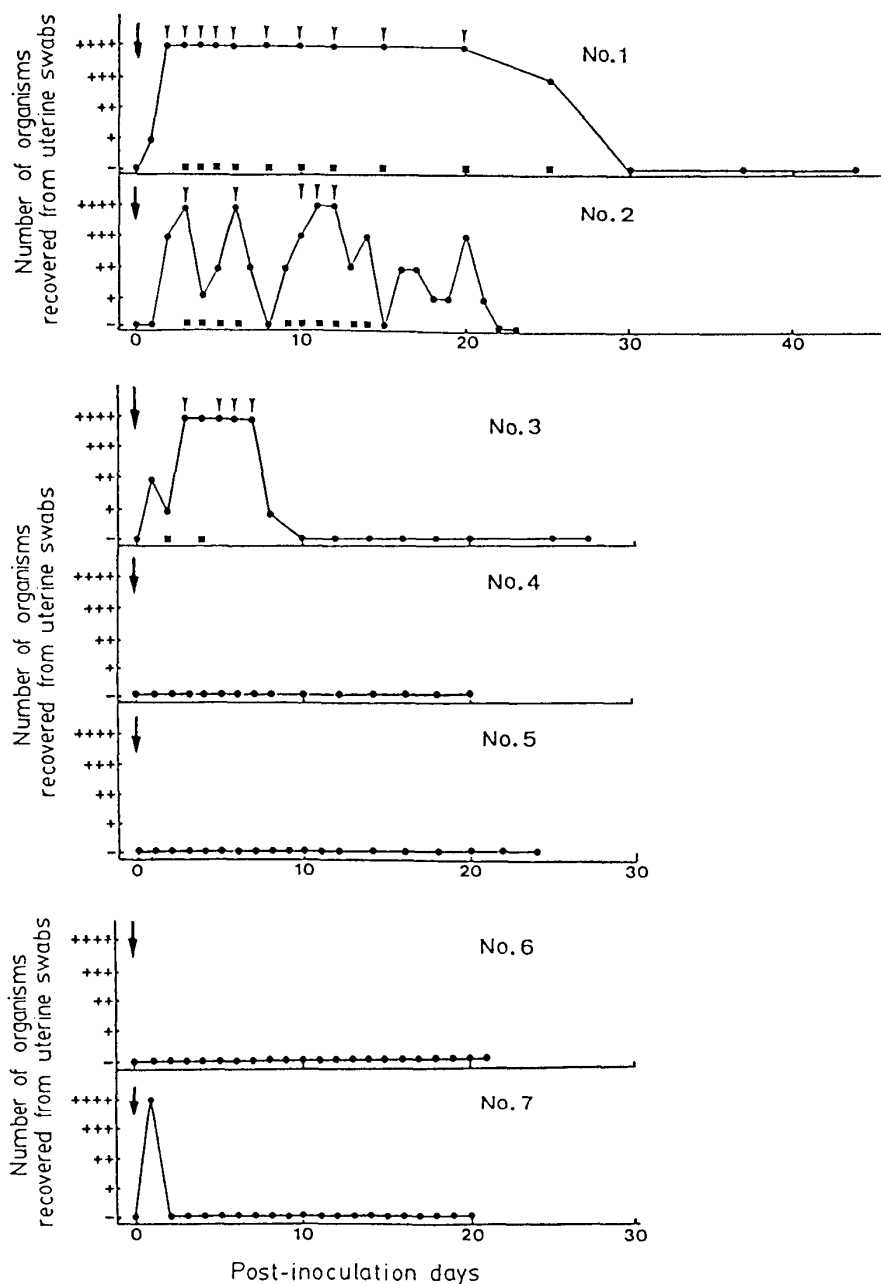


Fig. 1. Recovery of the organisms from uterine swabs and clinical signs of horses inoculated with heavily encapsulated strain F6 (Nos. 1 and 2), less heavily encapsulated strain RK26 (Nos. 3, 4 and 5) and non-capsulated strain f6 (Nos. 6 and 7) of *K. pneumoniae* capsular type 1. + + + +, more than 400 colonies per plate were grown from streaked swabs; + + +, 101-400 colonies per plate were grown from streaked swabs; + +, 11-100 colonies per plate were grown from streaked swabs; +, 1-10 colonies per plate were grown from streaked swabs; -, no growth; ↓, inoculation of organisms into the uterus; ▼, vaginal discharge; ■, cervicitis.

Horse No. 3 inoculated with the less heavily encapsulated strain discharged the organisms from the 1st to 8th PIDs, with numerous organisms from the 3rd to 7th PIDs. No recovery of the organisms was found thereafter before the day of sacrifice on the 27th PID. Two other horses (Nos. 4 and 5) did not show any bacterial discharge (Table 1, Fig. 1).

Horse No. 6 and No. 7 inoculated with non-capsulated variant f6, did not discharge the organisms during the period of 21 and 20 PIDs, respectively. The single exception was discharge of the organisms at only one day after inoculation in horse No. 7 (Table 1, Fig. 1).

Recovery of *K. pneumoniae* from uterine and vaginal tissue at autopsy

Recovery of heavily encapsulated strain from uterine and vaginal tissue at autopsy was shown in Table 1. Organisms were recovered in large numbers from the vagina, cervix, uterine body and uterine horns of horse No. 1, and in smaller numbers from the same tissue of No. 2 (Table 1).

Less heavily encapsulated organisms and non-capsulated organisms were never recovered from the vagina, cervix, uterine body, uterine horns and ovaries of the inoculated mares (Nos. 3–5 and Nos. 6–7, respectively) (Table 1).

Pathological findings

Results of pathological observation were shown in Table 2. Edema, vesicle and hyperemia of endometrium were observed macroscopically in horse No. 1 (mare) inoculated with heavily encapsulated strain. Edema and hyperemia in lamina propria, proliferation, basal vacuolation and degeneration or necrosis of luminal epithelium, and mononuclear cell, neutrophilic leukocytes and eosinophilic leukocytes infiltration in lamina propria were observed in the mare. No particular pathological change was observed in horse No. 2 (filly).

The almost same pathological changes were observed in horse No. 3 (mare) inoculated with less heavily encapsulated strain. The degree of pathological change of the mare was milder than that of horse No. 1. Mild infiltration of mononuclear cells and neutrophilic leukocytes in lamina propria was observed in horse No. 4 (mare). No particular pathological change was observed in horse No. 5 (filly).

No particular pathological change was observed in horse Nos. 6 (mare) and 7 (filly) inoculated with non-capsulated strain.

Colonial morphology and encapsulation of organisms recovered from cervical swabs and reproductive tissues

Organisms recovered from samples of the mares and fillies inoculated with heavily encapsulated, less heavily encapsulated and non-capsulated strains were similar to each of the inoculated strains in colonial morphology and encapsulation (light microscopic examination after negative staining with Indian ink). Transverse diameter of the capsule of recovered bacteria of the less heavily encapsulated strain ranged from 1.2 to 1.3 μm , the same as the inoculated one.

TABLE 2 Pathological findings of uterus of horses inoculated with 3 differently encapsulated strains of *K. pneumoniae* capsular type 1

Horses No.	Macroscopic findings ^a					Histological findings ^a								
	Edema	Vesicle	Incras- sation	Hyper- emia	Pus	Edema	Hyper- emia	Prolif- eration of lumin- al epi- thelium	Basal vacuola- tion of luminal epithelium	Degenera- tion or necrosis of luminal epithelium	Mononu- clear cell infil- tration	Neutro- philic leukocyte infil- tration	Eosino- philic leukocyte infil- tration	
1	++	+	+	++	-	+++	++	++	++	+	+++	++	+++	
2	-	+	-	-	-	-	-	-	-	-	-	-	-	
3	+	+	-	+	-	++	+	+	+	+	++	+	++	
4	-	-	-	-	-	-	-	-	-	-	+	+	-	
5	-	-	-	-	-	-	-	-	-	-	-	-	-	
6	-	-	+	-	-	-	-	-	-	-	-	-	-	
7	-	-	-	-	-	* ^b	*	*	*	*	*	*	*	

^a +, mild to +++, severe.^b Not done.

DISCUSSION

The results obtained indicate that there is a difference in the ability to cause metritis in horses among the heavily encapsulated, less heavily encapsulated and non-capsulated strains of *K. pneumoniae* capsular type 1.

It was shown in the previous study that heavily encapsulated strains were highly virulent for mice and were protected from phagocytosis by equine and murine PMNL, while less heavily encapsulated strains (semen-origin) and non-capsulated variants were low in virulence for mice and were easily ingested by the PMNL. The difference of virulence among 3 differently encapsulated strains in mice and *in vitro* was reflected in the present study in the difference in ability to cause metritis in mares.

In the previous study, it was epidemiologically shown that mares bred to stallions carrying the less heavily encapsulated strain did not develop metritis while mares bred to stallions carrying the heavily encapsulated strain did.⁴⁾ In the present study, the less heavily encapsulated strain isolated from semen caused only very slight metritis in only 1 of 3 mares. The epidemiological findings previously reported were thus confirmed experimentally by the results of the present study.

Experimental uterine infection of a pony mare in winter anestrus with *K. pneumoniae* capsular type 1 was reported.⁸⁾ No sign of external vulval discharge and no real evidence of vaginal and cervical inflammation were shown, and the strain was recovered from the cervix of the pony at 48 hrs post-inoculation only. Encapsulation of the strain inoculated into the pony was not clear. In the present study, a mare in anestrus and a filly, both inoculated with heavily encapsulated strain, exhibited metritis. Experimental production of metritis with *K. pneumoniae* capsular type 1 in a mare in anestrus was thus shown. Of the 3 horses inoculated with the less heavily encapsulated strain, 2 mares were in estrus and were aged 20 years and 8 years. Of the 2, only 1 (20 years old) exhibited very slight metritis. The 8-year-old one, inoculated with organisms that were 6 times smaller than those inoculated into the 20-year-old mare, did not show any signs of metritis. It is not clear whether the difference between the two was only due to the size of inoculum. It seems, however, that the less heavily encapsulated strain is less able to cause metritis in mares.

The mares used in the present study were not sufficient in number or uniform in conditions such as age and estrous cycle. It was supposed that during estrus, the uterus provides optimal conditions for growth of contagious equine metritis bacteria.^{10,11)} Generally speaking, however, clearance of bacteria is accelerated in the uterus of horses in the estrous stage due to a large number of leukocytes accumulated in the mucosa of the uterus and in the uterine cavity, which resulted in increased phagocytosis.⁹⁾ Uterine IgG concentration in normal mares was higher in anestrus than in estrus.⁶⁾ In the present study, the heavily encapsulated strain of *K. pneumoniae* capsular type 1 caused severe and moderate metritis in a mare in anestrus and a filly, respectively, while the less heavily encapsulated strain produced slight metritis in

only a mare of 2 mares and nothing in a filly. And non-capsulated variant did not cause any metritis in a mare in anestrus or a filly. Although the number of horses was not sufficient and the conditions of the horses were not ideal, correlation between capability to cause metritis and encapsulation of *K. pneumoniae* capsular type 1 strains was demonstrated.

Pathological findings of uterus of the horses were paralleled in the present study with clinical findings of the horses. Only exception was a filly inoculated with heavily encapsulated strain which showed the signs of metritis for the first 12 days and bacterial recovery for 20 days, but did not show pathological change at autopsy on 23rd day. Pathological change might be revealed in the uterus of the filly if the filly was sacrificed during the time of clinical metritis.

Colonial morphology and encapsulation of the organisms recovered from samples from the mare inoculated with the less heavily encapsulated strain were similar to those of the inoculated strain, which was semen origin. The results indicated that the diameter of capsule and colonial morphology of the recovered organisms were similar to those of semen-type organisms⁵⁾ (capsules were 1.3-1.5 μ m in transverse diameter, colonies were less mucoid and opaque) and not cervical swab-type organisms⁵⁾ (capsules were 1.7-2.2 μ m in transverse diameter, colonies were mucoid and between opaque and translucent in density). The presumption⁵⁾ that less heavily encapsulated organisms of semen-type might be changed to less heavily encapsulated organisms of cervical swab-type by increasing slightly the thickness of the capsule and changing the colonial morphology in the uterine cavity was thus negated in the present study.

REFERENCES

- 1) BROWN, J. E., CORSTVET, R. E. & STRATTON, L. G. (1979): A study of *Klebsiella pneumoniae* infection in the uterus of the mare. *Am. J. Vet. Res.*, **40**, 1523-1530
- 2) EGUCHI, M., YOKOMIZO, Y. & KUNYASU, C. (1987): Biochemical characteristics of *Klebsiella pneumoniae* derived from horses. *Jpn. J. Vet. Sci.*, **49**, 279-283
- 3) KAMADA, M., ODA, T., WADA, R., FUKUNAGA, Y. & KUMANOMIDO, T. (1984): Isolation of *Klebsiella pneumoniae*, capsule type 1, from mares with metritis and infertility in Japan. *Bull. Equine Res. Inst.*, **21**, 95-99
- 4) KIKUCHI, N., IGUCHI, I. & HIRAMUNE, T. (1987): Capsule types of *Klebsiella pneumoniae* isolated from the genital tract of mares with metritis, extra-genital sites of healthy mares and the genital tract of stallions. *Vet. Microbiol.* (in press)
- 5) KIKUCHI, N., TAKAYANAGI, N., KOSAKA, Y., HIRAMUNE, T. & YANAGAWA, R. Presence of less heavily encapsulated *Klebsiella pneumoniae* capsular type 1 in semen of healthy stallions and cervical swabs of mares suffering from metritis, and comparison of virulence between heavily and less heavily encapsulated strains. (in press)
- 6) MITCHELL, G., LIU, I. K. M., PERRYMAN, L. E., STABENFELDT, G. H. & HUGHES, J. P. (1982): Preferential production and secretion of immunoglobulins by the equine endometrium—a mucosal immune system. *J. Reprod. Fert. Suppl.*, **32**, 161-168

- 7) PLATT, H., ATHERTON, J. G. & ØRSKOV, J. (1976): *Klebsiella* and *Enterobacter* organisms isolated from horses. *J. Hyg., Camb.*, **77**, 401-408
- 8) RICKETTS, S. W. (1980): Endometrial biopsy studies of mares experimentally infected with *Haemophilus equigenitalis* and *Klebsiella aerogenes* capsule type 1. International symposium on equine venereal disease, Newmarket, September 1979. Newmarket, Suffolk, UK; Animal Health Trust., 27-36
- 9) ROBERTS, S. J. (1971): Veterinary obstetrics and genital disease (theriogenology). Edwards Brothers, Inc. Michigan, USA [Translated in Japanese by USUI, K. & KAWATA K. 1978. Jui sanko-hanshokugaku. pp 421-446. Gakusosha, Tokyo]
- 10) SAHU, S. P., PIERSON, R. E. & DARDIRI, A. H. (1980): Contagious equine metritis: effect of intrauterine inoculation of contagious equine metritis agent in pony mares. *Am. J. Vet. Res.*, **41**, 5-9
- 11) SAHU, S. P. (1981): Contagious equine metritis: effect of vaccination on control of the disease. *Am. J. Vet. Res.*, **42**, 45-48