



# HOKKAIDO UNIVERSITY

Title	BICEPHALIC LARVAL CESTODE OF TAENIIDAE FROM RATS IN MALAYSIA
Author(s)	KAMIYA, Masao; OOI, Hong Kean; OHBAYASHI, Masashi et al.
Citation	Japanese Journal of Veterinary Research, 35(4), 275-282
Issue Date	1987-10-30
DOI	<a href="https://doi.org/10.14943/jjvr.35.4.275">https://doi.org/10.14943/jjvr.35.4.275</a>
Doc URL	<a href="https://hdl.handle.net/2115/8933">https://hdl.handle.net/2115/8933</a>
Type	departmental bulletin paper
File Information	KJ00002376906.pdf



## BICEPHALIC LARVAL CESTODE OF TAENIIDAE FROM RATS IN MALAYSIA<sup>1)</sup>

Masao KAMIYA<sup>2)</sup>, Hong Kean OOI<sup>2,3)</sup>, Masashi OHBAYASHI<sup>2)</sup>  
and Chee Kong OW-YANG<sup>4)</sup>

(Accepted for publication September 27, 1987)

Ten cysticerci were recovered from 3 *Rattus rattus* and 1 *R. argentiventer* collected near Sungai Petani, Kedah, Malaysia, in July 1985 and in August 1986. All the cysticerci possess a pair of taeniid strobilae. The cysticerci were found in the thoracic and peritoneal cavities, in the muscle and also in the subcutaneous tissue. Each scolex has an average of 52 hooks. The size of the large hook is 300–306  $\mu\text{m}$  and the small hook is 200–220  $\mu\text{m}$ . A cysticercus, which was surgically implanted into the peritoneal cavity of a rat, *R. rattus*, collected from the same area and brought back to laboratory, was fed to a cat. However, no cestode was recovered from the cat.

Key words: Bicephalic cysticercus, *Rattus* spp., Malaysia

In 1978, we started a project on the phylogenic and taxonomic studies on parasites in Southeast Asia by collecting small mammals in Thailand (OHBAYASHI, 1984). As a continuation of this project, the trapping of rodents was conducted in West Malaysia in July 1985 and August 1986.

During a routine search for parasites in the captured rodents, we came across a hitherto unknown larval cestode with a pair of taeniid strobilae, in two species of rats. This paper presents a comparative morphological study of the aforementioned larva in relation to those that had already been described. Experimental infection of the cysticercus in a cat was carried out in an attempt to determine its definitive host.

### MATERIALS AND METHODS

Trappings of small mammals were conducted in July 1985 and in August 1986 in the paddy field at Bukit Meriam, which is about 20 km from Sungai Petani, Kedah, West Malaysia (Figs.1&2). Live wire net cage and banana bait were used.

---

<sup>1)</sup> This study was supported by Overseas Scientific Research Grants No. 60041002 (1985) and 61043002 (1986) from the Ministry of Education, Science and Culture, Japan.

<sup>2)</sup> Department of Parasitology, Faculty of Veterinary Medicine, Hokkaido University, Sapporo 060, Japan.

<sup>3)</sup> Hokkaido Veterinary Center, Sapporo 064, Japan.

<sup>4)</sup> Division of Parasitology, Institute for Medical Research, Kuala Lumpur, Malaysia

The host animals were euthanized with an overdose of chloroform and then the various body measurements taken. The host animals were identified by studying their skin coat and skull. The cysticerci collected from the thoracic and peritoneal cavities,



FIGURE 1 The irrigation canal in the paddy field where the infected rats were caught



FIGURE 2 The village adjacent to the paddy field where the infected rats were caught

subcutaneous tissue and the muscle were processed according to the method as described by TAKAO (1986). Briefly, the parasites were fixed in acetic acid-alcohol and some specimens were stained with Semichon's carmine. For a detailed study of the rostellar hooks, the scolex was placed on a slide glass and the rostellum cut off with a razor blade. A drop of lacto-phenol was then dripped onto the cut rostellum and a cover slip placed over so that the rows of hooks could be observed *en face* under the light microscope. The hooks were then measured.

### RESULTS

Ten cysticerci were collected from 3 *Rattus rattus* and 1 *R. argentiventer*. All the cysticerci have a pair of taeniid scoleces. Details of the host, site of parasitism and the number of cysticerci recovered is shown in Table 1.

Two of the cysticerci recovered were surgically implanted into the peritoneal cavity of a *R. rattus* caught in Bukit Meriam. The rat was then brought back alive to Japan and 10 days later, one cysticercus removed. The cysticercus was then fed

TABLE 1 Bicephalic taeniid cysticercus collected in Malaysia

Date	Locality	Host		Site of parasitism (cyst no.)
		Species	sex	
July 1985	Bukit Meriam	<i>Rattus rattus</i>	♂	Thoracic cavity(2), muscle(1)
July 1985	Bukit Meriam	<i>R. rattus</i>	♂	Thoracic cavity(1), peritoneal cavity(1)
August 1986	Bukit Meriam	<i>R. rattus</i>	♂	Subcutaneous tissue of thorax(1)
August 1986	Bukit Meriam	<i>R. argentiventer</i>	♂	Abdominal muscle(1), subcutaneous tissue of neck(1), peritoneal cavity(2)*

\* Implanted into a rat, *R. rattus*, brought back to Japan and one cyst fed to a cat. No cestode was recovered from the cat 40 days after infection.

orally to a cat after confirming that it was still alive. Forty days after the feeding, the cat was necropsied but no cestode was recovered. The rat was also necropsied 3 months after the implantation but no sign of the implanted cysticercus could be seen. The cysticercus might have degenerated and been absorbed.

The larval cestode was enclosed by a translucent cyst and spherical in shape with a diameter of 5–15 mm. After evagination it showed a pair of strobilae of equal

length arising from the blastocyst (Fig. 3). The blastocyst, oval in shape, measured 5–15 mm. The proglottids were broad and short. Each scolex had 4 suckers, a short rostellum and a total of 52 large and small hooks which were arranged into 2 rows where the outer and the inner rows of hooks were orderly intermingled. The




FIGURE 3 Evaginated bicephalic cysticercus  
Grid=1cm

large hook measured 300–306  $\mu$ m (Fig. 4) and the small hook 200–220  $\mu$ m (Fig. 5).

#### DISCUSSION

ABULADZE (1964), VERSTER (1969) and SCHMIDT (1986) had listed the number of species in the genus *Taenia* as 123, 70 and 104, respectively. Among these species, those with cysticercus comparable to the present species in having more than one scolex are *Taenia endothoracicus*, *T. krepkogorski*, *T. parva*, *T. selousi*, *T. polyacantha*, *T. twitchelli* and *T. crassiceps*. Morphological details of the larval form of these species as well as the anomalous *T. taeniaeformis* cysticercus, which were reported to have 2 scoleces, were compared with our specimens (Table 2). The larval *T. taeniaeformis* from *R. norvegicus*, which were described by YAMASHITA (1949) and KUNTZ (1943) as having 2 scoleces, possess the same number and shape of rostellar hooks as the normal single scolex possessing specimens. However, it is thought that the larval *T. taeniaeformis* described by them are aberrant and deformed ones.

The bicephalic cysticercus described in this paper has a greater number of hooks, and both the large and small hooks are shorter than those of *T. taeniaeformis*. Although the general shape of the hooks of our specimen resembles that of *T. endothoracicus*, *T. krepkogorski* and *T. parva* in that the blades are slim, it differs from

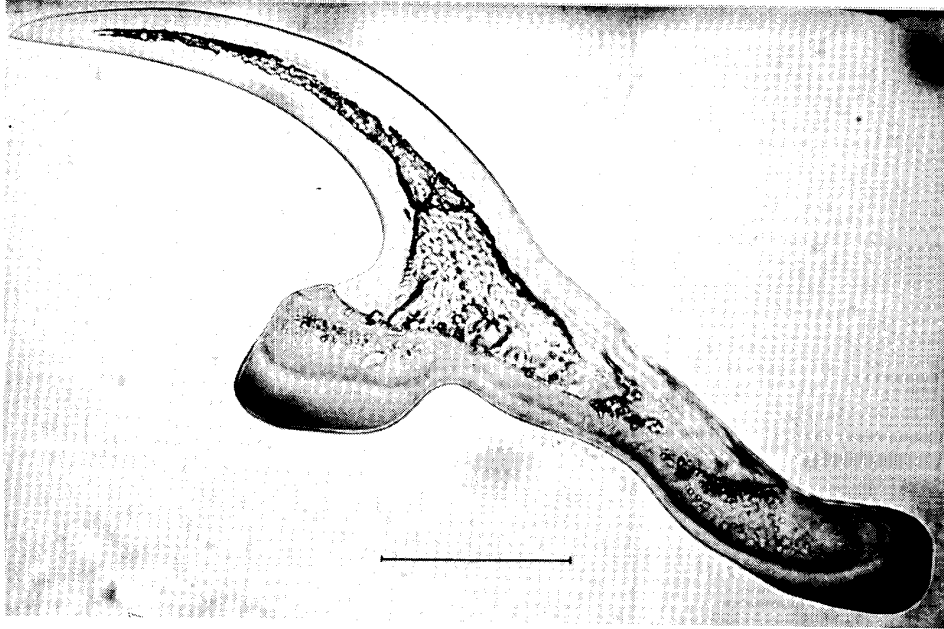


FIGURE 4 A large rostellar hook of the bicephalic cysticercus  
Bar=0.05mm

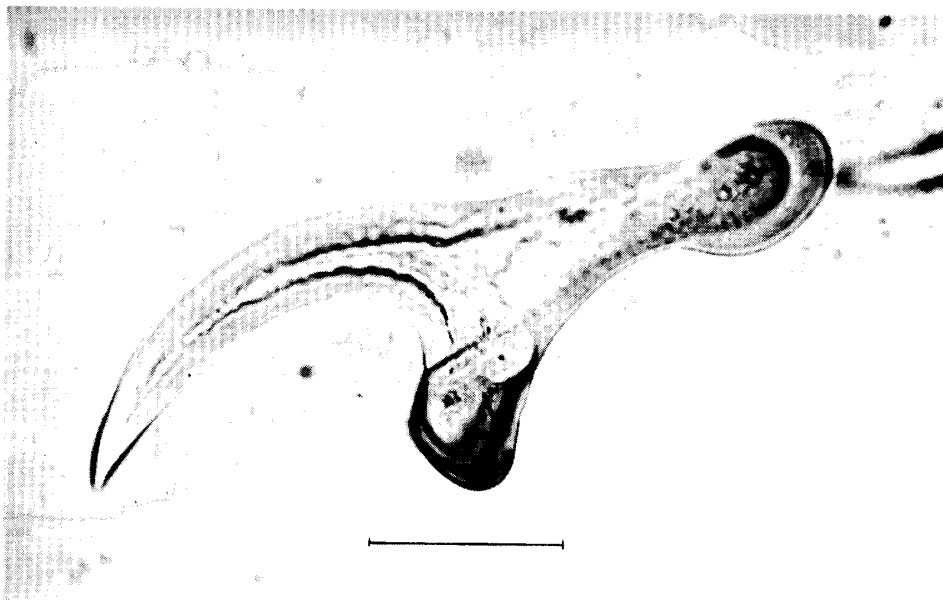


FIGURE 5 A small rostellar hook of the bicephalic cysticercus  
Bar=0.05mm

TABLE 2 Comparison of the bicephalic taeniid cysticercus from Malaysia with other taeniids described by various authors

Species	Author	Locality	Host	Habitat	Hook		Remarks
					Number	Length( $\mu$ )	
<i>Taenia</i> sp.	Present authors	Malaysia	Def: ? Int: <i>Rattus</i> spp.	Thoracic & peritoneal cavities, subcutaneous tissue, muscle	52	L: 300-306 S: 200-220	H*
<i>T. endothoracicus</i>	KIRSCHENBLATT (1948)	North America Asia	Def: <i>Vulpes vulpes</i> Int: <i>Meriones</i> spp.	Thoracic cavity	52-60	L: 351-372 S: 224-241	M
<i>T. krepkogorski</i>	SCHULZ & LANDA (1934)	USSR	Def: <i>Felis</i> spp., <i>V. vulpes</i> Int: <i>Rhombomys opimus</i>		66-72	L: 265-315 S: 182-200	
<i>T. parva</i>	VERSTER (1969)	Africa,	Def: <i>Genetta</i> spp., <i>Felis</i> sp.		40	L: 408-416	H
	VERSTER (1969)	Europe	Int: <i>Rattus</i> spp., <i>Apodemus</i> sp.			S: 256	
<i>T. selousi</i>	LEUCKART (1856)	South Africa	Def: <i>Felis silvestris</i> Int: <i>Rhodomys pumilo</i>		42-46	L: 256-274 S: 175.6 $\pm$ 5.1	
<i>T. polyacantha</i>	LEUCKART(1856)	Northern hemisphere	Def: <i>Vulpes</i> sp., <i>Alopex</i> spp. Int: Rodents		62	L: 196-214 S: 123-133	TT
<i>T. twitchelli</i>	SCHWARTZ(1927)	North America	Def: <i>Gulo gulo</i> Int: <i>Erithizon dorxatum</i>		36	L: 189-198 S: 155-163	M
<i>T. crassiceps</i>	ABULADZE(1964)	Northern hemisphere	Def: <i>Vulpes</i> spp., <i>Alopex</i> spp. Int: Rodents	Thoracic & peritoneal cavities, subcutaneous tissue, muscle	30-36	L: 180-197 S: 130-157	
<i>T. taeniaeformis</i>	ABULADZE(1964)	Worldwide	Def: Cat Int: Rodents	Liver	34-36	L: 460 S: 300	H
<i>T. taeniaeformis</i>	YAMASHITA (1949)	Sapporo	Def: Cat Int: Rodents	Liver	36	L: 396 S: 252	H**

H: *Hydatigena* type M: *Multiceps* type TT: *Tetratirotaenia* type \*: all bicephalic \*\*: teratogenic

Def: definitive host, Int: intermediate host L: large hook, S: small hook

them in that they have a longer guard and a caudal process arising from the haft. The rostellar hooks of *T. endothoracicus* are greater in number, about 52–62, and the large and small hooks are 351–371  $\mu\text{m}$  and 224–241  $\mu\text{m}$ , in size, respectively. Although the size of the large and small hooks of *T. krepkogorski* overlaps with that of our specimen, it has more hooks, numbering 66–72. *T. parva* has larger but less hooks, numbering 40, and the large and small hooks measured 408–416  $\mu\text{m}$  and 256  $\mu\text{m}$ , respectively. Thus, on the basis of the morphological features of the rostellar hooks, the present bicephalic cysticercus does not fit into any hitherto known *Taenia* species. In the near future, we shall use the method as described by Rausch et al. (1984), for comparing the morphology of the rostellar hooks, and also try to make a quantitative study of the angle between the blade and the guard of the hooks.

Despite a lapse of one year in the collection of the host animals from the same area, all our cysticerci have the same characteristic traits including: 2 strobilae arising from a common blastocyst; a non-hepatic site of parasitism, that is, the thoracic and peritoneal cavities, the subcutaneous tissue and the muscle; and the use of the *Rattus* species as the host animal. All these indicate that it may belong to a hitherto unknown new species of *Taenia*. Although we could not obtain the adult worm by experimental infection in the cat, a parasitological survey for the adult worm in the carnivores inhabiting the area where the infected rats were caught, and experimental infection of the cysticercus in canids are warranted.

#### ACKNOWLEDGEMENTS

We thank Dr. H. ABE of Faculty of Agriculture, Hokkaido University for identifying the host animals, Datuk Dr. Teong Wah LIM of Institute for Medical Research, Kuala Lumpur, for his support, Mr. Yeok Ba Ooi, Mr. Yock Huat Ooi of Sungai Petani, Mr. Murad OMAR, Mr. Abu Bakar DIN of Bukit Meriam and other members of our project team for helping to trap the animals, and also Dr. R. L. RAUSCH of University of Washington, Seattle, for the instructive discussion.

#### REFERENCES

- 1) ABULADZE, K. I. (1964): Taeniata of animals and man and diseases caused by them. Izdat. Nauka, Moscow, 1–530 (in Russian)
- 2) KIRSCHENBLATT, Y. D. (1948): New data on larval stages of cestodes in Georgian rodents. *Trudy Zool. Sekt., Tbilisi*, **9**, 268–271 (in Russian) [VERSTER, A. (1969)]
- 3) KUNTZ, R. E. (1943): Cysticercus of *Taenia taeniaeformis* with two strobilae. *J. Parasitol.*, **29**, 424–425
- 4) LEUCKART, K. G. F. R. (1856): Die Blasenwürmer und ihre Entwicklung. Zugleich ein Beitrag zur Kenntnis der cysticercus-Leber. Giessen, 1–162 [VERSTER, A. (1969)]

- 5) OHBAYASHI, M. (1984): Phylogenic and taxonomic studies on parasites in Southeast Asia. I. Report of Overseas Scientific Expedition sponsored by the Ministry of Education, Science and Culture, Japan. 1-166 (in Japanese)
- 6) RAUSCH, R. L., D'ALESSANDRO, A. & OHBAYASHI, M. (1984): The taxonomic status of *Echinococcus cruzi* Brumpt and Joyeux 1924 (Cestoda: Taeniidae) from an agouti (Rodentia: Dasyproctidae) in Brazil. *J. Parasitol.*, **70**, 295-302
- 7) SCHMIDT, G. D. (1986): CRC handbook of tapeworm identification. CRC Press, Boca Raton, Florida, 1-675
- 8) SCHULZ, R. E. & LANDA, D. M. (1934): Parasitic worms of the great gerbil, *Rhombomys opimus* Licht. *Vest. Mikrobiol. Epidemiol. Parazitol.*, **13**, 305-316 [VERSTER, A. (1969)]
- 9) SCHWARTZ, B. (1927): A subcutaneous tumour in primate caused by tapeworm larvae experimentally reared to maturity in dogs. *J. Agric. Res.*, **35**, 471-480 [VERSTER, A. (1969)]
- 10) TAKAO Y. (1986): A new cestode, *Atelemerus major* n. sp. found in a marine fish in Japan (Pseudophyllidea: Echinophallidae). *Jpn. J. Parasitol.*, **35**, 175-182
- 11) VERSTER, A. (1969): A taxonomic revision of the genus *Taenia* Linnaeus, 1758 s. str. *Onderstepoort J. Vet. Res.*, **36**, 3-58
- 12) YAMASHITA, J. (1949): On three cases of abnormalities found in the rat cestode, *Cysticercus fasciolaris*. *Trans. Sapporo Nat. Hist. Soc.*, **18**, 4-7 (in Japanese)