



HOKKAIDO UNIVERSITY

Title	AN IMMUNOHISTOCHEMICAL STUDY OF THE GASTRO-ENTERO-PANCREATIC ENDOCRINE CELLS IN THE ALIMENTARY TRACT OF THE KOREAN TREE SQUIRREL, SCIURUS VULGARIS COREA
Author(s)	LEE, Hyeung-Sik; HASHIMOTO, Yoshiharu; KON, Yasuhiro et al.
Citation	Japanese Journal of Veterinary Research, 39(2-4), 117-131
Issue Date	1991-12-26
DOI	https://doi.org/10.14943/jjvr.39.2-4.117
Doc URL	https://hdl.handle.net/2115/8936
Type	departmental bulletin paper
File Information	KJ00002377520.pdf



AN IMMUNOHISTOCHEMICAL STUDY OF
THE GASTRO-ENTERO-PANCREATIC ENDOCRINE
CELLS IN THE ALIMENTARY TRACT OF
THE KOREAN TREE SQUIRREL,
SCIURUS VULGARIS COREA

Hyeung-Sik LEE¹, Yoshiharu HASHIMOTO, Yasuhiro KON
and Makoto SUGIMURA

(Accepted for publication : Sept. 21, 1991)

The regional distribution and relative frequencies of gastrointestinal endocrine cells were studied immunohistochemically in the gastrointestinal mucosa of Korean tree squirrels. Seven kinds of endocrine cells were identified in this study. Although a large number of 5-hydroxytryptamine-immunoreactive cells were seen throughout the gastrointestinal tract, they were most predominant in the duodenum. A moderate number of glucagon-immunoreactive cells which were restricted to the cardia and fundus of the stomach was also observed. Bovine chromogranin-immunoreactive cells were numerous in the cardia and pylorus of the stomach, found in moderate numbers in the fundus, duodenum and large intestine, but rare in the jejunum. Porcine chromogranin-immunoreactive cells were found in moderate numbers in the stomach but were rare in the duodenum. Gastrin/cholecystokinin-immunoreactive cells were abundant in the pyloric gland region but scarce in the duodenum. Bovine pancreatic polypeptide-immunoreactive cells were observed to be rare and found only in the pyloric gland region. Somatostatin-immunoreactive cells were distributed moderately in the stomach but were few in number in the intestines. No insulin-immunoreactive cells were found in the gastrointestinal tract of Korean tree squirrels. These results suggest that although the Korean tree squirrel is a herbivorous rodent, the distribution pattern of its gastro-entero-endocrine cells is rather similar to that reported for omnivorous animals.

Key words : gastro-entero-pancreatic endocrine cells, gastrointestinal tract, immunoreactive endocrine cell, Korean tree squirrel.

The present study was supported by a grant from the Ministry of Education of Korea in 1990.

- ¹. Department of Biology, Kyungsan University, Kyungsan 712-240, Korea. Department of Veterinary Anatomy, Faculty of Veterinary Medicine, Hokkaido University, Sapporo 060, Japan.

INTRODUCTION

Hormone secreting cells of the gastro-entero-pancreatic system are known to synthesize various peptides that play indispensable roles in the physiology of the gastrointestinal tract.

In the human endocrine system, as many as 18 different endocrine cell types have been identified by electron microscopy and immunohistochemistry²⁵⁾. Although many studies have covered the distribution and frequency of different endocrine cell types in the gastrointestinal tract of various vertebrates, little work has been done on the endocrine cells of Korean tree squirrels using the light and electron microscopes^{5,6,18)}. This species does not hibernate during winter and immunohistochemically the endocrine cells of their gastrointestinal tract have not previously been investigated during this season.

The purpose of the present work was to clarify the fundamental regional distribution and relative frequency of each endocrine cell type in the gastrointestinal tract of the Korean tree squirrel, *Sciurus vulgaris corea*, by specific immunohistochemistry.

MATERIALS AND METHODS

Five adult Korean tree squirrels, *Sciurus vulgaris corea*, of both sexes, captured in winter were used in this study. Samples from 14 portions of the gastrointestinal tract (Fig. 1) were fixed in Bouin's fluid. After dehydration in alcohol series followed by paraffin embedding, 4 μ m histological sections were prepared. The representative sections were then deparaffinized, rehydrated and immunostained with the peroxidase antiperoxidase (PAP) method²⁷⁾. Background blocking was performed with normal goat serum prior to incubation with the specific antiserum (Table 1). After rinsing in PBS buffer, the sections were incubated in secondary serum. They were then washed in PBS buffer and finally the PAP complex was prepared. The peroxidase reaction was carried out in a solution of 3,3'-diaminobenzidine tetrahydrochloride containing 0.01% hydrogen peroxide in Tris HCl buffer. After immunostaining, the sections were lightly counterstained with Mayer's hematoxylin.

The mean numbers of respective immunoreactive endocrine cells per 0.25 mm² were randomly calculated in 10 epithelial areas according to their relative frequency as seen under light microscope.

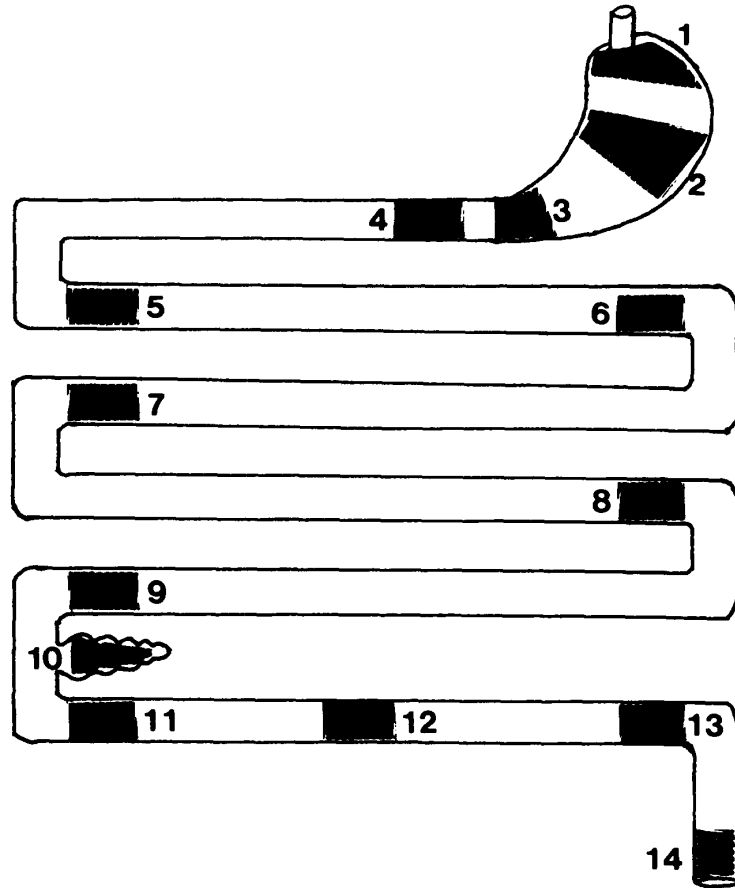


Fig. 1. Sampling portions in the gastrointestinal tract of the Korean tree squirrel. 1. Cardiac gland region 2. Fundic gland region 3. Pyloric gland region 4. Proximal portion of the duodenum 5. Distal portion of the duodenum 6. Proximal portion of the jejunum 7. Distal portion of the jejunum 8. Proximal portion of the ileum 9. Distal portion of the ileum 10. Cecum 11. Proximal portion of the colon 12. Middle portion of the colon 13. Distal portion of the colon 14. Rectum.

Table 1. Antisera used in this study

Antisera*	Code	Source	Dilution
5-hydroxytryptamine (5-HT)	8535028	Immunonuclear Corp., Stillwater	1:10,000
Glucagon	8635013	"	1:800
Insulin	8622014	"	1:2,000
Bovine chromogranin (Bovine CG)	8541011	"	1:500
Porcine chromogranin (Porcine CG)	8541012	"	1:2,000
Gastrin/cholecystokinin (Gas/CCK)	i600/004	Union Chimique Belge, bioproducts	1:100
Bovine pancreatic polypeptide (BPP)	i607	"	1:5,000
Somatostatin	CA325	Cambridge Research Biochemical Billerica	1:1,000

* All antisera were raised in rabbits except for insulin which was raised in a guinea pig.

RESULTS

In the present study, seven kinds of immunoreactive endocrine cells were detected with the antisera against 5-hydroxytryptamine, glucagon, bovine chromogranin, porcine chromogranin, gastrin/cholecystokinin, bovine pancreatic polypeptide and somatostatin. However, no insulin-immunoreactive cells were found in the gastrointestinal tract of the Korean tree squirrels. The regional distribution and relative frequency of the immunoreactive endocrine cells in the gastrointestinal tract are shown in Fig. 2.

The number of endocrine cells was observed to decrease distally from the stomach to the small intestine and large intestine. The immunoreactive endocrine cells in the cardiac and fundic regions were round or pyramidal with no luminal contact. However many of these cells seen in the intestines were oval, pyramidal or elongated spindle and occasionally their apical cytoplasmic processes were in contact with the lumen.

Numerous 5-HT-immunoreactive cells were demonstrated in the epithelia from the cardia of the stomach to the rectum, with almost uniform frequency (Fig. 2). In the cardiac gland region, the distribution of these cells was limited to the basal portion of the epithelium (Fig. 3a), whereas in fundic and pyloric gland regions they were scattered mainly in the lower one third (Figs. 3b,c). In the intestines, the majority of

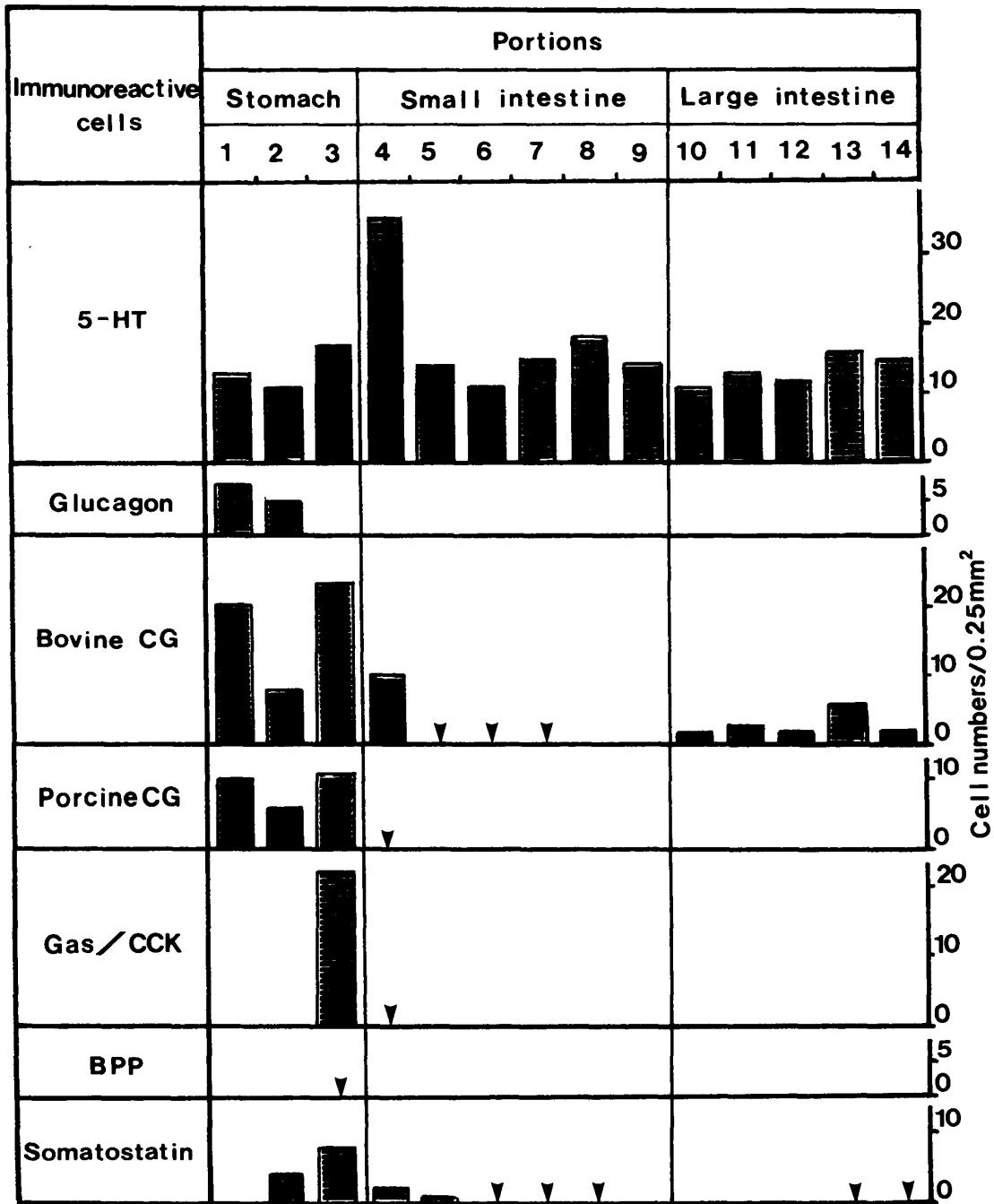


Fig. 2. The regional distributions and relative frequencies of immunoreactive cells in the gastrointestinal tract of the Korean tree squirrel. Arrowheads indicate that immunoreactive cells are rare.

5-HT-immunoreactive cells were distributed in the basal portions of the intestinal glands or intestinal villi (Figs. 3d-g), but were not observed in the duodenal glands (Fig. 3d).

Moderate numbers of glucagon-immunoreactive cells were found to be restricted to the basal portions of the cardiac and fundic glands (Figs. 4a,b).

Bovine CG-immunoreactive cells were distributed in the epithelia throughout the gastrointestinal tract with the exception of the ileum (Fig. 2). In the stomach, they were numerous in the cardiac and pyloric gland regions (Fig. 5a) but moderate in numbers in the fundic gland region. In the intestine, bovine CG-immunoreactive cells were moderate in numbers in the duodenum, rare in the jejunum (Fig. 5b) and few in the large intestine. In addition, these cells were identified mostly in the basal portion of the stomach glands, and in the intestinal glands.

The regional distribution of porcine CG-immunoreactive cells in the stomach showed a similar pattern to that of bovine CG-immunoreactive cells (Fig. 2). While the frequency of the immunoreactive endocrine cells detected in the stomach was moderate (Figs. 6a,b), they were rare in the duodenum being confined to the intestinal glands, and could not be demonstrated from the jejunum to the rectum.

Gas/CCK-immunoreactive cells were dominant only in the pylorus of the stomach, and were rare in the duodenum (Fig. 2). Although mainly limited in the basal portions of the pyloric glands, sometimes they were also found in the epithelia of the pylorus (Fig. 7a) and in the intestinal glands of the duodenum (Fig. 7b).

BPP-immunoreactive cells were rare and restricted to the basal portions of the pyloric glands (Fig. 8).

Somatostatin-immunoreactive cells were demonstrated throughout the gastrointestinal tract except for the cardia of the stomach and the portions from the ileum to the distal colon (Fig. 2). Moderate numbers were found in the fundus and pylorus of the stomach (Fig. 9a), but gradually decreased distally along the intestine. In the stomach, they were detected mainly in the basal portion of glands (Fig. 9a). The immunoreactive endocrine cells were detected occasionally in epithelia of the intestinal villi (Fig. 9b). However, no somatostatin-immunoreactive cells were detected in the duodenal glands (Fig. 9b).

DISCUSSION

Comparing the present results with those reported for other mammalian species, some differences in the regional distribution and relative frequencies of immunoreactive endocrine cells in every part of the gastrointestinal tract were observed. In particular, 5-HT-, Gas/CCK-, BPP- and somatostatin-immunoreactive cells were detected in the duodenal glands of the pig¹⁰⁾ and the Japanese field vole²¹⁾, whereas in the Korean tree squirrel, the duodenal glands were devoid of these immunoreactive endocrine cells.

In the present study, although the duodenal mucosa contains the highest number of 5-HT-immunoreactive cells, these cells were also numerously observed in the mucosa of the other intestinal segments. This result shows that the regional distribution and relative frequency of 5-HT-immunoreactive cells in this species is quite similar to those of the Korean native cattle⁴⁾, pig¹⁰⁾, Holstein Friesian cattle¹³⁾ and the Korean native goat²⁰⁾. However, it is known that these endocrine cells are numerous in the spiral colon of the Japanese field vole²¹⁾ and in the colon of the Korean hedgehog¹⁹⁾. This diversity of cellular locality in the intestines may be due to a certain reflex of gastro-physiological functions related to the nutritional and anatomical differences among the various species.

LARSSON et al.¹⁶⁾ reported that the regional relative number of glucagon-immunoreactive cells in the stomach was greater in the cardia than in the fundus in man, rat and pig, but the highest frequency was found in the ileum of the rat, cat, dog and pig. We demonstrated that glucagon-immunoreactive cells were found exclusively in the stomach, while the intestinal mucosae were devoid of these cells. This pattern of distribution is similar to that of other mammals^{12,14,21)}.

Recently, much attention has been given to the structural significance of CGs. CG A is widely distributed in the endocrine cells of mammals^{3,23)}. This suggests a putative role for CGs as precursors of bioactive peptides. Accordingly, CG-immunoreactive cells have been shown to be present in all identifiable endocrine cell types in the gastrointestinal tract^{8,9,11,15)}. We found that the regional distribution of these cells detected as bovine CG-immunoreactive cells and porcine CG-immunoreactive cells in the stomach showed a similar pattern to that reported earlier. However, the relative number of porcine CG-immunoreactive cells was less frequent than those of bovine CG. In other segments, no porcine CG-immunoreactive cells were found except for rare occurrences in the duodenum. We also observed that bovine CG-immunoreactive cells stained more intensely than that of porcine CG. It is suggested that the bovine CG antiserum used is more sensitive than the porcine CG antiserum. These results may also reflect the difference in the amino acid sequence of the bovine and porcine CG. However, it still remains to be worked out.

Numerous Gas/CCK-immunoreactive cells were demonstrated in the pyloric glands in the present study. Similar finding has been reported for the mouse, guinea pig, rabbit^{17,26)}, Korean native cattle⁴⁾ and the Korean native goat²⁰⁾. In the Japanese field vole²¹⁾, the cells were detected in the cecum and spiral colon distally. However, in other mammalian species, Gas/CCK-immunoreactive cells were commonly restricted to the pyloric gland region and small intestine^{7,26)}.

Our results showed that BPP-immunoreactive cells were rare and restricted to the pyloric glands. The pattern of regional distribution of these cells in the ileum, colon and rectum was quite different from that of other mammals^{2,4,13,20-22,24)}. In the honey possum²⁹⁾, the cells were not detected in the gastrointestinal tract at all,

whereas in the echidna²⁸⁾ they were found on rare occasions in the small intestine. Whether BPP-immunoreactive cells are actually absent from the intestine of Korean tree squirrels or whether it is due to our failure to detect the immunohistological reactivity stemming from species differences at the molecular level, still remains to be clarified.

Somatostatin-immunoreactive cells play important roles in gastric regulation, namely, the feedback control of gastric acid secretion¹²⁾. The double peaked pattern of regional distribution of these cells in some species suggests that there are actually two groups of cells; one which is most numerous in the fundic glands^{1,12,20,21)}, and the other in the pyloric glands^{2,4,10,13,14,22)}. The results for the somatostatin cells in Korean tree squirrels support these findings. In conclusion, we have thus demonstrated the characteristic patterns of distribution of seven kinds of endocrine cells and their relative frequencies in the Korean tree squirrel, *Sciurus vulgaris corea*.

REFERENCES

- 1) ALUMETS, J., SUNDLER, F. & HÅKANSON, R. (1977): Distribution, ontogeny and ultrastructure of somatostatin immunoreactive cells in the pancreas and gut. *Cell Tissue Res.*, **185**, 465–479
- 2) CALINGASAN, N. Y., KITAMURA, N., YAMADA, J., OOMORI, Y. & YAMASHITA, T. (1984): Immunocytochemical study of the gastroenteropancreatic endocrine cells of the sheep. *Acta Anat.*, **118**, 171–180
- 3) CETIN, Y., MÜLLER-KÖPPEL, L., AUNIS, D., BADER, M-F. & GRUBE, D. (1989): Chromogranin A (Cg A) in the gastro-entero-pancreatic (GEP) endocrine system II. Cg A in mammalian entero-endocrine cells. *Histochemistry*, **92**, 265–275
- 4) CHO, S. W. & KITAMURA, N. (1988): Immunocytochemical study of the endocrine cells in the gastrointestinal tract of the Korean native cattle. *Korean J. Vet. Res.*, **28**, 251–259
- 5) CHUNG, I. C. (1976): The endocrine cells in the gastrointestinal tract. *Korean J. Anat.*, **9**, 1–34
- 6) CHUNG, J. W. & KWUN, H. S. (1973): Comparative histological study on the argentaffin and argyrophil cells in the gastrointestinal mucosae of the vertebrates. *J. Catholic Med. College*, **25**, 25–49
- 7) DOCKRAY, G. J. (1978): Gut hormones. 129–139, Edinburgh: Churchill Livingstone
- 8) FACER, P., BISHOP, A. E., LLOYD, R. V., WILSON, B. S., HENNESSY, R. J. & POLAK, J. M. (1985): Chromogranin: a newly recognized marker for endocrine cells of the human gastrointestinal tract. *Gastroenterology*, **89**, 1366–1373
- 9) GRUBE, D., AUNIS, D., BADER, F., CETIN, Y., JORNS, A. & YOSHIE, S. (1986): Chromogranin A (CGA) in the gastro-entero-pancreatic (GEP) endocrine system. I. CGA in the mammalian endocrine pancreas. *Histochemistry*, **85**, 441–452
- 10) ITO, H., YAMADA, J., YAMASHITA, T., HASHIMOTO, Y. & KUDO, N. (1987): An immunohistochemical study on the distribution of endocrine cells in the gastrointestinal tract of the pig. *Jpn. J. Vet. Sci.*, **49**, 105–114

- 11) ITO, H., HASHIMOTO, Y., KITAGAWA, H., KON, Y. & KUDO, N. (1988): Distribution of chromogranin containing cells in the porcine gastroenteropancreatic endocrine cells. *Ibid*, **50**, 395–404
- 12) KITAMURA, N., YAMADA, J., CALINGASAN, N. Y. & YAMASHITA, T. (1984): Immunocytochemical distribution of endocrine cells in the gastrointestinal tract of the horse. *Equine Vet. J.*, **16**, 103–107
- 13) KITAMURA, N., YAMADA, J., CALINGASAN, N. Y. & YAMASHITA, T. (1985): Histologic and immunocytochemical study of endocrine cells in the gastrointestinal tract of the cow and calf. *Am. J. Vet. Res.*, **46**, 1381–1386
- 14) KITAMURA, N., YAMADA, J., YAMASHITA, T. & YANAIHARA, N. (1982): Endocrine cells in the gastrointestinal tract of the cat. *Biomed. Res.*, **3**, 612–622
- 15) KONECKI, D. S., BENEDUM, U. M., GERDES, H. H. & HUTTNER, W. B. (1987): The primary structure of human chromogranin A and pancreastatin. *J. Biol. Chem.*, **262**, 17026–17030
- 16) LARSSON, L. -I., HOLST, J. J., HÅKANSON, R. & SUNDLER, F. (1975): Distribution and properties of glucagon immunoreactivity in the digestive tract of various mammals: an immunohistochemical and immunochemical study. *Histochemistry*, **44**, 281–290
- 17) LARSSON, L-I. & REHFELD, J. (1978): Evolution of CCK-like hormones. In: *Gut hormones*. ed. Bloom S. R., 68–73, Edinburgh: Churchill Livingstone
- 18) LEE, H. S. & LEE, J. H. (1986): Electron microscopic observations of endocrine cells on the squirrel's gastrointestinal tract. *Korean J. Vet. Res.*, **26**, 19–30
- 19) LEE, J. H. (1988): An immunohistochemical and ultrastructure studies on the gut endocrine cells in the hedgehog, *Erinaceus koreans*. *Korean J. Electron Microscopy*, **18**, 59–76
- 20) LEE, J. H. & LEE, H. S. (1990): An immunohistochemical study of the endocrine cells in gastrointestinal tract of the Korean native goat. *Korean J. Vet. Res.*, **30**, 261–270
- 21) OHARA, N., KITAMURA, N., YAMADA, J. & YAMASHITA, T. (1986): Immunohistochemical study of gastroenteropancreatic endocrine cells of the herbivorous Japanese field vole, *Microtus montebelli*. *Res. Vet. Sci.*, **41**, 21–27
- 22) PARK, I. S. (1986): Distribution, histochemical properties and ultrastructures of the endocrine cells in the gastrointestinal tract of the ruminants. *J. Catholic Med. College*, **39**, 1065–1079
- 23) RINIDI, G., BUFFA, R., SESSA, F., TORTORA, O. & SOLCIA, E. (1986): Chromogranin A, B and C immunoreactivities of mammalian endocrine cells. Distribution, distinction form costored hormones/prohormones and relationship with the argyrophil component of secretory granules. *Histochemistry*, **85**, 19–28
- 24) SJÖLUND, K., SANDÉN, C., HÅKANSON, R. & SUNDLER, F. (1983): Endocrine cells in human intestine: an immunocytochemical study. *Gastroenterology*, **85**, 1120–1130
- 25) SOLCIA, E., CREUTZFELT, W., FALKMER, S., FUJITA, T., GREIDER, M. H., GROSSMAN, M. I., GRUBE, D., HÅKANSON, R., LARSSON, L-I., LECHAGO, J., LEWIN, K., POLAK, J. M. & RUBIN, W. (1981): Human gastroenteropancreatic endocrine-paracrine cells: Santa Monica 1980 classification. In: *Cellular basis of chemical messengers in the*

- digestive system, 159–165, eds. Grossman, M. I., Brazier, M. A. B. & Lechargo, J., New York: Academic Press
- 26) SOLCIA, E., VASSALLO, G. & CAPELLA, C. (1969): Studies on the G cells of the pyloric mucosa, the probable site of gastrin secretion. *Gut*, **10**, 379–388
 - 27) STERNBERGER, L. A. (1979): *Immunohistochemistry*, 2nd ed. 104–169, New York: John Wiley & Sons
 - 28) YAMADA, J., MATSUZAKI, H., KITAMURA, N., YAMASHITA, T. & KRAUSE, W. J. (1985): An immunohistochemical survey of endocrine cells and nerves in the proximal duodenum of the echidna, *Tachyglossus aculeatus*. *Z. mikrosk. -anat. Forsch.*, **99**, 209–218
 - 29) YAMADA, J., RICHARDSON, K. C. & WOOLLER, R. D. (1989): An immunohistochemical study of gastrointestinal endocrine cells in a nectarivorous marsupial, the honey possum (*Tarsipes rostratus*). *J. Anat.* **162**, 157–168

Fig. 3. 5-HT-immunoreactive cells throughout the gastrointestinal tract. a. cardiac gland region, b. fundic gland region, c. pyloric gland region, d. proximal portion of the duodenum, e. proximal portion of the jejunum, f. distal portion of the colon, g. rectum. a-c, e-g; $\times 165$, d; $\times 82.5$

Fig. 4. Glucagon-immunoreactive cells (arrowheads) in the cardiac (a) and fundic gland region (b).
a, b; $\times 330$

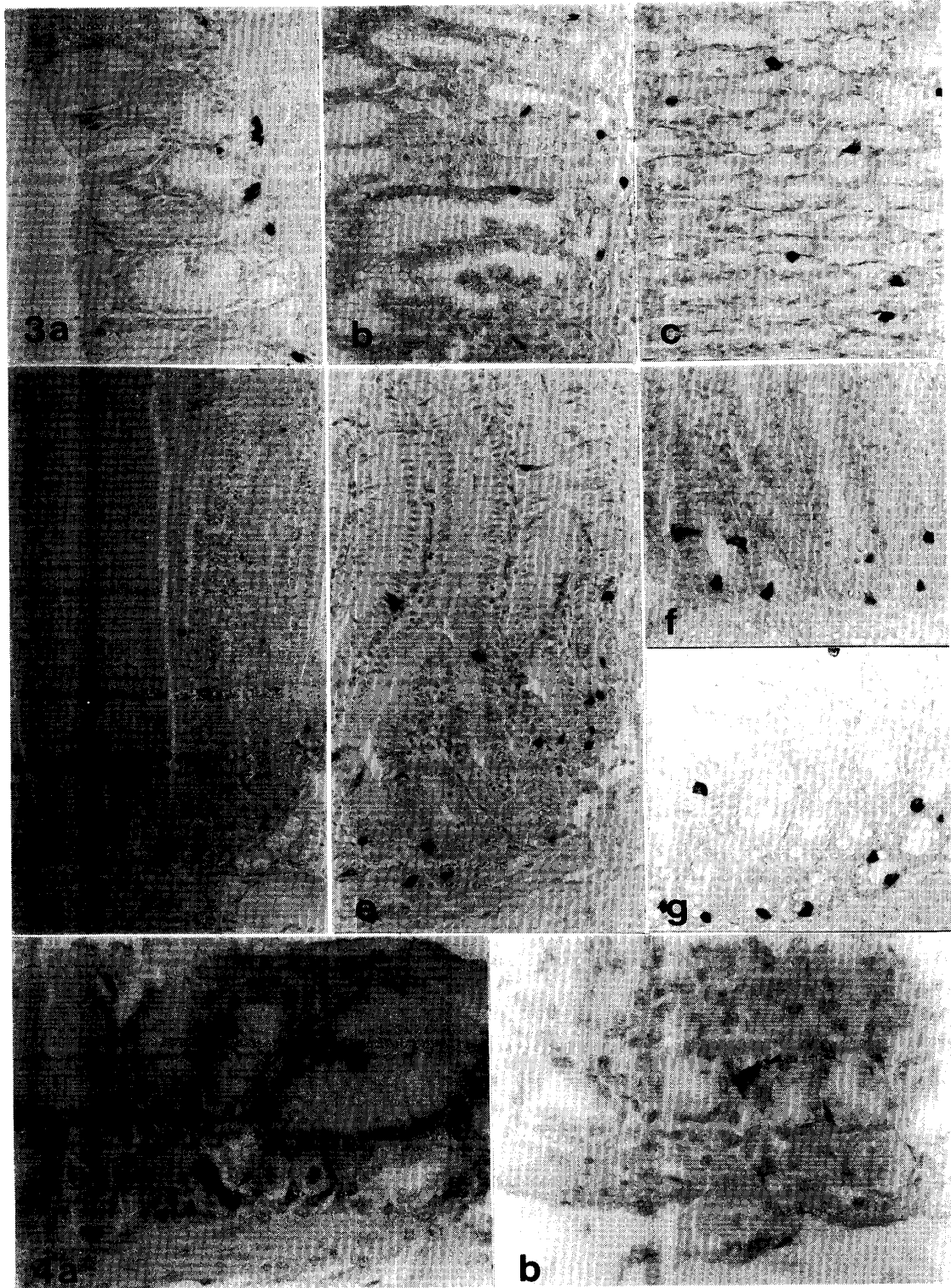


Fig. 5. Bovine CG-immunoreactive cells (arrowheads) in the gastrointestinal tract.

a. pyloric gland region, b. distal portion of the colon.

a, b ; $\times 165$

Fig. 6. Porcine CG-immunoreactive cells (arrowheads) in the stomach and duodenum.

a. cardiac gland region, b. pyloric gland region.

a, b ; $\times 165$

Fig. 7. Gas/CCK-immunoreactive cells in the pyloric gland region (a) and the proximal portion of the duodenum (b).

a, b ; $\times 165$

Fig. 8. BPP-immunoreactive cells (arrowheads) in the pyloric gland region.

$\times 165$

Fig. 9. Somatostatin-immunoreactive cells (arrowheads) in the gastrointestinal tract.

a. pyloric gland region, b. proximal portion of the duodenum.

a, b ; $\times 165$

