



Title	Neutral lipid storage disease with myopathy with a novel homozygous PNPLA2 variant
Author(s)	Yamada, Kazuki; Yaguchi, Hiroaki; Abe, Megumi et al.
Citation	Clinical neurology and neurosurgery, 228, 107670 https://doi.org/10.1016/j.clineuro.2023.107670
Issue Date	2023-05
Doc URL	https://hdl.handle.net/2115/92180
Rights	© 2023. This manuscript version is made available under the CC-BY-NC-ND 4.0 license http://creativecommons.org/licenses/by-nc-nd/4.0/
Rights(URL)	https://creativecommons.org/licenses/by-nc-nd/4.0/
Type	journal article
File Information	Clin Neurol Neurosurg 228 107670.pdf



Title page

Neutral lipid storage disease with myopathy with a novel homozygous *PNPLA2* variant

Kazuki Yamada, MD¹, Hiroaki Yaguchi, MD, PhD¹, Megumi Abe, MD¹, Kaede Ishikawa, MD¹,

Daiki Tanaka, MD¹, Yuki Oshima, MD¹, Akihiko Kudo, MD¹, Hisashi Uwatoko, MD, PhD¹,

Shinichi Shirai, MD, PhD¹, Ikuko Takahashi-Iwata, MD, PhD¹, Masaaki Matsushima, MD,

PhD¹, Ichizo Nishino², Ichiro Yabe, MD, PhD¹

1. Department of Neurology, Faculty of Medicine and Graduate School of Medicine,

Hokkaido University, Sapporo, Japan

2. Department of Neuromuscular Research, National Institute of Neuroscience, National

Center of Neurology and Psychiatry (NCNP), 4-1-1 Ogawa-Higashi, Kodaira, Tokyo

Correspondence to:

Hiroaki Yaguchi and Ichiro Yabe (co-correspondence)

Department of Neurology, Faculty of Medicine and Graduate School of Medicine,

Hokkaido University, N-15 W-7, Kita-ku, Sapporo, Japan

TEL: +81-11-706-6028

FAX: +81-11-700-5356

E-mail:

yaguchi-h@pop.med.hokudai.ac.jp (Hiroaki Yaguchi),

yabe@med.hokudai.ac.jp (Ichiro Yabe)

Conflict of interests: None of the authors have any conflicts of interest associated with this study.

Manuscript word count: 1223 words

Key words: Neutral lipid storage disease with myopathy (NLSDM), *PNPLA2* gene

Highlights:

- We report a case of NLSDM with a novel mutation, c. 40G>A, of the *PNPLA2* gene.
- The clinical manifestations caused by the variant were shown to be relatively mild.
- The patient had a medical history of cancer.

Abstract

We report a case of NLSDM (Neutral lipid storage disease with myopathy) with a novel homozygous mutation c. 40G>A of the *PNPLA2* gene encoding adipose triglyceride lipase (ATGL). The patient was a 47-year-old woman with consanguineous parents. She showed weakness in the right upper limb and had a history of thyroid cancer. A biopsy of the right biceps brachii muscle revealed lipid accumulation in most muscle fibers. We performed target next-generation sequencing and identified a novel variant c. 40G>A in the *PNPLA2* gene. Although the variant may have affected lipase activity which is essential in lipid metabolism, clinical symptoms were mild. This might be because the patient is female and other environmental factors contributed to the mild severity.

Introduction

Neutral lipid storage disease with myopathy (NLSDM) caused by mutations in the *PNPLA2* gene encoding adipose triglyceride lipase (ATGL) is a rare autosomal recessive disorder characterized by abnormal accumulation of triglycerides in several tissues(1). NLSDM occurs in most patients in their 30s, with progressive muscle weakness predominantly in the proximal muscles and then in the distal muscles in advanced stages(2). Although various accompanying conditions such as cardiomyopathy, hepatomegaly, diabetes mellitus, and deafness are observed, cancer has not been reported(3). We report here a case of NLSDM with a novel homozygous mutation c. 40G>A (p.Gly14Ser) of the *PNPLA2* gene with a history of cancer.

Patient

The patient was a 47-year-old woman with consanguineous parents. Her parents did not show muscle weakness. She experienced weakness in the right distal upper limb and had a high level of creatinine kinase (approximately 1000~1500 U/L) at the age of 45 years. She gradually developed weakness in the entire right upper limb and visited our hospital at the age of 47 years. She had a medical history of fatty liver and thyroid cancer at the age of 35 years. Her height was 162.5 cm and her weight was 57.2 kg. Neurological examination showed left ptosis and

weakness of the right upper limb with a reduction of deep tendon reflexes. Muscle strength in the right upper limb (muscle strength graded by manual muscle testing) was as follows: 4 in the deltoid, 3 in the biceps brachii, 4 in the infraspinatus, and 4 in the flexor digitorum profundus. Serum creatine kinase was slightly elevated to 336 U/L (41~153) and the level of triglycerides was 144 mg/dL (30~117). Electromyography was performed on the right deltoid, bilateral biceps brachii, right rectus femoris, and left gastrocnemius muscles. Myogenic alterations (fibrillation potential, decreased motor unit potential amplitude, and early recruitment at full effort) were shown in the right deltoid and biceps brachii. MR images of the extremities showed fatty replacement predominantly involving the right deltoid and biceps brachii muscles, bilateral paraspinal muscle and posterior compartment of the bilateral lower leg (Fig.1). MRI of the neck and a nerve conduction study were not performed. An electrocardiogram and transthoracic echocardiography showed no abnormalities. A biopsy of the right biceps brachii muscle revealed variation in the size of fibers and lipid accumulation in most muscle fibers as shown by hematoxylin & eosin staining and Oil red O staining. Modified Gomori trichrome staining showed rimmed vacuoles (RVs) in some of the muscle fibers (Fig. 2 A, B and C). Vacuoles in the cytoplasm of neutrophils were seen in a peripheral blood smear (Jordan's anomaly) (Fig.2 D).

After obtaining informed consent, we performed target next-generation sequencing for analysis

of 115 genes related to diverse myopathies that have been reported in more than two cases in Japan. A novel variant, c. 40G>A (p.Gly14Ser), was identified in homozygosis in the *PNPLA2* gene exon 2, which was predicted to be probably damaging in Polyphen2 and deleterious in SIFT, and the CADD score was 32. Sanger sequencing was performed to confirm the variant. The allele frequency of the variant was 0.000006571 (1/152174) in The Genome Aggregation Database. Based on the clinical, histopathological, and molecular results, we made a diagnosis of NLSDM.

Discussion

We reported a case of NLSDM in a patient who had a history of cancer with a novel homozygous variant, c. 40G>A (p.Gly14Ser), in the *PNPLA2* gene. The patient was born to first-cousins parents. Her parents did not show muscle weakness.

In this case, a novel variant, c. 40G>A (p.Gly14Ser), was identified in homozygosis in the *PNPLA2* gene exon 2. ATGL encoded by the *PNPLA2* gene is a protein localized in lipid droplets and is involved in triglyceride degradation. Loss of ATGL function results in abnormal lipid metabolism and abnormal accumulation of triglycerides in skeletal muscle, leading to NLSDM(3). The N-terminal region of ATGL (exons 1-5) contains a Patatin-like structural domain that is essential in triglyceride hydrolysis and the C-terminal region (exons 6-10)

contains hydrophobic lipid-binding stretches(2). To date, 60 different *PNPLA2* mutations that were concentrated in exons 4-7 have been identified, with 42% of the mutations being frameshift mutations and 29% being missense mutations(1). Recent studies have shown that a missense mutation that results in an ATGL protein with residual lipolytic activity may be associated with slowly progressive myopathy(2). Moreover, it is thought that mutations affecting the N-terminal region tend to cause severe myopathy with cardiomyopathy, while mutations affecting the C-terminal region tend to cause mild myopathy(2). On the other hand, *PNPLA2* mutational type or functional defects did not show a great impact on phenotype in a multicentric cohort study of 45 cases of NLSDM, and the correlation between severity of clinical symptoms and mutations identified is unresolved(3). In our case, the initial symptom was weakness in the distal muscle of the right upper limb, being consistent with a previous report(3). The reason for the unilateral muscle weakness was thought to be overuse of the muscle. The fact that the patient was right-handed and that she often used a computer at work was assumed to be the cause of the initial symptom. The severity of NLSDM may be influenced by gender, multiple environmental factors such as diet and exercise, and some additional genetic or epigenetic factors. Cardiomyopathy has been reported in almost 20% of female patients versus 55% of male patients, and the difference is thought to be due to the protective role of estrogens on cardiac function(2). In our case, a missense mutation in exon 2 was predicted to be

a deleterious mutation by multiple software for in silico functional analysis and was judged as Likely Pathogenic based on ACMG/AMP guidelines 2015. Although the variant in the Patatin-like structural domain may have affected lipase activity, clinical symptoms were mild without cardiomyopathy. This might be because the patient is female and other environmental factors contributed to the mild severity,

A role of ATGL in cancer has been revealed by recent studies(4). Reprogramming of lipid metabolism in cancer cells results in the accumulation of lipid droplets (LDs) in cancer cells. Furthermore, massive accumulation of LDs in non-adipocytes promotes cancer cell invasion, metastasis, and drug resistance and has been recognized as a marker of cellular carcinogenesis(5). In addition, to adapt to hypoxia, cancer cells change their metabolism from oxidative phosphorylation, the primary energy supply in normal cells, to glycolysis. This also inhibits intracellular fatty acid β -oxidation to reduce oxygen consumption(4). Therefore, ATGL activity and expression in cancer cells are negatively correlated with cancer cell activity(4). The possibility of accidental complications cannot be ruled out since cancer is a common disease, but our patient had a history of thyroid cancer at the relatively young age of 35 years. Although the complication of cancer in NLSDM being caused by a decrease of ATGL function has not been reported and the relevance is unknown, it is necessary to accumulate cases with caution in the future.

Conclusion

In conclusion, to the best of our knowledge, this case is the first reported case of NLSDM with the homozygous variant c. 40G>A (p.Gly14Ser) in the *PNPLA2* gene. The patient had consanguineous parents. NLSDM is a rare disease, and it is important to report novel genetic mutations and clinical features. This case suggests that cancer may be one of the complications of NLSDM. The pathogenicity of this mutation needs to be investigated by molecular biological procedures in the future.

Figure legends

Figure 1: T1-weighted images of the extremities.

A) An MR image showed fatty replacement predominantly involving the right deltoid muscle (arrow).

B) An MR image showed fatty replacement in bilateral biceps muscles and paraspinal muscle (arrow).

C) The right long head of the biceps femoris was slightly affected (arrowhead).

D) The bilateral lateral heads of the gastrocnemius and soleus muscles, the right peroneal muscle, and the left medial head of the gastrocnemius muscle were affected (arrowheads).

Figure 2: Pathological features of the patient.

A) Muscle biopsy of the right biceps brachii showed massive vacuoles of various sizes within myofibers under hematoxylin & eosin staining. An increase in the number of fibers with internal nuclei was shown.

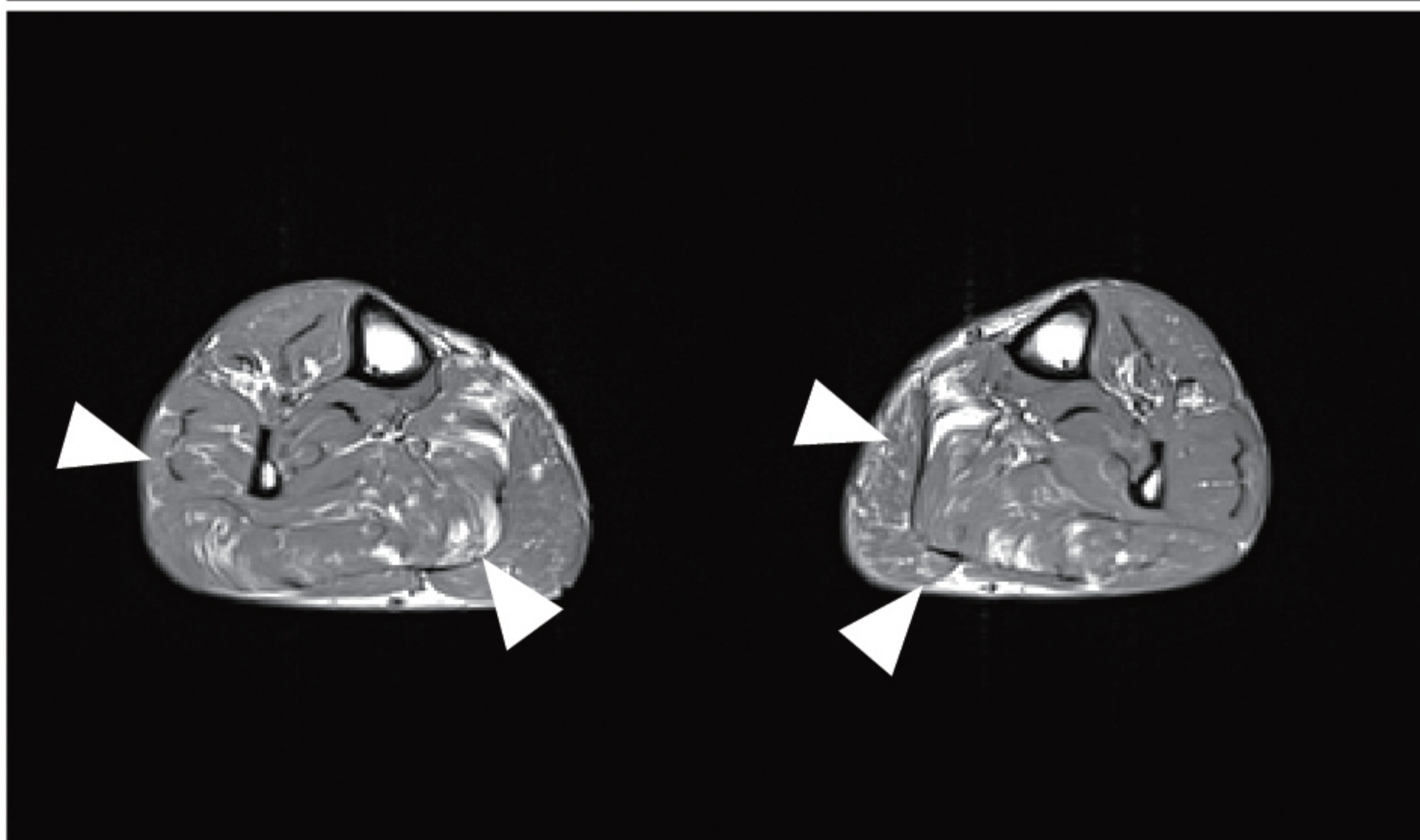
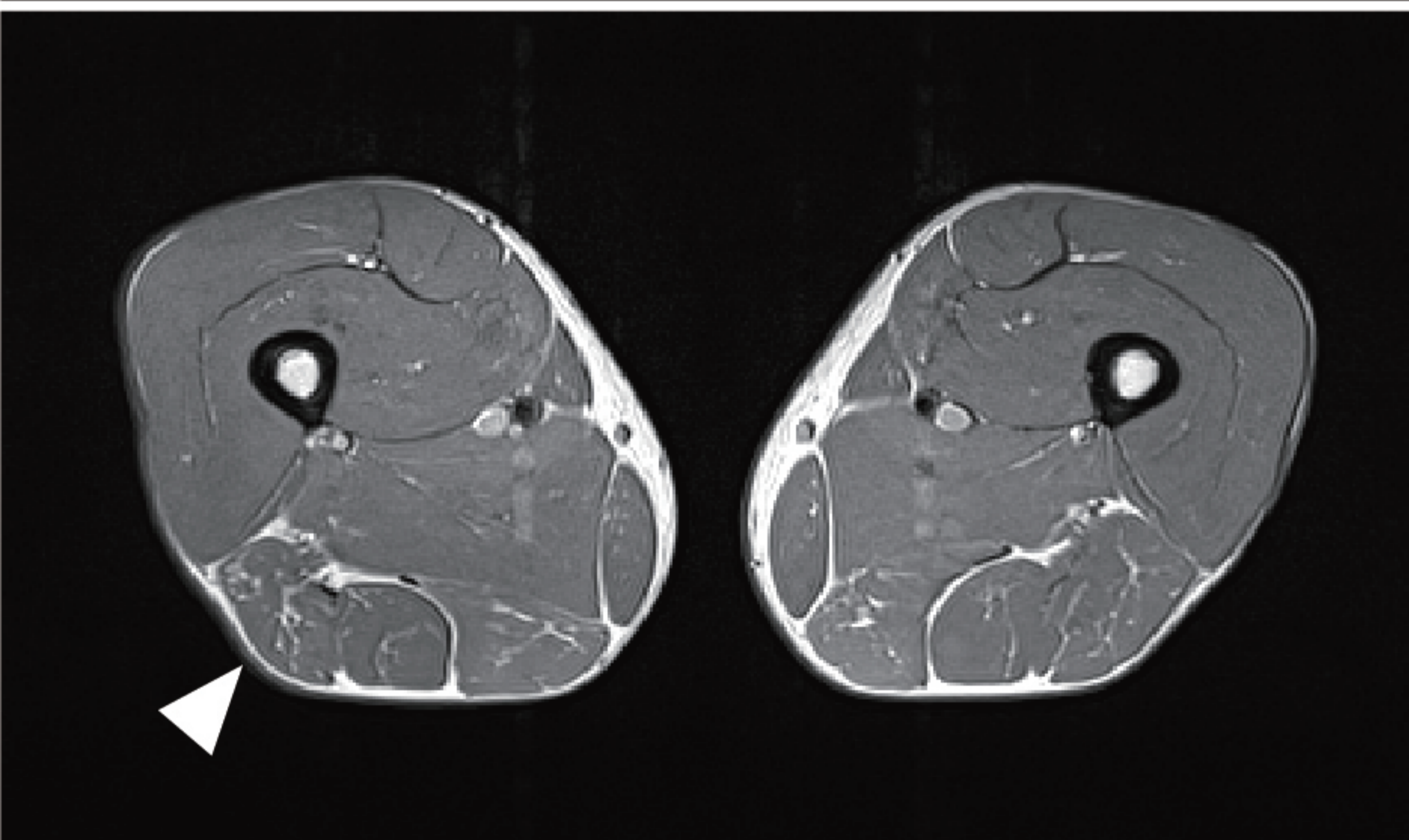
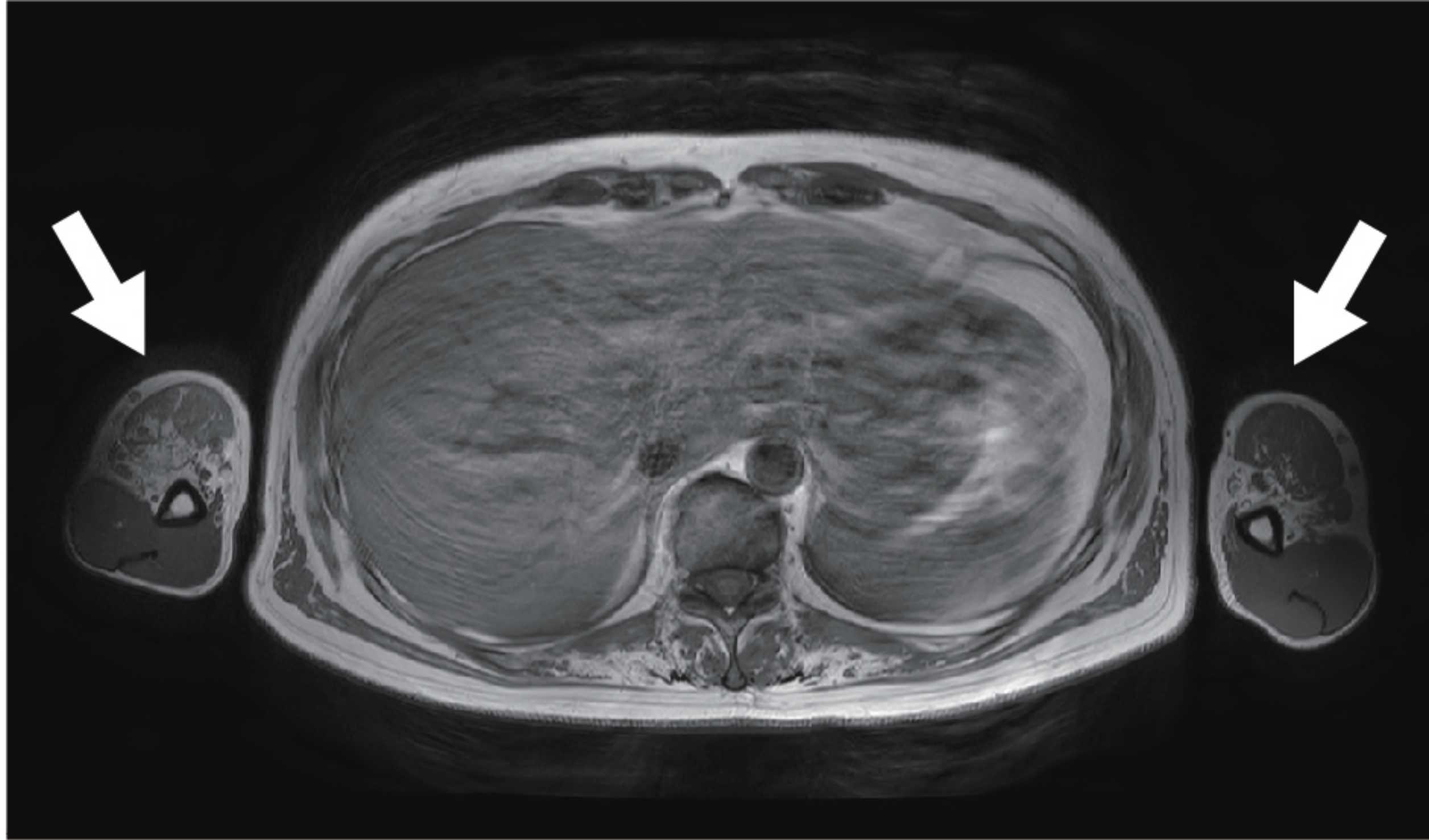
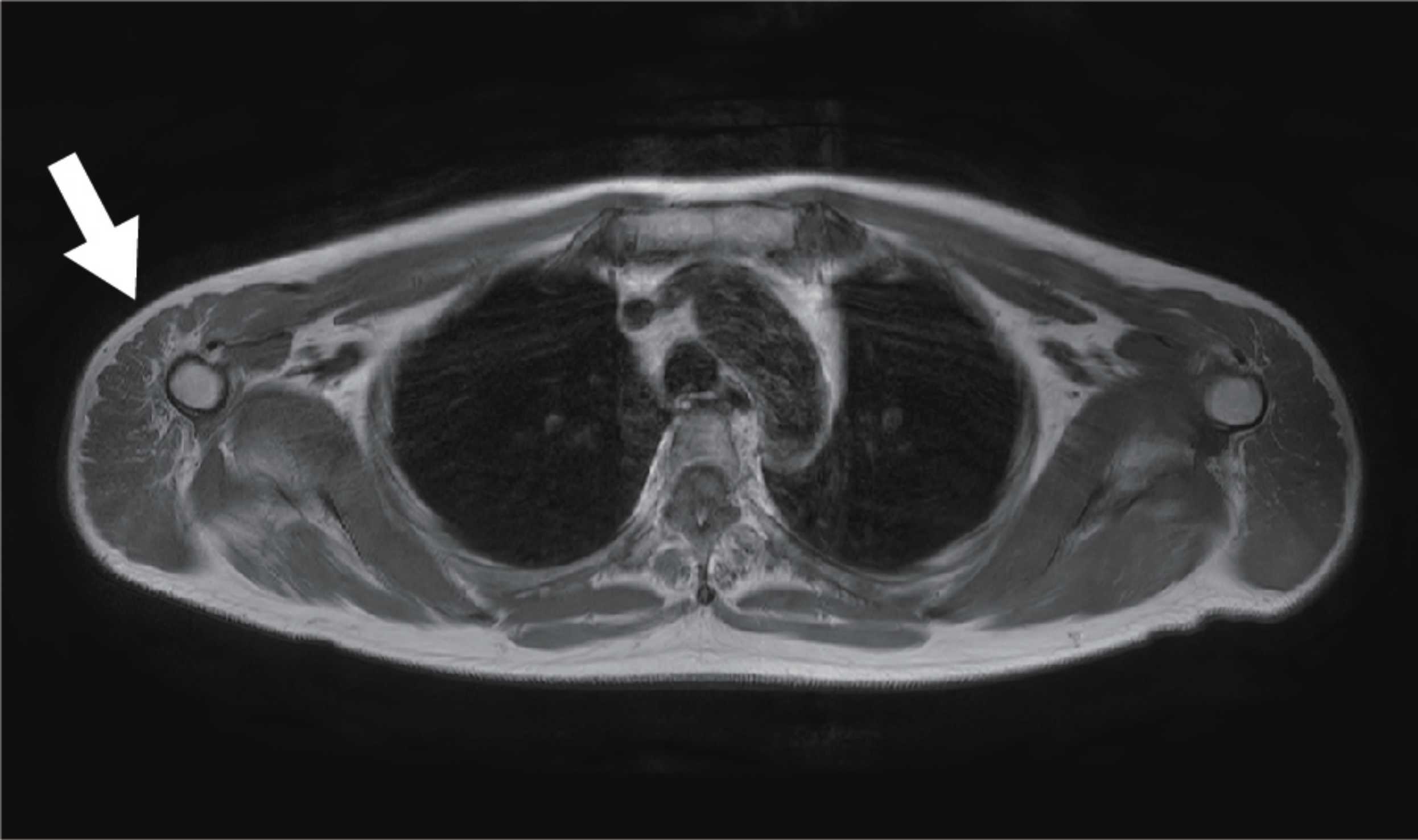
B) Modified Gomori trichrome staining revealed massive vacuoles with myofibers and rimmed vacuoles (arrowhead).

C) Oil red O staining revealed accumulation of a large number of lipid droplets consistent with the vacuoles seen in (A) and (B).

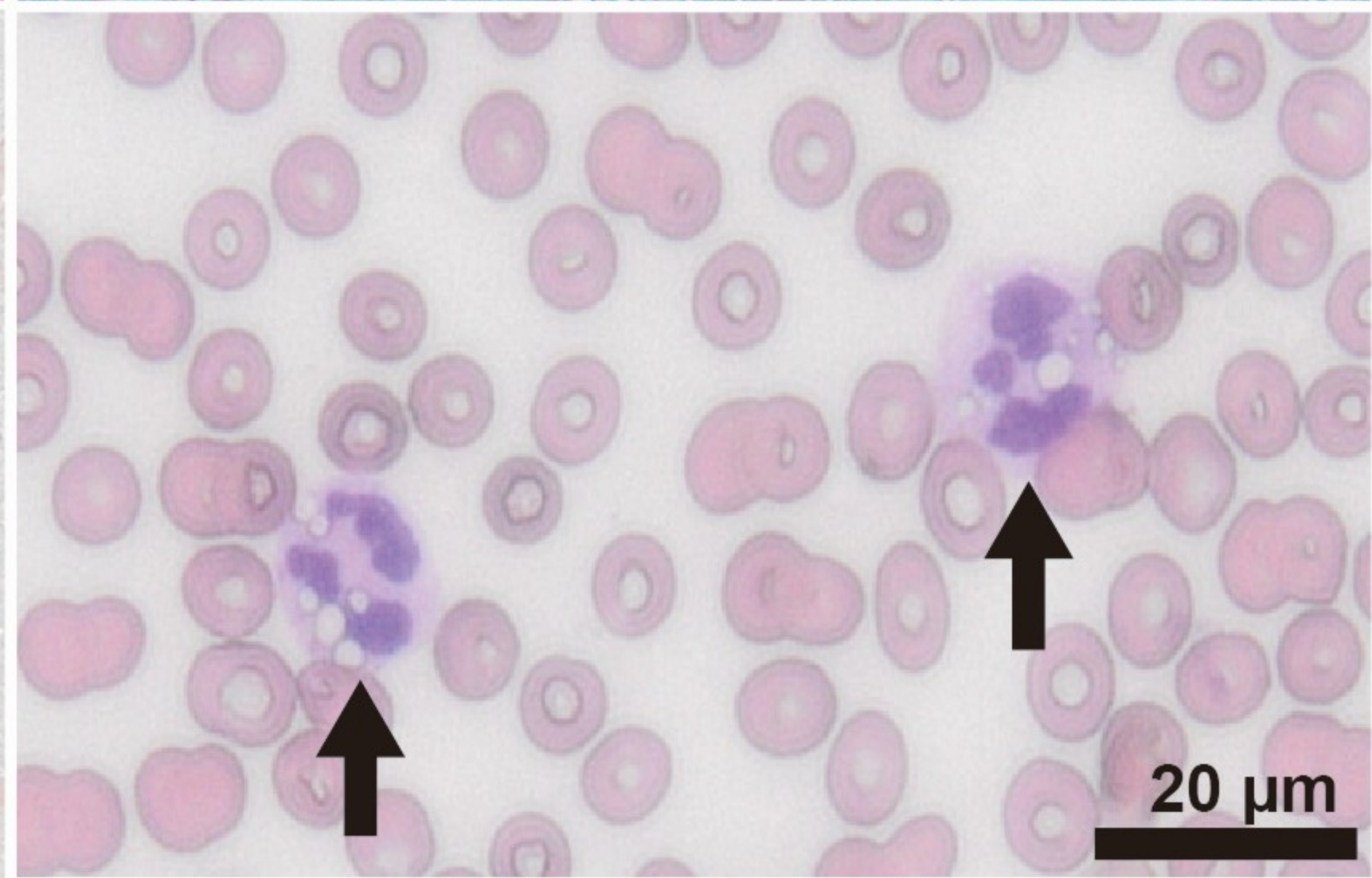
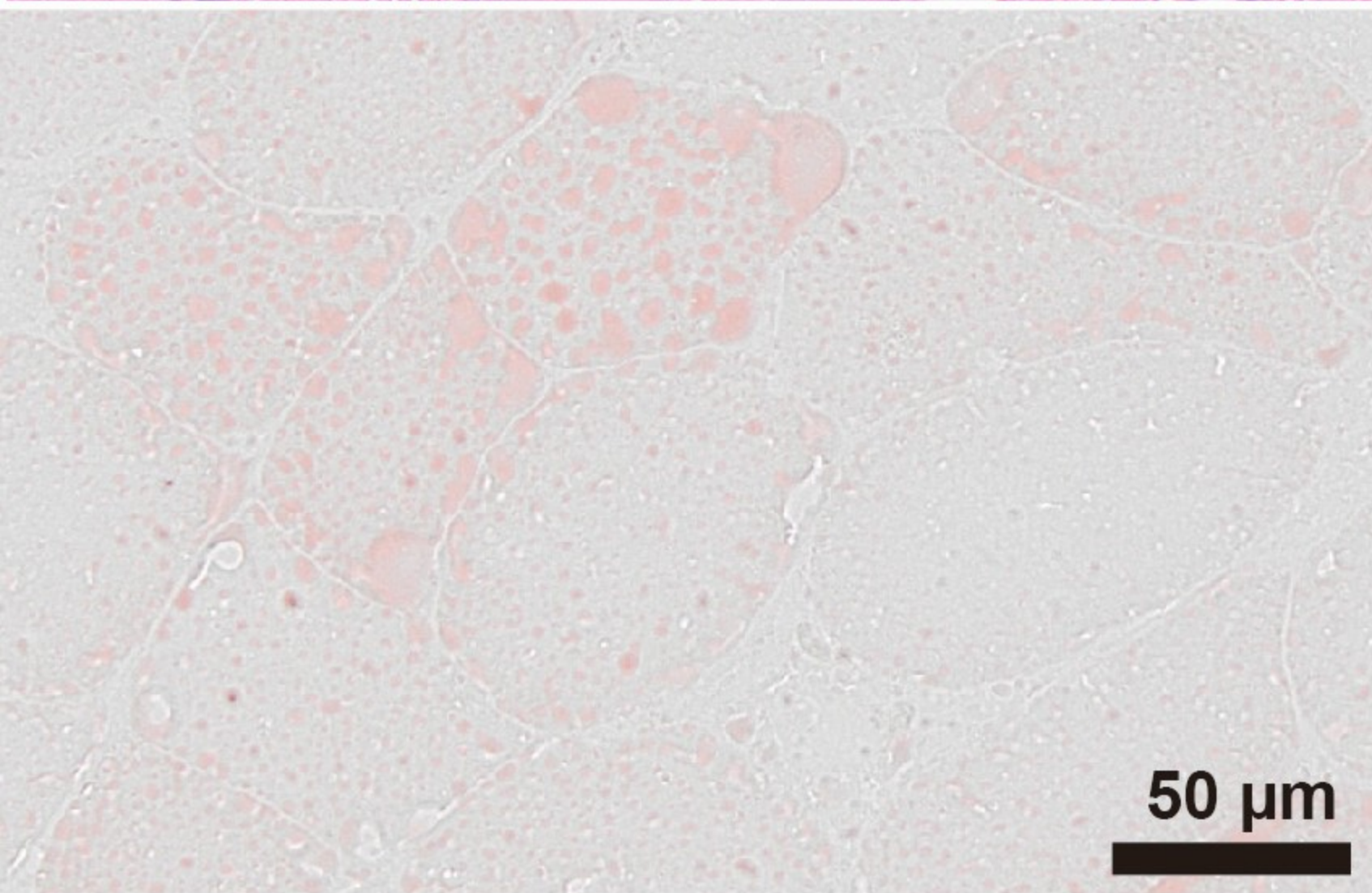
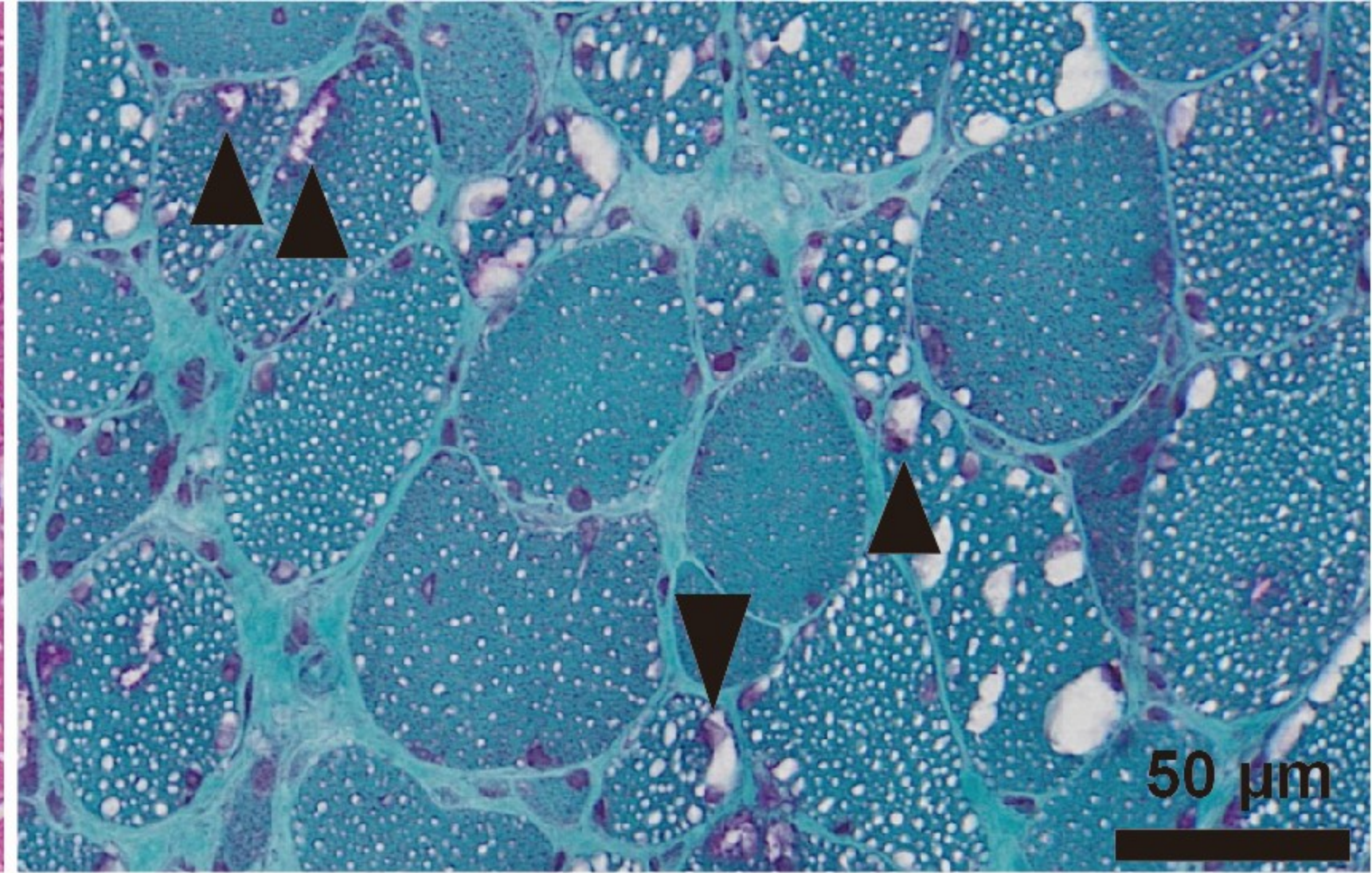
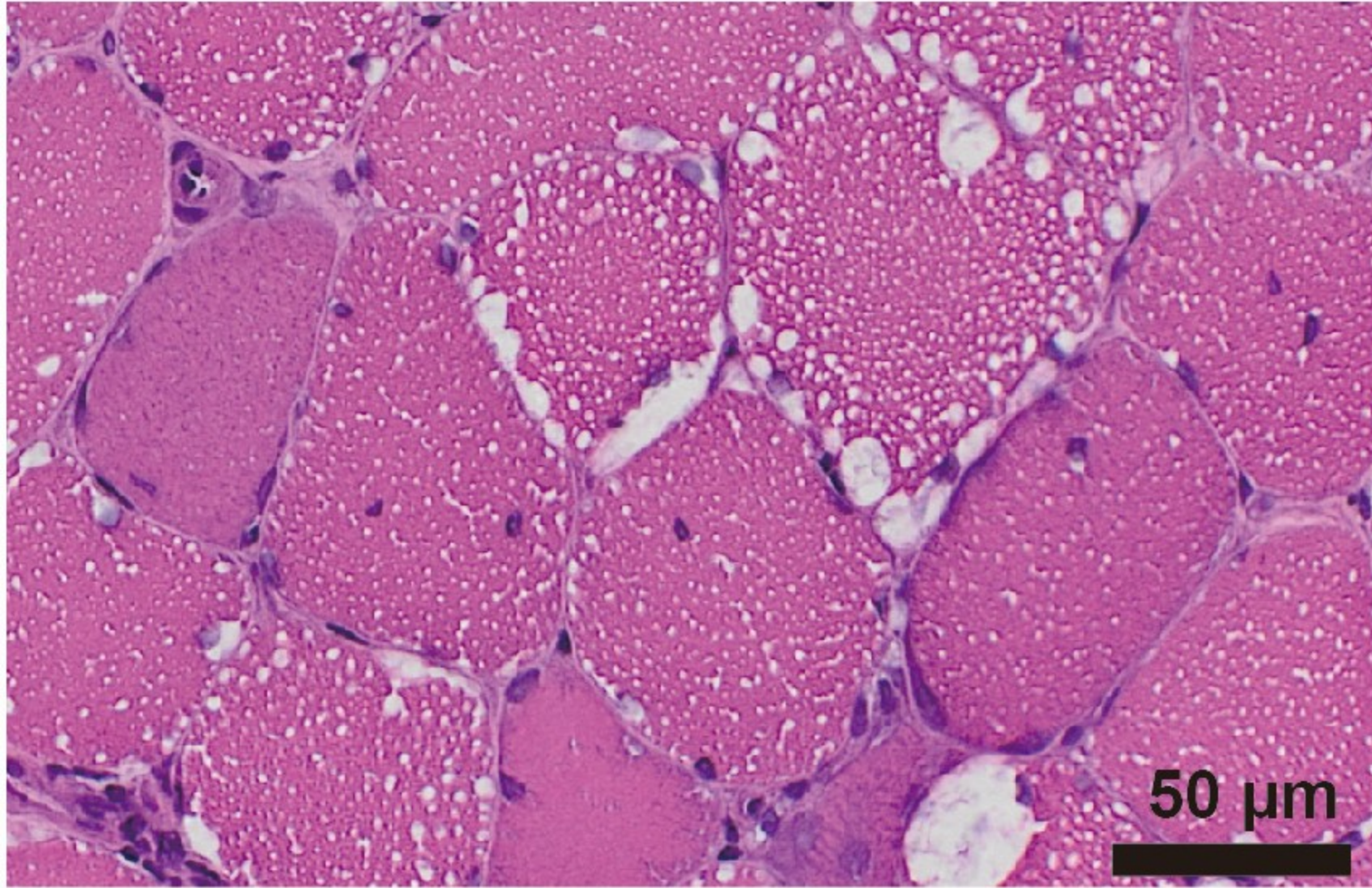
D) Peripheral blood smear showed cytoplasmic vacuolization in a polymorphonuclear leukocyte (Jordan's anomaly) (arrow).

References

1. Missaglia S, Tavian D, Angelini C. Neutral lipid storage disease with myopathy: A 10-year follow-up case report. *Eur J Transl Myol.* 2022;32(2).
2. Tan J, Yang H, Fan J, Fan Y, Xiao F. Patients with neutral lipid storage disease with myopathy (NLSDM) in Southwestern China. *Clin Neurol Neurosurg.* 2018;168:102–7.
3. Zhang W, Wen B, Lu J, Zhao Y, Hong D, Zhao Z, et al. Neutral lipid storage disease with myopathy in China: a large multicentric cohort study. *Orphanet J Rare Dis.* 2019;14(1).
4. Zhang R, Meng J, Yang S, Liu W, Shi L, Zeng J, et al. Recent Advances on the Role of ATGL in Cancer. *Front Oncol.* 2022;12.
5. Li Z, Liu H, Luo X. Lipid droplet and its implication in cancer progression. *Am J Cancer Res.* 202;10(12):4112.



Yamada et al. Figure 1



Yamada et al. Figure 2